



Patient Name: MANOJ KUMAR JHA

M/ 52 Yrs.

Ref. by:

Date: 16/2/2024

SONOGRAPHY OF ABDOMEN AND PELVIS

TECHNIQUE: Real time, B mode, gray scale sonography of the abdominal and pelvic organs was performed with convex transducer.

LIVER: The liver is normal in size, shape and has smooth margins. The hepatic parenchyma shows normal homogeneous echotexture without solid or cystic mass lesion or calcification. No evidence of intrahepatic biliary radical dilatation.

PORTAL VEIN: It measures normal in diameter.

GALL BLADDER: The gall bladder is well distended. There is no evidence of calculus, wall thickening or pericholecystic collection.

COMMON BILE DUCT: The visualised common bile duct is normal in caliber. No evidence of calculus is seen in the common bile duct. Terminal common bile duct is obscured due to bowel gas artifacts.

PANCREAS: The head and body of pancreas is normal in size, shape, contours and echo texture. Rest of the pancreas is obscured due to bowel gas artifacts.

SPLEEN: The spleen is normal in size and shape. Its echotexture is homogeneous.

KIDNEYS:

Right kidney	Left kidney
10.0 x 4.2 cm	9.5 x 5.0 cm

The kidneys are normal in size and have smooth renal margins. Cortical echotexture is normal. The central echo complex does not show evidence of hydronephrosis. No evidence of hydroureter or calculi, bilaterally.

URINARY BLADDER: The urinary bladder is well distended. It shows uniformly thin walls and sharp mucosa. No evidence of calculus is seen. No evidence of mass or diverticulum is noted. Significant post void residue is seen. Pre-void volume is approx. 360 cc. Post-void volume is approx. 90 cc.

PROSTATE: It is enlarged and measures about 4.5 x 4.3 x 3.7 cms; with a weight of 37 gm. The prostate gland shows well defined and smooth margins. The prostatic echotexture is normal and homogeneous.

There is no ascites. There is no obvious evidence of significant lymphadenopathy.

IMPRESSION:

- **Prostatic enlargement with post-void residue.**
- **No other abnormality detected.**

Thanks for the reference.

With regards,

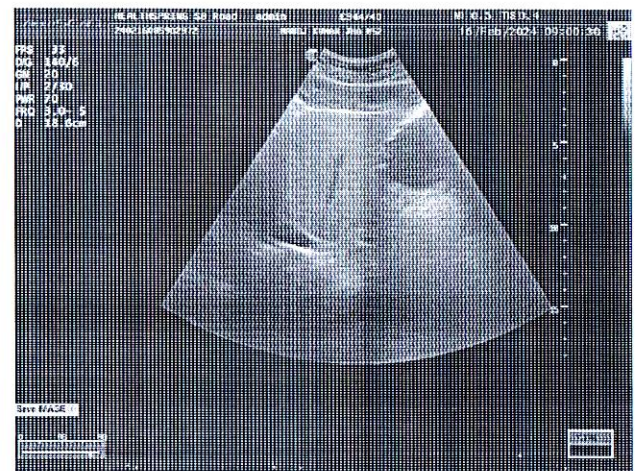
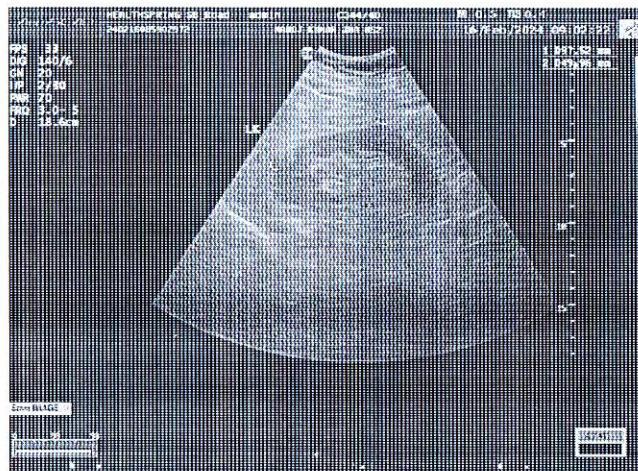
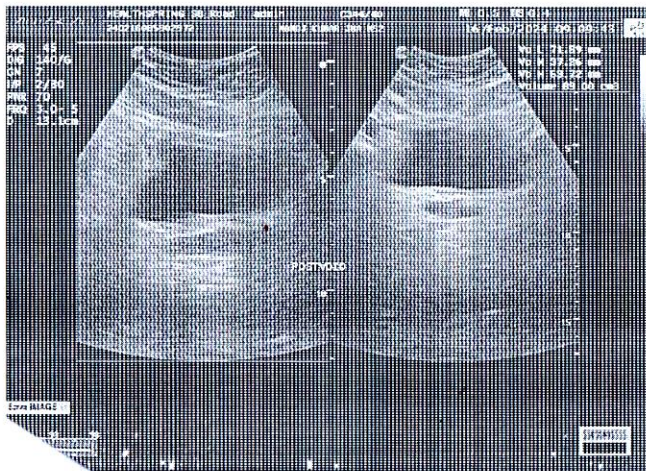
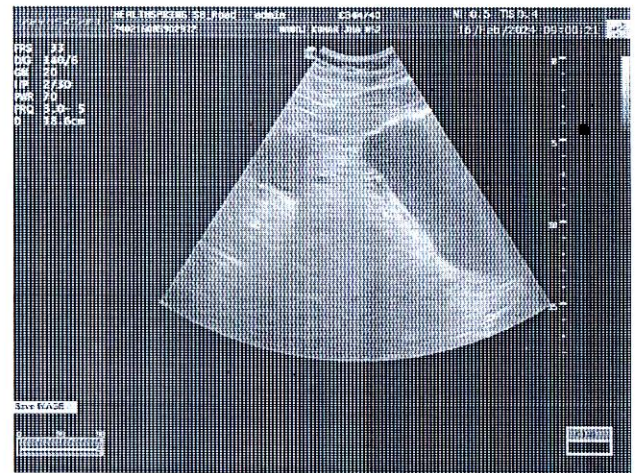
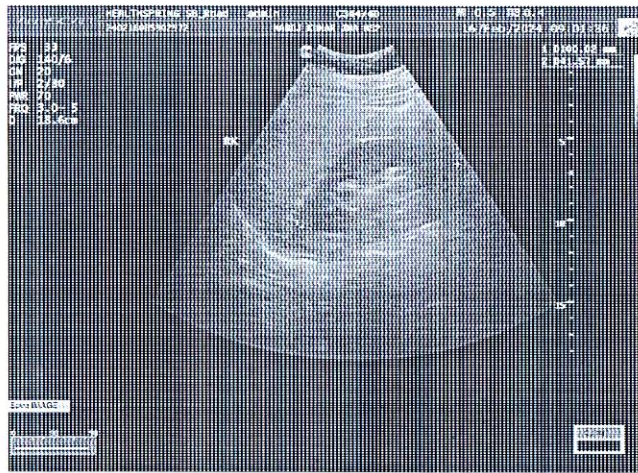
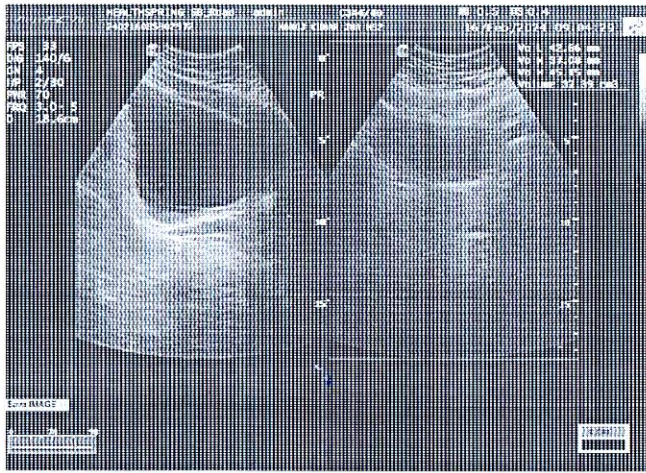
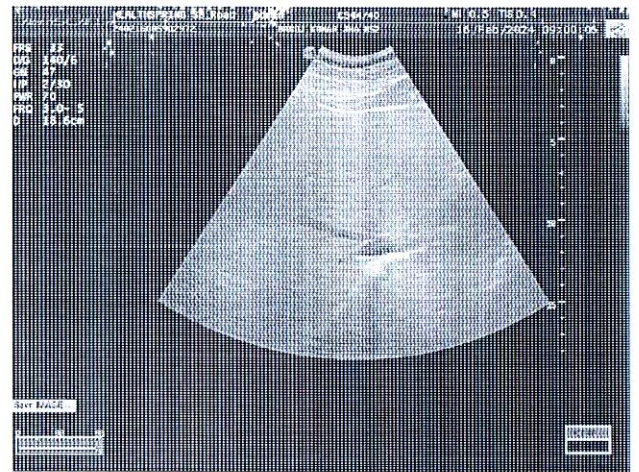
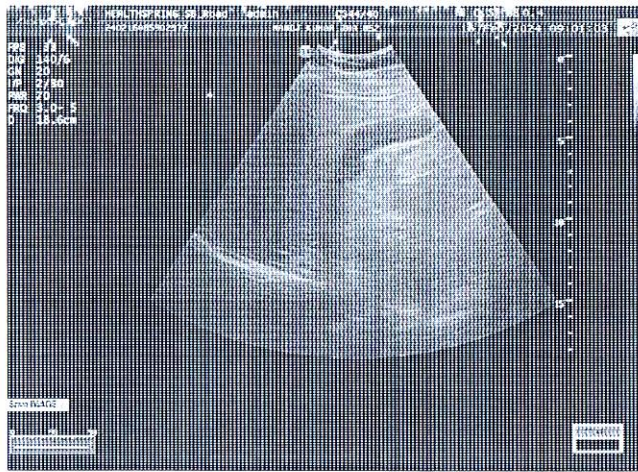
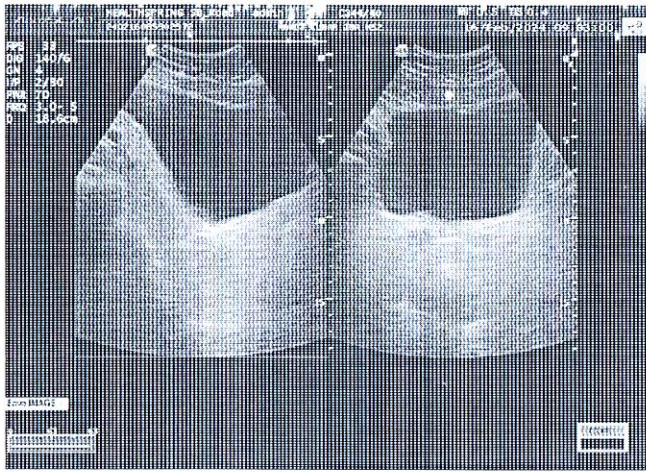


DR. Nitish Kotwal

CONSULTANT RADIOLOGIST

(MBBS, DMRD RADIOLOGY)

Investigations have their limitations. Solitary pathological/Radiological and other investigations never confirm the final diagnosis. They only help in diagnosing the disease in correlation to clinical symptoms and other related tests. Please interpret accordingly.





भारत सरकार

Government of India



Issue Date: 11/04/2012



मनोज कुमार झा

Manoj Kumar Jha

जन्म तिथि/DOB: 01/04/1971

पुरुष/ MALE

4487 1974 3513

VID : 9174 9799 1960 2674

मेरा आधार, मेरी पहचान

F12

Print
Screen

Scroll
Lock



Pause
Break

K120



GPS Map Camera



Google

Mumbai, Maharashtra, India

Shri Krishna Complex, KL Walawalkar Marg, Corner of new link road and fun cinemas lane, Veera Desai Industrial Estate, Andheri West, Mumbai, Maharashtra 400053, India
Lat 19.135455°

Long 72.832411°

16/02/24 10:16 AM GMT +05:30



GPS Map Camera



Google

Mumbai, Maharashtra, India

Shri Krishna Complex, KL Walawalkar Marg, Corner of new link road and fun cinemas lane, Veera Desai Industrial Estate, Andheri West, Mumbai, Maharashtra 400053, India
Lat 19.135466°

Long 72.832411°

16/02/24 10:15 AM GMT +05:30