


Name : Mrs. Sunitha Subash	Age : 42 Y	UHID :DKOR.0000023066
	Sex : F	
Address : KORAMANGALA		OP Number :CELEOPV342303
Plan : ARCOFEMI MEDIWHEEL FEMALE AHC CREDIT PAN INDIA OP AGREEMENT		Bill No :CELE-OCR-55573
		Date : 09.03.2024 08:12

Sno	Service Type/ServiceName	Department
1	ARCOFEMI - MEDIWHEEL - FULL BODY ANNUAL PLUS CHECK ADVANCED - FEMALE - 2D ECHO - PAN INDIA - FY2324	
1	GAMMA GLUTAMYL TRANSFERASE (GGT) - 12	
2	D ECHO - 11	
3	LIVER FUNCTION TEST (LFT)	
4	GLUCOSE, FASTING	
5	HEMOGRAM + PERIPHERAL SMEAR	
6	GYNACOBGLOGY CONSULTATION - 16 DR KRISHNA SHAN	
7	DIET CONSULTATION	
8	COMPLETE URINE EXAMINATION	
9	URINE GLUCOSE(POST PRANDIAL)	
10	PERIPHERAL SMEAR	
11	ECG - 13	
12	LBC PAP TEST- PAPSURE - 16	
13	RENAL PROFILE/RENAL FUNCTION TEST (RFT/KFT)	
14	DENTAL CONSULTATION - 15/20	
15	GLUCOSE, POST PRANDIAL (PP), 2 HOURS (POST MEAL)	
16	URINE GLUCOSE(FASTING)	
17	SONO MAMOGRAPHY - SCREENING - 8	
18	HbA1c, GLYCATED HEMOGLOBIN	
19	X-RAY CHEST PA - 9	
20	ENT CONSULTATION - 6	
21	FITNESS BY GENERAL PHYSICIAN	
22	BLOOD GROUP ABO AND RH FACTOR	
23	LIPID PROFILE	
24	BODY MASS INDEX (BMI)	
25	OPHTHAL BY GENERAL PHYSICIAN - 5	
26	ULTRASOUND - WHOLE ABDOMEN - 8	
27	THYROID PROFILE (TOTAL T3, TOTAL T4, TSH)	

Phyio - 14
Audiology - 3

BMI - 24.4

RE 6/6 N8
LE 6/6 N8

Correction
RE = Plano
+1.00DS
LE = -0.25
-0.75DS

MEDICAL FITNESS CERTIFICATE

DATE:

NAME:

AGE/SEX:

UHID:

CHIEF COMPLAINTS:

PAST/FAMILY HISTORY:

ALLERGIES:

GENERAL EXAMINATION:

PULSE: 60	BP: 112/72	TEMP:	RR:
HT: 146	WT: 52.1	WAIST:	BMI:

Vision	Rt	Lt	With Correction
DISTANT			
NEAR			
COLOUR			

vision (optical)

RE - 6/6 N8
LE - 6/6 P N8

Correction

RE = Plano
x 1.00 DSP

LE = -0.25
-0.75 DSP

SYSTEMIC EXAMINATION

Chest:

Cvs:

P/A:

IMPRESSION:

FINAL RECOMMENDATION:

GENERAL PHYSICIAN

Apollo Clinic

Consent Form


Patient Name: Sunitha Subash Age: 43

UHID Number: AKOR 23066 Company Name: Bank of Baroda

I Mr/Mrs/Ms. Sunitha Subash Employee of Bank of Baroda
(Company) want to inform you that I am not getting the Diet consultation
test done which is a part of routine health check package.

Reason if any: Reports are unavailable at this point of time.

And I claim the above statement in my full consciousness.

Patient signature:  Date: 9/3/24
Sunitha P.P

ms. Sunita Subash 42 F.

9/3/24.
Dr. KRISHNA SHANU
Gynaec.

HIC + LABC

Height :	Weight :	BMI :	Waist Circum :
Temp :	Pulse :	Resp :	B.P :

General Examination / Allergies
History

Clinical Diagnosis & Management Plan

H/O - 3/2/24.
P/L2 - BOTH LSCS.
P/A - NAD
P/B + P/V OK - (A).
B/L Br - NO Imp.

P/H -

AdV
R/w Report
B

Follow up date:

Doctor Signature

Ms. Sunita Subash

9/3/24

424/F

Dr. YASHASWI, MBBS, DLO
FELLOW IN RHINOLOGY
ALLERGY SPECIALIST
REG. No.: 71613
MOB.: 9448089291 / 9945126633

Height :	Weight :	BMI :	Waist Circum :
Temp :	Pulse :	Resp :	B.P :

General Examination / Allergies
History

Clinical Diagnosis & Management Plan

came for regular ENT
check-up
O/E (R) (L)
EAC (N) (N)
TM (R) (L)
Nose - B/L HIT
Throat - NAD
clinically ENT - NAD



Follow up date:

Doctor Signature

Patient Name : Mrs. Sunitha Subash
UHID : DKOR.0000023066
Reported on : 10-03-2024 09:02
Adm/Consult Doctor :

Age : 42 Y F
OP Visit No : CELEOPV342303
Printed on : 10-03-2024 09:02
Ref Doctor : SELF

DEPARTMENT OF RADIOLOGY

X-RAY CHEST PA


Both lung fields and hila are normal .
No obvious active pleuro-parenchymal lesion seen .
Both costophrenic and cardiophrenic angles are clear .
Both diaphragms are normal in position and contour .
Thoracic wall and soft tissues appear normal.

CONCLUSION :

No obvious abnormality seen

Printed on:10-03-2024 09:02

---End of the Report---


Dr. VIGNESH K
MBBS, MD Radio-Diagnosis
Radiology

Apollo Health and Lifestyle Limited

(CIN - U85110TG2000PLC115819)

Regd. Office: 1-10-60/62, Ashoka Raghupathi Chambers, 5th Floor, Begumpet, Hyderabad, Telangana - 500 016.

Ph No: 040-4904 7777, Fax No: 4904 7744 | Email ID: enquiry@apollohl.com | www.apollohl.com

APOLLO CLINICS NETWORK KARNATAKA

Bangalore (Basavanagudi | Bellandur | Electronic City | Fraser Town | HSR Layout | Indira Nagar | JP Nagar | Kundalahalli | Koramangala | Sarjapur Road) **Mysore** (VV Mohalla)

Online appointments: www.apolloclinic.com

TO BOOK AN APPOINTMENT

 **1860 500 7788**

2-D ECHO-CARDIOGRAPHY DOPPLER & COLOUR DOPPLER REPORT

NAME : MRS SUNITHA SUBASH

DATE:09/03/2024


AGE/SEX: 42 Y/ F

REF : ARCOFEMI- MEDIWHEEL

UHID: 23066/03/47

***** MEASUREMENTS & FLOW VELOCITIES AS DEPICTED IN IMAGES OVERLEAF.**

1. NORMAL VALVES.
2. NORMAL FLOW ACROSS ALL VALVES.
3. NO MR/ AR/ TR.
4. NORMAL GREAT VESSELS.
5. NORMAL SYSTEMIC VEINS & AT LEAST 3 PULMONARY VEINS SEEN DRAINING INTO LA.
6. NORMAL SIZED CHAMBERS.
7. NO REGIONAL WALL MOTION ABNORMALITIES.
8. INTACT SEPTAE (IVS & IAS).
9. GOOD LV & RV SYSTOLIC FUNCTION.
10. PERICARDIUM : NORMAL
11. NO OBVIOUS VEGETATION / CLOTS.



DR (CAPT.)S.V KRISHNA RAO

MD (PGI), DNB (Card)

Senior Consultant – Cardiologist

Reg No : ANP 19780000746KTK

To correlate with clinical findings & other relevant investigations .

Apollo Health and Lifestyle Limited

(CIN - U85110TG2000PLC115819)

Regd. Office: 1-10-60/62, Ashoka Raghupathi Chambers, 5th Floor, Begumpet, Hyderabad, Telangana - 500 016.

Ph No: 040-4904 7777, Fax No: 4904 7744 | Email ID: enquiry@apollohl.com | www.apollohl.com

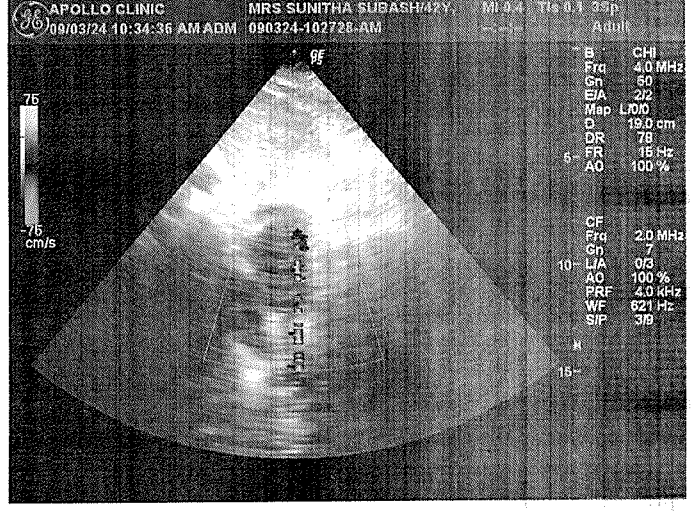
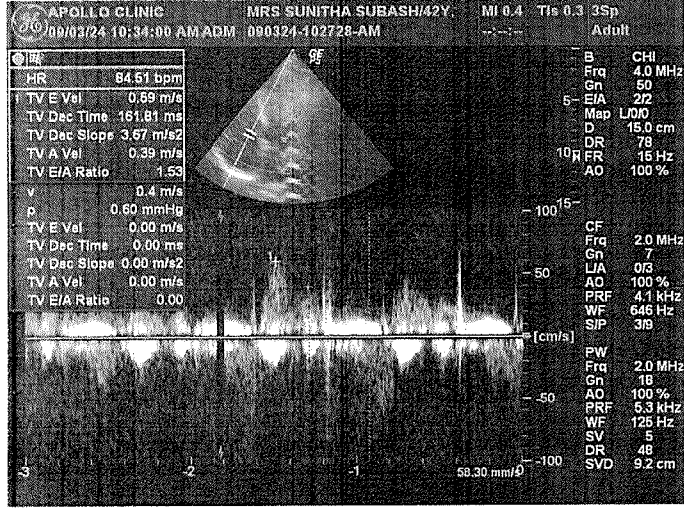
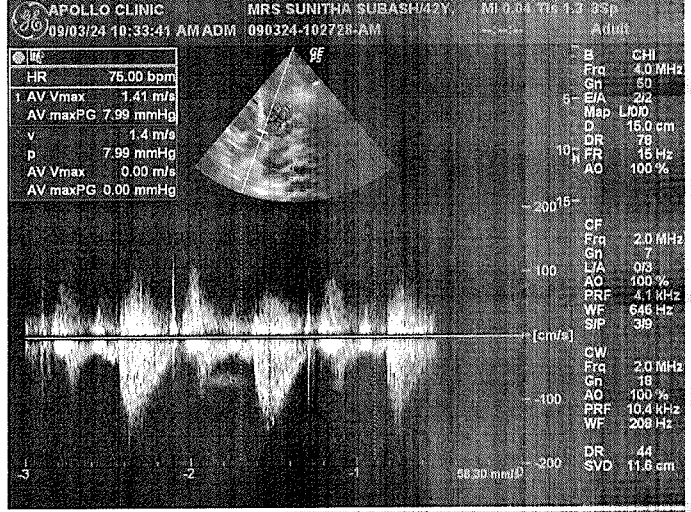
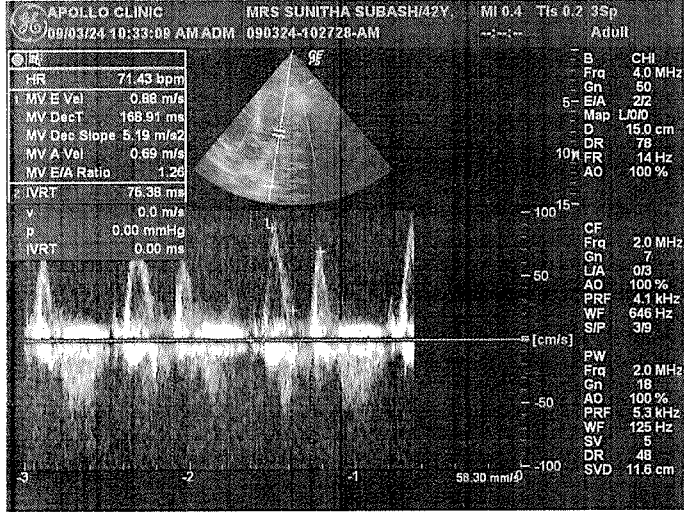
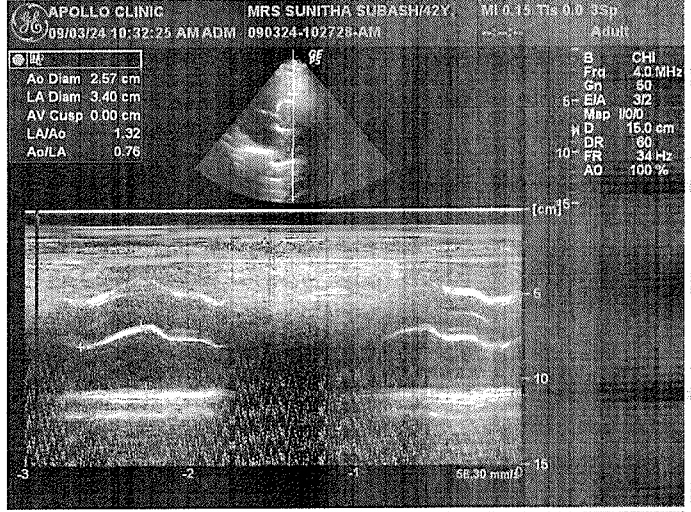
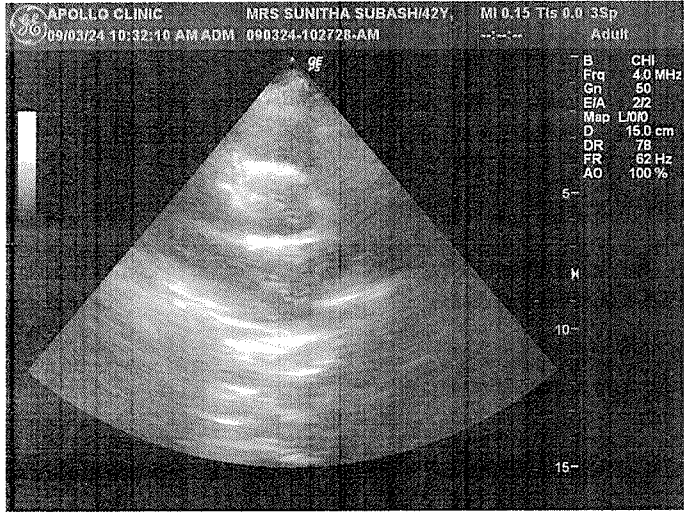
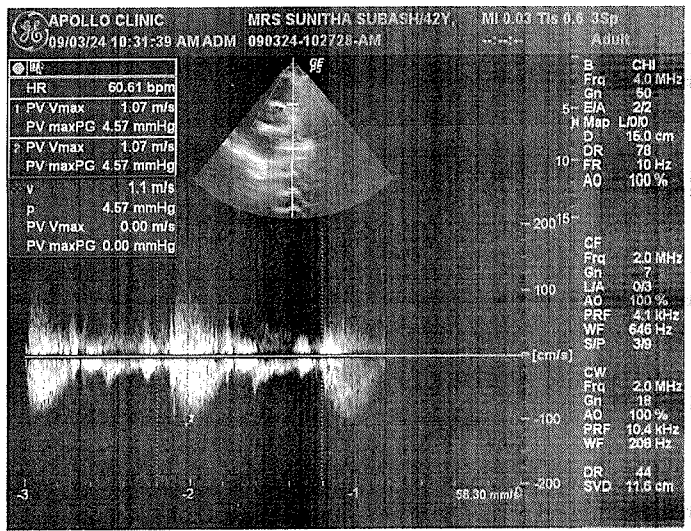
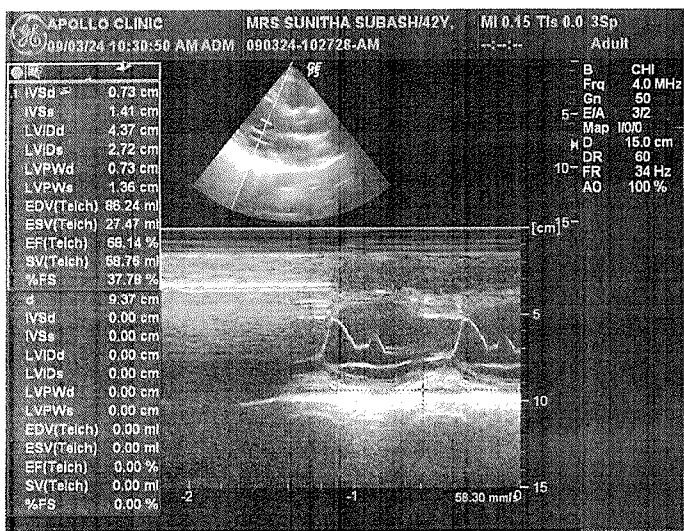
APOLLO CLINICS NETWORK KARNATAKA

Bangalore (Basavanagudi | Bellandur | Electronic City | Fraser Town | HSR Layout | Indira Nagar | JP Nagar | Kundalahalli | Koramangala | Sarjapur Road) **Mysore** (VV Mohalla)

Online appointments: www.apolloclinic.com

TO BOOK AN APPOINTMENT

 **1860 500 7788**



NAME:	MRS. SUNITHA SUBASH
AGE / SEX:	42 YRS/ FEMALE
DATE:	09/03/2024
REFERRED BY:	ARCOFEMI

ABDOMINAL ULTRASONOGRAPHY REPORT

LIVER: Appear normal in size and echogenicity. No focal lesion seen. The intra hepatic biliary and portal venous radicals are normal. Portal vein and CBD is normal.

GALL BLADDER: moderately distended and appears normal. No abnormal wall thickening / pericholecystic fluid seen.

Pancreas: normal to the extend visualized.

SPLEEN: Normal in size and echo texture. No focal lesion noted

KIDNEYS: Both kidneys are normal in position, size and echo texture. Normal cortico-medullary differentiation is maintained. No calculus/ hydronephrosis on both sides.

PELVIC ORGANS:

Urinary bladder well distended and appears normal in size, contour and wall thickness.

Uterus appear normal in size and echo texture . Myometrial echoes appear normal.
ET measures ~ 8.9 mm.

Bilateral ovaries are normal in size, shape and echo texture.

No free fluid in the abdomen and pelvis.

IMPRESSION:

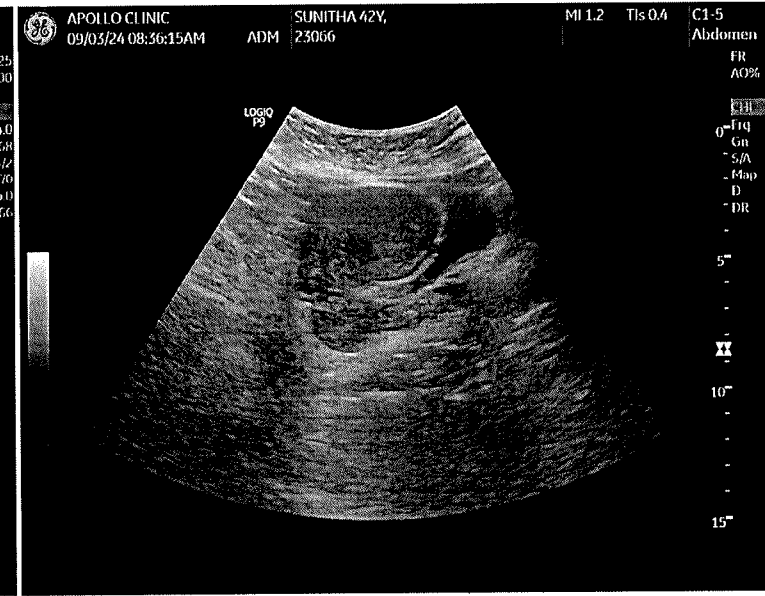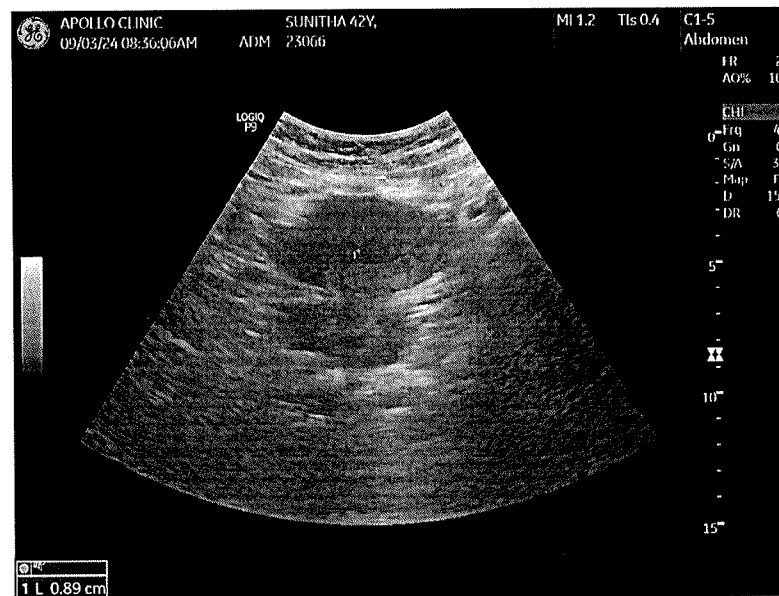
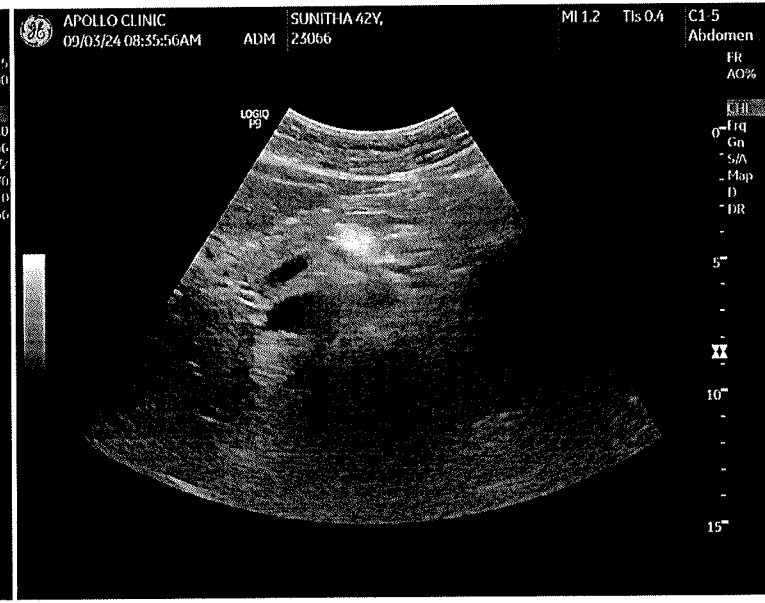
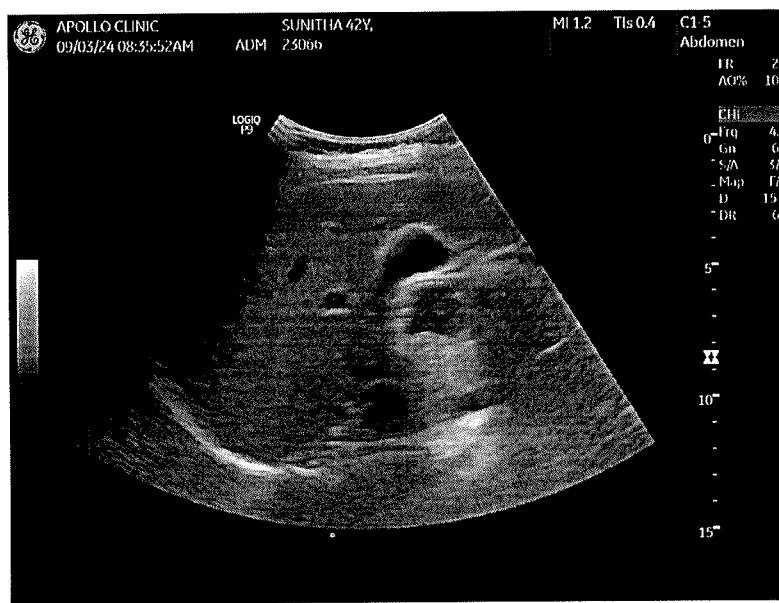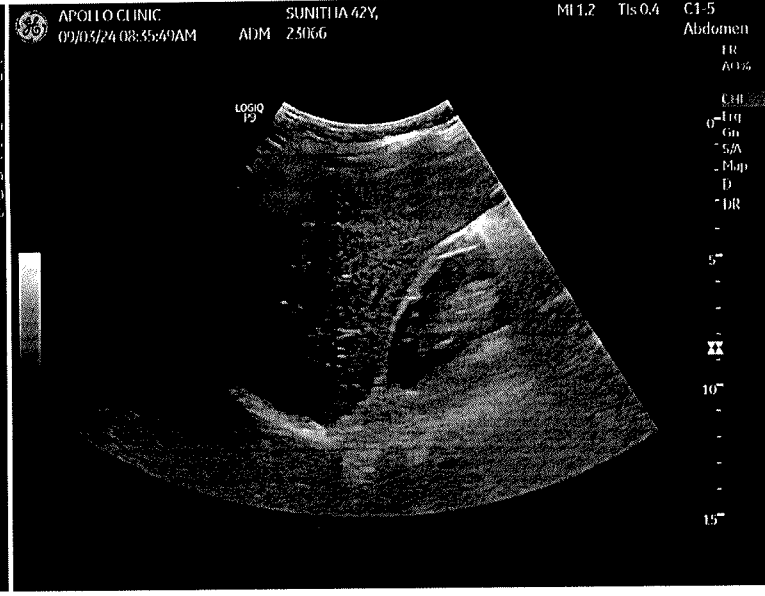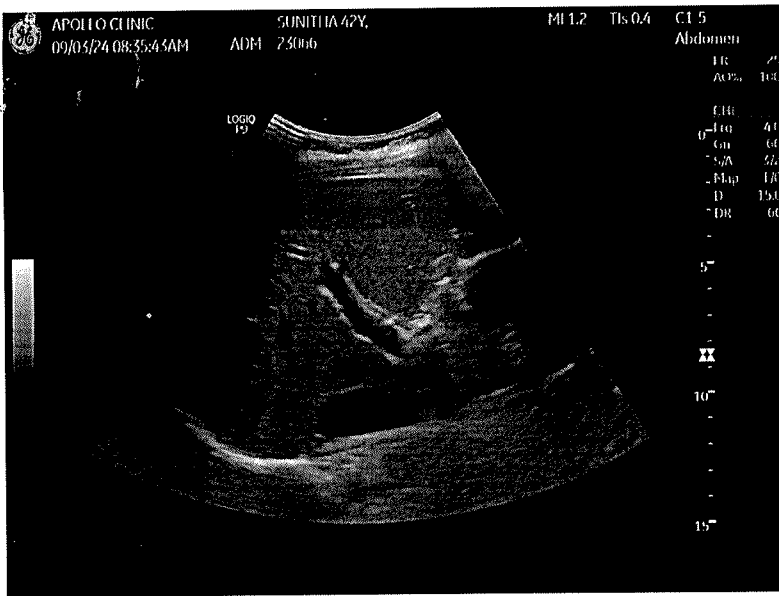
- ***No definitive sonological abnormality detected in present scan .***

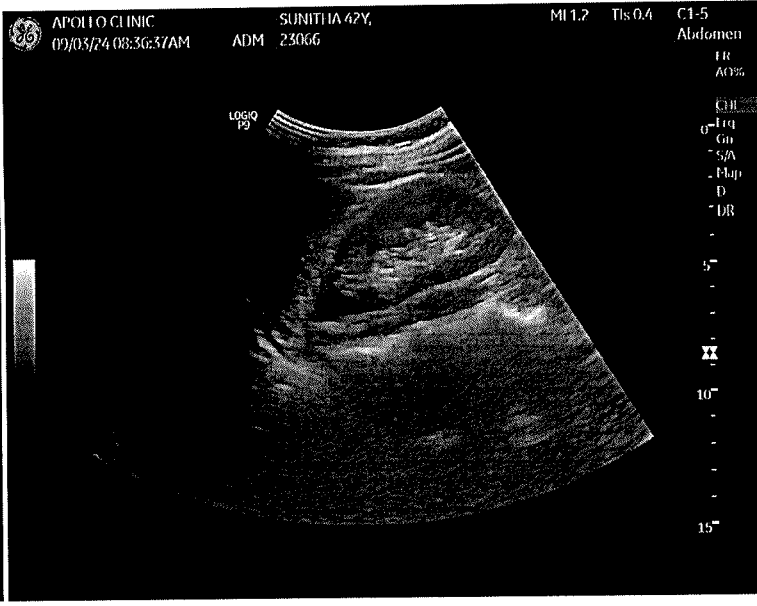
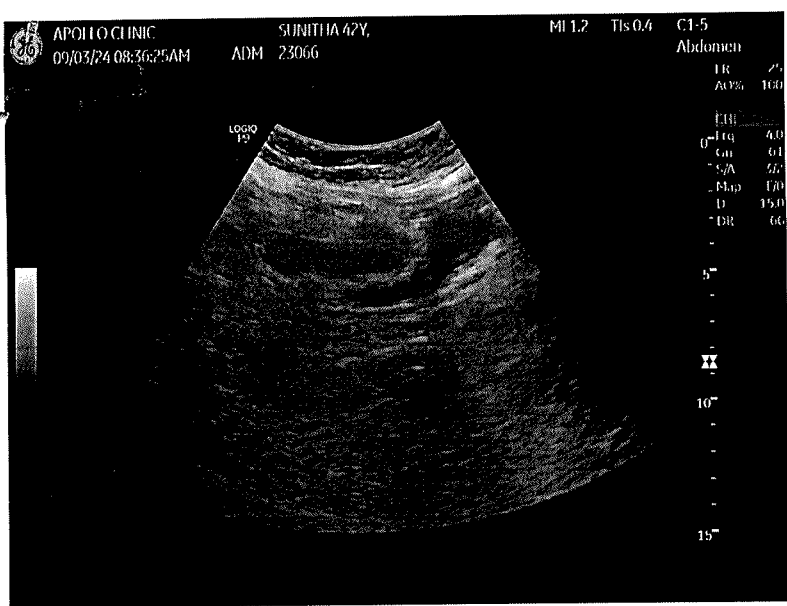
*To correlate clinically & with other investigations.
Not for medico-legal purpose*



DR. VIGNESH K

CONSULTANT RADIOLOGIST





Personal Details
UHID: 00XHEIPU6TF00VH
PatientID: 23066
Name: Mrs Sunitha Subash
Age: 42
Gender: Female
Mobile: 9740646383


Pre-Existing Medical- Symptoms
Conditions

Vitals

Measurements
HR: 53 BPM
PR: 153 ms
PD: 123 ms
QRSD: 76 ms
QRS Axis: - deg
QT/QTc: 399/399 ms

Report ID: AHLIP_00XHEIPU6TF00VH_V6TF00X3
Interpretation
Sinus Rhythm Regular Bradycardia
Normal Axis

Apollo Medical
Centre

Authorized by

Dr. Yogesh Kothari
M.D, DNB, FESC, FEP
Rep No- KMC 44065

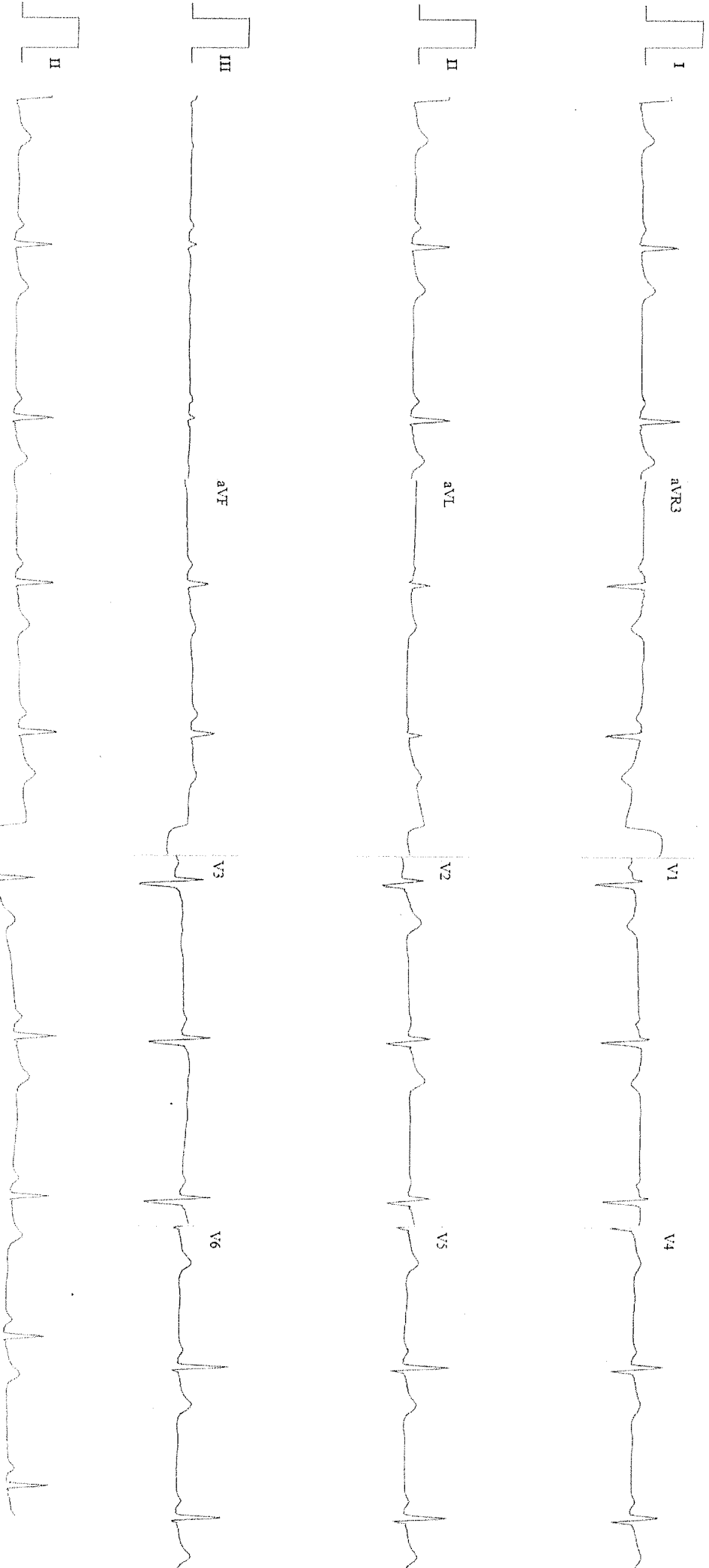


Fig. 1: Analysis of this report is based on 12-lead surface ECG. The results should be used as an advisory tool only and must be interpreted by a qualified physician.
Speed: 25 mm/sec F: 0.05 - 40 Hz Limb: 10 mm/mV Chest: 10 mm/mV

Version: 1.1.1 Copyright: Apollo Medical Centre

Fwd: Health Check up Booking Confirmed Request(bobS12671),Package Code-PKG10000367, Beneficiary Code-299338

Sunitha P.P <sunithapp@gmail.com>

Sat 2024-03-09 7:55 AM

To: Electronic City <ecity@apolloclinic.com>

----- Forwarded message -----

From: **Mediwheel** <wellness@mediwheel.in>

Date: Sun, 3 Mar, 2024, 5:24 pm

Subject: Health Check up Booking Confirmed Request(bobS12671),Package Code-PKG10000367, Beneficiary Code-299338

To: <sunithapp@gmail.com>

Cc: <customercare@mediwheel.in>

011-41195959

Dear **Sunitha P P,**

We are pleased to confirm your health checkup booking request with the following details.

Hospital Package Name : Mediwheel Full Body Annual Plus Above 50 Male

Patient Package Name : Mediwheel Full Body Health Checkup Male Above 40

Name of Diagnostic/Hospital : Apollo Clinic - Electronic City

Address of Diagnostic/Hospital- Apollo Clinic, 323/100, Opp.Ajmera infinity Apartment, Neeladri Nagar, Electronic city Phase -1, Electronic city - 560100

City : Bangalore

State :

Pincode : 560100

Appointment Date : 09-03-2024

Confirmation Status : Booking Confirmed

Preferred Time : 8:30am

Booking Status : Booking Confirmed

Member Information		
Booked Member Name	Age	Gender
Subash Balasubramaanaam	47 year	Male

Note - Please note to not pay any amount at the center.

Instructions to undergo Health Check:



ಭಾರತ ಚುನಾವಣಾ ಆಯೋಗ
ELECTION COMMISSION OF INDIA

ಮತದಾರರ ಪೋಟೋ ಗುರುತಿನ ಕಾರ್ಡ್ - Elector Photo Identity Card



AAH6836175



ಹೆಸರು : ಸುನಿತಾ ಸುಬಾಶ್

Name : SUNITHA SUBASH

ಗಂಡಿನ ಹೆಸರು : ಸುಬಾಶ್ ಬಾಲಸುಬ್ರಮಣ್ಯಂ

Husband's Name : SUBASH BALASUBRAMANIAM

ಲಿಂಗ / Gender : ಮಹಿಳೆ / Female

ಜನ್ಮ ದಿನಾಂಕ/ವಯಸ್ಸು :

Date of Birth / Age : 03-10-1980



NAME:	MRS. SUNITHA SUBASH
AGE / SEX:	42 YRS/ FEMALE
DATE:	09/03/2024
REFERRED BY:	ARCOFEMI

BILATERAL BREAST SCAN

All four Quadrants of each breast were scanned, followed by evaluation of the subareolar region and axillary tails.

Bilateral breast parenchyma display a uniform echogenicity and echo texture of the fibrofatty and glandular components, which are in normal proportion for this age and parity.

There is no evidence of any mass lesion, cysts or calcification seen in the bilateral breast.

Both Axillary tails are also normal.

No abnormal axillary lymphnodes noted.

Impression:

- No definitive sonological abnormality detected in present scan.
- US BIRADS I (NORMAL).

*To correlate clinically & with other investigations.
Not for medico-legal purpose*



DR. VIGNESH K

CONSULTANT RADIOLOGIST

