

MEDICAL HEALTH CHECK- UP ASSESMENT FORM

NAME : Mr / Mrs Rajalakshmi R.

DATE: 15/11/24

AGE: 40 yrs

SEX: Male / Female
 Female

NMU: NMU000-
5424/001008

DOCTOR'S NAME:
Heetha Paekose

TEMP :	<u>97.1</u> ° f	BP :	<u>128/75</u> mmHg
PULSE :	<u>62</u> b/m	HEIGHT :	<u>157</u> cm
RR :	<u>20</u> b/m	WEIGHT :	<u>52.9</u> kg
SPO2 :	<u>100 %RA</u>	HGT:	-

REMARK:



MEDICOVER HOSPITALS

DEPARTMENT OF OPHTHALMOLOGY

NAVI MUMBAI

DATE: 1st/1/24

PATIENT NAME: Mrs Rajlaxmi R.

AGE / SEX 40/F.

UMR NO: 54241100/008

	RE	LE
VA (DISTANCE)	6/6	6/6
VA (NEAR)	Ng (3)	Ng (3)
COLOUR VISION	Normal	Normal

MRx	O	D	SPHERE	CYLINDER	AXIS	VA	Accom
							+1.00, Nc
			plano	_____	_____	6/6	+1.00, Nc
		S	plano	_____	_____	6/6	+1.00, Nc

HISTORY :

→ No H/O DM or H/W thyroid

→ No H/O Ocular trauma CBA

→ No H/O spectacle use.

OCULAR FINDINGS :

(BE) - Ant seg wnl

(X BE) - Pre-senile Arcus ⊕ ⊕
in (LE)

ADVICE:

Dis (BE) - 0.3

Refresh Tears e/d qid 1777 x 1 month
- Flu c serum lipids.

Mon: Fri 11am to 2pm

AS
CDR. ANUSHREE VANUWALE



15/11/24.



**MEDICOVER
HOSPITALS**

NAVI MUMBAI

Rajalakshmi, R, F, 40yr.

c/o routine check up

O/E - S⁺⁺, Ca⁺⁺

Adm, - Scaling & polishing

Dr. Bineta Singh



**MEDICOVER****HOSPITALS**

NAVI MUMBAI

Name : Mrs. RAJALAKSHMI R
Bill No. : MCB54241103343Age /Sex : 40 Yrs / FEMALE
UMR No. : 542411001008**LABORATORY REPORT : BIOCHEMISTRY**

Parameters	Result	Reference Range	Units
BUN(BLOOD UREA NITROGEN)			
(Bill Date : 15-Nov-2024 09:17 AM Result ID : RMI241111118)			
BUN (Blood Urea Nitrogen.) <i>Calculated</i>	8	7 - 21.0	mg/dL
SERUM URIC ACID			
ill Date : 15-Nov-2024 09:17 AM Result ID : RMI241111122)			
SERUM URIC ACID <i>uricase</i>	4.8	2.4-5.7	mg/dL
LFT(LIVER FUNCTION TEST)			
(Bill Date : 15-Nov-2024 09:17 AM Result ID : RMI241111123)			
TOTAL BILIRUBIN <i>DIAZO</i>	0.7	<1.2	mg/dL
DIRECT BILIRUBIN <i>DIAZO</i>	0.2	<=0.20	mg/dL
INDIRECT BILIRUBIN <i>Calculated</i>	0.5	<=1.0	mg/dL
SGPT (ALT) <i>UV without P5P</i>	19	<=33	U/L
SGOT (AST) <i>UV without P5P</i>	16	<= 32	U/L
ALKALINE PHOSPHATASE (ALP) <i>PNPP, AMP Buffer - IFCC Ref.</i>	64	35 - 105	U/L
TOTAL PROTEINS <i>Biuret method</i>	7.6	6.0 - 8.0 g/dL	g/dL
SERUM ALBUMIN <i>Bromocresol Green (BCG)</i>	4.8	3.5 - 5.2 g/dL	g/dL
GLOBULINS <i>Calculated</i>	2.8	2.5 - 3.5 g/dL	g/dL
A/G RATIO <i>Calculation</i>	1.71	1.2 - 2.5	
GAMMA GLUTAMYL TRANSFERASE(GGT) <i>G-glutamyl-carboxy-γ-nitroanilide-IFCC</i>	18	6-42	U/L



**MEDICOVER****HOSPITALS**

NAVI MUMBAI

Name : Mrs. RAJALAKSHMI R.
Bill No. : MCB54241103343Age /Sex : 40Yrs/M
UMR No. : 542411001008**BUN / CREATININE RATIO**

(Bill Date : 15-Nov-2024 09:17 AM Result ID : RMI241111124)

BUN / CREATININE RATIO 9.1 * 10-20
*CALCULATED***SERUM CREATININE**

(Bill Date : 15-Nov-2024 09:17 AM Result ID : RMI241111125)

CREATININE 0.88 0.6 - 1.2 mg/dL
*Jaffe***LIPID PROFILE**

(Bill Date : 15-Nov-2024 09:17 AM Result ID : RMI241111126)

TOTAL CHOLESTEROL 284 * mg/dL
Enzymatic colorimetric
Desirable : < 200 mg/dL
Borderline High : 200 - 239 mg/dL
High risk : > 240 mg/dLHDL CHOLESTEROL 39 mg/dL
Homogeneous enzymatic colorimetric
Low : < 40 mg/dL
High : > 60 mg/dLLDL CHOLESTEROL 205 * mg/dL
Direct-Enzymatic colorimetric
Very High : - > 190 mg/dL
Optimal : - < 100 mg/dL
Near Optimal : 100 - 129 mg/dL
High : 160 - 189 mg/dL
Borderline High: 130-159 mg/dlVLDL 37 * mg/dL
Calculation
2 - 30 mg/dLSERUM TRYGLYCERIDES 185 * mg/dL
Enzymatic colorimetric
< 150 mg/dL
Borderline High : 150 - 199 mg/dL
High : 200 - 499 mg/dLCHO/HDL RATIO 7.28 *
Calculation
Normal : - < 3.5
High Risk : - > 5.0

LDL/HDL RATIO 5.26

HBA1C (GLYCOSYLATED HAEMOGLOBIN)

(Bill Date : 15-Nov-2024 09:17 AM Result ID : RMI241111127)

HBA1C 5.8 *
HPLC
" Normal : < 5.7%
Pre diabetic : 5.7 % - 6.5 %
Diabetic : > 6.5 %



MEDICOVER

HOSPITALS

NAVI MUMBAI

Name : Mrs. RAJALAKSHMI R.
Bill No. : MCB54241103343

Age /Sex : 40Y / FEMALE
UMR No. : 542411001008

T3,T4 AND TSH

(Bill Date : 15-Nov-2024 09:17 AM Result ID : RMI241111128)

T3 ECLIA	107.0	70 - 204	ng/dL
T4 ECLIA	7.24	5.1 - 14.1	ug/dL
TSH(THYROID STIMULATING HORMONE) ECLM	2.19	0.270 - 4.20	uIU/mL

FBS (FASTING BLOOD GLUCOSE WITH URINE GLUCOSE)

(Bill Date : 15-Nov-2024 09:17 AM Result ID : RMI241111129)

FASTING BLOOD GLUCOSE Hexokinase	91	Normal Range : 70 - 99 Impaired Glucose tolerance : 100 -125 Diabetes Mellitus : >=126	mg/dL
-------------------------------------	----	--	-------

FASTING URINE GLUCOSE NIL

PLBS (POST LUNCH BLOOD SUGAR WITH URINE SUGAR)

(Bill Date : 15-Nov-2024 09:17 AM Result ID : RMI241111304)

PLBS (POST LUNCH BLOOD GLUCOSE)	134		
URINE SUGAR	NIL		


DR. MEHROTRA VISHAL
MD Pathology





MEDICOVER

HOSPITALS

NAVI MUMBAI

Name : Mrs. RAJALAKSHMI R
Bill No. : MCB54241103343

Age / Sex : 40 Yrs / Female
UMR No. : 542411001006

LABORATORY REPORT : BLOOD BANK

Parameters	Result	Reference Range	Units
------------	--------	-----------------	-------

BLOOD GROUPING AND RH

(Bill Date : 15-Nov-2024 09:17 AM Result ID : RMI241111130)

BLOOD GROUP <i>Automated microcolumn gel method</i>	A		
--	---	--	--

RH TYPE	POSITIVE		
---------	----------	--	--

INTERPRETATION

1. If Rh is Du positive it is best considered as Rh negative as recipient and Rh positive as donor. Proper Cross matching is recommended before transfusion.
2. In case of forward and reverse grouping discrepancy, clinical correlation and repeat sample analysis is recommended.
3. For Infants below 6 months only forward grouping is performed.
4. A sub-grouping is recommended after the age of 6 months.


DR. MEHROTRA VISHAL
MD PATHOLOGY



**MEDICOVER****HOSPITALS**

NAVI MUMBAI

Name : Mrs. RAJALAKSHMI R.
Bill No. : MCB54241103343Age /Sex : 40 Yrs) FEMALE
UMR No. : 542411001008**LABORATORY REPORT : CLINICAL PATHOLOGY**

Parameters Result Reference Range Units

CUE(COMPLETE URINE EXAMINATION)

(Bill Date : 15-Nov-2024 09:17 AM Result ID : RMI241111121)

PHYSICAL EXAMINATION

VOLUME	20 ML		ml
COLOUR	PALE YELLOW	PALE YELLOW	
APPEARANCE	CLEAR	CLEAR	

CHEMICAL EXAMINATION

DEPOSIT	ABSENT	ANSENT	
SPECIFIC GRAVITY <i>Bromthymol blue</i>	1.020	1.000 - 1.030	
PH <i>Bromthymol blue</i>	6.5	5.0 - 8.0	
PROTEIN <i>Tetra-cromophenol blue/Leifson's test</i>	NIL	NIL (<15 mg/dL)	
GLUCOSE <i>Glucose oxidase Peroxidase/Benedict's test</i>	NIL	NIL (<25 mg/dL)	
UROBILINOGEN <i>Diazonium salt</i>	NIL	NIL	
KETONE <i>Sodium nitroprusside/Rothera's test.</i>	NIL	NIL (<5 mg/dL)	
BILIRUBIN <i>Dipstick/Fouchet's test</i>	NEGATIVE	NEGATIVE	
BILE SALT <i>Heys sulphur powder</i>	NEGATIVE	NEGATIVE	
BILE PIGMENT <i>Fouchet test</i>	NEGATIVE	NEGATIVE	
NITRITE <i>Sulfanilic acid</i>	NEGATIVE	NEGATIVE	



**MEDICOVER****HOSPITALS**

NAVI MUMBAI

Name : Mrs. RAJALAKSHMI R
Bill No. : MCB54241103343Age / Sex : 40Y (s) FEMALE
UMR No. : 542411001008**LABORATORY REPORT : HAEMATOLOGY**

Parameters	Result	Reference Range	Units
CBP(COMPLETE BLOOD PICTURE)			
(Bill Date : 15-Nov-2024 09:17 AM Result ID : RMI241111119)			
R B C COUNT <i>Electrical Impedance</i>	4.36	3.8-4.8	10 ¹² /L
HEMOGLOBIN <i>Photometric</i>	12.7	12.0 - 15.0	gms/dL
PCV/HCT <i>Calculated</i>	40.0	36 - 46	%
MCV <i>Calculated</i>	91.8	83 - 101	fl
MCH <i>Calculated</i>	29.1	27 - 32	pg
MCHC <i>Calculated</i>	31.7	31.5 - 34.5	g/dL
RDW(cv)	14.4 *	11.6 - 14.0 %	%
TLC (TOTAL LEUCOCYTE COUNT) <i>Impedance</i>	5.82	4.0 - 10.0	10 ³ /μl
<u>DIFFERENTIAL COUNT</u>			
NEUTROPHILS <i>DHSS/Microscopy</i>	56	40 - 80 %	
LYMPHOCYTES <i>DHSS/Microscopy</i>	38	20 - 40 %	
MONOCYTES <i>DHSS/Microscopy</i>	04	02 - 10 %	
EOSINOPHILS <i>DHSS/Microscopy</i>	02	00 - 06 %	
BASOPHILS <i>DHSS/Microscopy</i>	00	00 - 01 %	
PLATELET COUNT <i>Electrical Impedance</i>	263	150 - 400	10 ³ /μL





MEDICOVER

HOSPITALS

NAVI MUMBAI

Name : Mrs. RAJALAKSHMI R
Bill No. : MCB54241103343

Age / Sex : 40 Yrs FEMALE
UMR No. : 542411001008

ESR

(Bill Date : 15-Nov-2024 09:17 AM Result ID : RMI241111120)

ESR
MODIFIED WESTERNGREN'S METHOD

40 *

0 - 20

mm/1st hour


DR. MEHROTRA VISHAL
MD Pathology



Patient ID:	2411001008	Patient Name:	RAJALAKSHMI R 40YRS/F
Age:		Sex:	F
Accession Number:		Modality:	CR
Referring Physician:		Study:	BREAST
Study Date:	15-Nov-2024		

X-RAY MAMMOGRAPHY

INDICATION: Routine screening.

MAMMOGRAPHY

Bilateral mammograms were obtained in the oblique mediolateral and craniocaudal projections.

The film markers are placed on the axillary / lateral part of the breast.

Both breasts display scattered areas of fibroglandular density. (ACR category b).

There is no focal spiculated mass lesion seen.

There are no clusters of microcalcification, distortion of the lobular architecture or nipple retraction.

Skin and subcutaneous tissues are normal.

IMPRESSION :-

No significant abnormality is seen.

BIRADS Category I (Negative)

Suggest a routine screening mammography after one year.

(BIRADS CATEGORY : BIRADS 0 - Requires additional evaluation, I - Negative, II - Benign findings, III - Probably benign findings, IV - Suspicious abnormality, V - Highly suggestive of malignancy, VI - Known biopsy proven malignancy.)



Dr. Yogini Hetal Shah

MBBS, DNB, DMRD

Date: 15-Nov-2024 16:09:45

Patient ID:	542411001008	Patient Name:	RAJALAKSHMI R
Age:	40YRS	Sex:	F
Accession Number:		Modality:	US
Referring Physician:	DR.DMO	Study:	USG ABDOMEN PELVIS
Study Date:	15-Nov-2024		

ULTRASOUND EXAMINATION OF ABDOMEN & PELVIS

The Liver is normal in size (14 cm) and shows mild increase in parenchymal reflectivity. No focal lesion is seen. The Hepatic veins appear normal. There is no evidence of any dilated IHBR. The portal vein appears normal.

The gall bladder is partially distended. C.B.D. is of normal caliber.

The Pancreas is normal in size and shows homogeneous reflectivity. There is no evidence of any calcification or ductal dilatation.

The spleen is normal in size and shows a homogeneous echotexture. It measures 9 cm in long axis. There is no evidence of any focal lesion.

Both kidneys are normal in position and size. They show normal cortical reflectivity and cortico-medullary distinction.

The Right Kidney measures 10.4 x 3.8 cm.

The Left Kidney measures 9.1 x 3.8 cm.

There is no obvious evidence of renal calculi, hydronephrosis, or mass noted.

There is no evidence of ascites.

The Urinary bladder is distended and shows normal wall thickness. No evidence of any intraluminal mass or calculi.

The uterus is anteverted. It measures 8.4 x 4.6 x 4.0 cm.

The uterine myometrial echotexture is homogeneous. No focal lesion is seen.

The Endometrial thickness is 5.8 mm.

Both ovaries are visualized and appear normal in size and reflectivity.

The Right ovary measures 2.4 x 1.6 cm.

The Left ovary measures 2.5 x 1.4 cm.

No evidence of any fluid collection in the pelvis.

Patient ID:	542411001008	Patient Name:	RAJALAKSHMI
Age:	40YRS	Sex:	F
Accession Number:		Modality:	US
Referring Physician:	DR.DMO	Study:	USG ABDOMEN PELVIS
Study Date:	15-Nov-2024		

IMPRESSION:

- **Grade I fatty liver.**



DR. SUYOG SANGALE
MBBS DMRE
CONSULTANT RADIOLOGIST

Date: 15-Nov-2024 15:17:24

Rate 78 . Sinus rhythm.....normal P axis, V-rate 50- 99
 PR 200 . Borderline low voltage, extremity leads.....all extremity leads <0.6mV
 QRS 105 . Nonspecific T abnormalities, anterior leads.....T <-0.10mV, V2-V4
 QT 436 . Borderline prolonged QT interval.....QTc >485ms
 QTc 497 . Baseline wander in lead(s) V3

Handwritten initials/signature

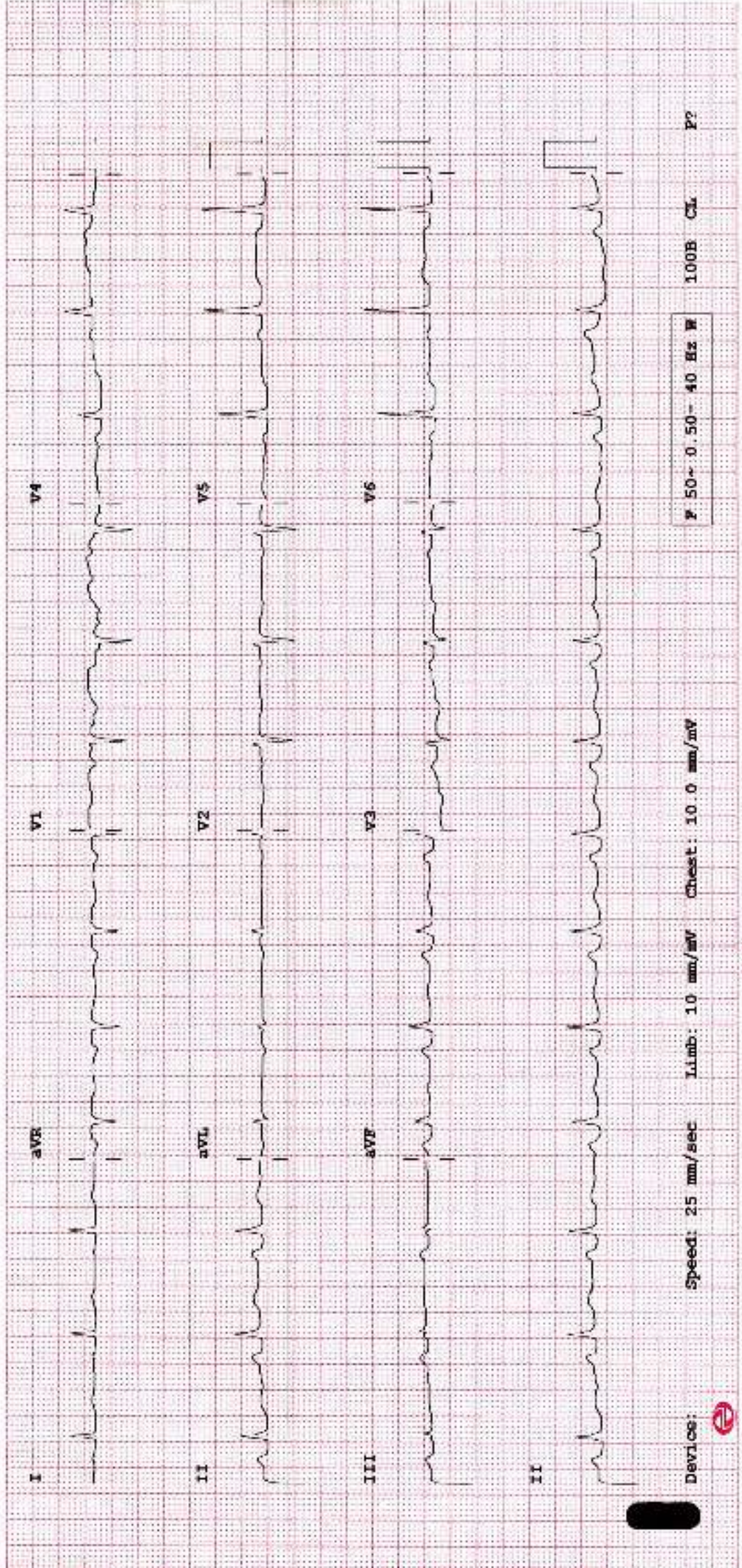
--AXIS--

P 75
 QRS 49
 T 30

12 Lead; Standard Placement

- ABNORMAL ECG -

Unconfirmed Diagnosis



Device: Speed: 25 mm/sec Limb: 10 mm/mV Chest: 10.0 mm/mV

P 50~ 0.50~ 40 Hz W

100B CL P2

2D ECHO CARDIOGRAPHY WITH COLOR DOPPLER

<i>Name</i> : Mrs. Rakshi Issai	Date:- 15/11/2024
<i>Age / Sex</i> : 28 Yrs / Female	UMR No. 542411000999
<i>Referred By</i> : Health checkup	

FINDINGS:

- No left ventricle regional wall motion abnormality.
- Normal left ventricle systolic function. LVEF = 60%.
- No left ventricle diastolic dysfunction.
- Trivial mitral regurgitation.
- No aortic regurgitation. No aortic stenosis.
- Trivial tricuspid regurgitation. No pulmonary hypertension. PASP = 20 mm Hg.
- No left ventricle clot / vegetation / pericardial effusion.
- Intact IAS and IVS.
- Normal left atrium and left ventricle dimensions.
- Normal right atrium and right ventricle dimensions.
- Normal right ventricle systolic function. No hepatic congestion.

IMP:

- No RWMA.
- Trivial MR and TR. No PH.
- Normal LV and RV systolic function.



DR. KESHAV KALE
DNB (Cardiology), MD (Medicine), MBBS
PhD (Cardiology), MNAMS, LL.B (Law)
FSCAI (USA), AFACC (USA), FESC (EU)
Consultant & Interventional Cardiologist



MEDICOVER
HOSPITALS

NAVI MUMBAI

M-MODE MEASUREMENTS:

LA	34	mm
AO root	29	mm
AO CUSP SEP	18	mm
LVID(s)	32	mm
LVID(d)	41	mm
IVS(d)	10	mm
LVPW(d)	10	mm
RVID(d)	28	mm
RA	30	mm
LVEF	60	%

	PEAK	MEAN	Vmax	Gradient of Regurgitation
MITRAL	N			Trivial
AORTIC	5			Nil
TRICUSPID	25			Trivial
PULMONERY	4			Nil

