

Patient Name : Mr. M Kodanda Rama

Age/Gender : 56 Y/M

UHID/MR No. : CINR.0000161929

OP Visit No : CINROPV217214

Sample Collected on :

Reported on : 27-01-2024 16:13

LRN# : RAD2218173

Specimen :

Ref Doctor : SELF

Emp/Auth/TPA ID : 9880093929

DEPARTMENT OF RADIOLOGY

X-RAY CHEST PA

Both lung fields and hila are normal .

No obvious active pleuro-parenchymal lesion seen .

Both costophrenic and cardiophrenic angles are clear .

Both diaphragms are normal in position and contour .


Thoracic wall and soft tissues appear normal.

CONCLUSION :

No obvious abnormality seen



Dr. DHANALAKSHMI B
MBBS, DMRD
Radiology

Name : Mr. M Kodanda Rama Address : bangalore Plan : ARCOFEMI MEDIWHEEL MALE AHC CREDIT PAN INDIA OP AGREEMENT	Age : 56 Y Sex : M	UHID :CINR.0000161929  <small>* CINR . 0000161929 *</small> OP Number :CINROPV217214 Bill No :CINR-OCR-93265 Date : 27.01.2024 09:33
---	---	---

Sno	Service Type/ServiceName	Department
1	ARCOFEMI - MEDIWHEEL - FULL BODY ANNUAL PLUS ABOVE 50Y MALE - 2D ECHO - PAN INDIA - FY2324	
	1 URINE GLUCOSE(FASTING)	
	2 GAMMA GLUTAMYL TRANSFERASE (GGT)	
	3 PROSTATIC SPECIFIC ANTIGEN (PSA TOTAL)	
	4 HbA1c, GLYCATED HEMOGLOBIN	
	5 2D ECHO	
	6 LIVER FUNCTION TEST (LFT)	
	7 X-RAY CHEST PA	
	8 GLUCOSE, FASTING	
	9 HEMOGRAM + PERIPHERAL SMEAR	
	10 ENT CONSULTATION	
	11 FITNESS BY GENERAL PHYSICIAN	
	12 DIET CONSULTATION	
	13 COMPLETE URINE EXAMINATION	
	14 URINE GLUCOSE(POST PRANDIAL)	
	15 PERIPHERAL SMEAR	
	16 ECG	
	17 BLOOD GROUP ABO AND RH FACTOR	
	18 LIPID PROFILE	
	19 BODY MASS INDEX (BMI)	
	20 OPHTHAL BY GENERAL PHYSICIAN	
	21 RENAL PROFILE/RENAL FUNCTION TEST (RFT/KFT)	
	22 ULTRASOUND - WHOLE ABDOMEN . 9	
	23 THYROID PROFILE (TOTAL T3, TOTAL T4, TSH)	
	24 DENTAL CONSULTATION ~ 1	
	25 GLUCOSE, POST PRANDIAL (PP), 2 HOURS (POST MEAL)	

OPHTHAL PRESCRIPTION

PATIENT NAME: *m. Kodanata Rama* DATE: *27/1/24*

UHID NO: *161924*

AGE: *36*

OPTOMETRIST NAME: Ms. Swathi

GENDER: *m*

This is to certify that I have examined
years and findings of his/her eye examination are as follows,

	RIGHT EYE				LEFT EYE			
	SPH	CYL	AXIS	BCVA	SPH	CYL	AXIS	BCVA
Distance	<i>0.25</i>	<i>-</i>			<i>0.25</i>	<i>-</i>		
Add	<i>2.75</i>				<i>2.75</i>	<i>-</i>		

PD - RE: *31* - LE: *31* -

Colour Vision: *normal (BG)*

Remarks:

Apollo clinic Indiranagar

Date : 27-01-2024

Department : GENERAL

MR NO : CINR.0000161929

Doctor :

Name : Mr. M Kodanda Rama

Registration No :

Age/ Gender : 56 Y / Male

Qualification :

Consultation Timing: 09:32

Height : 171 cm	Weight : 70.8 kg	BMI : 24.21 kg/m ²	Waist Circum : 94 cm
Temp : 98.6 °F	Pulse : 100 bpm	Resp : 18 bpm	B.P : 140/90 mmHg

General Examination / Allergies
History

Clinical Diagnosis & Management Plan

Follow up date:

Doctor Signature

11.03.1967
56 Years

Male

27.01.2024 13:11:58
APOLLO CLINIC
INDIRANAGAR
BANGALORE

QRS: 64 ms
QT/QTcBaz: 334 / 426 ms
PR: 158 ms
P: 98 ms
RR/PP: 610 / 612 ms
P/QRS/T: 73 / -51 / 53 degrees

Location:
Room:
Order Number:
Indication:
Medication 1:
Medication 2:
Medication 3:

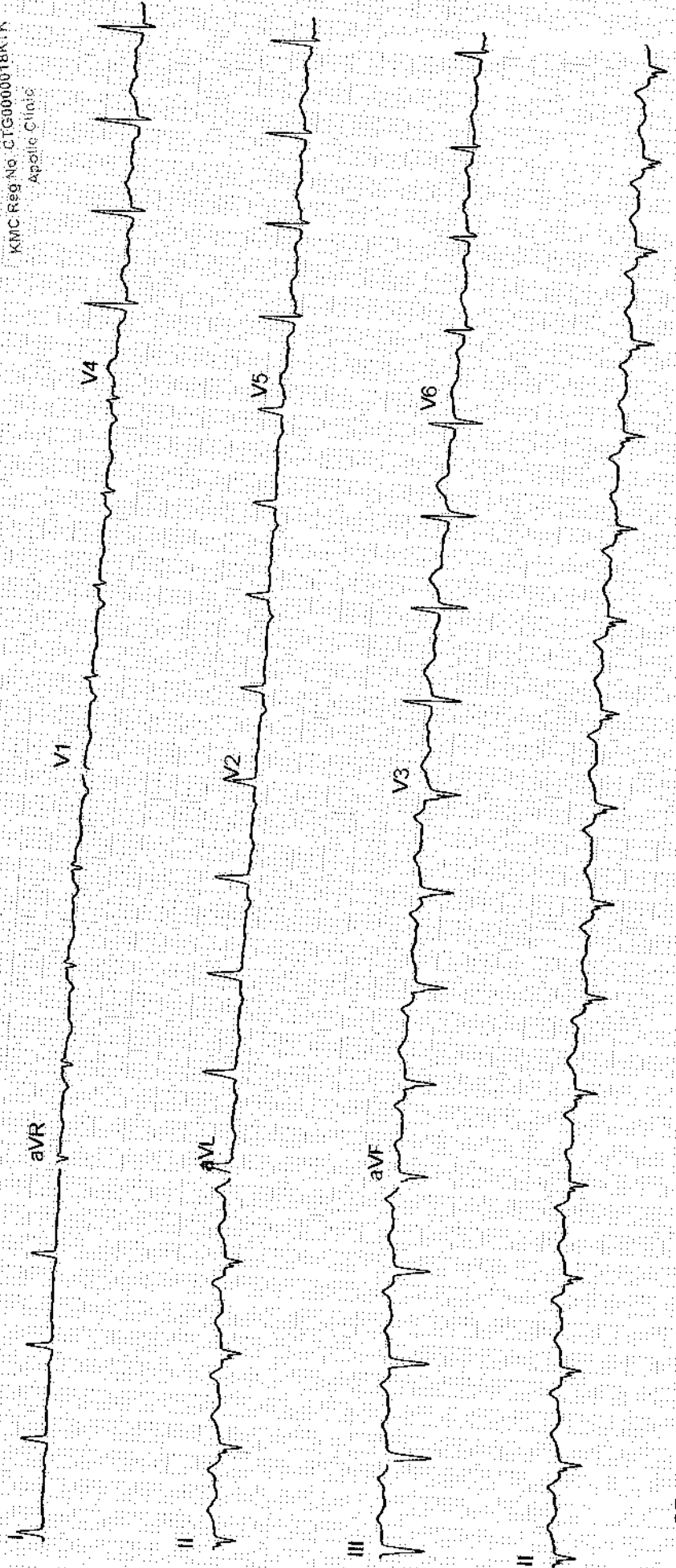
98 bpm
- / - mmHg

Technician:
Ordering Ph:
Referring Ph:
Attending Ph:

Left Axis Deviation
Normal



~~Dr. M. SUDHAKAR RAO~~
MBBS, MD, DM (Cardiology), FACC, FESC, FSCAI
Consultant Cardiologist
KMC Reg No: CTG0000018KTK
Apollo Clinic



GE MAC2000 1.1 12SL™ V241

25 mm/s 10 mm/mV

ADS 0.56-20 Hz 50 Hz
Unconfirmed
4x2.5x3_25_R1

NAME: MR KODANDA RAMA	AGE/SEX: 56Y/M	OP NUMBER: 161929
Ref By : SLEF	DATE: 27-01-2024	

M mode and doppler measurements:

CM	CM	M/sec	
AO: 2.5	IVS(D): 1.0	MV: E Vel: 0.6	A Vel : 0.8
LA: 2.5	LVIDD(D): 3.5	AV Peak: 0.8	
	LVPW(D):1.3	PV peak:0.5	
	IVS(S): 1.3		
	LVID(S):2.3		
	LVPW(S):1.4		
	LVEF: 60%		
	TAPSE:2.4		

Descriptive findings:

Left Ventricle	Normal
Right Ventricle:	Normal
Left Atrium:	Normal
Right Atrium:	Normal
Mitral Valve:	Normal
Aortic Valve:	Normal
Tricuspid Valve:	Normal
IAS:	Normal
IVS:	Normal

IVC:

Normal

Others

Normal

IMPRESSION :

Normal cardiac chamber and valves

No Regional wall motion abnormality

No MR/AR/TR


No clot/vegetation/pericardial effusion

Grade I LV diastolic dysfunction

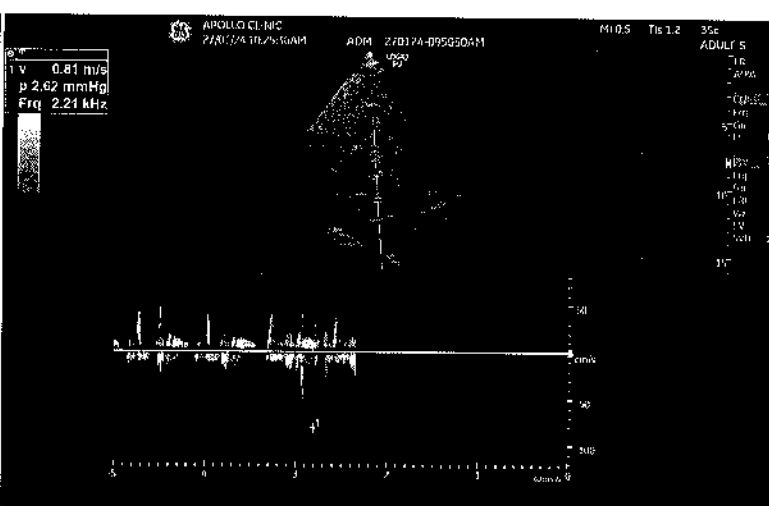
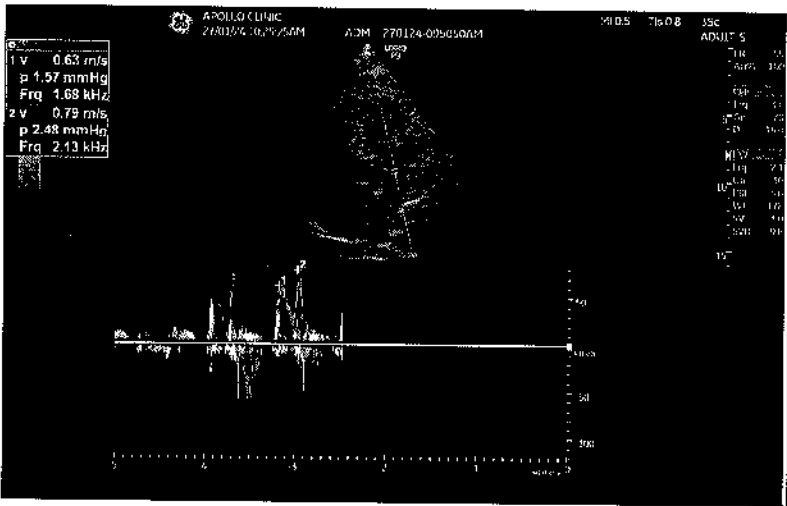
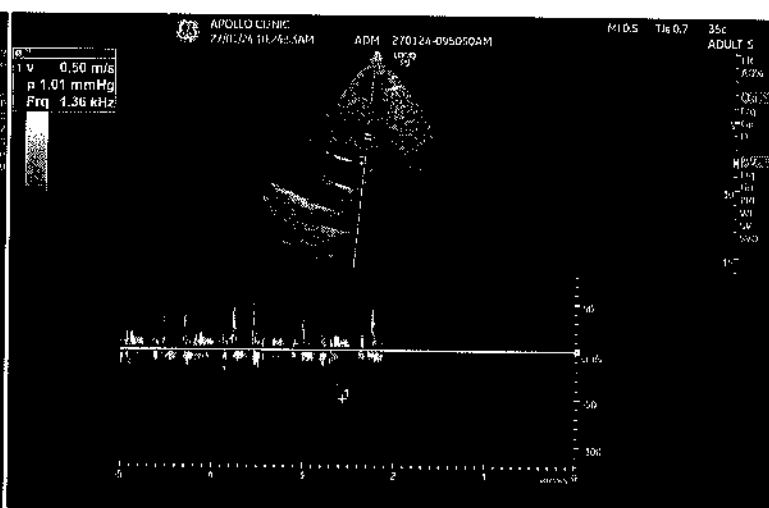
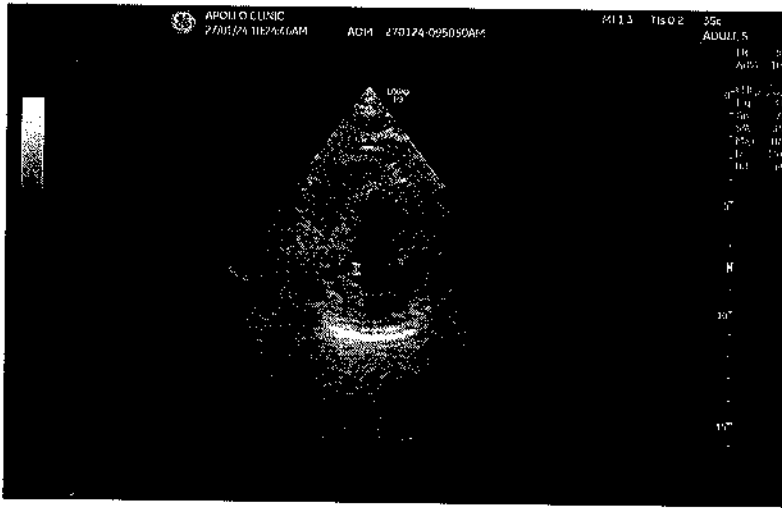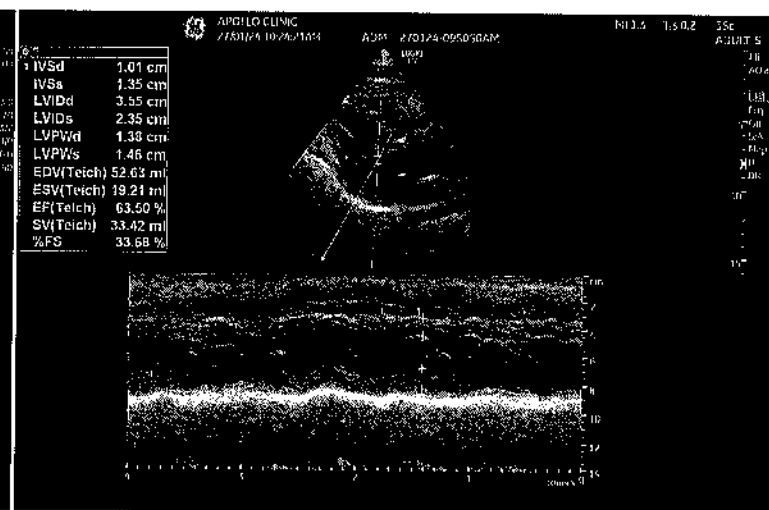
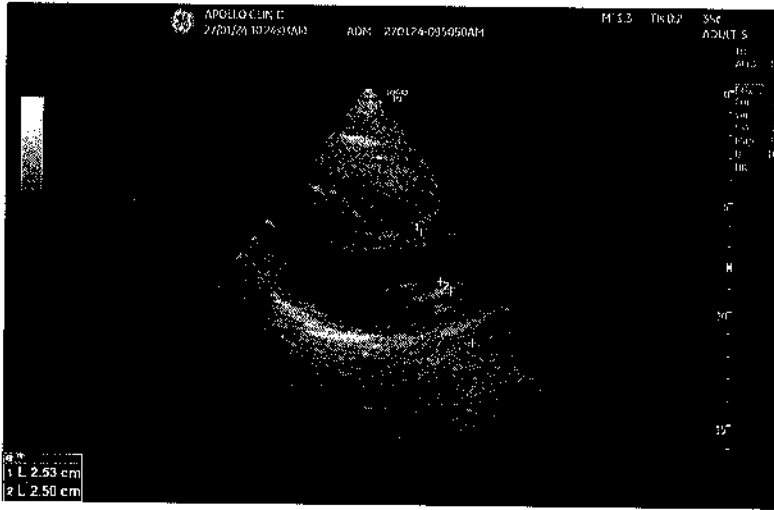
Normal LV systolic function - LVEF= 60%

DR JAGADEESH H V MD,DM

CONSULTANT CARDIOLOGIST



Dr. JAGADEESH H V
MBBS,MD, DM (Cardiol)
Consultant Cardiologist
KMC Ramoji Film City
Apollo Clinic



SUGGESTIVE LIST OF MEDICAL TESTS

FOR MALE	FOR FEMALE
CBC	CBC
ESR	ESR
Blood Group & RH Factor	Blood Group & RH Factor
Blood and Urine Sugar Fasting	Blood and Urine Sugar Fasting
Blood and Urine Sugar PP	Blood and Urine Sugar PP
Stool Routine	Stool Routine
Lipid Profile	Lipid Profile
Total Cholesterol	Total Cholesterol
HDL	HDL
LDL	LDL
VLDL	VLDL
Triglycerides	Triglycerides
HDL / LDL ratio	HDL / LDL ratio
Liver Profile	Liver Profile
AST	AST
ALT	ALT
GGT	GGT
Bilirubin (total, direct, indirect)	Bilirubin (total, direct, indirect)
ALP	ALP
Proteins (T, Albumin, Globulin)	Proteins (T, Albumin, Globulin)
Kidney Profile	Kidney Profile
Serum creatinine	Serum creatinine
Blood Urea Nitrogen	Blood Urea Nitrogen
Uric Acid	Uric Acid
HBA1C	HBA1C
Routine urine analysis	Routine urine analysis
USG Whole Abdomen	USG Whole Abdomen
General Tests	General Tests
X Ray Chest	X Ray Chest
ECG	ECG
2D/3D ECHO / TMT	2D/3D ECHO / TMT
Stress Test	Thyroid Profile (T3, T4, TSH)
PSA Male (above 40 years)	Mammography (above 40 years) and Pap Smear (above 30 years).
Thyroid Profile (T3, T4, TSH)	Dental Check-up consultation
Dental Check-up consultation	Physician Consultation
Physician Consultation	Eye Check-up consultation
Eye Check-up consultation	Skin/ENT consultation
Skin/ENT consultation	Gynaec Consultation

Health Check Code : PKG10000367

Name of Diagnostic/Hospital : Apollo Clinic - Indiranagar

Address of Diagnostic/Hospital- : 2012,1st floor, Above vision express, Next to Starbucks, 100 feet road, HAL 2nd stage, Indiranagar - 560038

Appointment Date : 27-01-2024

Preferred Time : 9:00am-9:30am

Member Information		
Booked Member Name	Age	Gender
M Kodanandaram	56 year	Male

We will get back to you with confirmation update shortly. Please find the package details as attached for your reference.

Tests included in this Package

- Bmi Check
- Ent Consultation
- Dietician Consultation
- Thyroid Profile
- ESR
- Blood Glucose (Fasting)
- General Physician Consultation
- TMT OR 2D ECHO
- Blood Group
- Blood Glucose (Post Prandial)
- Chest X-ray
- ECG
- USG Whole Abdomen
- Eye Check-up consultation
- Urine Sugar Fasting
- Urine Sugar PP
- Dental Consultation
- Urine analysis
- CBC
- HbA1c
- Lipid Profile
- Kidney Profile
- Liver profile
- Prostate Specific Antigen (PSA Male)

Thanks,
Mediwheel Team

You have received this mail because your e-mail ID is registered with This is a system-generated e-mail **Arcofemi Healthcare Limited**, please don't reply to this message.

Please visit to our **Terms & Conditions** for more informaion. This email is recieved because you are register with us [Click here](#) to unsubscribe.



ಭಾರತ ಸರ್ಕಾರ

Government of India



ಕೊಂಡರಾಮ ಮನ್
Kodandarama M
ಜನ್ಮ ದಿನಾಂಕ/ DOB: 11/03/1967
ವೈರಾಜ / MALE



4839 6129 8678

ನನ್ನ ಅಧಾರ್, ನನ್ನ ಗುರುತು

Patient Name : Mr. M Kodanda Rama

Age/Gender : 56 Y/M

UHID/MR No. : CINR.0000161929

OP Visit No : CINROPV217214

Sample Collected on :

Reported on : 27-01-2024 14:02

LRN# : RAD2218173

Specimen :

Ref Doctor : SELF

Emp/Auth/TPA ID : 9880093929

DEPARTMENT OF RADIOLOGY

ULTRASOUND - WHOLE ABDOMEN

LIVER: Appears normal in size, **shape and show mild diffusely increased echogenicity.** No focal parenchymal lesions identified. No evidence of intra/extrahepatic biliary tree dilatation noted. Portal vein appears to be of normal size.

GALLBLADDER: Moderately distended. No definite calculi identified. No evidence of abnormal wall thickening noted.

SPLEEN: Appears normal in size, shape and echopattern. No focal parenchymal lesions identified.

PANCREAS: Obscured by bowel gas. However, the visualized portion appear normal.

KIDNEYS: Both kidneys appear normal in size, shape and echopattern. Corticomedullary differentiation appears maintained. No evidence of calculi or hydronephrosis on either side.

URINARY BLADDER: Distended and appears normal. No evidence of abnormal wall thickening noted.

PROSTATE: Prostate is normal in size and echo-pattern.

No free fluid or lymphadenopathy is seen.

IMPRESSION:

GRADE I FATTY LIVER.



Dr. DHANALAKSHMI B
MBBS, DMRD
Radiology