

Patient Name : Mrs.SWATI S	Collected : 09/Nov/2024 10:34AM
Age/Gender : 34 Y 11 M 15 D/F	Received : 09/Nov/2024 01:30PM
UHID/MR No : CVIM.0000228350	Reported : 09/Nov/2024 02:17PM
Visit ID : CVIMOPV638859	Status : Final Report
Ref Doctor : Self	Sponsor Name : ARCOFEMI HEALTHCARE LIMITED
Emp/Auth/TPA ID : 22E37133	

DEPARTMENT OF HAEMATOLOGY

ARCOFEMI - MEDIWHEEL - FULL BODY HEALTH ANNUAL PLUS CHECK - FEMALE - 2D ECHO - PAN INDIA - FY2324

PERIPHERAL SMEAR , WHOLE BLOOD EDTA

**RBC's are Normocytic Normochromic,
WBC's are normal in number and morphology
Platelets are Adequate
No Abnormal cells seen.**



DR.Sanjay Ingle
M.B.B.S,M.D(Pathology)
Consultant Pathologist

SIN No:VIR241100726

This test has been performed at Apollo Health and Lifestyle Ltd- Sadashiv Peth Pune, Diagnostics Lab



Patient Name : Mrs.SWATI S	Collected : 09/Nov/2024 10:34AM
Age/Gender : 34 Y 11 M 15 D/F	Received : 09/Nov/2024 01:39PM
UHID/MR No : CVIM.0000228350	Reported : 09/Nov/2024 02:29PM
Visit ID : CVIMOPV638859	Status : Final Report
Ref Doctor : Self	Sponsor Name : ARCOFEMI HEALTHCARE LIMITED
Emp/Auth/TPA ID : 22E37133	

DEPARTMENT OF CLINICAL PATHOLOGY

ARCOFEMI - MEDIWHEEL - FULL BODY HEALTH ANNUAL PLUS CHECK - FEMALE - 2D ECHO - PAN INDIA - FY2324

Sneha Shah
Dr Sneha Shah
 MBBS, MD (Pathology)
 Consultant Pathologist

SIN No:VIR241100729

This test has been performed at Apollo Health and Lifestyle Ltd- Sadashiv Peth Pune, Diagnostics Lab



Patient Name : Mrs.SWATI S	Collected : 09/Nov/2024 10:34AM
Age/Gender : 34 Y 11 M 15 D/F	Received : 09/Nov/2024 01:38PM
UHID/MR No : CVIM.0000228350	Reported : 09/Nov/2024 02:22PM
Visit ID : CVIMOPV638859	Status : Final Report
Ref Doctor : Self	Sponsor Name : ARCOFEMI HEALTHCARE LIMITED
Emp/Auth/TPA ID : 22E37133	

DEPARTMENT OF CLINICAL PATHOLOGY

ARCOFEMI - MEDIWHEEL - FULL BODY HEALTH ANNUAL PLUS CHECK - FEMALE - 2D ECHO - PAN INDIA - FY2324

Test Name	Result	Unit	Bio. Ref. Interval	Method
URINE GLUCOSE(POST PRANDIAL)	NEGATIVE		NEGATIVE	GOD-POD

Test Name	Result	Unit	Bio. Ref. Interval	Method
URINE GLUCOSE(FASTING)	NEGATIVE		NEGATIVE	GOD-POD

*** End Of Report ***

Sneha Shah

Dr Sneha Shah
 MBBS, MD (Pathology)
 Consultant Pathologist

SIN No:VIR241100731

This test has been performed at Apollo Health and Lifestyle Ltd- Sadashiv Peth Pune, Diagnostics Lab



Patient Name	: Mrs. Swati S	Age	: 34Yrs 11Mths 16Days
UHID	: CVIM.0000228350	OP Visit No.	: CVIMOPV638859
Printed On	: 09-11-2024 07:46 AM	Advised/Pres Doctor	: --
Department	: Radiology	Qualification	: --
Referred By	: Self	Registration No.	: --
Employer Id	: 22E37133		

DEPARTMENT OF RADIOLOGY

ULTRASOUND ABDOMEN AND PELVIS

Liver appears normal in size and echotexture. No focal lesion is seen.
PV and CBD normal. No dilatation of the intrahepatic biliary radicals.

Gall bladder is well distended. No evidence of calculus. Wall thickness appears normal. No evidence of periGB collection. Tiny polyp measuring 3.5 mm seen on anterior wall.

Spleen appears normal. No focal lesion seen. Splenic vein appears normal.

Pancreas appears normal in echopattern. No focal/mass lesion/calcification. No evidence of peripancreatic free fluid or collection. Pancreatic duct appears normal.

Both the kidneys appear normal in size, shape and echopattern. Cortical thickness and CM differentiation are maintained. No calculus / hydronephrosis seen on either side.

Urinary Bladder is well distended and appears normal. No evidence of any wall thickening or abnormality. No evidence of any intrinsic or extrinsic bladder mass detected.

Uterus appears normal in size. It shows normal shape & echo pattern.
Endometrial echo-complex appears normal and measures 8.6 mm.

Both ovaries appear normal in size, shape and echotexture. Right vary shows a 24 mm follicle and left ovary shows a 14 mm follicle.
No evidence of any adnexal pathology noted.

Bowel loops and Retroperitoneum appear normal. Aorta and IVC appear normal.
No abnormal lymphadenopathy noted.

IMPRESSION:-

Tiny gall bladder polyp seen.

(The sonography findings should always be considered in correlation with the clinical and other investigation finding where applicable.)

---End Of The Report---



Dr. PREETI P KATHE
DMRE, MD, DNB
2003/04/1886
Radiology

Patient Name	: Mrs. Swati S	Age	: 34Yrs 11Mths 16Days
UHID	: CVIM.0000228350	OP Visit No.	: CVIMOPV638859
Printed On	: 09-11-2024 08:05 AM	Advised/Pres Doctor	: --
Department	: Radiology	Qualification	: --
Referred By	: Self	Registration No.	: --
Employer Id	: 22E37133		

DEPARTMENT OF RADIOLOGY

X-RAY CHEST PA

Trachea appears normal.

Both the lung fields are clear.

Cardiac shadows appear apparently normal.

Both domes of diaphragm appear normal.


Both costophrenic angles are clear.

Bony thoracic cage shows no deformity. Visualised bones appear normal.

Soft tissues appear normal.

Impression: Essentially Normal Study.

---End Of The Report---



Dr. PREETI P KATHE
DMRE, MD, DNB
2003/04/1886
Radiology



सत्यमेव जयते

भारत सरकार

GOVERNMENT OF INDIA



स्वाति शर्मा

Swati Sharma

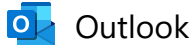
जन्म तिथि/DOB: 26/06/1994

महिला/ FEMALE



3251 1874 6976

मेरा आधार, मेरी पहचान



Your appointment is confirmed

From noreply@apolloclinics.info <noreply@apolloclinics.info>

Date Thu 2024-11-07 18:24

To pummy.25nov@gmail.com <pummy.25nov@gmail.com>

Cc Vimannagar Apolloclinic <vimannagar@apolloclinic.com>; Syamsunder M <syamsunder.m@apollohl.com>; Dr. Neha Gupta <neha.gupta@apolloclinic.com>



Dear MS. SWATI,

Greetings from Apollo Clinics,

Your corporate health check appointment is confirmed at **VIMAN NAGAR clinic** on **2024-11-09** at **08:00-08:15**.

Payment Mode	
Corporate Name	ARCOFEMI HEALTHCARE LIMITED
Agreement Name	[ARCOFEMI MEDIWHEEL FEMALE AHC CREDIT PAN INDIA OP AGREEMENT]
Package Name	[ARCOFEMI - MEDIWHEEL - FULL BODY HEALTH ANNUAL PLUS CHECK - FEMALE - 2D ECHO - PAN INDIA - FY2324]

"Kindly carry with you relevant documents such as HR issued authorization letter and or appointment confirmation mail and or valid government ID proof and or company ID card and or voucher as per our agreement with your company or sponsor."

Note: Video recording or taking photos inside the clinic premises or during camps is not allowed and would attract legal consequences.

Note: Also once appointment is booked, based on availability of doctors at clinics tests will happen, any pending test will happen based on doctor availability and clinics will be updating the same to customers.

Instructions to be followed for a health check:

1. Please ensure you are on complete fasting for 10-To-12-Hours prior to check.
2. During fasting time do not take any kind of alcohol, cigarettes, tobacco or any other liquids (except Water) in the morning. If any medications taken, pls inform our staff before health check.
3. Please bring all your medical prescriptions and previous health medical records with you.
4. Kindly inform our staff, if you have a history of diabetes and cardiac problems.

For Women:

1. Pregnant women or those suspecting are advised not to undergo any X-Ray test.
2. It is advisable not to undergo any health check during menstrual cycle.

For further assistance, please call us on our Help Line #: 1860 500 7788.

Clinic Address: NYATI MILLENIUM PREMISES, COOPERATIVE SOCIETY LIMITED, SHOP NO.S1 & STILT FLOOR, BUILDING "C".

Contact No: (020) 2663 4331 - 32 - 34.

P.S: Health Check-Up may take 4 - 5hrs for completion on week days & 5 - 6hrs on Saturdays, kindly plan accordingly, Doctor Consultation will be completed after all the Reports are ready.

Warm Regards,
Apollo Clinic

CERTIFICATE OF MEDICAL FITNESS

This is to certify that I have conducted the clinical examination

of Swati S on 09/11/24

After reviewing the medical history and on clinical examination it has been found that he/she is

	Tick
<ul style="list-style-type: none">• Medically Fit	<input checked="" type="checkbox"/>
<ul style="list-style-type: none">• Fit with restrictions/recommendations <p>Though following restrictions have been revealed, in my opinion, these are not impediments to the job.</p> <p>1. <u>MSL G. B. Poy...</u></p> <p>2.</p> <p>3.</p> <p>However the employee should follow the advice/medication that has been communicated to him/her.</p> <p>Review after _____</p>	<input type="checkbox"/>
<ul style="list-style-type: none">• Currently Unfit. <p>Review after _____ recommended</p>	<input type="checkbox"/>
<ul style="list-style-type: none">• Unfit	<input type="checkbox"/>

Dr. Alla
B.B.S.
Registration No. 2023/117050
Medical Officer
The Apollo Clinic, (Location)

This certificate is not meant for medico-legal purposes

Date : 11/9/2024
 Patient Name : Mrs. Swati S
 UHID : CVIM.0000228350
 Age / Gender : 34Yrs 11Mths 15Days/
 Female
 Consultation Timing : 10:27 AM
 Department : General Practice
 Doctor : Dr. ALIA FATHIMA
 Registration No. : 9050
 Qualification : MBBS

Height : 152	Weight : 51	BMI : 22	Waist Circum : 82
Temp : 97	Pulse : 80	Resp : 18	B.P : 120/80

General Examination / Allergies History

O/E: conscious oriented

RS
 CVS
 P/A
 CAS | NASD

Clinical Diagnosis & Management Plan

HTC
 no c/o at present.
 Past h/o : Nil
 Sx h/o : 1. c section
 Fam h/o : Parents: S. HTN
 no alcoholics
 no allergies
 Diet: Nonveg
adv: = NH B₁₂ & iV H₂O₃
 - Post rep consultation

Follow up date:

Dr. Alia Fathima
 M.B.B.S.
 Registration No. 9234/9050
 Doctor Signature

9/10/24

om Sawati

Pili - LSCS 35 yr.
5 yr.

MH

Imp 23/10/24
2-8/28-30 Reg

OIH

Pili

ALS - Not willing
for pap smear

PH

NOT

DR. DIVYA AGALGE

OBSTETRICIANS & GYNECOLOGIST

Reg. No. 200000495

EYE EXAMINATION

DATE:-

9/11/20

NAME:- *Dr. K. S. Srinivas*

AGE:- *30*

CORPORATE:- *Dr. Srinivas*

	Right Eye	Left Eye
Distant vision	<i>6/6</i>	<i>6/6</i>
Near vision	<i>N/5</i>	<i>N/5</i>
Color vision	<i>Normal</i>	<i>Normal</i>
Fundus examination	<i>Normal</i>	<i>Normal</i>
Intraocular pressure	<i>Normal</i>	<i>Normal</i>
Slit lamp exam.	<i>Normal</i>	<i>Normal</i>

Dr. Srinivas

Impression - Normal Eye Check Up.

[Signature]

(Ophthalmology)

226350
34 Years

Mrs. Swathi S. (VMM)
Female

09-Nov-24 1:19:27 PM

Rate 66 Sinus rhythm normal p axis, V-rate 50-99

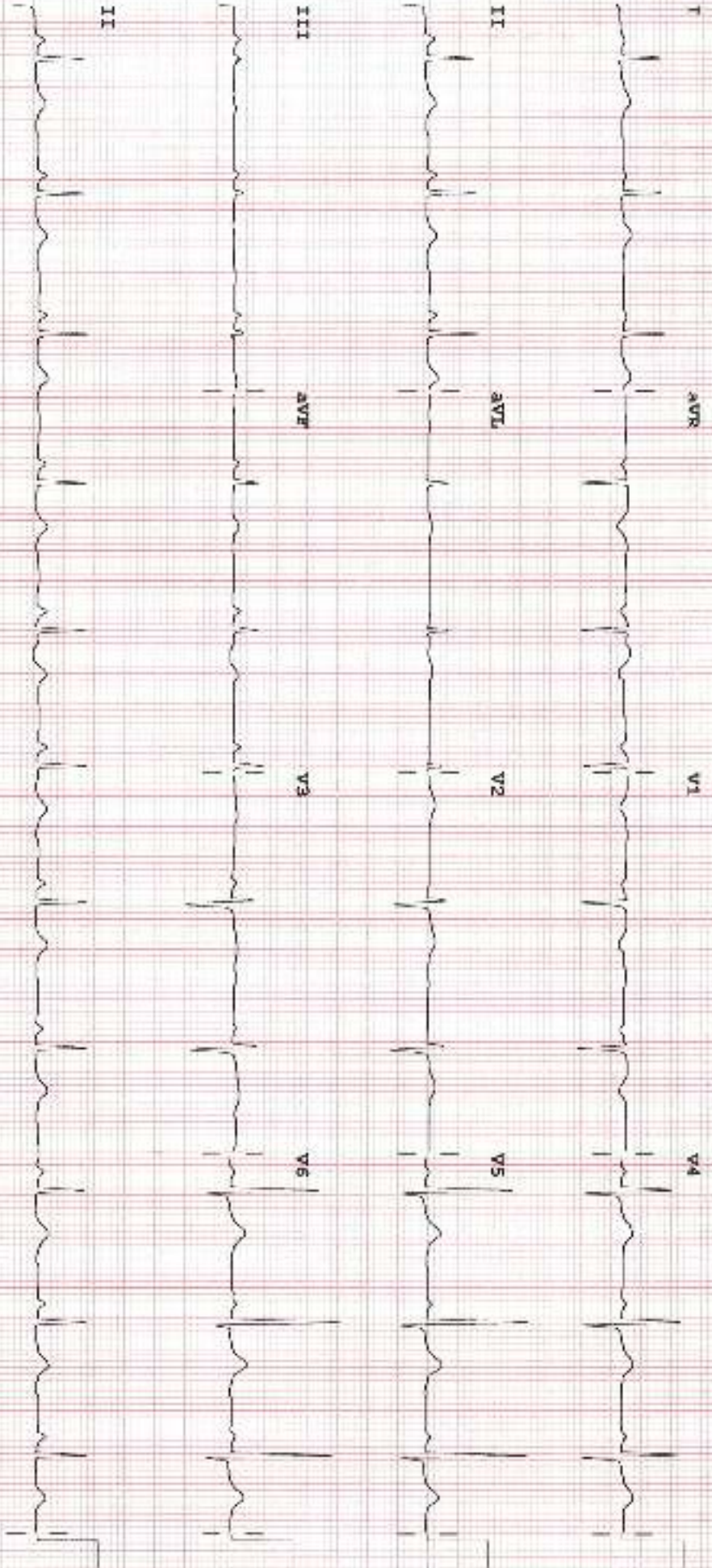
PR 133
QRSD 70
QT 419
QTc 439

--AXIS--
P 56
QRS 41
T 30

12 Lead: Standard Placement

- NORMAL ECG -

Unconfirmed Diagnosis



Device: Speed: 25 mm/sec Limb: 10 mm/mV Chest: 10.0 mm/mV

F 50- 0.50- 40 Hz W PH100B CL? P?

AXIS CE

Patient Name	: Mrs. SWATI S	Collected	: 09/Nov/2024 10:34AM
Age/Gender	: 34 Y 11 M 15 D/F	Received	: 09/Nov/2024 01:30PM
UHID/MR No	: CVIM.0000228350	Reported	: 09/Nov/2024 02:17PM
Visit ID	: CVIMOPV636859	Status	: Final Report
Ref Doctor	: Self	Sponsor Name	: ARCOFEMI HEALTHCARE LIMITED
Emp/Auth/TPA ID	: 22E37133		

DEPARTMENT OF HAEMATOLOGY

ARCOFEMI - MEDIWHEEL - FULL BODY HEALTH ANNUAL PLUS CHECK - FEMALE - 2D ECHO - PAN INDIA - FY2324

Test Name	Result	Unit	Blo. Ref. Interval	Method
HEMOGRAM , WHOLE BLOOD EDTA				
HAEMOGLOBIN	13.2	g/dL	12-15	Spectrophotometer
PCV	40.50	%	36-46	Electronic pulse & Calculation
RBC COUNT	4.82	Million/cu.mm	3.8-4.8	Electrical Impedance
MCV	84	fL	83-101	Calculated
MCH	27.5	pg	27-32	Calculated
MCHC	32.7	g/dL	31.5-34.5	Calculated
R.D.W	14.3	%	11.6-14	Calculated
TOTAL LEUCOCYTE COUNT (TLC)	8,380	cells/cu.mm	4000-10000	Electrical Impedance
DIFFERENTIAL LEUCOCYTIC COUNT (DLC)				
NEUTROPHILS	72.5	%	40-80	Electrical Impedance
LYMPHOCYTES	19.6	%	20-40	Electrical Impedance
EOSINOPHILS	1	%	1-6	Electrical Impedance
MONOCYTES	6.7	%	2-10	Electrical Impedance
BASOPHILS	0.2	%	<1-2	Electrical Impedance
ABSOLUTE LEUCOCYTE COUNT				
NEUTROPHILS	6075.5	Cells/cu.mm	2000-7000	Calculated
LYMPHOCYTES	1642.48	Cells/cu.mm	1000-3000	Calculated
EOSINOPHILS	83.8	Cells/cu.mm	20-500	Calculated
MONOCYTES	561.46	Cells/cu.mm	200-1000	Calculated
BASOPHILS	16.76	Cells/cu.mm	0-100	Calculated
Neutrophil lymphocyte ratio (NLR)	3.7		0.78- 3.53	Calculated
PLATELET COUNT	285000	cells/cu.mm	150000-410000	Electrical impedance
ERYTHROCYTE SEDIMENTATION RATE (ESR)	5	mm at the end of 1 hour	0-20	Modified Westergren
PERIPHERAL SMEAR				

RBC's are Normocytic Normochromic,
WBC's are normal in number and morphology
Platelets are Adequate
No Abnormal cells seen.

Page 2 of 15



Dr. Sanjay Ingle
M.B.B.S.M.D.(Pathology)
Consultant Pathologist

SIN No: VIR241100726

This test has been performed at Apollo Health and Lifestyle Ltd- Sadashiv Peth Pune, Diagnostics Lab





Certificate No. MC-5697

Patient Name	: Mrs.SWATI S	Collected	: 09/Nov/2024 10:34AM
Age/Gender	: 34 Y 11 M 15 D/F	Received	: 09/Nov/2024 01:30PM
UHID/MR No	: CVIM0000228350	Reported	: 09/Nov/2024 02:17PM
Visit ID	: CVIMOPV638859	Status	: Final Report
Ref Doctor	: Self	Sponsor Name	: ARCOFEMI HEALTHCARE LIMITED
Emp/Auth/TPA ID	: 22E37133		

DEPARTMENT OF HAEMATOLOGY

ARCOFEMI - MEDIWHEEL - FULL BODY HEALTH ANNUAL PLUS CHECK - FEMALE - 2D ECHO - PAN INDIA - FY2324




DR. Sanjay Ingle
M.B.B.S., M.D. (Pathology)
Consultant Pathologist

SIN No: VIR241100726

This test has been performed at Apollo Health and Lifestyle Ltd- Sadashiv Path Pune, Diagnostics Lab

Patient Name	: Mrs. SWATI S	Collected	: 09/Nov/2024 10:34AM
Age/Gender	: 34 Y 11 M 15 D/F	Received	: 09/Nov/2024 01:30PM
UHID/MR No	: CVIM 0000228350	Reported	: 09/Nov/2024 04:06PM
Visit ID	: CVIMOPV638659	Status	: Final Report
Ref Doctor	: Self	Sponsor Name	: ARCOFEMI HEALTHCARE LIMITED :
Emp/Auth/TPA ID	: 22E37133		

DEPARTMENT OF HAEMATOLOGY

ARCOFEMI - MEDIWHEEL - FULL BODY HEALTH ANNUAL PLUS CHECK - FEMALE - 2D ECHO - PAN INDIA - FY2324

Test Name	Result	Unit	Bio. Ref. Interval	Method
BLOOD GROUP ABO AND RH FACTOR , WHOLE BLOOD EDTA				
BLOOD GROUP TYPE	O			Microplate Hemagglutination
Rh TYPE	Positive			Microplate Hemagglutination



DR. Sanjay Ingle
M.B.B.S., M.D (Pathology)
Consultant Pathologist

SIN No: VIR241100726

This test has been performed at Apollo Health and Lifestyle Ltd- Sadashiv Peth Pune, Diagnostics Lab



Patient Name	: Mrs. SWATI S	Collected	: 09/Nov/2024 10:34AM
Age/Gender	: 34 Y 11 M 15 D/F	Received	: 09/Nov/2024 01:32PM
UHID/MR No	: CVIM.0000228350	Reported	: 09/Nov/2024 03:14PM
Visit ID	: CVIMOPV638859	Status	: Final Report
Ref Doctor	: Self	Sponsor Name	: ARCOFEMI HEALTHCARE LIMITED
Emp/Auth/TPA ID	: 22E37133		

DEPARTMENT OF BIOCHEMISTRY

ARCOFEMI - MEDIWHEEL - FULL BODY HEALTH ANNUAL PLUS CHECK - FEMALE - 2D ECHO - PAN INDIA - FY2324

Test Name	Result	Unit	Bio. Ref. Interval	Method
HBA1C (GLYCATED HEMOGLOBIN) , WHOLE BLOOD EDTA				
HBA1C, GLYCATED HEMOGLOBIN	5.1	%		HPLC
ESTIMATED AVERAGE GLUCOSE (eAG)	100	mg/dL		Calculated

Comment:

Reference Range as per American Diabetes Association (ADA) 2023 Guidelines:

REFERENCE GROUP	HBA1C %
NON DIABETIC	< 5.7
PREDIABETES	5.7 – 6.4
DIABETES	≥ 6.5
DIABETICS	
EXCELLENT CONTROL	6 – 7
FAIR TO GOOD CONTROL	7 – 8
UNSATISFACTORY CONTROL	8 – 10
POOR CONTROL	>10

Note: Dietary preparation or fasting is not required.

1. HbA1C is recommended by American Diabetes Association for Diagnosing Diabetes and monitoring Glycemic Control by American Diabetes Association guidelines 2023.
2. Trends in HbA1C values is a better indicator of Glycemic control than a single test.
3. Low HbA1C in Non-Diabetic patients are associated with Anemia (Iron Deficiency/Hemolytic), Liver Disorders, Chronic Kidney Disease. Clinical Correlation is advised in interpretation of low Values.
4. Falsely low HbA1c (below 4%) may be observed in patients with clinical conditions that shorten erythrocyte life span or decrease mean erythrocyte age. HbA1c may not accurately reflect glycaemic control when clinical conditions that affect erythrocyte survival are present.
5. In cases of Interference of Hemoglobin variants in HbA1C, alternative methods (Fructosamine) estimation is recommended for Glycemic Control.
 - A- HbF >25%
 - B- Homozygous Hemoglobinopathy.
 (Hb Electrophoresis is recommended method for detection of Hemoglobinopathy)

DR. Sanjay Ingle
M.B.B.S.M.D(Pathology)
Consultant Pathologist

SIN No. VIR241100727

This test has been performed at Apollo Health and Lifestyle Ltd- Sadashiv Peth Pune, Diagnostics Lab



Patient Name	: Mrs.SWATI S	Collected	: 09/Nov/2024 10:34AM
Age/Gender	: 34 Y 11 M 15 DF	Received	: 09/Nov/2024 01:22PM
UHID/MR No	: CVIM.000228350	Reported	: 09/Nov/2024 02:35PM
Visit ID	: CVIMOPV636859	Status	: Final Report
Ref Doctor	: Self	Sponsor Name	: ARCOFEMI HEALTHCARE LIMITED
Emp/Auth/TPA ID	: 22E37133		

DEPARTMENT OF BIOCHEMISTRY

ARCOFEMI - MEDIWHEEL - FULL BODY HEALTH ANNUAL PLUS CHECK - FEMALE - 2D ECHO - PAN INDIA - FY2324

Test Name	Result	Unit	Bio. Ref. Interval	Method
LIVER FUNCTION TEST (LFT) , SERUM				
BILIRUBIN, TOTAL	1.39	mg/dL	0.3-1.2	DPD
BILIRUBIN CONJUGATED (DIRECT)	0.20	mg/dL	<0.2	DPD
BILIRUBIN (INDIRECT)	1.19	mg/dL	0.0-1.1	Dual Wavelength
ALANINE AMINOTRANSFERASE (ALT/SGPT)	12.38	U/L	<35	IFCC
ASPARTATE AMINOTRANSFERASE (AST/SGOT)	23.0	U/L	<35	IFCC
AST (SGOT) / ALT (SGPT) RATIO (DE RITIS)	1.8		<1.15	Calculated
ALKALINE PHOSPHATASE	76.26	U/L	30-120	IFCC
PROTEIN, TOTAL	7.91	g/dL	6.6-8.3	Biuret
ALBUMIN	4.67	g/dL	3.5-5.2	BROMO CRESOL GREEN
GLOBULIN	3.24	g/dL	2.0-3.5	Calculated
A/G RATIO	1.44		0.9-2.0	Calculated

Comment:

LFT results reflect different aspects of the health of the liver, i.e., hepatocyte integrity (AST & ALT), synthesis and secretion of bile (Bilirubin, ALP), cholestasis (ALP, GGT), protein synthesis (Albumin) Common patterns seen:

1. Hepatocellular Injury:

*AST – Elevated levels can be seen. However, it is not specific to liver and can be raised in cardiac and skeletal injuries. *ALT – Elevated levels indicate hepatocellular damage. It is considered to be most specific lab test for hepatocellular injury. Values also correlate well with increasing BMI. Disproportionate increase in AST, ALT compared with ALP. AST: ALT (ratio) – In case of hepatocellular injury AST: ALT > 1 In Alcoholic Liver Disease AST: ALT usually >2. This ratio is also seen to be increased in NAFLD, Wilson's diseases, Cirrhosis, but the increase is usually not >2.

2. Cholestatic Pattern:*ALP – Disproportionate increase in ALP compared with AST, ALT. ALP elevation also seen in pregnancy, impacted by age and sex.*Bilirubin elevated- predominantly direct , To establish the hepatic origin correlation with elevated GGT helps.

3. Synthetic function impairment:*Albumin- Liver disease reduces albumin levels, Correlation with PT (Prothrombin Time) helps.

4. Associated tests for assessment of liver fibrosis - Fibrosis-4 and APRI Index.




Dr Sneha Shah
MBBS, MD (Pathology)
Consultant Pathologist
SIN No: VIR241100728

This test has been performed at Apollo Health and Lifestyle Ltd - Sadashiv Peth Pune, Diagnostics Lab



Certificate No: MC-5697

Patient Name	: Mrs.SWATI S	Collected	: 08/Nov/2024 10:34AM
Age/Gender	: 34 Y 11 M 15 D/F	Received	: 08/Nov/2024 02:32PM
LHID/MR No	: CVIM.D000228350	Reported	: 09/Nov/2024 03:30PM
Visit ID	: CVIMOPV638859	Status	: Final Report
Ref Doctor	: Self	Sponsor Name	: ARCOFEMI HEALTHCARE LIMITED
Emp/Auth/TPA ID	: 22F37133		

DEPARTMENT OF IMMUNOLOGY

ARCOFEMI - MEDIWHEEL - FULL BODY HEALTH ANNUAL PLUS CHECK - FEMALE - 2D ECHO - PAN INDIA - FY2324

High	High	High	High	Pituitary Adenoma; TSHoma/Thyrotropinoma
------	------	------	------	--



DR. Sanjay Ingle
M.B.B.S., M.D.(Pathology)
Consultant Pathologist

SIN No: VIR241100732

This test has been performed at Apollo Health and Lifestyle Ltd- Sadashiv Peth Pune, Diagnostics Lab

Patient Name	: Mrs.SWATI S	Collected	: 09/Nov/2024 10:34AM
Age/Gender	: 34 Y 11 M 15 D/F	Received	: 09/Nov/2024 01:38PM
UHID/MR No	: CVIM.0000228350	Reported	: 09/Nov/2024 02:22PM
Visit ID	: CVIMOPV638859	Status	: Final Report
Ref Doctor	: Self	Sponsor Name	: ARCOFEMI HEALTHCARE LIMITED
Emp/Auth/TPA ID	: 22E37133		

DEPARTMENT OF CLINICAL PATHOLOGY

ARCOFEMI - MEDIWHEEL - FULL BODY HEALTH ANNUAL PLUS CHECK - FEMALE - 2D ECHO - PAN INDIA - FY2324

Test Name	Result	Unit	Bio. Ref. Interval	Method
URINE GLUCOSE(POST PRANDIAL)	NEGATIVE		NEGATIVE	GOD-POD

Test Name	Result	Unit	Bio. Ref. Interval	Method
URINE GLUCOSE(FASTING)	NEGATIVE		NEGATIVE	GOD-POD

*** End Of Report ***



Sneha Shah
 Dr Sneha Shah
 MBBS, MD (Pathology),
 Consultant Pathologist
 SIN No:VIR241100731

This test has been performed at Apollo Health and Lifestyle Ltd- Sadashiv Peth Pune, Diagnostics Lab

Patient Name	: Mrs.SWATI S	Collected	: 08/Nov/2024 10:34AM
Age/Gender	: 34 Y 11 M 15 D/F	Received	: 08/Nov/2024 01:38PM
UHID/MR No	: CVIM.D000229350	Reported	: 08/Nov/2024 02:22PM
Visit ID	: CVIMCPV638859	Status	: Final Report
Ref Doctor	: Self	Sponsor Name	: ARCOFEMI HEALTHCARE LIMITED
Emp/Ault/VTPA ID	: 22E37133		

TERMS AND CONDITIONS GOVERNING THIS REPORT

1. Reported results are for information and interpretation of the referring doctor or such other medical professionals, who understand reporting units, reference ranges and limitation of technologies.Laboratories not be responsible for any interpretation whatsoever.
2. It is presumed that the tests performed are, on the specimen / sample being to the patient named or identified and the verifications of particulars have been confirmed by the patient or his / her representative at the point of generation of said specimen.
3. The reported results are restricted to the given specimen only. Results may vary from lab to lab and from time to time for the same parameter for the same patient (within subject biological variation).
4. The patient details along with their results in certain cases like notifiable diseases and as per local regulatory requirements will be communicated to the assigned regulatory bodies.
5. The patient samples can be used as part of internal quality control, test verification, data analysis purposes within the testing scope of the laboratory.
6. This report is not valid for medico legal purposes. It is performed to facilitate medical diagnosis only.



Dr. Sneha Shah
MBBS, MD (Pathology)
Consultant Pathologist

SIN No:VIR241100731

This test has been performed at Apollo Health and Lifestyle Ltd- Sadashiv Peeth Pune, Diagnostics Lab



NAME	SWATI S	DATE	11/11/2024
AGE/SEX	34 Y/ F	REF	

ECHOCARDIOGRAPHY REPORT

LV SIZE - NORMAL
NORMAL WALL THICKNESS
RWMA - ABSENT
LV SYSTOLIC FUNCTION - NORMAL
TRIVIAL TRICUSPID REGURGITATION.RVSP- 22 MM HG
PULMONARY PRESSURES - NORMAL.
IAS IVS INTACT
IVC NORMAL
PERICARDIAL EFFUSION/ CLOT/ VEGETATION ABSENT

MEASUREMENTS

AOMM	LAMM	IVSD MM	LVIDD MM	PWD MM	LVIDS MM	EF %
23	25	09	44	09	25	60

IMPRESSION:

NORMAL LV SYSTOLIC FUNCTION
NO PULMONARY HYPERTENSION

DR PRAMOD NARKHEDE

MBBS, DNB (MEDICINE), DNB (CARDIOLOGY), FSCAI
INTERVENTIONAL CARDIOLOGIST
MMC 2004093195
7350684764

Patient Name	: Mrs. Swati S	Age	: 34Yrs 11Mths 10Days
UHID	: CVIM.0000225350	OP Visit No.	: CVIMOPV638859
Printed On	: 09-11-2024 08:09 AM	Advised / Pres Doctor	: --
Department	: Radiology	Qualification	: --
Referred By	: Self	Registration No.	: --
Employer Id	: 22037183		

DEPARTMENT OF RADIOLOGY

X-RAY CHEST PA

Trachea appears normal.

Both the lung fields are clear.

Cardiac shadows appear apparently normal.

Both domes of diaphragm appear normal.

Both costophrenic angles are clear.

Bony thoracic cage shows no deformity. Visualised bones appear normal.

Soft tissues appear normal.

Impression: Essentially Normal Study.

---End Of The Report---



Dr. PREETI P KATHE
DMRE, MD, DNB
2003/04/1886
Radiology

Patient Name	: Mrs. Swati S	Age	: 34Yrs 11Mths 16Days
UHID	: CVIM0000228350	OP Visit No.	: CVIMOPV638859
Printed On	: 09-11-2024 07:46 AM	Advised/Pres Doctor	: --
Department	: Radiology	Qualification	: --
Referred By	: Self	Registration No.	: --
Employee Id	: 22E37133		

DEPARTMENT OF RADIOLOGY

ULTRASOUND ABDOMEN AND PELVIS

Liver appears normal in size and echotexture. No focal lesion is seen.
PV and CBD normal. No dilatation of the intrahepatic biliary radicals.

Gall bladder is well distended. No evidence of calculus. Wall thickness appears normal. No evidence of periGB collection. Tiny polyp measuring 3.5 mm seen on anterior wall.

Spleen appears normal. No focal lesion seen. Splenic vein appears normal.

Pancreas appears normal in echopattern. No focal/mass lesion/calcification. No evidence of peripancreatic free fluid or collection. Pancreatic duct appears normal.

Both the kidneys appear normal in size, shape and echopattern. Cortical thickness and CM differentiation are maintained. No calculus / hydronephrosis seen on either side.

Urinary Bladder is well distended and appears normal. No evidence of any wall thickening or abnormality. No evidence of any intrinsic or extrinsic bladder mass detected.

Uterus appears normal in size. It shows normal shape & echo pattern.
Endometrial echo-complex appears normal and measures 8.6 mm.

Both ovaries appear normal in size, shape and echotexture. Right vary shows a 24 mm follicle and left ovary shows a 14 mm follicle.
No evidence of any adnexal pathology noted.


Bowel loops and Retroperitoneum appear normal. Aorta and IVC appear normal.
No abnormal lymphadenopathy noted.

IMPRESSION:-

Tiny gall bladder polyp seen.

(The sonography findings should always be considered in correlation with the clinical and other investigation finding where applicable.)

---End Of The Report---



Dr. PREETI P KATHE
DMRE, MD, DNB
2003/04/1886
Radiology



Apollo Clinic

CONSENT FORM

Patient Name: Swati S. Age: 35

UHID Number: Company Name: Bank of Baroda

I Mr/Mrs/Ms Swati Employee of Bank of Baroda

(Company) Want to Inform you that I am not interested in getting Pap Smear

Tests done which is a part of my routine health check package. ENT consultations pending

And I claim the above statement in my full consciousness.

Patient Signature: Swati

Date: 9/11/24