


भारत सरकार
GOVERNMENT OF INDIA


 रबिन्द्र नाथ
 Rabindra Nath
 जन्म तिथि/DOB: 28/01/1973
 पुरुष/ MALE
 Mobile No: 9818324661



8110 5052 8622
 VID : 9179 3486 5879 4893

मेरा आधार, मेरी पहचान

Handwritten signature


भारतीय विशिष्ट पहचान प्राधिकरण
UNIQUE IDENTIFICATION AUTHORITY OF INDIA

पति:
 आत्मज: श्री धर लाल, 538, डीडीए जनता फ्लॉट्स,
 एनटीपीसी के पास, बदरपुर, बदरपुर, दक्षिण दिल्ली,
 दिल्ली - 110044

Address :
 S/O: Shri Dhar Lal, 538, DDA Janta Flats,
 Near NTPC, Badarpur, Badarpur, South
 Delhi,
 Delhi - 110044



8110 5052 8622
 VID : 9179 3486 5879 4893

 1947
 1800 300 1947

 help@uidai.gov.in

 www.uidai.gov.in

 P.O. Box No. 1947,
 Bengaluru-560 001

MALIK RADIX HEALTH CARE PVT. LTD.
 C-217, C-218, Nirman Vihar,
 Delhi-110092
 Ph.: 011-49287456, 011-61381379
 Regd. No. 607



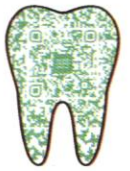RADIX COSMO DENTAL

(UNIT OF MALIK RADIX HEALTHCARE PVT. LTD.)

C-216, 217, 218, Nirman Vihar, Vikas Marg, Delhi - 110092

Ph. : 011-22508272, 22520249 • M. : 9999254639

E-mail : radixhealthcare@yahoo.co.in • www.radixhealthcare.org



CONSULTANTS ON PANEL

PAEDIATRICS

Dr Ravi Malik (MBBS, MD)
Dr Harit Prasad (MBBS, MD, Pdt)
Dr Ritu Jain (MBBS, MD)

GYNAECOLOGY

Dr Renu Malik (MBBS, MD)
Dr Meena Malhotra (MBBS, MD)
Dr Rajni (MBBS, MD)
Dr Manju Gupta (MBBS, MS)
Dr Vaishali Saini (MBBS, DGO)
Dr Rupam Arora (MBBS, MD)

DENTAL

Dr Shruti Malik (BDS, MDS)
Dr Annu Saini (BDS, MDS)
Dr Rachit Thukral (BDS, MDS)
Dr Mohit Mangla (BDS, MDS)
Dr Tarun Mittal (BDS, MDS)
Dr Geetika Sharma (BDS)
Dr Shilpa Verma (BDS)

CHILD GASTROENTEROLOGY

Dr S. K Mittal (MBBS, MD)

MEDICINE

Dr A S Talwar (MBBS, MD)
Dr Sunny Uppal (MBBS, MD)
Dr Surendra Rajpal (MBBS, MD)

RESPIRATORY MEDICINE /PULMONOLOGY

Dr Abhinav Bhanot (MBBS, DNB)

LAPAROSCOPY SURGERY

Dr Ajay Jain (MBBS, MS)
Dr Deepak Saran (MBBS, MS)
Dr Pradeep Saini (MBBS, MS)
Dr G. S Garg (MBBS, MS)

ORTHOPAEDICS

Dr Vikas Bhardwaj (MBBS, MS ORTHO, DNB)
Dr Prabhat Aggarwal (MBBS, MS ORTHO)
Dr KB Tiwari (MBBS, MS ORTHO)
Dr Deepak Kumar Arora (MBBS, MS ORTHO)

EYE/OPTHALMOLOGY

Dr Nidhi Gupta (MBBS, MS, DNB, PGDM)
Dr Himanshu Singh Pundir (MBBS, MS)

ENT

Dr Sharad Kumar Singhi (MBBS, MS)
Dr Prateek Sharma (MBBS, MS)
Dr Ashok Singh (MBBS, MS)
Dr A K Lahiri (MBBS, MS)

RADIOLOGY(ULTRASOUND)

Dr K K Sinha (MBBS DMRB)
Dr T K Vohra (MBBS, MD)
Dr Rajesh Malhotra (MBBS, MD)
Dr Ashish Tomar (MBBS, MD)

PATHOLOGY

Dr Reema Dahiya (MBBS, MD PATH)
Dr Meenu Aggarwal (MBBS, MD PATH)

ANAESTHESIA

Dr Rajesh Dhali (MBBS, MD)
Dr Rakesh Atrey (MBBS, MD)
Dr R K Arora (MBBS, MD)
Dr Swaraj Garg (MBBS, MD)

DERMATOLOGY

Dr Niharika Jha (MBBS, MD)

PLASTIC & COSMETIC SURGERY

Dr Ayush Jain (MBBS, MS, MCh)

PAEDIATRIC SURGERY

Dr Dharmendra Singh (MBBS, MS, M.Ch)
Dr Satish Aggarwal (MBBS, MS, M.Ch)

PAEDIATRIC NEPHROLOGY

Dr A S Vasudev (MD, Dip.in. Paed.)

NEPHROLOGY

Dr Javed (MBBS, MD, Nephro)

CARDIOLOGY

Dr Nishant Tyagi (MBBS, MD)

NEUROLOGY

Dr Amit Batra (MBBS, MD)

GASTROENTEROLOGY

Dr Deepak Lahoti (MBBS, MD)
Dr Naresh Aggarwal (MBBS, MD)
Dr Ashok Goyal (MBBS, MD)
Dr Ankur Singhal (MBBS, MD)

UROLOGY

Dr Nikhil Sharma (MBBS, Mch)
Dr Ankur Singhal (MBBS, MD)

PSYCHIATRY

Dr Mohit Sharma (MBBS, MD)

PHYSIOTHERAPY

Dr Kirti Dwivedi

Dr Ravi Kumar

NUTRITIONIST

Dr Deepika Kohli

Dr Sakshi Rana

CLINICAL PSYCHOLOGIST

Dr. Sarika Singh

Dr. Shruti Malik

BDS, MDS (Endodontics)

+91-9899561092

Timings : 10:00 am. to 2:00 pm.
6:00 pm. to 8:30 pm.

CLINICAL EXAMINATION:-

1. TMJ:-

Routine dental check up.

2. DENTAL STATUS:

M/H - Nothing relevant reported

- a. Caries Teeth :
- b. Fracture Teeth :
- c. Root Stumps : ofc.
- d. Gingivitis :
- e. Periodontitis :
- f. Impacted Teeth :
- g. Malaligned Teeth :

ofc.

Stains +

Calculus +

Missing - 17

3. ORAL LESIONS:-

4. DIAGNOSIS:-

ofc.

Oral prophylaxis

5. TREATMENT PLANNING:

P. kit.

6. FOLLOW UP:-

Referral To Other Consultant: Yes/ No

If Yes, please mention the Name:

Doctor's Signature

Annika

Facilities Available :

- ★ MULTI-SPECIALITY HOSPITAL ★ MODULAR FULLY EQUIPPED OT ★ NURSERY ★ LAPROSCOPIC SURGERY
- ★ 24X7 EMERGENCY ★ OPG ★ DENTAL ★ 24X7 DIAGNOSTICS ★ LABOUR ROOM ★ ECHO ★ EEG ★ DIGITAL X-RAY ★ CT SCAN
- ★ ECG ★ ULTRASOUND ★ RICU/ICU ★ ALL SPECIALITY OPD ★ PLASTIC & COSMETIC SURGERY ★ DIALYSIS ★ PHARMACY

MAC600 1.02

ID: 9818324661

1-Mar-2024 9:44:50

ID: 9818324661

Rabindra Nath

I

aVR

V1

V4

II

aVL

V2

V5

III

aVF

V3

V6

0

51years

Male

Vent. rate 61 bpm
 QRS duration 88 ms
 QT/QTc 366/368 ms
 PR interval 132 ms
 P duration 84 ms
 RR interval 983 ms
 P-R-T axes 17 44 42

Auto gain applied
 25.0 mm/s
 5.0|5.0 mm/mV
 50Hz
 61 bpm

by 2.5s + 1 rhythm ld

MAC600 1.02

12SL™ v239

abgm

Malik Radix HealthCare.

ELECTROCARDIOGRAM

Name: MR. RABINDRA NATH

Age & Sex: 51 YR/ MALE

Ref By: MEDIWHEEL

Date: 11/03/2024

ECG FINDINGS:

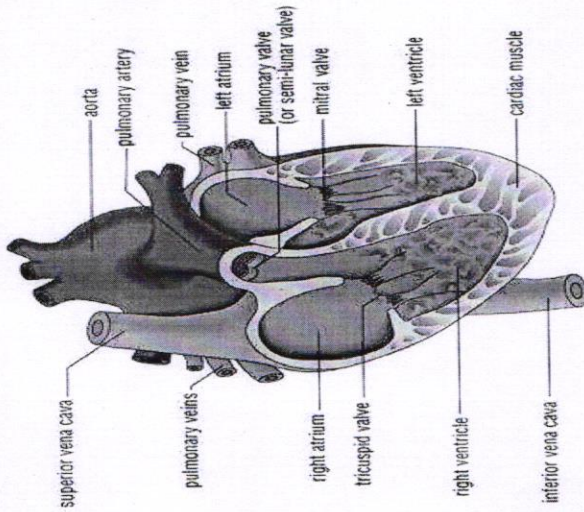
Rate 61 bpm Rhythm Sinus Mechanism Normal

Axis Normal P Wave Normal PR Interval 0.13/Sec

QRS Complex Normal QT Interval Normal Q Wave Normal

ST Segment Normal T Wave Normal

Conclusion Sinus Rhythm, Normal Axis, WNL.



Doctors Signature Dr. SHEIKH NAZIR AHMED
M.D. "Physician"
PGDCC
DMC-46499



LAB REPORT

Reg. Date	11/03/2024	Patient Id	2403110004	DOB.	28/01/1973
Name	MR. RABINDRA NATH	Gender	M	Perm. ID	
Age	51 Yrs. 1 Mn. 12 Day	Panel	MEDIWHEEL	Reported	11/03/2024 18:55:33
Ref. By	MEDIWHEEL				

Test Name	Result	Units	Ref. Range
MW FULL BODY ANNUAL PLUS ABOVE 50 MALE			

HAEMATOLOGY

COMPLETE HAEMOGRAM

HAEMOGLOBIN (HB%)	12.7	gm/dl	13 - 18
TOTAL LEUCOCYTE COUNT (TLC)	5,800	/cumm	4000 - 11000
DIFFERENTIAL LEUCOCYTE COUNT (DLC)			
NEUTROPHIL	67	%	40 - 80
LYMPHOCYTE	24	%	28 - 55
MONOCYTE	05	%	02 - 10
EOSINOPHIL	04	%	01 - 06
BASOPHIL	00	%	0 - 0
ESR (WESTEGREN'S METHOD)	16	mm/1st hr.	0 - 10
R B C COUNT	4.80	Millions/cmm	4.247 - 5.4
P.C.V / HAEMATOCRIT	40.4	%	40 - 54
M C V	84.2	fl.	80 - 100
M C H	26.5	Picogram	27.0 - 31.0
M C H C	31.4	gm/dl	33 - 37
PLATELET COUNT	2.16	Lakh/cu mm	1.50 - 4.50
BLOOD GROUP ABO	" A "		
RH TYPING	Positive		
BLOOD SUGAR FASTING	89.37	mg/dl	70 - 100
URINE SUGAR FASTING	NIL		NIL

THYROID PROFILE

Free T3 ELFA	2.87	ng/ml	02 - 04
Free T4 ELFA	1.14	ug/dl	0.8 - 2.7

Checked by : _____
Page 1 Contd...2

If test results are alarming or unexpected, patient is advised to contact the laboratory immediately for possible remedial action.

Facilities Available

- Multispeciality Hospital - 24 Hours Emergency - X-Ray/ ECG/ Ultrasound/ CT Scan - Dental- Fully Equipped Operation Theatre
- Fully Functional Lab - 24/7 Casualty/ ICU-Nursery 24/7 Pharmacy - Labour Room - All Speciality OPD - Laproscopic Surgery - ECHO - Plastic Surgery



LAB REPORT

Reg. Date	11/03/2024	Patient Id	2403110004	DOB.	28/01/1973
Name	MR. RABINDRA NATH	Gender	M	Perm. ID	
Age	51 Yrs. 1 Mn. 12 Day	Panel	MEDIWHEEL	Reported	11/03/2024 18:55:33
Ref. By	MEDIWHEEL				

Test Name	Result	Units	Ref. Range
TSH Serum/ELFA	4.910	uIU/ml	0.25 - 5.50 uIU/ml

Interpretation

Clinical Use

- Diagnose Hypothyroidism and Hyperthyroidism
- Monitor T4 replacement or T4 suppressive Therapy
- Quantify TSH levels in the subnormal range

Increased Levels : Primary Hypothyroidism Subclinical Hypothyroidism, TSH dependent, Thyroid Hormone Resistance.

Decreased Levels : Grave's Disease, Autonomous Thyroid Hormone Secretion, TSH Deficiency

LIPID PROFILE

TOTAL CHOLESTEROL	174.80	mg/dL	130.0 - 200.0 (<200)
TRIGLYCERIDES	83.10	mg/dL	80.5 - 150.0 (<150)
H D L CHOLESTEROL DIRECT	51.00	mg/dL	35.0 - 60.0 (<40->59)
V L D L	16.6	mg/dL	4.0 - 30. (23-45)
L D L CHOLESTEROL	107.2	mg/dL	50.0 - 150.0 (50-150)
TOTAL CHOLESTEROL / HDL RATIO	3.4		3.3 - 5.1
LDL / HDL CHOLESTEROL RATIO	2.1		1.5 - 3.5
SERUM URIC ACID	5.77	mg/dl	3.4 - 7.0
BLOOD UREA NITROGEN (BUN)	9.20	mg/dl	6.0 - 21.0

Checked by : _____
Page 2 Contd...3

If test results are alarming or unexpected, patient is advised to contact the laboratory immediately for possible remedial action.

Facilities Available

- Multispeciality Hospital - 24 Hours Emergency - X-Ray/ ECG/ Ultrasound/ CT Scan - Dental- Fully Equipped Operation Theatre
- Fully Functional Lab - 24/7 Casualty/ ICU-Nursery 24/7 Pharmacy - Labour Room - All Speciality OPD - Laproscopic Surgery - ECHO - Plastic Surgery



LAB REPORT

Reg. Date	11/03/2024	Patient Id	2403110004	DOB.	28/01/1973
Name	MR. RABINDRA NATH	Gender	M	Perm. ID	
Age	51 Yrs. 1 Mn. 12 Day	Panel	MEDIWHEEL	Reported	11/03/2024 18:55:33
Ref. By	MEDIWHEEL				

Test Name	Result	Units	Ref. Range
SERUM CREATININE	1.00	mg/dl	0.7 - 1.4
BUN/CREAT RATIO	4.31	mg/dl	10 - 20
<u>LIVER FUNCTION TEST (LFT)</u>			
BILIRUBIN TOTAL	1.00	mg/dl	0.2 - 1.2
CONJUGATED (D. BILIRUBIN)	0.15	mg/dl	0.00 - 0.3
UNCONJUGATED (I.D. BILIRUBIN)	0.85	mg/dl	0.2 - 0.9
SGOT / AST	15.30	IU/L	0 - 35
SGPT / ALT	14.2	IU/L	0 - 35
ALKALINE PHOSPHATASE	114.20	U/L	64 - 306
TOTAL PROTEIN	8.84	gm/dl	6.0 - 8.3
ALBUMIN	4.29	gm/dl	3.2 - 5.0
GLOBULIN	4.29	gm/dl	2.5 - 5.6
A/G RATIO	1.00		0.9 - 2.0
GAMMA GT	20.14	IU/L	0.0 - 45.0
TOTAL PSA	0.91	ng/ml	
Chemiluminescence			

INTERPRETATION :
Expected Values :

99%	:	of Healthy males	0.0-4.0 ng/ml
80%	:	of Benign prostatic hypertrophy	0.0-4.0 ng/ml
81%	:	of Prostatic Carcinomas	Above 4.0 ng/ml

PSA is reliable tumour marker for already diagnosed prostatic carcinomas. It is uniquely associated only with prostatic tissue, and therefore is specific for it. Baseline levels measured prior to therapeutic intervention and followed later by serial periodical measurements will predict the outcome of therapy. It also helps in early discovery of recurrences, relapses and metastases.

Urine Routine Examination

Checked by : -----
 Page 3 Contd...4

If test results are alarming or unexpected, patient is advised to contact the laboratory immediately for possible remedial action.

Facilities Available

- Multispeciality Hospital - 24 Hours Emergency - X-Ray/ ECG/ Ultrasound/ CT Scan - Dental- Fully Equipped Operation Theatre
- Fully Functional Lab - 24/7 Casualty/ ICU-Nursery 24/7 Pharmacy - Labour Room - All Speciality OPD - Laproscopic Surgery - ECHO - Plastic Surgery



LAB REPORT

Reg. Date	11/03/2024	Patient Id	2403110004	DOB.	28/01/1973
Name	MR. RABINDRA NATH	Gender	M	Perm. ID	
Age	51 Yrs. 1 Mn. 12 Day	Panel	MEDIWHEEL	Reported	11/03/2024 18:55:33
Ref. By	MEDIWHEEL				

Test Name	Result	Units	Ref. Range
-----------	--------	-------	------------

PHYSICAL EXAMINATION

QUANTITY	25	ml.	
COLOUR	Pale Yellow		Pale Yellow
TRANSPARENCY	Clear		
SPECIFIC GRAVITY	1.025		
PH	6.0		

CHEMICAL EXAMINATION

ALBUMIN	Nil
SUGAR	Nil

MICROSCOPIC EXAMINATION

PUS CELLS	1-2	/HPF
RBC'S	Nil	/HPF
CASTS	Nil	
CRYSTALS	NIL	
EPITHELIAL CELLS	0-1	/HPF
BACTERIA	Nil	
OTHERS	Nil	

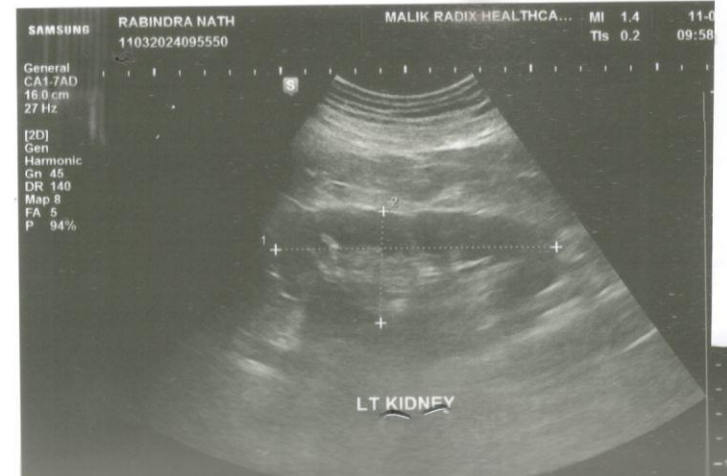
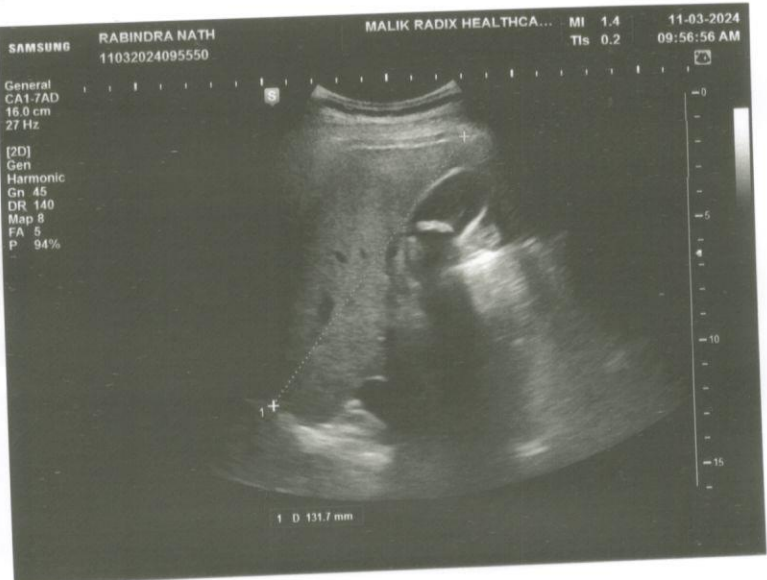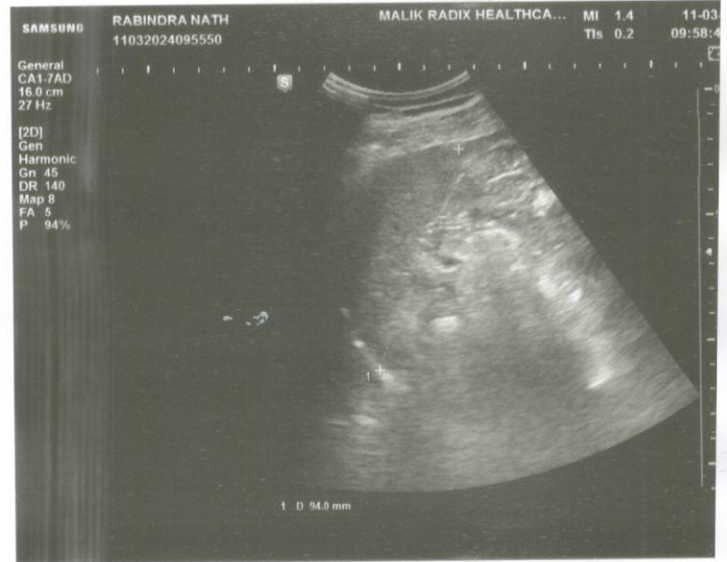
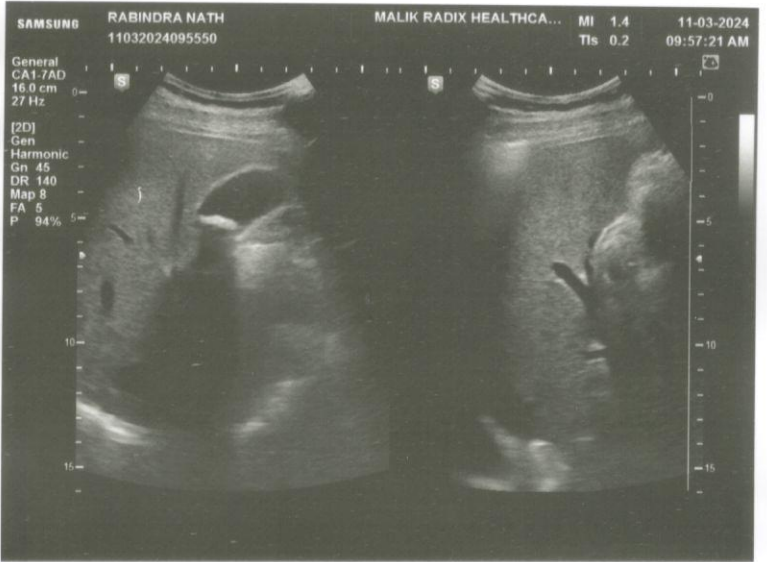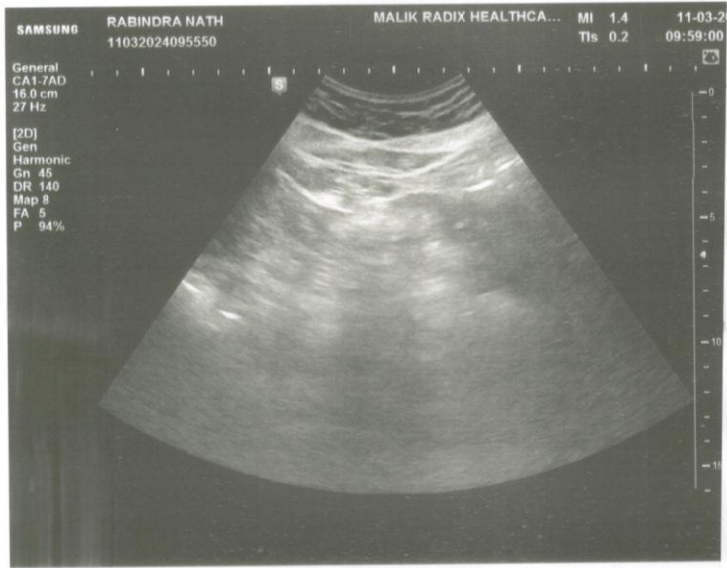
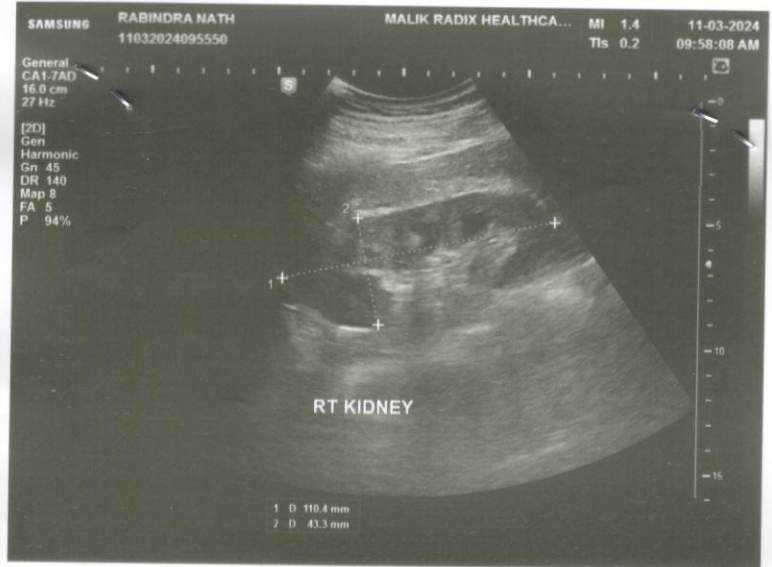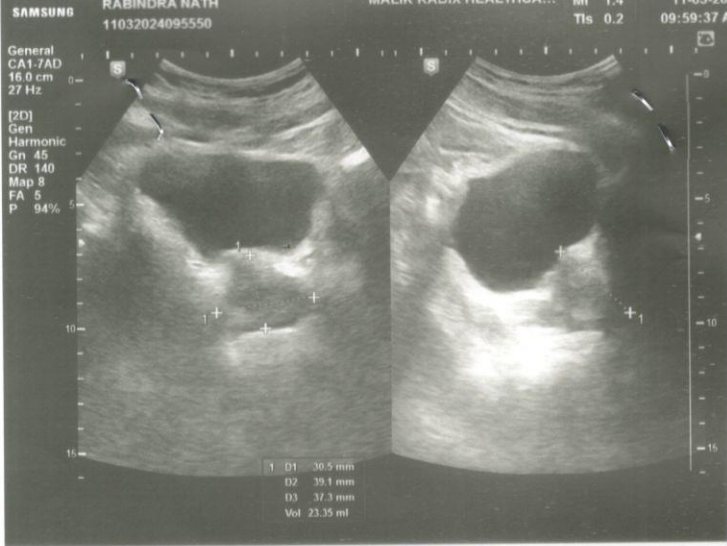DR. MEENU AGGARWAL
M.B.B.S, MD (Path.)

Dr. Reema Dahiya
Dr. REEMA DAHIYA
M.B.B.S, MD (Path.)
Checked by: _____
Page 4 of 4
C-217, C-218, Nirman Vihar
Delhi-92

If test results are alarming or unexpected, patient is advised to contact the laboratory immediately for possible remedial action.

Facilities Available

- Multispeciality Hospital - 24 Hours Emergency - X-Ray/ ECG/ Ultrasound/ CT Scan - Dental- Fully Equipped Operation Theatre
- Fully Functional Lab - 24/7 Casualty/ ICU-Nursery 24/7 Pharmacy - Labour Room - All Speciality OPD - Laproscopic Surgery - ECHO - Plastic Surgery





NAME	MR. RABINDRA NATH	AGE	51 YRS/M
REFD. BY.	HEALTH CHCEK UP	DATE	11.03.24

Ultrasound Examination of Whole Abdomen & Pelvis:

Liver: Liver appears normal in size (13.1 cm) with normal outlines and shows normal parenchymal echotexture. No focal SOL is seen in liver. IHBR & portal radicles are normal.

Gallbladder: Gallbladder is well distended. Gb shows multiple calculi , largest measuring 16.5 mm . Common bile duct is normal in course & caliber.

Pancreas: Pancreas retroperitoneum obscured by bowel gasses.

Spleen: Spleen shows normal size (9.4cm), outline & echotexture.

Kidneys: Kidneys show normal size, shape, position & echotexture. No calculus/ hydronephrosis or SOL is seen in kidneys. Cortico- medullary differentiation and cortical thickness is normal on both sides.

Right kidney measures –11.0 x 4.3 cm

Left kidney measures –11.1 x 4.4 cm

Great abdominal vessels are normal.

No ascites seen.

No para-aortic lymph nodes seen.

Urinary bladder Urinary bladder is well distended. Walls and lumen appear normal.

Prostate is normal in size (23.3cc) with normal outline and echotexture. No focal lesion is seen.

IMPRESSION:

Cholelithiasis


Dr Shreyash Tiwary MD (Rad- diag)

Regn. No. DMC 85802

RADIOLOGIST :

Facilities Available