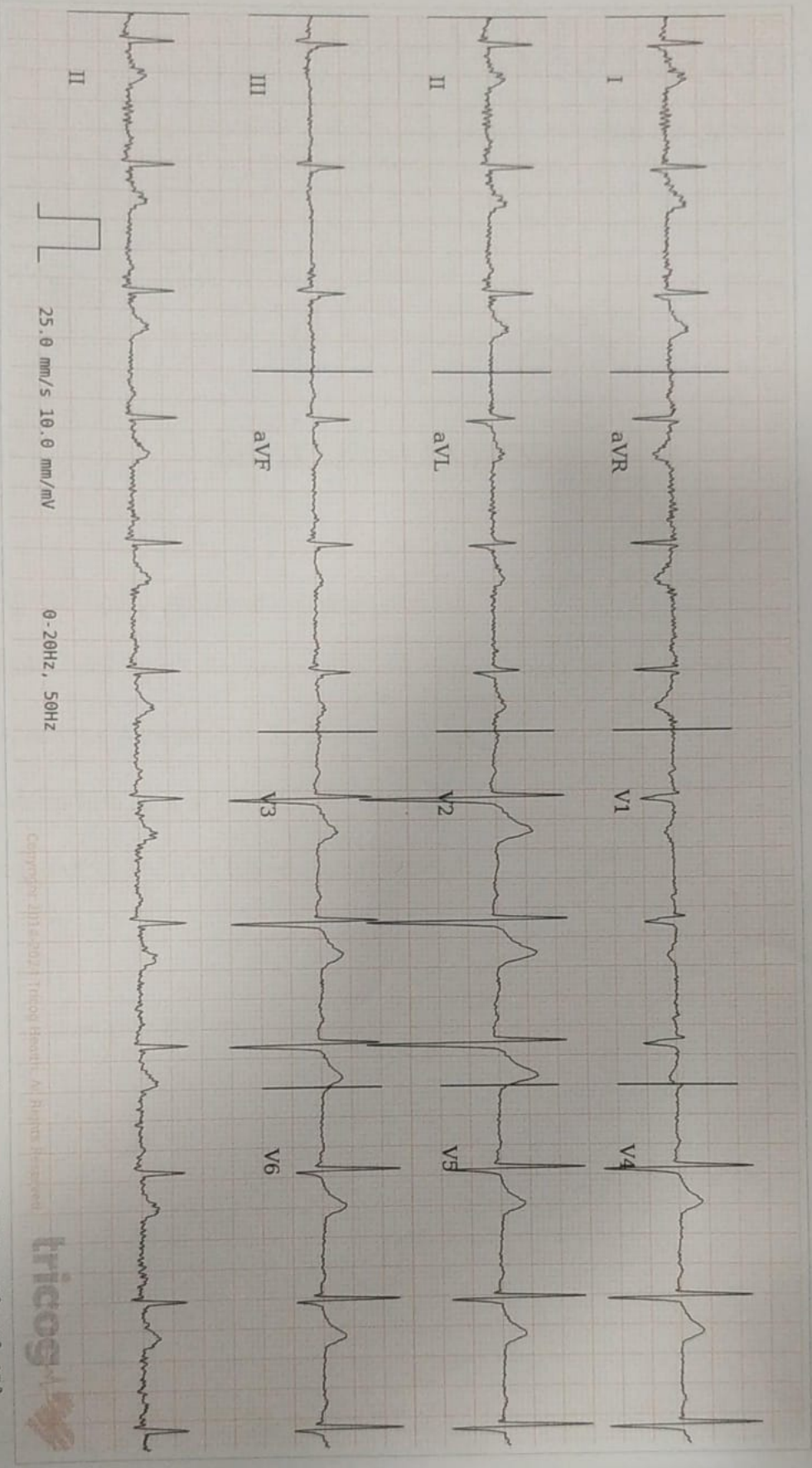




Lotus Diagnostic & Imaging Centre

Date and Time: 21st Mar 24 12:11 PM

Age / Gender: 34/Male
Patient ID: 1234
Patient Name: Manjeet



AR: 71bpm VR: 71bpm QRS: 90ms QT: 378ms QTcB: 411.19ms PRI: 170ms P-R-T: 42° 54° 27°

Sinus Rhythm. LVH by voltage noted. Please correlate clinically.





Lotus Diagnostic & Imaging Centre

A Unit of Lotus Diagnostic & Imaging Solution Pvt. Ltd.

HB से लेकर MRI तक एक ही छत के नीचे

PATIENT NAME: MANJEET
REF. BY: TPA

AGE/SEX: 34 YRS/M
DATE: MARCH 21, 2024

X-RAY CHEST PA VIEW

- Bilateral lung parenchyma appears normal.
- Bilateral domes of diaphragm and costophrenic angles are normal.
- Cardiac and mediastinal shadow appear normal.
- Bilateral hila appear normal.
- Bony thorax and soft tissue appear normal.

Advised: Clinical correlation

Dr. Rambaksh Sharma
Consultant Radiologist

Dr. Anshul Jain
Consultant Radiologist

Dr. Rajesh Reddu
MBBS, DMRD
Consultant Radiologist

Dr. Amit Verma
Echocardiography Specialist

Dr. Sonam Aneja
Consultant Pathologist



Lotus Diagnostic & Imaging Centre

A Unit of Lotus Diagnostic & Imaging Solution Pvt. Ltd.

HB से लेकर MRI तक एक ही छत के नीचे

PATIENT NAME: MANJEET
REF. BY: TPA

AGE/SEX: 34 YRS/M
DATE: MARCH 21, 2024

USG WHOLE ABDOMEN

Liver: measures 16.6 cm and shows fatty changes. No focal area of altered echogenicity is seen. IHBR not dilated. CBD is normal in diameter.

GB: is normal, Wall thickness is normal.

Pancreas: head and body shows normal size and parenchymal attenuation.

Spleen: normal in size (10.9 cm) and normal echotexture.

Right Kidney: shows calculus of size 5.4 mm at lower pole. is normal in position, size and morphology. Pelvi calyceal system is normal. CMD is maintained.

Left Kidney: is normal in position, size and morphology. No evidence of any calculus detected. Pelvi calyceal system is normal. CMD is maintained.

Urinary Bladder: appears normal.


Prostate: normal in size and echotexture.

No obvious abnormal bowel dilatation or wall thickening is seen in present scan.

No free fluid seen.

IMPRESSION: - Hepatomegaly with fatty changes in liver, Right renal calculus.

Clinical correlation and further evaluation is suggested.


Dr. Ram Baksh Sharma
Radiologist

Dr. Rambaksh Sharma
Consultant Radiologist

Dr. Anshul Jain
Consultant Radiologist

Dr. Rajesh Reddu
MBBS, DMRD
Consultant Radiologist

Dr. Amit Verma
Echocardiography Specialist

Dr. Sonam Aneja
Consultant Pathologist