



భారత ప్రభుత్వం
GOVERNMENT OF INDIA




కారంచెట్టి సుధా రాణి

Karamchetti Sudha Rani

పుట్టిన తేదీ/ DOB: 03/04/1987

స్త్రీ / FEMALE

2113 8381 0622



ఆధార్ - సామాన్యుని హక్కు



భారత విశిష్ట గుర్తింపు ప్రాధికార సంస్థ

Unique Identification Authority of India

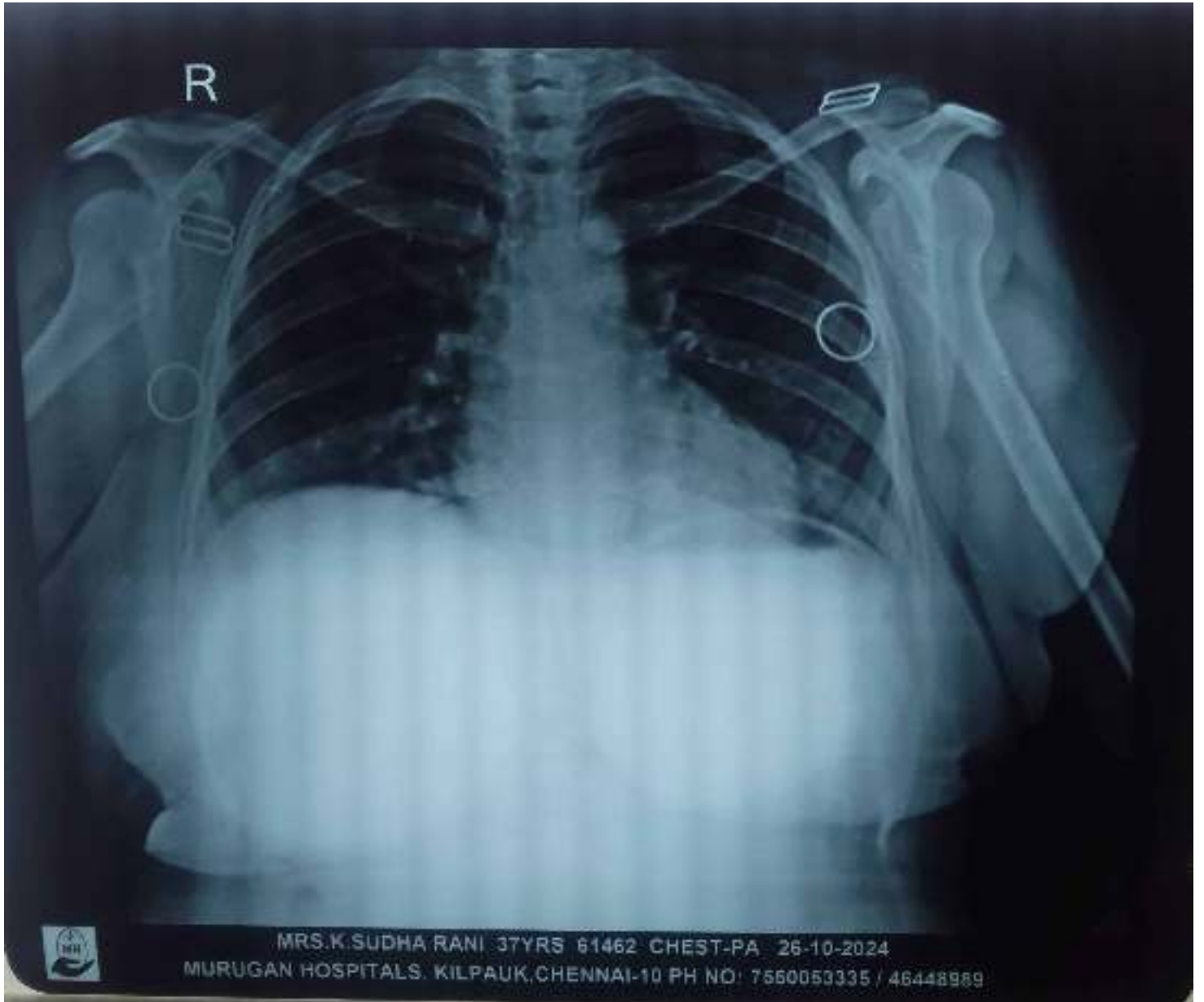
చిరునామా:

W/O కిశోర్ బాబు, 2-230,
లింగంగుంట్ల, లింగంగుంట్ల,
లింగంగుంట్ల, గుంటూరు,
ఆంధ్ర ప్రదేశ్ - 522402

Address:

W/O Kishore Babu, 2-230,
Lingamgunta, Lingamgunta,
Lingamgunta, Guntur,
Andhra Pradesh - 522402

2113 8381 0622



MRS.K.SUDHA RANI 37YRS 61462 CHEST-PA 26-10-2024
MURUGAN HOSPITALS, KILPAUK, CHENNAI-10 PH NO: 7550053335 / 46448989



SCAN REPORT

| | | | |
|------------|---------------------|------------|-----------------|
| NAME | : MRS. K.SUDHA RANI | PATIENT ID | : MH20240061462 |
| AGE/SEX | : 37-Years / Female | IP / OP NO | : OP21100683 |
| CONSULTANT | : DR. ARUN PRAKASH | DATE | : 26/10/2024 |

ULTRA SOUND SCAN OF ABDOMEN

LIVER: Normal in size and measures- 12.4 cm and normal in echotexture. No focal lesions are seen. No dilatation of intra-hepatic biliary radicals present. Hepatic veins and IVC appear normal. Portal vein is normal in caliber. Common bile duct is normal in caliber.

GALL BLADDER: Contracted

PANCREAS: Head and body normal tail, obscured by bowel gas.

PARA AORTIC AREAS: Aorta and IVC appear normal. No evidence of para aortic lymphadenopathy.

SPLEEN: Normal in size. Normal in echotexture. No evidence of focal lesions.

RIGHT KIDNEY: Measures 9.3 x 5.0 cm and is normal in size and echotexture. Cortico medullary differentiation is well maintained. There is no hydronephrosis or mass.

LEFT KIDNEY: Measures 8.4 x 4.6 cm and is normal in size and echotexture. Cortico medullary differentiation is well maintained. There is no calculus or hydronephrosis or mass.

Healing Hearts and Lives

URINARY BLADDER: Minimally distended

UTERUS AND OVARIES: Could not be assessed due to minimally distended bladder.

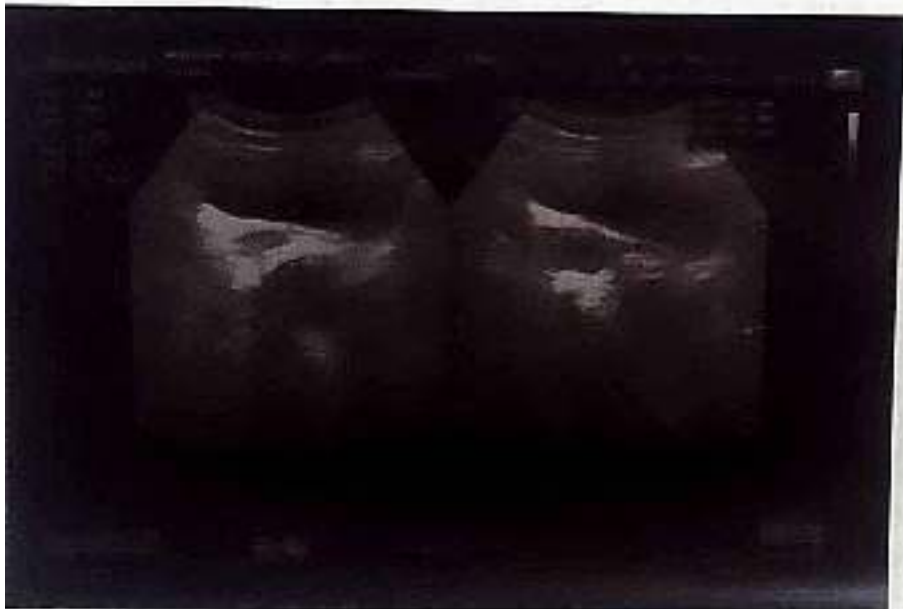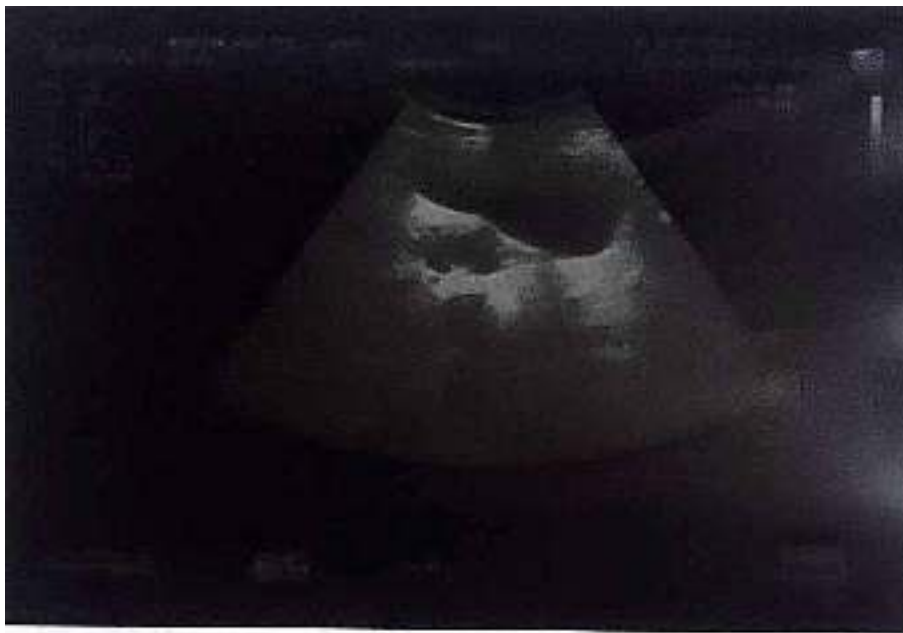No ascites present. No retroperitoneal lymphadenopathy present.

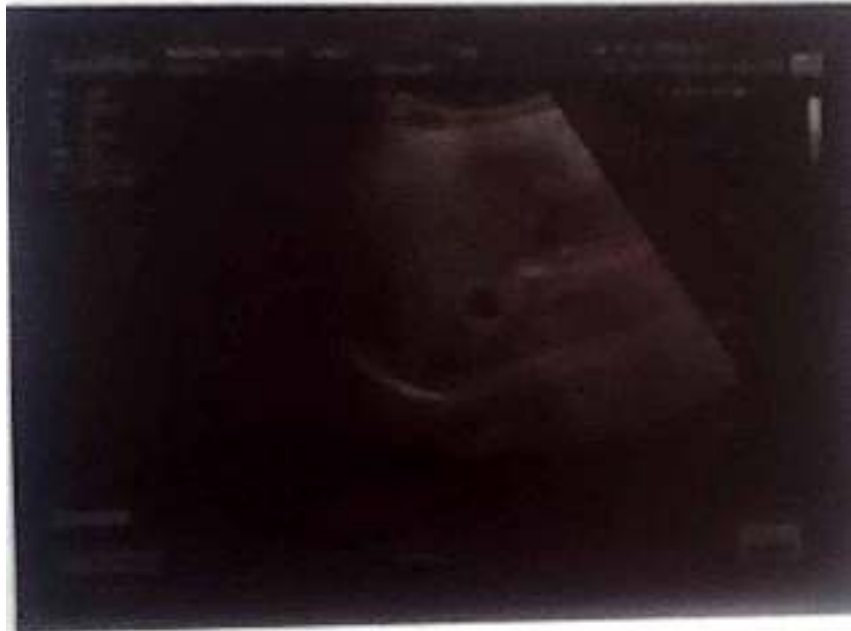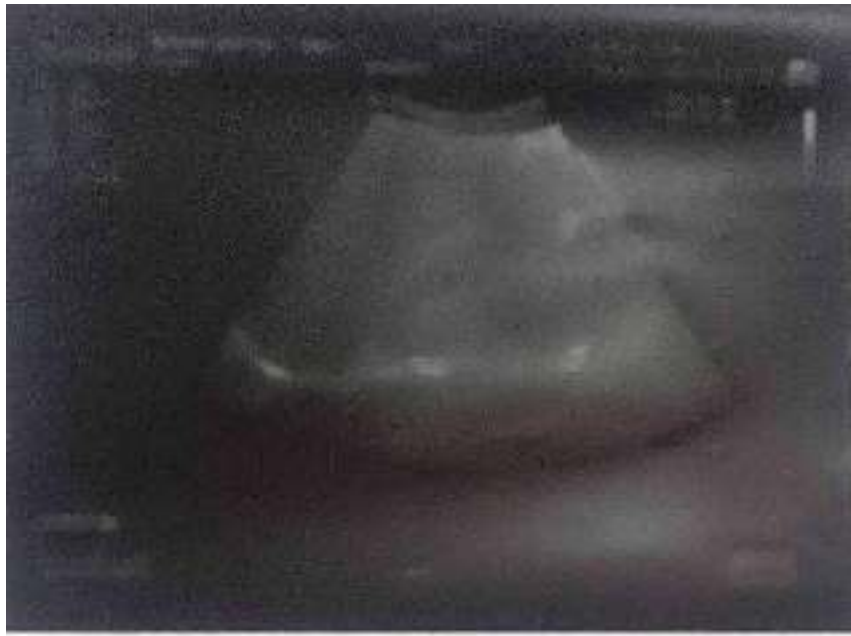
IMPRESSION:

No significant abnormality detected in the visualized abdominal organs.



CONSULTANT RADIOLOGIST,







ECHO CARDIOGRAM REPORT

NAME : MRS. K.SUDHA RANI PATIENT ID : MH20240061462
AGE/SEX : 37-Years / Female IP / OP NO : OP21100683
CONSULTANT: DR. ARUN PRAKASH DATE : 26/10/2024

2D PLAX (mm)

RV - 24 mm
AO - 34 mm
LA - 24 mm

M-Mode (mm)

IVS - 09 mm
PW - 10 mm
LVD - 42 mm
LVS - 26 mm
EF - 67 %
FS - 37 %

IMPRESSION:

No RWMA
Normal biventricular function
No pulmonary hypertension
No pericardial effusion
No clot/ Vegetation.

COLOR DOPPLER

Normal

DOPPLER (m/sec)

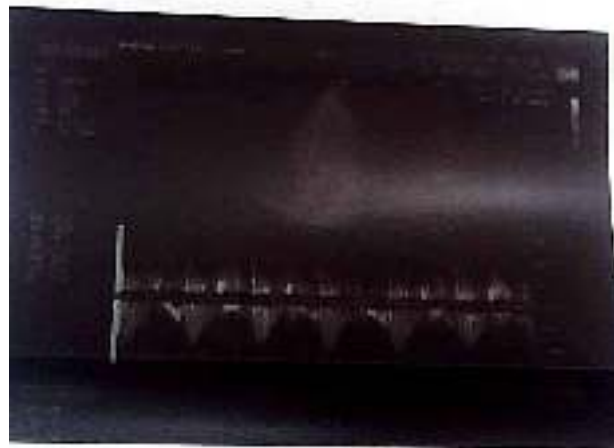
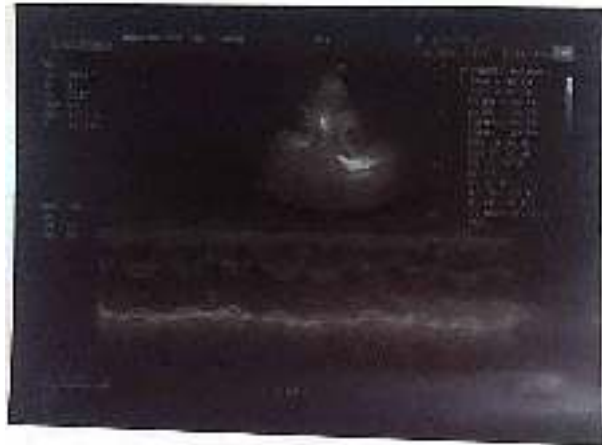MITRAL E - 0.8 m/s
MITRAL A - 0.4 m/s
PULMONARY - 0.9 m/s
AORTIC - 1.2 m/s
TRICUSPID - 0.4 m/s

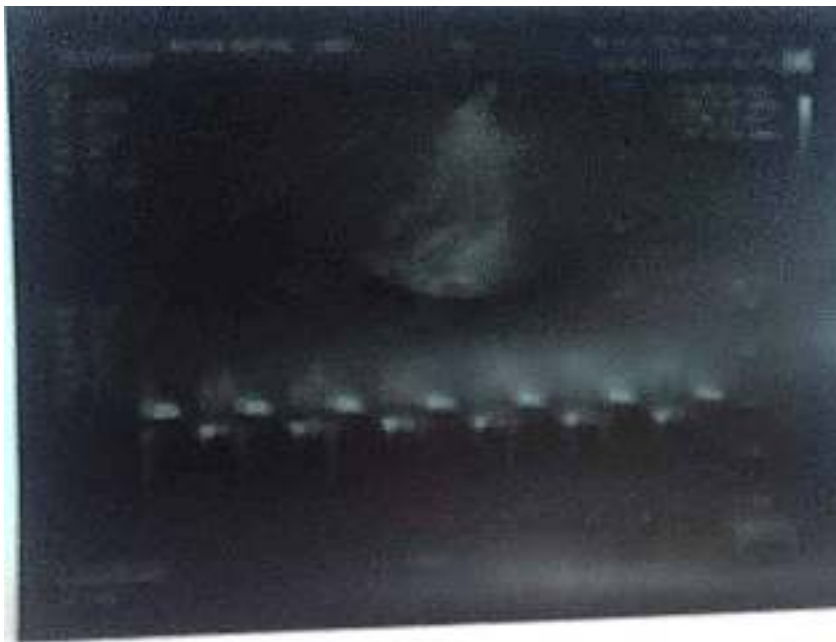

CONSULTANT CARDIOLOGIST

Healing Hearts and Lives

264/125, Kilpauk Garden Road, Kilpauk, Chennai - 600 010.
Phone : +91 44 4644 8989 / 75500 53335 | Email : muruganhosp@gmail.com
Website : www.muruganhospitals.in





Sex:
 Divisions:
 HR: 101bpm
 P Dur PR int 101 155ms
 QRS Dur 102ms
 QT QTc int 334 433 ms
 P QRS T axis 51 13 157

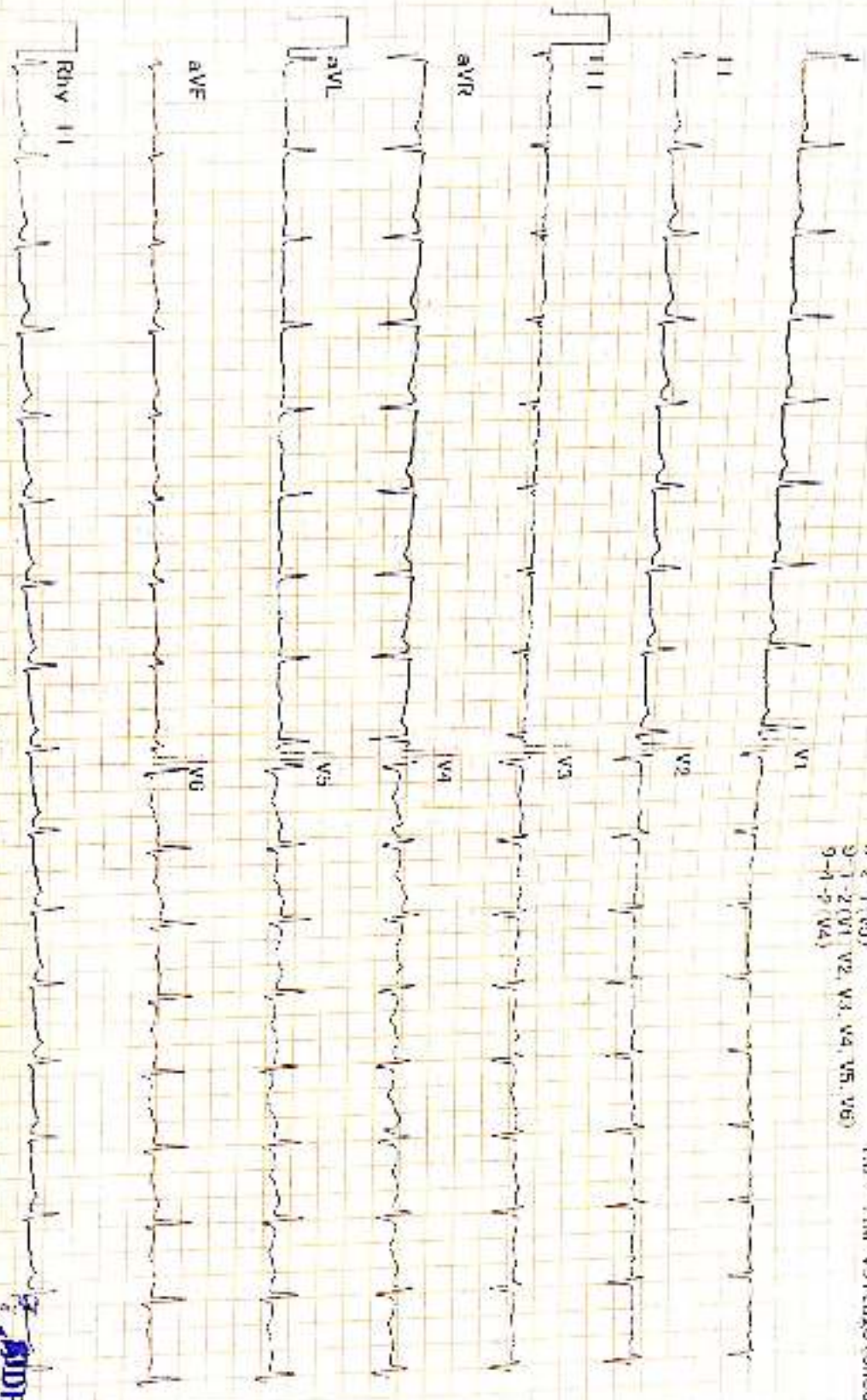
Age: 2024-10-26 11:23
 HT:
 Bed No.
 RWB SV1 amp 0.53uV
 RWS SV1 amp 0.43uV
 RV6 SV1 amp 0.571mV
 RV6 SV2 amp 0.577uV
 0.536mV

Height:
 Weight:
 Hospital No.
 cm
 kg

Mimnerda Code
 4-5-011 (aVL)
 5-2-1 (V5)
 2-1-2 (V1 V2 V3 V4 V5 V6)
 9-4-2 (V4)

Hospital:

Diagnosis Info
 812: Sinus Tachycardia
 671: Negative T(V5)
 152: Low Voltage (Obest Leads)



Diagnosis for reference, ask your doctor to confirm
 AUTO PRINT 6X2+1R 101bpm 10 mm/mV 0.50Hz-25Hz AO 50Hz 25 mm/sec Confirmed by





MURUGAN HOSPITALS

HEALING HANDS



LAB REPORT

Patient Name : Mrs. K.SUDHA RANI
Age / Gender : 37-Years / Female
UHID ID : MH20240061462
Doctor Name : Dr. ARUN PRAKASH

OP Report No. : INVA2117758
Bill No. : INV2407714
Sample Date : 26/10/2024 - 09:30 AM
Report Date : 26/10/2024 - 04:05 PM

| Test Name | Result | Units | Reference Interval |
|-----------|--------|-------|--------------------|
|-----------|--------|-------|--------------------|

HAEMATOLOGY

COMPLETE BLOOD CELL COUNT(CBC)

| | | | |
|----------------------------|----------------|----------------------|--|
| HAEMOGLOBIN | <u>8.1</u> | gms/dl | male :13.0 - 17.0 female :12.0 - 15.0 |
| PACKED CELL VOLUME | <u>27.4</u> | % | male : 40 - 50 female : 36 - 46 |
| RBC COUNT | 4.11 | millions cells/cu.mm | female: 3.8 - 4.8 male : 4.5 - 5.5 |
| TOTAL WBC | 6,940 | Cells/Cumm | 4,000 - 11,000 |
| Differential Count | | | |
| NEUTROPHILS | 58.7 | % | 40 - 65 |
| LYMPHOCYTES | 36.1 | % | 30-50 |
| EOSINOPHILS | <u>0.5</u> | % | 01-06 |
| MONOCYTES | 4.7 | % | 1-10 |
| BASOPHILS | 00 | % | 0-2 |
| ESR 60 MTS | 19 | mm | 5 - 20 |
| PLATELET COUNT | 2.84 | Lakhs/cumm | 1.5 - 4.5 |
| MCV | <u>66.6</u> | fL | 76 - 96 |
| MCH | <u>19.6</u> | pg | 27 - 32 |
| MCHC | <u>29.4</u> | gms/dl | 30 - 36 |
| BLOOD GROUPING & RH TYPING | " B " POSITIVE | | |

Page 1 of 4

Healing Hearts and Lives

264/125, Kilpauk Garden Road, Kilpauk, Chennai - 600 010.
Phone : +91 44 4644 8989 / 75500 53335 | Email : muruganhosp@gmail.com
Website : www.muruganhospitals.in



LAB REPORT

Patient Name : Mrs. K.SUDHA RANI
Age / Gender : 37-Years / Female
UHID ID : MH20240061462
Doctor Name : Dr. ARUN PRAKASH

OP Report No. : INVA2117758
Bill No. : INV2407714
Sample Date : 26/10/2024 - 09:30 AM
Report Date : 26/10/2024 - 04:05 PM

| Test Name | Result | Units | Reference Interval |
|-----------|--------|-------|--------------------|
|-----------|--------|-------|--------------------|

BIO CHEMISTRY

| | | | |
|---------------------------|-----|--------|----------------------------------|
| BLOOD SUGAR FASTING | 83 | mgs/dl | 70-110 |
| BLOOD SUGAR POST PRANDIAL | 108 | mgs/dl | 80- 160 |
| SERUM CREATININE | 0.7 | mg/dl | 0.6-1.4 |
| SERUM URIC ACID | 2.7 | mg/dl | male 3.1-7.0 , female 2.5-5.6 |
| LIPID PROFILE | | | |
| TOTALCHOLESTEROL | 148 | mg/dl | < 200 |
| TRIGLYCERIDE | 106 | mg/dl | < 150 |
| HDL | 41 | mg/dl | 35 - 80 |
| VLDL | 21 | mg/dl | 2 to 30 |
| LDL | 86 | mg/dl | <130 |
| CHOLESTEROL/ HDL RATIO | 3.6 | mg/dl | |



LAB REPORT

Patient Name : Mrs. K.SUDHA RANI
 Age / Gender : 37-Years / Female
 UHID ID : MH20240061462
 Doctor Name : Dr. ARUN PRAKASH

OP Report No. : INVA2117758
 Bill No. : INV2407714
 Sample Date : 26/10/2024 - 09:30 AM
 Report Date : 26/10/2024 - 04:05 PM

| Test Name | Result | Units | Reference Interval |
|----------------------------|--------|-------|--|
| LIVER FUNCTION TEST | | | |
| BILLIRUBIN(TOTAL) | 0.4 | mg/dl | 0.0 -1.0 |
| BILLIRUBIN(DIRECT) | 0.2 | mg/dl | 0.1- 0.30 |
| BILLIRUBIN(INDIRECT) | 0.2 | mg/dl | 0.2-0.8 |
| SGOT | 16 | IU/L | 0-38 |
| SGPT | 17 | IU/L | 0.0-40 |
| ALKALINE PHOSPHATASE | 94 | IU/L | 40-140 |
| | | | 4-6Years 93-309 |
| | | | 13-15Years 74-390 |
| TOTAL PROTEIN | 7.8 | gm/dl | 6.6-8.7 |
| ALBUMIN | 4.0 | gm/dl | 3.5 - 5.5 |
| GLOBULIN | 3.8 | gm/dl | 2.0-3.5 |
| AG RATIO | 1.0 | | |
| GAMMA G T | 11.4 | U/L | < 55 U/L |
| BLOOD UREA NITROGEN | 7.6 | mg/dl | 7-21 |
| HBA1C | 5.6 | % | normal: <6.0 good control: 6.1-7.0 fair control: 7.1- 8.0 poor control:8.1 -10.0 unsatisfactory: >10.0 |



MURUGAN HOSPITALS

HEALING HANDS



LAB REPORT

Patient Name : Mrs. K.SUDHA RANI
 Age / Gender : 37-Years / Female
 UHID ID : MH20240061462
 Doctor Name : Dr. ARUN PRAKASH

OP Report No. : INVA2117758
 Bill No. : INV2407714
 Sample Date : 26/10/2024 - 09:30 AM
 Report Date : 26/10/2024 - 04:05 PM

| Test Name | Result | Units | Reference Interval |
|-----------|--------|-------|--------------------|
|-----------|--------|-------|--------------------|

CLINICAL PATHOLOGY

| | | | |
|----------------------|-------------|-------|--|
| URINE SUGAR (F) | NIL | | |
| URINE SUGAR (PP) | NIL | | |
| URINE ROUTINE | | | |
| COLOUR | PALE YELLOW | | |
| APPEARANCE | CLEAR | | |
| REACTION | ACIDIC | | |
| SUGAR | NIL | | |
| ALBUMIN | NIL | | |
| DEPOSITES | | | |
| PUS CELLS | 3 - 4 | / HPF | |
| EPI CELLS | 1 - 2 | / HPF | |
| RBC COUNT | NIL | / HPF | |
| CAST | NIL | | |
| CRYSTALS | NIL | | |
| OTHERS | NIL | | |

KAVIYARASAN
 Verified by

*** End of Report ***

Authorized Signature

Healing Hearts and Lives

264/125, Kilpauk Garden Road, Kilpauk, Chennai - 600 010.
 Phone : +91 44 4644 8989 / 75500 53335 | Email : muruganhosp@gmail.com
 Website : www.muruganhospitals.in



MURUGAN HOSPITALS

HEALING HANDS



LAB REPORT

Patient Name : Mrs. K.SUDHA RANI
Age / Gender : 37-Years / Female
UHID ID : MH20240061462
Doctor Name : Dr. ARUN PRAKASH

OP Report No. : INVA2117758
Bill No. : INV2407714
Sample Date : 26/10/2024 - 09:30 AM
Report Date : 26/10/2024 - 11:50 PM

| Test Name | Result | Units | Reference Interval |
|-----------|--------|-------|--------------------|
|-----------|--------|-------|--------------------|

ENDOCRINOLOGY

| | | | |
|-----|--------|--------|--------------------|
| T3 | 0.893 | ng/ml | 0.52-1.85 |
| T4 | 10.608 | ug/dl | 5.0 -13.0 ug/dl |
| TSH | 3.712 | uIU/ml | 0.39 - 0.16 uiu/ml |

KAVIYARASAN

Verified by

*** End of Report ***



Healing Hearts and Lives



MURUGAN HOSPITALS

HEALING HANDS



NAME : MRS.K.SUDHA RANI
AGE / SEX : 37Y/FEMALE
CONSULTANT: DR.ARUN PRAKASH

UHID : MH202400601462
OP/IP : OP
DATE : 26.10.2024

CHEST XRAY PA VIEW

- Trachea is in midline.
- Hila appear Normal.
- Mediastinal shadow appears normal.
- Costophrenic&Cardiophrenic angles appear free.
- Cardiothoracic ratio is within normal limits.
- Lungs fields appear clear
- Bony thorax and soft tissue appear normal

IMPRESSION:

- No significant abnormality noted.

CONSULTANT RADIOLOGIST



264/125, Kilpauk Garden Road, Kilpauk, Chennai - 600 010.

☎ : +91 44 46448989 / 7550053335

email : muruganhospitals@gmail.com