


MS. JAHAN MEHAZ

30/F;

9098330033



Adw → ortho 

8/20202092

**Apollo Sage Hospital - Bhopal**

Regd No. NH/7272/Sept. 2022  
(A unit of S. R. Associates)

KH.No. 98/3-99-100, E-8 Arera Colony, Bhopal - 462026 (MP) India

+91 -755- 4308101

Emergency +91 -755- 3505050


info@apollosage.in


www.apollosage.in



Scan here to  
know us better

 ApolloSageHospitals

 apollosagehospital

 apollo-sage-hospital

Dr. Siddharth Malhotra

M.B.B.S., M.S. (Ophthalmology), F.I.A.C.R.I., Hyd. (Cornea & LASIK)

F.R.C.S. (Australia) (Ocular surface & Stem cells)

Fellow, S. Prasad Eye Institute, Hyderabad, Ex-Faculty ASGI Eye Group, Hyderabad

Consultant Ophthalmologist & Cornea Super-specialist

Corneo-refractive & Cornea transplant surgeon

Name: Mrs. Jahan Mehraz      Age/Sex: 30/ F

Date: 22/12/2023

Snellen	BCVA	Glasses	Pinhole
6/36			6/9
6/12			6/6

Eye	Sphere	Cylinder	Axis	BCVA
R	-1.50 D		—	6/9
L	-0.75 D	0.50	10°	6/6

-1.75 D SPH  
-1.25 / 0.50 X 30 D



Female

30 Years

22.12.20 11:20:10

Location:  
F m: ar:  
Order Nu. ar:  
Indication:  
Medication 1:  
Medication 2:  
Medication 3:

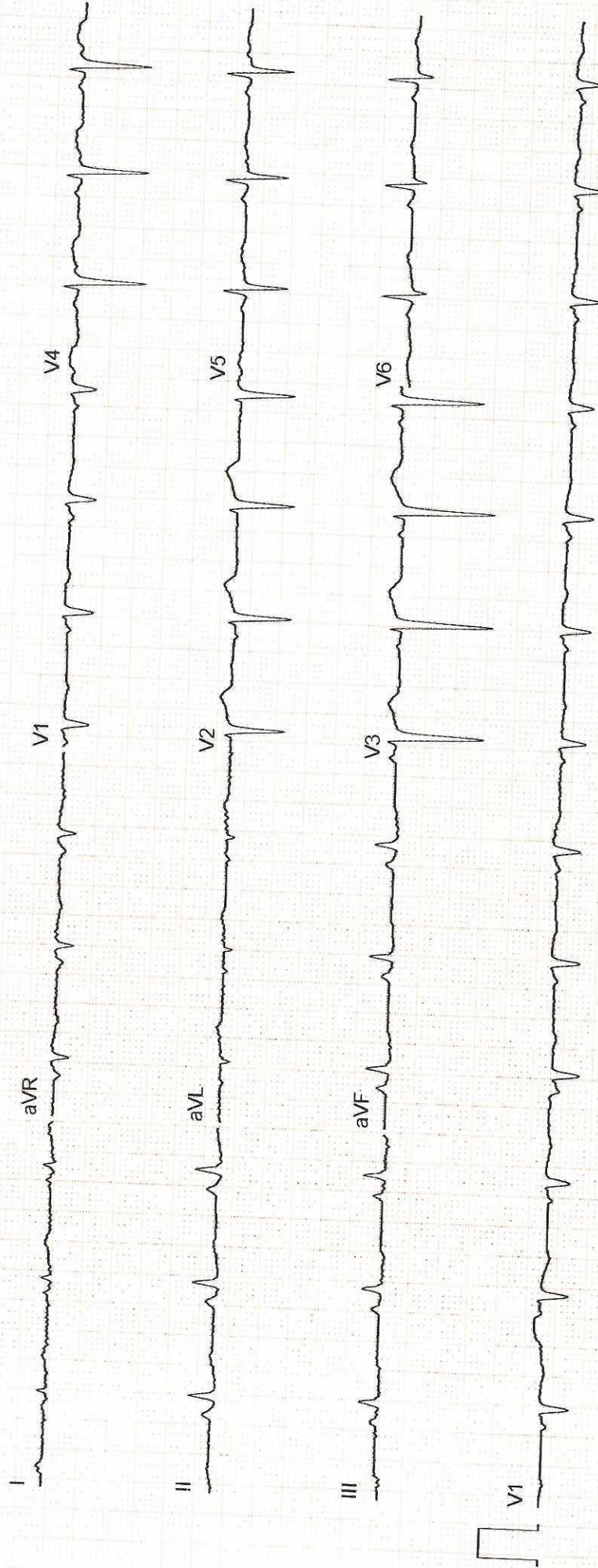
CE 0537 001 D 736

81 bpm  
--/-- mmHg

Normal sinus rhythm  
Normal ECG

QRS : 86 ms  
QT / QTcBaz : 376 / 436 ms  
PR : 128 ms  
P : 98 ms  
RR / PP : 742 / 740 ms  
P / QRS / T : 68 / 82 / 19 degrees

Technician:  
Ordering Ph:  
Referring Ph:  
Attending Ph:





APOLLO SAGE HOSPITAL  
BAWADIYAN KALAN  
BHOPAL

Station  
Telephone:

**EXERCISE STRESS TEST REPORT**

Patient Name: MEHNAZ, JAHAN  
Patient ID: HC-25160  
Height: 169 cm  
Weight: 67.1 kg

DOB: 11.06.1993  
Age: 30 yrs  
Gender: Female  
Race: Indian

Study Date: 22.12.2023  
Test Type: Treadmill Stress Test  
Protocol: BRUCE

Referring Physician: --  
Attending Physician: Dr. Anurag Jain  
Technician: Radha Prajapati

Medications:  
--

Medical History:  
T2DM

Reason for Exercise Test:  
Screening for CAD

**Exercise Test Summary**

Phase Name	Stage Name	Time in Stage	Speed [ km/h ]	Grade [ % ]	HR [ bpm ]	BP [ mmHg ]	Comment
PRETEST	SUPINE	00:19	0.00	0.00	109	120/80	
	STANDING	00:16	0.00	0.00	108	120/80	
	HYPERV.	00:14	0.00	0.00	106	120/80	
	WARM-UP	00:12	1.60	0.00	107	120/80	
EXERCISE	STAGE 1	03:00	2.70	10.00	142	130/80	
	STAGE 2	01:57	4.00	12.00	162	140/80	
RECOVERY		03:04	0.00	0.00	113	120/80	

The patient exercised according to the BRUCE for 4:57 min:s, achieving a work level of Max. METS: 7.00. The resting heart rate of 113 bpm rose to a maximal heart rate of 164 bpm. This value represents 86 % of the maximal, age-predicted heart rate. The resting blood pressure of 120/80 mmHg, rose to a maximum blood pressure of 140/80 mmHg. The exercise test was stopped due to Target heart rate achieved.

**Interpretation**

Summary: Resting ECG: abnormal.  
Functional Capacity: normal.  
HR Response to Exercise: appropriate.  
BP Response to Exercise: normal resting BP - appropriate response.  
Chest Pain: none.  
Arrhythmias: none.  
ST Changes: none.  
Overall impression: Normal stress test.

**Conclusions**

-No ST-T changes Noted During Exercise & Recovery  
-Negative Stress Test

Physician  Technician \_\_\_\_\_

PRINTED IN USA

3



### ULTRA SONOGRAPHY ABDOMEN

Patient Name:	JAHAN MEHNAZ	Patient ID:	ASHB.0000025160
Age:	30 Years	Sex:	F
Accession Number:	17101.223009603	Modality:	US
Referring Physician:	Gopal Batni	Study:	ULTRASOUND - WHOLE ABDOMEN
Study Date:	22-Dec-2023		

**Liver:-** is normal in size and echotexture. Portal and hepatic venous system appears normal. Intra and extra hepatic biliary radicals are not dilated.

**Gall Bladder:-** The gallbladder is identified and is normal in size and shape. A small polypoidal lesion is noted in the gallbladder lumen measuring approximately 4mm in size. The polypoidal lesion is echogenic with smooth surface and appears to be arising from gallbladder wall. No shadowing or acoustic enhancement is noted posterior to the lesion. The gallbladder wall thickness is within normal limits.

**Pancreas** is normal in size outline and echopattern.

**Spleen** is normal in size and echopattern.

**Both kidneys** are normal in size, shape and echogenicity. Central pelvicalyceal sinus and corticomedullary ratio are normal.

Right kidney measures:- 11.3x3.7cm

Left kidney measures:- 10.7x4.5cm

No evidence of ascites is seen.

**Urinary bladder** is normal in shape and contour. Its wall is normal.

**Uterus and ovaries:-** are normal in size and echopattern. Cervix shows normal echopattern. No adnexal mass. No free fluid in POD.

Uterus measures:- 8.7x4.7x2.8cm. Endometrial thickness is 5mm.

Right ovary measures 3.7x1.9x2.3cm, volume- 8.6cc.

Left ovary measures 4.2x1.9x2.6cm, volume- 11cc. Left ovary shows dominant follicle measure ~ 15x14mm.

#### IMPRESSION:- Sonography Study Reveals:-

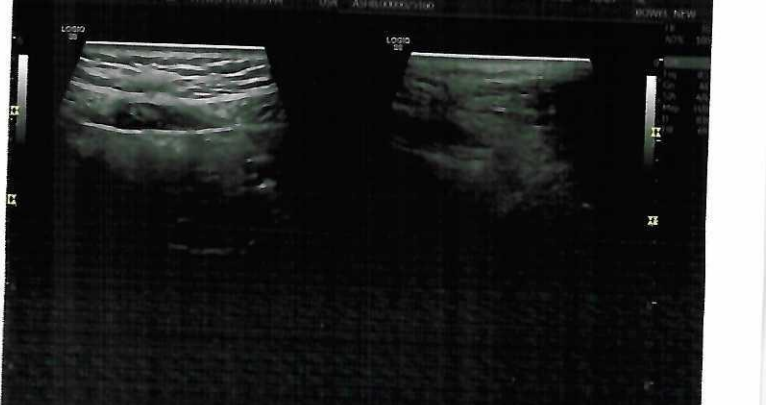
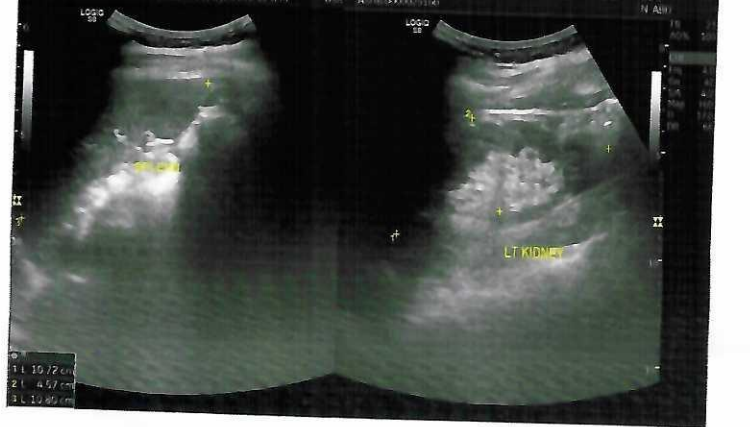
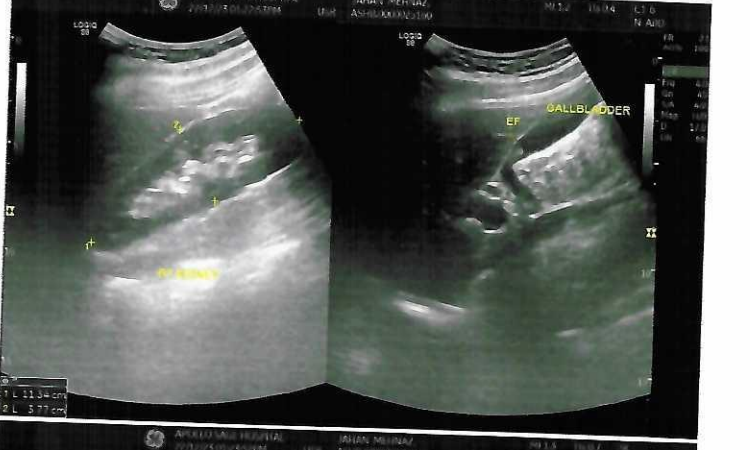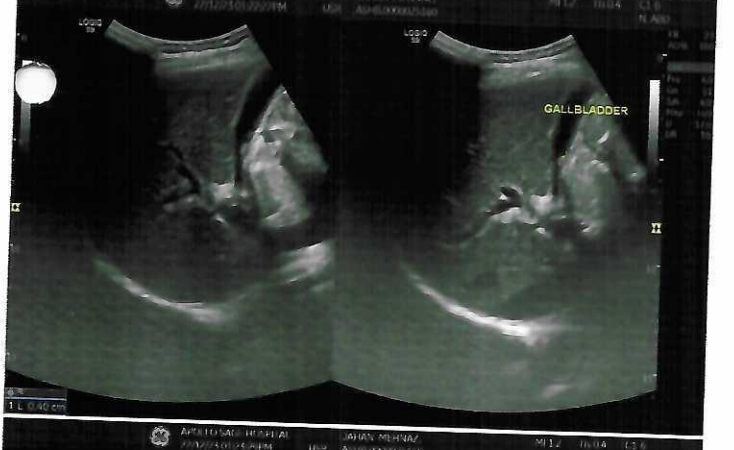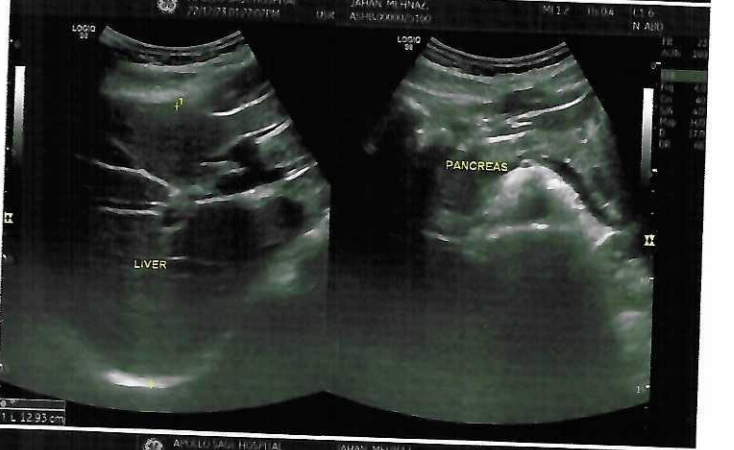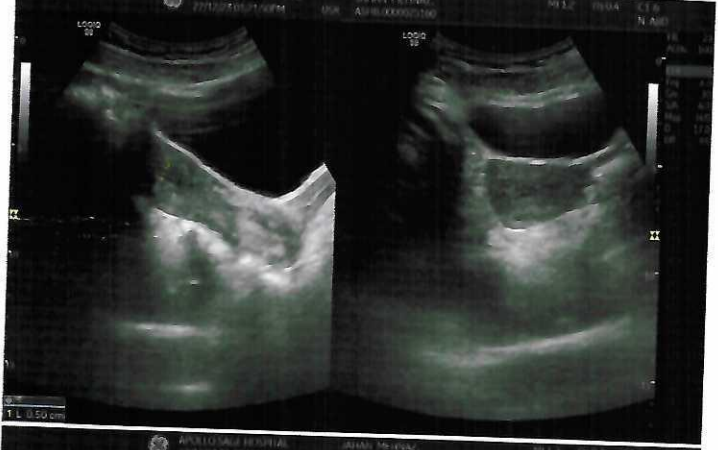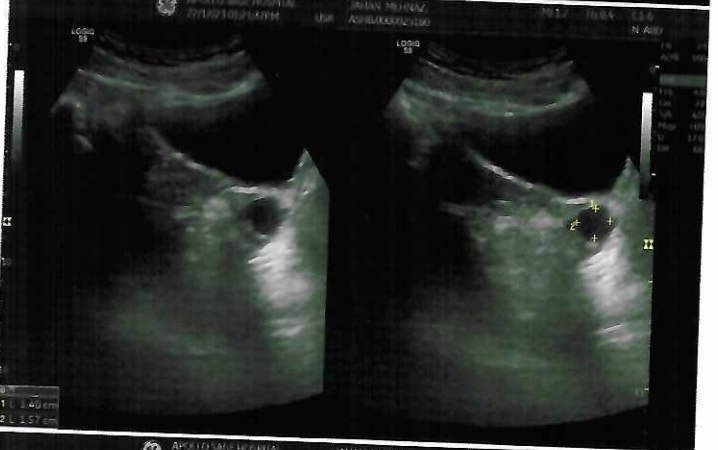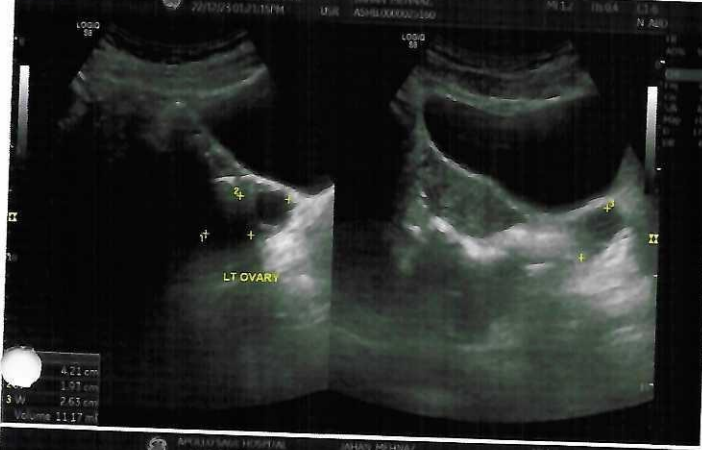
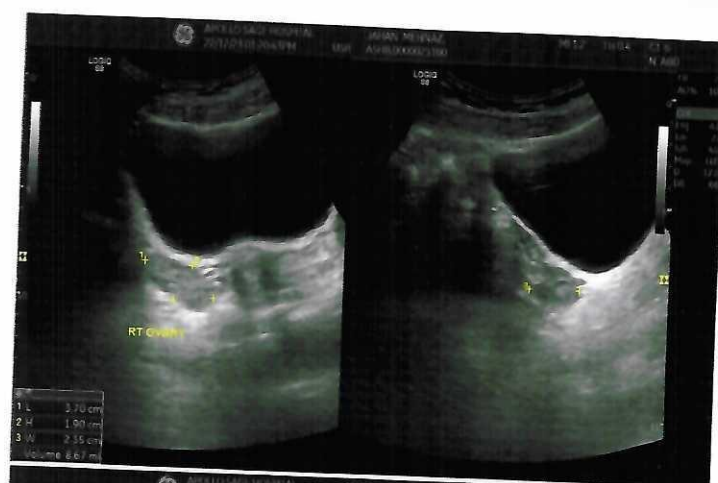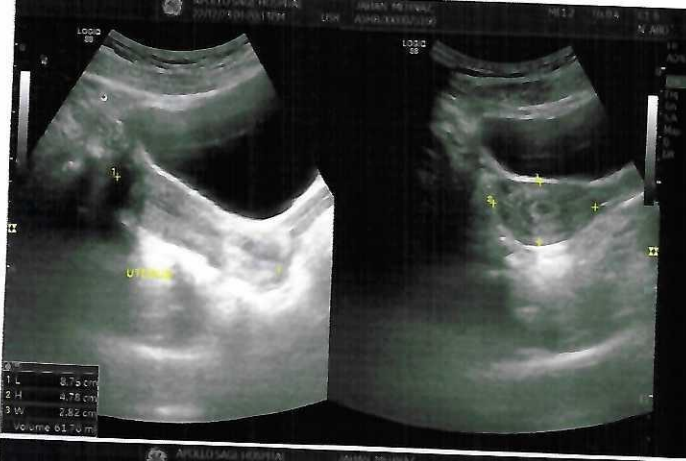- Small polypoidal lesion measuring 4mm is noted in the gallbladder lumen with features consistent with gallbladder polyp.

ADV:- Clinical Correlation.

*Nohitas*

DR. HARI SANTOSH  
CONSULTANT RADIOLOGIST







Patient Name:	JAHAN MEHNAZ	Patient ID:	ASHB.0000025160
Age:	30 Years	Sex:	F
Accession Number:	17101.123013755	Modality:	DX
Referring Physician:	Gopal Batni	Study:	CHEST
Study Date:	22-Dec-2023		

### X-RAY CHEST (PA VIEW)

Both lung fields are clear. No active pleural or parenchymal lesion is seen.

The hila, mediastinum, bony thoracic cage and the diaphragmatic domes are normal.

The costophrenic and cardiophrenic angles are clear.

The cardiac silhouette is unremarkable.

### IMP:- RADIOGRAPHIC IMAGE REVEALS:-

Normal findings are seen.

Thanks for Ref



DR. HARI SANTOSH  
CONSULTANT RADIOLOGIST

Date: 22-Dec-2023 12:52:47





# Out Patient Assessment Form

Apollo Hospital, Bhopal

Place Patient Label Here

MS. JAHAN MEH...

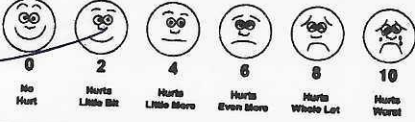If label Not Available, Write Pt. Name UHID No. IP  
No Age, Sex, Date, Name of Treating Physician

Date : 22/12/23

Time : 11:27 AM Consultant Name : HC

### Pain Assessment

### Nursing Assessment



Height 169 CM Weight : 67 kg Pulse : 96/m BP : 99/70  
Allergies (if any) No Falls risk : Yes  No   
Oral hygiene : Poor  Fair  Good

### Investigation Ordered

Sp2 - 99.1  
Bmi - 23.5

Chief complains past medical / surgical history. Diagnosis, Treatment Plan, Current Medications & Follow - up advice :

### Patient Education (Patient Is Briefed on Following) Cost May Vary In Course Of Disease

Proposed Care Plan Yes  No

Expected Outcome : Yes  No

Expected Cost : Yes  No

Admission Advice : Yes  No

Consultant Signature

Date :  
Time