

10-Feb-2024 PM12:34:27

ID: 23018113

Name: Mrs. Divya H

Sex: F cm kg Birth date: / mmHg

34 years

1100 Sinus rhyt_{ml}
1102 Sinus arrhythmia [RR int. change over 20%]
9110 ** normal ECG **

Indication:

Symptoms:

History:

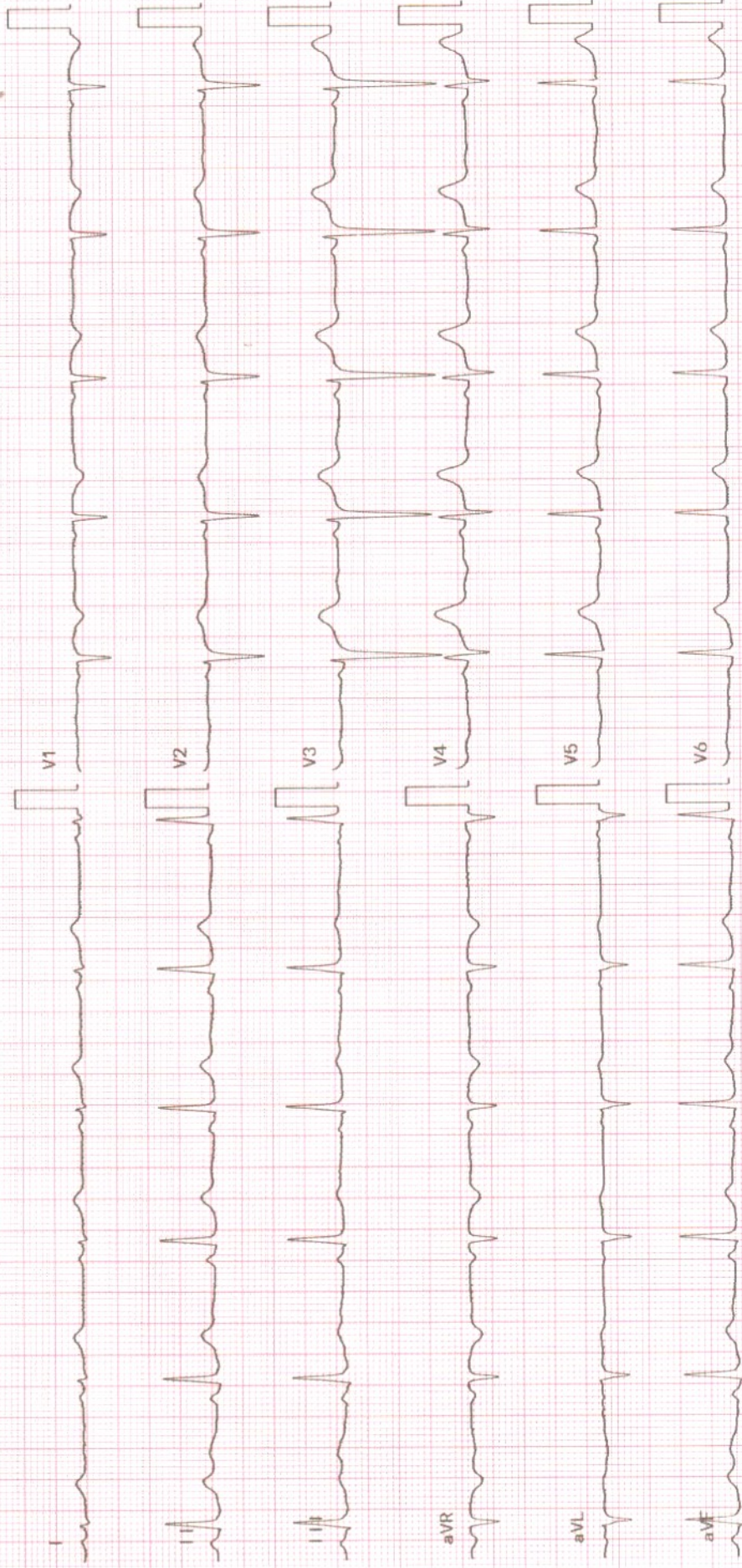
Heart rate 65 bpm
R int 132 ms
RS dur 84 ms
P/QTc(E) int 402/413 ms
V/ORS/T axis 50/86/51 °
V5/SV1 amp 0.96/0.58 mV
V5+SV1 amp 1.55 mV

Unconfirmed Report

Reviewed by:

10 mm/mV 25 mm/s Filter: H50 D 35 Hz

10 mm/mV



Patient name :	Mrs. DIVYA H	Date :	10/02/24
Age :	34 years GENDER: FEMALE	Patient ID :	18113
Ref by :	DR. CMO	OP/ IP :	HEALTH CHECKUP

2D- ECHOCARDIOGRAPHY

M - MODE AND DOPPLER MEASUREMENTS

(c.m)	(c.m)	(cm/sec)	
AO : 2.7 (2.5-3.7)	LVIDD : 3.5 (3.5-5.5)	MV EV : 86.2	AV : 71.4
LA : 2.7 (1.9-4.0)	LVIDS : 2.9 (2.4-4.2)	AV : 115	
RA : 2.2 (<4.4)	IVSD : 1.1 (0.6-1.1)	PV : 62.6	
RV : 1.9 (<3.5)	IVSS : 1.1 (0.9-1.2)	TV EV : ----	AV : ----
TAPSE: 1.7 (>1.6)	LVPWD : 1.1 (0.6-1.1)	Diastolic Function : NO LVDD	
	LVPWS : 1.1 (0.9-1.2)		
	EF : 60%		

DESCRIPTIVE FINDINGS

Left Ventricle	: NORMAL
Right Ventricle	: NORMAL
Left Atrium	: NORMAL
Right Atrium	: NORMAL
Wall motion analysis	: NO RWMA
Mitral Valve	: NORMAL, TRIVIAL MR
Aortic Valve	: NORMAL
Tricuspid Valve	: NORMAL, TRIVIAL TR, JET GRDT-10mmHg
Pulmonary Valve	: NORMAL
IAS	: INTACT
IVS	: INTACT
Pericardium	: NORMAL
Other Findings	: IVC NORMAL AND COLLAPSING

IMPRESSION:

NORMAL CHAMBER DIMENSIONS
 NORMAL LV SYSTOLIC FUNCTION EF : 60%
 NORMAL LV DIASTOLIC FUNCTION
 TRIVIAL MR/TR, JET GRDT-10mmHg
 NO PULMONARTERY HYPERTENSION
 NO REGIONAL WALL MOTION ABNORMALITIES
 NO CLOTS/ PERICARDIAL EFFUSION /VEGETATION

DR. RAHUL S PATIL
 CONSULTANT CARDIOLOGIST



NABH



NABL



No.1



UNITED HOSPITAL

Care Par Excellence
Jayanagar, Bangalore

Out Patient Record

Patient Name : Mrs.DIVYA H UHID : UHJA23018113
 Age / Sex : 34 Years / Female OP NO/Reg Dt : 10-02-2024 11:47 AM
 Spouse / Father Name : CHETAN KUMAR Department :
 Address : # 34/249,Maruhti Nagara Harishina Kunte Referred By :
 Nelamangala , BANGALORE CITY H O, Consultant : Dr.Preventive Health Check Up
 KMC No. :

Complaints / Findings / Observations :

for health check up

*Ht - 38.319
 Ht - 148cm
 PR - 70b/m
 SpO2 - 99%
 BP - 90/60*

Investigations:

Dr. Yoga Lakshmi SK
 MBBS, MS OBG, FRCOG, FRCR
 Consultant Obstetrics and
 Gynecologist, Endometriosis
 and IVF Specialist
 KMC Reg. No. 90384

Treatment / Care of Plan / Provisional Diagnosis :

*Sty faced
 Dated*

*ML - Gyn
 PIC
 All vms*

Follow Up Advice :

*no 4/ AM, happy Count - 1000000
 no 4/ on 4/24
 no 4/ any 4/24*

*cro - 4/24
 one soft*

*P/A - pt not with
 P/S -*

*Boat - 4/24
 Signature of the Doctor
 Dr. Yoga Lakshmi SK*

UNITED HOSPITAL (A Unit of United Brothers Healthcare Services Private Limited)

Sooooooooo



NABH



NABL



No.1



UNITED HOSPITAL

Care Par Excellence
Jayanagar, Bangalore

Out Patient Record

Patient Name : Mrs.DIVYA H

UHID : UHJA23018113

Age / Sex : 34 Years / Female

OP NO/Reg Dt : 10-02-2024 11:47 AM

Spouse / Father Name : CHETAN KUMAR

Department :

(Ophtho)

Address : # 34/249, Maruhti Nagara Harishina Kunte
Nelamangala , BANGALORE CITY H O,

Referred By :

Consultant : Dr.Preventive Health Check Up

KMC No. :

Complaints / Findings / Observations :

Routine Eye test

Investigations:

V/A < 6/60 (R)

A/R < 20

Treatment / Care of Plan / Provisional Diagnosis :

Further 20

Eye: Normal 50m cyc

Follow Up Advice :

yearly review

Signature of the Doctor

10/2/24

UNITED HOSPITAL (A Unit of United Brothers Healthcare Services Private Limited)

United Hospital

No.110 (30), Madhavan Park Circle, 10th Main Rd,
3rd Block Jayanagar, Bangalore - 560 011

T: 080 4566 6666

E: appointments@unitedhospital.in
W: www.unitedhospitals.com

DEPARTMENT OF RADIODIAGNOSIS

Name	Divya H	Date	10/02/24
Age	34 years	Hospital ID	UHJA23018113
Sex	Female	Ref.	Health check

ULTRASOUND ABDOMEN AND PELVIS

FINDINGS:

Liver is normal in size and echopattern. No intra or extra hepatic biliary duct dilatation. *There is a well defined hyperechoic lesion measuring 1.2 x 1.1 cms in segment VI.* Portal vein is normal in size, course and caliber. CBD is not dilated.

Gall bladder is normal without evidence of calculi, wall thickening or pericholecystic fluid.

Pancreas - Visualized part of the pancreatic head and body appears normal in size, contour and echogenicity. Rest of the pancreas is obscured by bowel gas.

Spleen is normal in size, shape, contour and echopattern. No evidence of mass or focal lesions.

Right Kidney is normal in size (9.0 x 2.4 cms), position, shape and echopattern. Corticomedullary differentiation is maintained. No evidence of calculi or hydronephrosis. *There is a simple cortical cyst measuring 10 mm in the upperpole region.*

Left Kidney is normal in size (9.0 x 3.8 cms), position, shape and echopattern. Corticomedullary differentiation is maintained. No evidence of calculi or hydronephrosis.

Retroperitoneum- Visualized aorta appeared normal. No obvious enlarged para-aortic nodes.

Urinary Bladder is well distended. Wall thickness is normal. No evidence of calculi, mass or mural lesion.

Uterus is anteverted and normal in size, measures 7.7 x 3.7 x 4.7 cms. Myometrial and endometrial echoes are normal. Endometrium measures 5.0 mm.

Right ovary is normal in size and echopattern, measures 1.8 cc.

Left ovary is normal in size and echopattern, measures 2.0 cc.

Both adnexa: Normal. No mass is seen.

There is no ascites or pleural effusion. Appendix could not be localized. No RIF probe tenderness.

IMPRESSION:

- Small hyperechoic lesion in the liver as mentioned above - likely hepatic hemangioma (Benign incidental finding).
- Right renal simple cortical cyst. Bosniak 1 – Benign.



Dr. Elluru Santosh Kumar
Consultant Radiologist

Please bring this report during your visit to the Hospital / ಆಸ್ಪತ್ರೆಗೆ ಬರುವಾಗ ಈ ರಿಪೋರ್ಟನ್ನು ತನ್ನಿ