



GPS Map Camera

**Balaghat, Madhya Pradesh, India**

R57P+5HH, MP SH 11, Chitragupt Nagar, Balaghat, Madhya Pradesh 481001, India

Lat 21.813051°

Long 80.186422°

10/02/24 01:18 PM GMT +05:30



Google

**PATHOLOGY REPORT**

• Auto Analyzer • Hematology Analyzer • A.B.G. • Computerized Lab

NAME : MR. RAJAT KUMAR      AGE : 37Yrs.      SEX : M  
 REF. BY : Dr. B. M. SHARNAGAT (M.D.)      DATE : 10/02/2023

**URINE ANALYSIS REPORT (By urometer120 analyzer)**

**PHYSICAL EXAMINATION**


Colour : pale Yellow  
 Quantity : 10ml  
 Apperance : clear

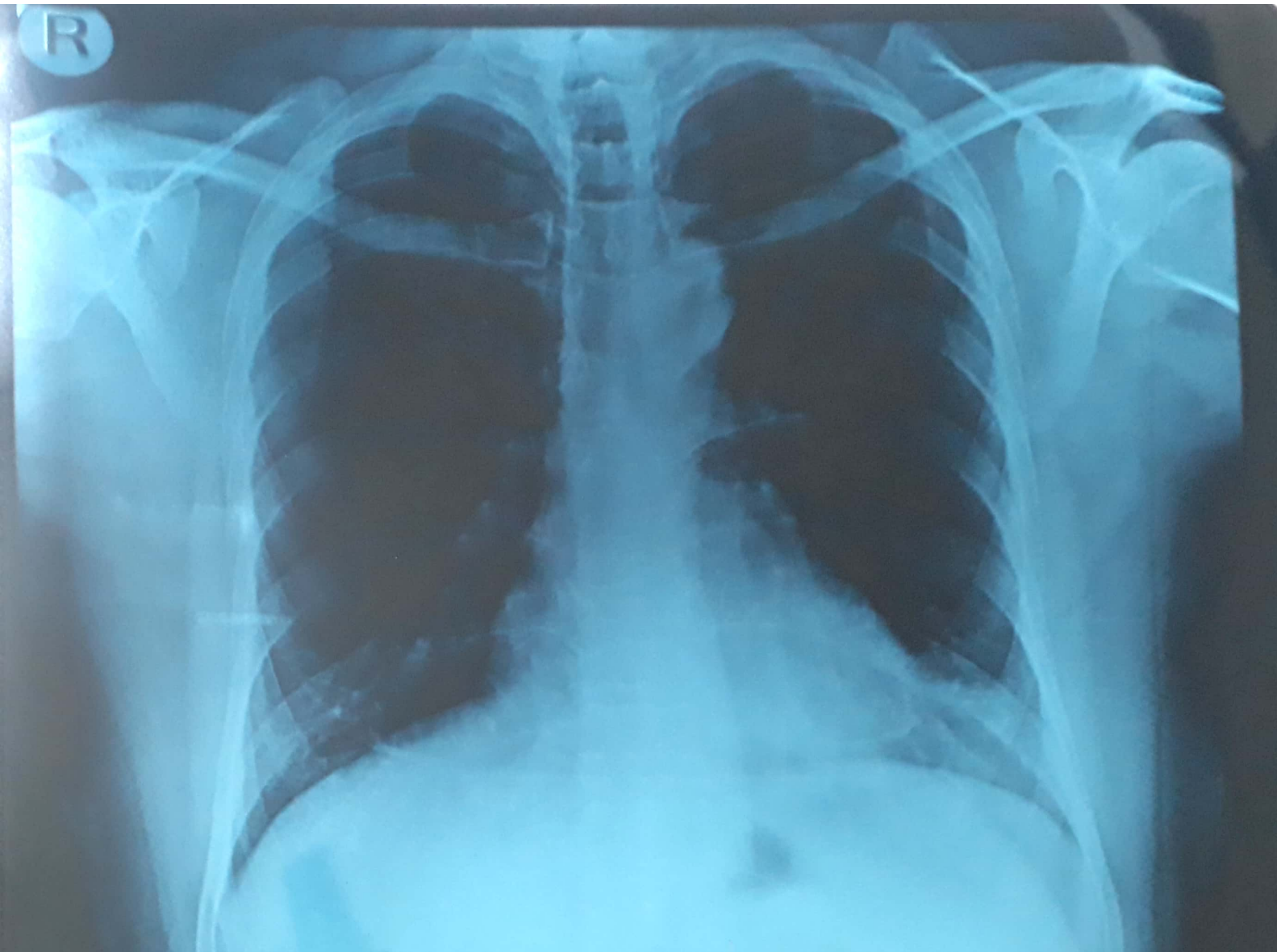
**CHEMICAL EXAMINATION**

Sugar : nil  
 Bile Pigment : nil  
 Nitrite : nil  
 Protein : nil  
 Bilirubin : nil  
 Ketone : nil  
 Albumin : nil  
 Urobilinogen : Normal      0.01 mg/ml  
 Specific gravity : 1.015      1.010-1.030  
 Reaction(pH) : 5.5      (Acidic3-6, Alkaline8-10)

**MICROSOPIC EXAMINATION**

Pus(WBCs) Cells : NIL/ hpf  
 RBC : nil/hpf  
 Crystals : Absent  
 Spermatozoa : Absent  
 Epithelial Cells : Absent  
 Bactria : Absent

  
**Dr. B. M. SHARNAGAT**  
 M.D. (Medicine) Regd. No 4612  
 AYUSHMAN HOSPITAL  
 & U.C. Pathologist, Technician  
 (Ayushman Hospital, Baleshwar)  
 (AYUSHMAN HOSPITAL) 481001





**Balaghat, Madhya Pradesh, India**

R57P+5HH, MP SH 11, Chitragupt Nagar, Balaghat, Madhya Pradesh 481001, India

Lat 21.813051°

Long 80.186422°

10/02/24 01:29 PM GMT +05:30



Google



डा. बी. एम. शरणागत  
एम.डी. (मेडिसिन)



रजि.नं. - 4612  
कार्डियो - डायबेटोलॉजिस्ट  
एवं परामर्श चिकित्सक

सर्किट हाउस रोड, बालाघाट 07632-241070 | समय-सुबह 10 बजे से संध्या 8.00 बजे तक

Name MR. RAJAT KUMAR

R/O

Date 10/02/2024

### General Physical Examination

Date of Examination 10/02/2024

Name MR. RAJAT KUMAR Age 37y DOB 08/10/1986 Sex M

Referred by MEDIWHEEL

Photo Id AADHAAR CARD ID

Ht 1.78 (CM)

Wt 73 (kg)

Chest (Expiration): 96 (cm)

Abdomen Circumference 101 (cm)

Blood Pressure 130/90 mm Hg

PR 17 /min

RR 7 /min

Temp 95.5 F

BMI 21

Eye Examination RE 6/6 LE 6/6

Other: NIL

On examination he/she appears physically and mentally fit: Yes/No

Signature of Examinee: [Signature]

Name of Examinee: MR. RAJAT KUMAR

Signature Medical Examiner:

Name Medical Examiner DR. B. M. SHARNAGAT

Dr. B. M. SHARNAGAT

M.D. (Medicine) Regd. No. 4612

AYUSHMAN HOSPITAL

& Diagnostic Research Center

BALAGHAT (M.P.) 461001

### || उपलब्ध सुविधाएं ||

- क्रिटिकल केयर युनिट/आई.सी.सी.यू., सेंट्रल ऑक्सीजन पाइप लाईन युक्त
- फेफड़ों के कार्य क्षमता की कम्प्यूटाईज्ड जांच (P.F.T.)
- मल्टीपरा, पल्स ऑक्स, डीप्रिन्वीलेटर एवं वेंटिलेटर सुविधाएँ
- फिजियोथेरेपी युनिट एवं डायटेशियन परामर्श।
- कम्प्यूटाईज्ड ई.सी.जी., टी.एम.टी., होल्टर मॉनिटरिंग व अल्ट्रासोनो नेबुलाईजेशन
- डायबीटिज, अस्थमा एवं किडनी क्लिनिक।
- एक्सरे, पैथालॉजी, मेडिकल स्टोर्स व कैंटीन सुविधा
- मनोचिकित्सक, चर्मरोग, कैंसर एवं किडनी विशेषज्ञ द्वारा परामर्श - प्रति रविवार



आयुष्मान हॉस्पिटल  
एण्ड डायग्नोस्टिक रिसर्च सेन्टर

Regd.No. : NHA/REG/BGT/2012/21

NAME - MR. RAJAT KUMAR

Age - 37Y/M

R / By - MEDIWHEEL

Date - 10/02/2024


X- RAY CHEST ( PA VIEW)

- \*Bony cage - Normal.
- \*Trachea - Normal.
- \* Heart - Position --- Normal.  
C-T ratio---Within normal limits.  
Cardiac borders--- Normal.  
Specific chamber enlargement---None.
- \*Aorta- Position---Normal.
- \*Mediastinum- Relative Position ---Normal.  
Any Lesion---None.
- \*Angles- Cardiophrenic angles---Clear.  
Costophrenic angles---Clear.
- \*Pleura- Normal.
- \*Lungs- .Lung apices seen clear.  
.Both lungs seen clear.  
.No evidence of any focal active lesion in lung fields.  
.Broncho-vascular markings appear normal.
- \*Hilar shadows- Normal.
- \*Diaphragms- Relative position---Normal.  
Outline---Normal.

OPINION

"X-RAY CHEST APPEARS NORMAL."  
"NO ABNORMALITY DETECTED."

Thanks for referral.

  
**Dr. B. M. SHARNAGAT**  
M.D. (Medicine) Regd.No. 4612.  
AYUSHMAN HOSPITAL  
& Diagnostic Research Center  
BALAGHAT. (M.P.) 481001





## 2D ECHOCARDIOGRAPHY AND DOPPLER REPORT

Name -MR. KUMAR RAJAT

Age - 37Yrs/M

Refd By - SELF

Date - 10.02.2024

### M-Mode & Essential Measurements :-

Heart Rate :74Bpm	LVID(D) : 41 mm	MV Annulus :24mm	RVID(d) : 34 mm
Aortic Root :31 mm	LVID(S) : 24 mm	TV Annulus :22mm	IVC : 16 mm
Left Atrium : 35mm	IVSd (D) : 12 mm	AO Annulus :17mm	Mitral-Epss : 08 mm
LVEF : 60 %	LVPWd(D):10mm	PV Annulus :21mm	TAPSE : 16 mm

### 2D Echo Findings :-

RWM(LV) : NORMAL  
 VALVES : NORMAL  
 CHAMBERS : NORMAL SIZED  
 IAS/IVS : INTACT  
 CLOT/VEGETATION : NIL  
 PERICARDIAL EFFUSION : NIL  
 PLEURAL EFFUSION : NIL

### Doppler Study :-

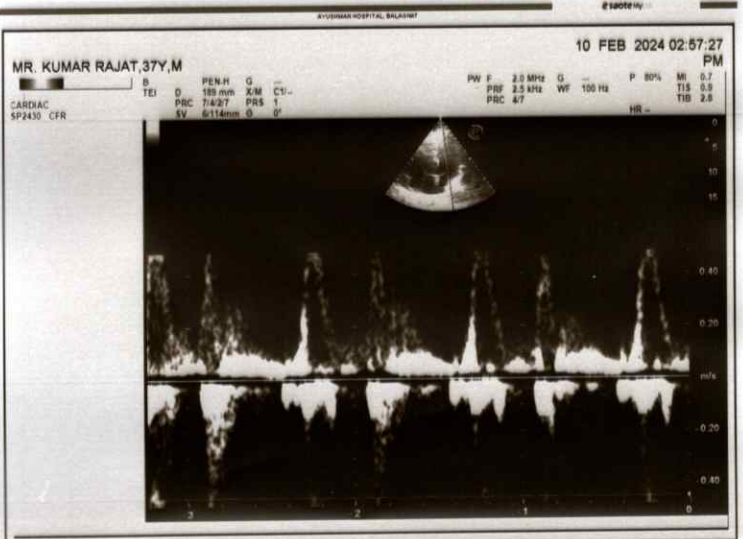
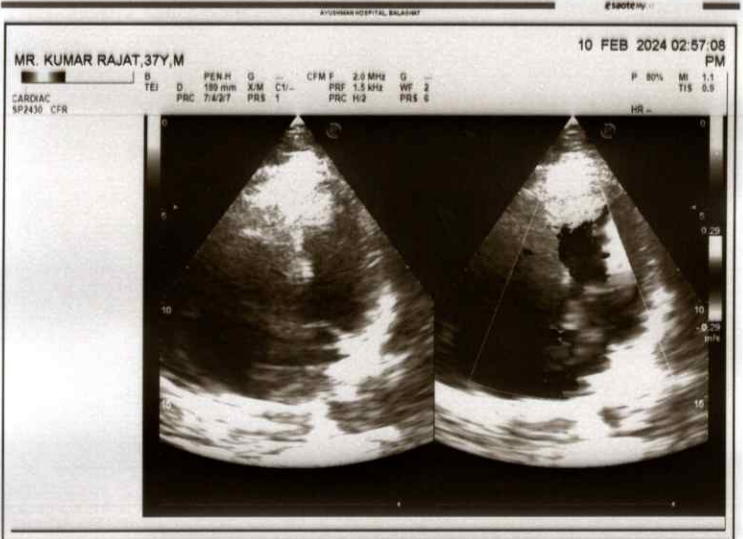
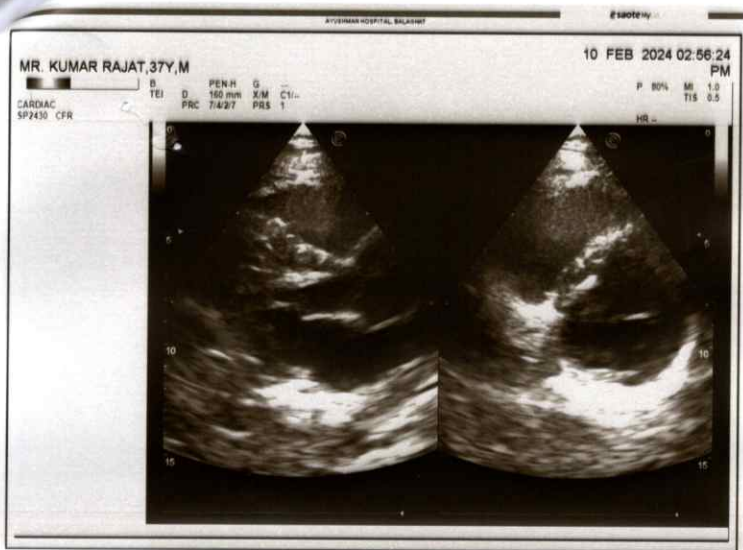
<u>VALVES</u>	Peak Gradient (mm of Hg)	Mean Gradient (mm of Hg)	Valve area (Normal Range)	Grade of Regurgitation
Mitral Valve	--	--	4.0-6.0	NIL
Aortic Valve	--	--	2.5-4.0	NIL
Tricuspid Valve	--	--	7.0-9.0	NIL
Pulmonary valve	--	--	2.0-3.0	NIL

Estimated PASP by TR jet = 25 mm of Hg.

### FINAL DIAGNOSIS :-

NO RWMA/LVDD  
 NORMAL VALVES  
 NORMAL LV SYSTOLIC FU  
 NORMAL RV FUNCTION.

  
**Dr. B.M. SHARNAGAT**  
 M.D. (Medicine) Regd No 4612  
 Dr. B.M. Sharnagat (MD Medicine)  
 AYUSHMAN HOSPITAL  
 & Diagnostic Research Center  
 BALAGHAT (M.P.) 481001







ULTRASOUND REPORT

**Name - MR. KUMAR RAJAT**

**Refd. By - SELF**

**Age - 37Yrs/M**

**Date -10.02.2024**

LIVER : The liver is normal in size and shape . It shows normal parenchymal echo texture.  
The IHBR , IHPR and porta hepatis appear normal.

There is no e/o any lesion.

GALLBLADDER : Normal , There is no e/o evidence of calculi.

PANCREAS : Normal in size and shows normal echotexture.

SPLEEN : Spleen is normal in size and shows homogenous echo texture.

KIDNEYS : Both kidneys are normal in size, shape, contour and in position .

There is no renal calculi and no pelvi calyceal dilatation .

**LEFT KIDNEY MEASURES : 8.5 X 6.3 CM**

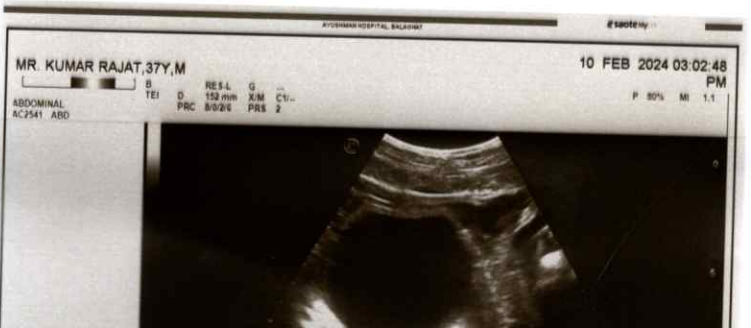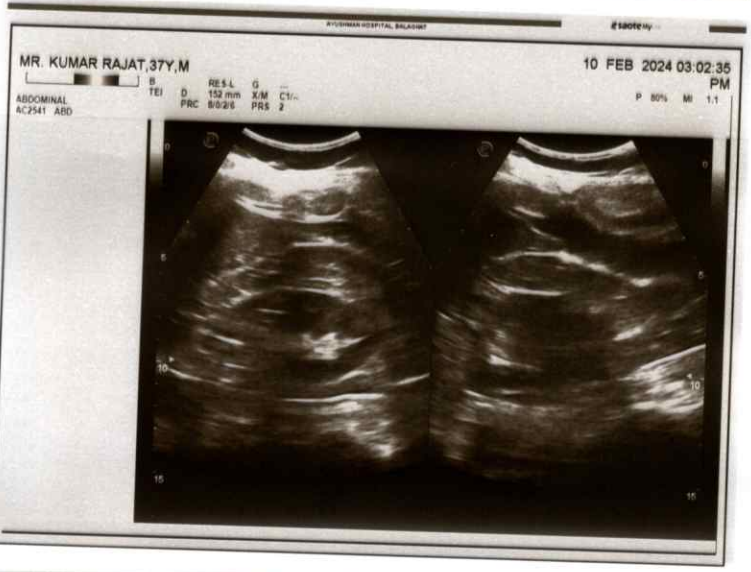
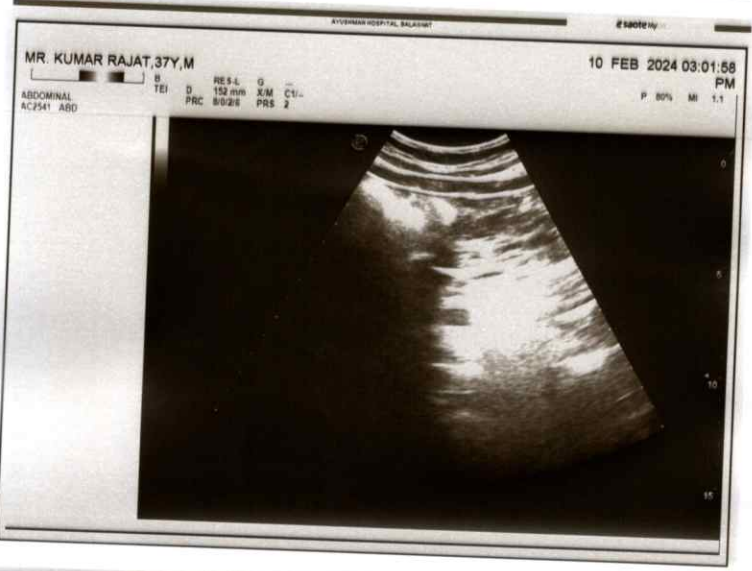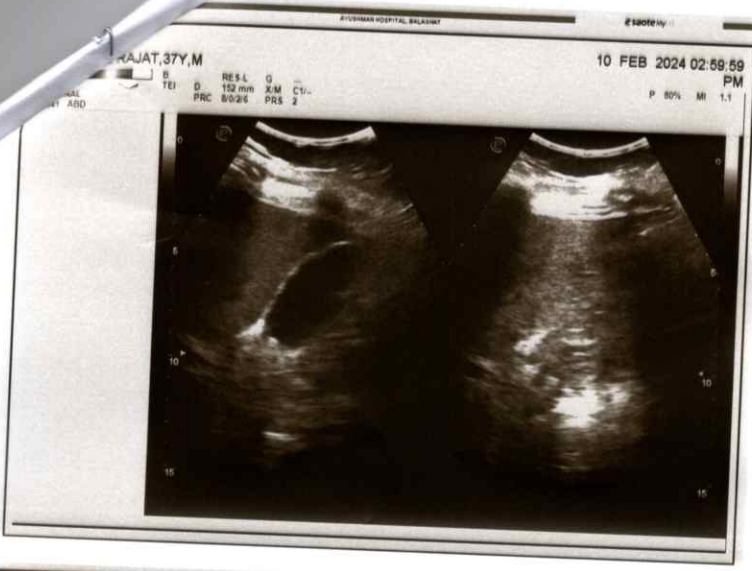**RIGHT KIDNEY MEASURES : 6.2 X 4.7 CM**

PROSTATE : The prostate is normal in size and shows normal echo texture .

There is no e/o free fluid in pelvis .

IMPRESSION : NORMAL STUDY OF ABDOMEN .

**Dr. B.M. SHARNAGAT**  
M D (Medicine) Regd.No.4612  
AYUSHMAN HOSPITAL  
Dr. B.M. Sharnagat (MD) Medical

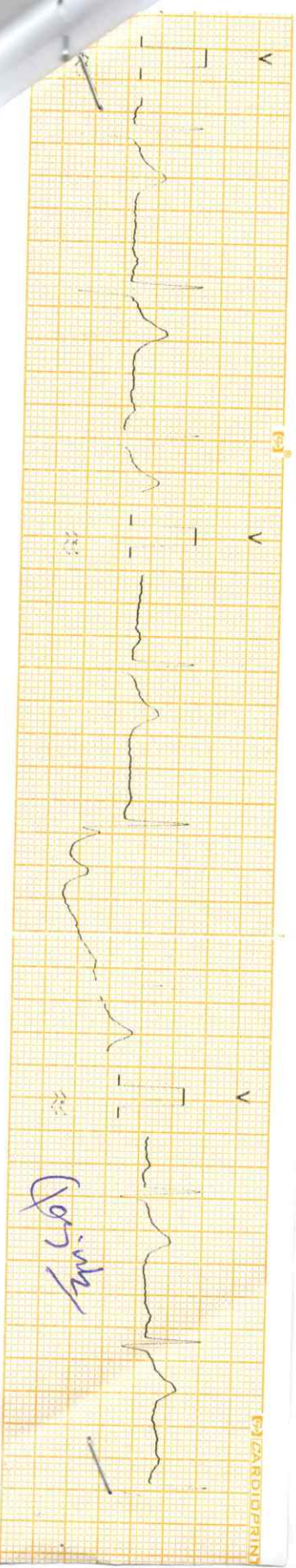
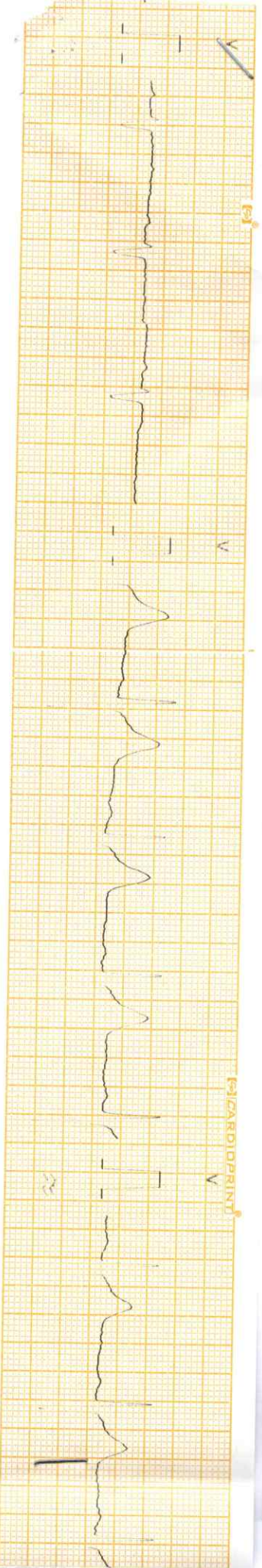
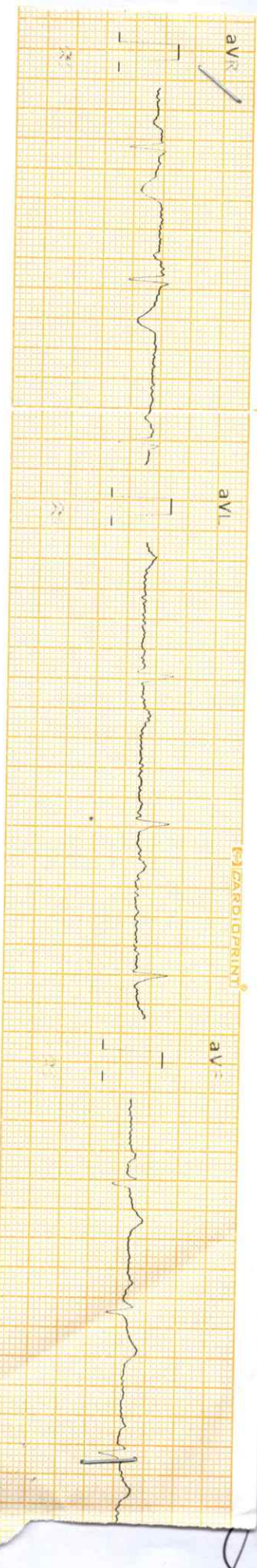
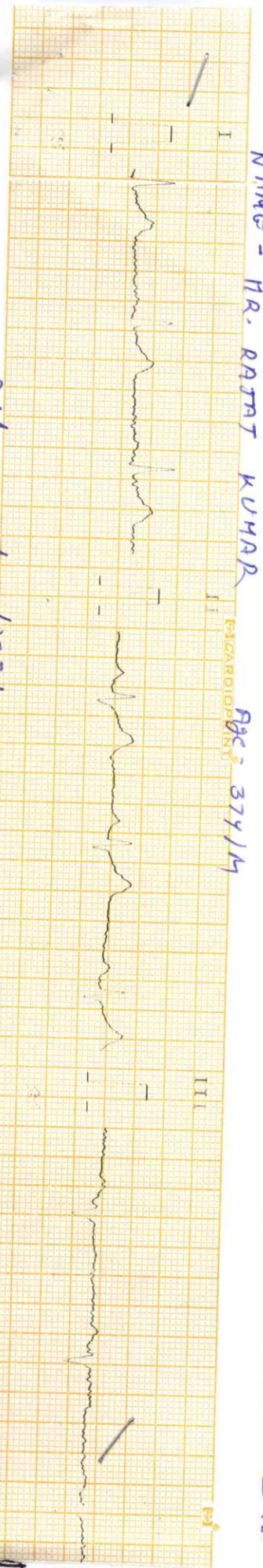




NAME - MR. RAJAT KUMAR

REG: 37914

DATE - 10/10/2024



Normal

REPORT - NORMAL

Dr. B.M. SHARNAGAT

M.D. (Medicine) Regd. No. 13





भारतीय विशिष्ट पहचान प्राधिकरण  
भारत सरकार  
Unique Identification Authority of India  
Government of India



E-Aadhaar Letter

ನೋಂದಣಿ ಸಂಖ್ಯೆ/Enrolment No.: 1177/81118/00044

Date: 17/04/2014

Kumar Rajat (ಕುಮಾರ್ ರಜತ್)

ಮಾಹಿತಿ

S/O: Sri Ram Shankar Prasad Sinha, Tajpur Road,  
Dharampur, Indranagar, Samastipur, Samastipur,  
Bihar - 848101

- ಆಧಾರ್ ಗುರುತಿನ ಪುರಾವೆಯೇ ಹೊರತು ಪೌರತ್ವದ್ದಲ್ಲ
- ನಿಮ್ಮ ಗುರುತನ್ನು ಸಾಬೀತುಪಡಿಸಲು ಆನ್ ಲೈನ್ ಮೂಲಕ ದೃಢೀಕರಿಸಿ
- ಎಲೆಕ್ಟ್ರಾನಿಕ್ ಪ್ರಕ್ರಿಯೆ ಮೂಲಕ ಮುದ್ರಿತವಾದ ವಿದ್ಯುನ್ಮಾನ ದಾಖಲೆ ಇದಾಗಿದೆ

ನಿಮ್ಮ ಆಧಾರ್ ಸಂಖ್ಯೆ/ Your Aadhaar No.:

5540 7285 9707



INFORMATION

- Aadhaar is a proof of identity, not of citizenship.
- To establish identity, authenticate online.
- This is electronically generated letter.

ಆಧಾರ್-ಶ್ರೀ ಸಾಮಾನ್ಯನ ಅಧಿಕಾರ

Validity unknown  
Digitally signed by Sandeep Bhardwaj  
Date: 2014.04.17 09:27:10 IST

1947 1800 300 1947 help@uidai.gov.in www.uidai.gov.in

- ಆಧಾರ್ ದೇಶದಾದ್ಯಂತ ಮಾನ್ಯತೆಯನ್ನು ಪಡೆದಿದೆ.
- ಆಧಾರ್ ನಿಮ್ಮ ಕೆಲವು ಒಂದು ಬಾರಿ ಮಾತ್ರ ನೋಂದಣಿ ಮಾಡಿಸಬೇಕಾಗುತ್ತದೆ.
- ದಯವಿಟ್ಟು ನಿಮ್ಮ ಮೊಬೈಲ್ ಸಂಖ್ಯೆ ಹಾಗೂ ಇ-ಮೇಲ್ ವಿಳಾಸವನ್ನು ನಿಶ್ಚಿತ, ಉಪ್ಪು ದಲ್ಲಿ ಅನೇಕ ಸೇವೆಗಳನ್ನು ಪಡೆಯಲು ಇದು ನಿಮಗೆ ಸಹಾಯಕವಾಗಿದೆ.

- Aadhaar is valid throughout the country.
- You need to enrol only once for Aadhaar.
- Please update your mobile number and e-mail address. This will help you to avail various services in future.



भारत सरकार  
GOVERNMENT OF INDIA



भारतीय विशिष्ट पहचान प्राधिकरण  
UNIQUE IDENTIFICATION AUTHORITY OF INDIA



ಕುಮಾರ್ ರಜತ್  
Kumar Rajat  
ಜನ್ಮ ದಿನಾಂಕ/ DOB: 08/10/1986  
ಪುರುಷ / MALE



ವಿಳಾಸ:

S/O: ಶ್ರೀ ರಾಮ್ ಶಂಕರ್  
ಪ್ರಸಾದ್ ಸಿನ್ಹ, ತಜಪುರ ರೋಡ್,  
ಧರಂಪುರ, ಇಂದ್ರನಗರ,  
ಸಮಸ್ತಿಪುರ, ಸಮಸ್ತಿಪುರ,  
ಬಿಹಾರ್ - 848101

Address:

S/O: Sri Ram Shankar Prasad Sinha,  
Tajpur Road, Dharampur,  
Indranagar, Samastipur, Samastipur,  
Bihar - 848101

Rajat

5540 7285 9707

5540 7285 9707

ಆಧಾರ್-ಶ್ರೀ ಸಾಮಾನ್ಯನ ಅಧಿಕಾರ

Aadhaar-Aam Admi ka Adhikar

Dr. B. M. SHARNAGAT

M D (Medicine) Regd. No. 4612

AYUSHMAN HOSPITAL

Research Center





**PATHOLOGY REPORT**

• Auto Analyzer • Hematology Analyzer • A.B.G. • Computerised Lab

**CBC Report done on Hemtology Analyzer Mispa CountX Plus**

First Name: MR. RAJAT      Last Name: KUMAR      Gender: Male      Age: 37 Years  
 Sample ID: 20      Patient Type:      Patient ID:      Mode: WB  
 Dpt.: PATHOLOGY      Time of Analysis: 10-02-2024 15:45

Modules	Result	Unit	Ref. Ranges
1 WBC	5.3	10 <sup>3</sup> /uL	4.0 - 10.0
2 Lymph#	1.6	10 <sup>3</sup> /uL	0.8 - 4.0
3 Mid#	0.3	10 <sup>3</sup> /uL	0.1 - 1.5
4 Gran#	3.4	10 <sup>3</sup> /uL	2.0 - 7.0
5 Lymph%	30.1	%	20.0 - 40.0
6 Mid%	6.4	%	3.0 - 15.0
7 Gran%	63.5	%	50.0 - 70.0
8 RBC	4.42	10 <sup>6</sup> /uL	4.00 - 5.50
9 HGB	14.0	g/dL	12.0 - 16.0
10 HCT	41.8	%	40.0 - 54.0
11 MCV	94.5	fL	80.0 - 100.0
12 MCH	31.7	pg	27.0 - 34.0
13 MCHC	33.6	g/dL	32.0 - 36.0
14 RDW-CV	13.1	%	11.0 - 16.0
15 RDW-SD	43.4	fL	35.0 - 56.0
16 PLT	165	10 <sup>3</sup> /uL	100 - 300
17 MPV	H 13.0	fL	6.5 - 12.0
18 PDW	16.6		15.0 - 17.0
19 PCT	0.215	%	0.108 - 0.282
20 P-LCC	78	10 <sup>3</sup> /uL	30 - 90
21 P-LCR	H 47.3	%	11.0 - 45.0

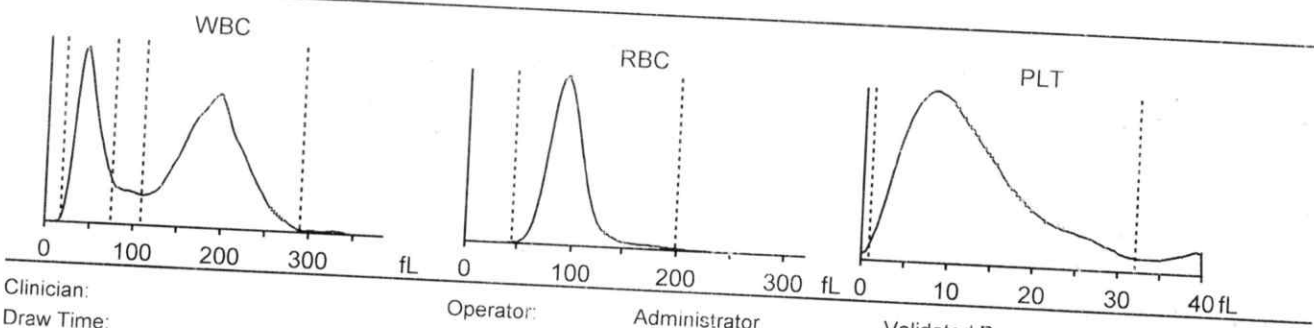
WBC Message

---

RBC Message

---

PLT Message



Clinician:      Operator:      Administrator:      Validated By:      Time of Printing: 10-02-2024 15:46  
 Draw Time:      Delivery Time:      1/1

[This report only applies to the corresponding sample analyzed]

**Dr. B. M. SHARNAGAT**  
 M.D. (Medicine) Regd. No. 4612  
 I/C Pathologist/Technician  
 (Ayushman Hospital, Balaghat)  
 Research Center  
 BALAGHAT (M.P.) 481001

• This Report is not valid for MLC purpose.  
 • This Report is only for Physician's help to confirm the diagnosis.

NAME : MR. RAJAT KUMAR

AGE : 37Yrs.

SEX : M

REF. BY : Dr. B. M. SHARNAGAT (M.D.)

DATE : 10/02/2023

**BIOCHEMISTRY**

TEST	RESULTS	UNITS	REF. RANGE
------	---------	-------	------------

**BLOOD SUGAR**

B.SUGAR (f)	:86	mg/ dl	60-100
(p.p)	:125	mg/dl	120-160

METHOD : GOD-POD

Blood group **B**

Rh Type **Positive**

**STOOL EXAMINATION**

Stool for Routine& Microscopic Examination : Normal

Stool for Occult blood : Negative

**THYROID HORMONE**

TSH	4.5	uIU/mL	0.3 - 5.0
T3	0.85	ng/mL	0.6-1.8
T4	10.6	ug/dL	4.5-11.6

**LIPID PROFILE**

S. Cholesterol	:174	mg/dl	UP TO <200
S. Triglycerides	:142	mg/dl	UP TO <150
HDL Cholesterol	:36	mg/dl	32 -60
LDL Cholesterol	:99	mg/dl	UP TO <100
VLDL Cholesterol	:28	mg/dl	7 - 35
LDL / HDL Ratio	:2.9	%	2.5 - 5.0
S. Cholesterol / HDL Ratio	:4.3	%	3.5 - 5.0

**D.B.M. SHARNAGAT**  
 M.D. (Medicine) Reg. No. 4612  
 AYUSHMAN HOSPITAL  
 & Diagnostic Research Center  
 (Ayushman Hospital, Balaghat)

- This Report is not valid for MLC purpose.
- This Report is only for Physician's help to confirm the diagnosis.



NAME : MR. RAJAT KUMAR

AGE : 37Yrs.

SEX : M

REF. BY : Dr. B. M. SHARNAGAT (M.D.)

DATE : 10/02/2023

**BIOCHEMISTRY**

TEST	RESULTS	UNITS	REF. RANGE
<b><u>KFT</u></b>			
Serum CREATININE	:0.96	mg/dl	0.8-1.2
BUN	:15	mg/dl	8-20
<b><u>LFT</u></b>			
Bilirubin-Total	:0.8	mg%	0-1.2
Direct	:0.5	mg%	0-0.6
Indirect	:0.3	mg%	0-0.5
SGPT <sub>(ALT)</sub>	:20	IU/L	7-35
SGOT <sub>(AST)</sub>	:29	IU/L	8-40
Alk.Phosphatase	:105	U/L	86-306 Adult
<b>TOTAL PROTEINS</b>	7.3	gm/dl	6.2-8.2
Albumin	4.7	g/dl	3.5-5.5
Globulin	2.8	g/dl	2.5-3.2
A/G Ratio	1.6		1.5-2.5
GGT	16	U/L	9-48
<b>S.URIC ACID</b>	3.5	mg/dl	3.4- 7.2
<b>HbA1C</b>	5.2 %		

Nondiabetic :4.5 -6.2  
 Good Control: 6.0 -7.0%  
 Fair Control: 7.0 -8%  
 Poor Control: >8%

(Action Suggested)

ESR  
Method

:06 1 st Hr  
westangren

0-20

**Dr. B. M. SHARNAGAT**  
 M.D. (Medicine) Reg. No. 4612  
 J.C. Pathologist/Technician  
 (Ayushman Hospital, Balaghat)  
 BALAGHAT (M.P.) 481001

- This Report is not valid for MLC purpose.
- This Report is only for Physician's help to confirm the diagnosis.