

# PACE HOSPITALS

Hitech City: Beside Avasa Hotel, Pillar No. 18, Hyderabad - 81. T: 040 4848 6868  
 Miyapur: Beside South India Shopping, Madinaguda, Hyderabad - 50, T:040 48486767

## DEPARTMENT OF BIOCHEMISTRY

Patient Name	: Miss. PAGALA JASMEEN	Age / Sex	: 31 Y(s)/Female
Ref By	: Dr. GENERAL PHYSICIAN	UMR No	: UMR105813
Bill Date	: 10-Aug-24 08:48 am	Bill No	: BIL185889
Lab No	: BIO/24/8/756	Result No	: RES545050
Samp.Coll	: 10-Aug-24 09:13 am	Auth. Tim	: 10-Aug-2024 11:26 am
Reported On	: 10-Aug-24 11:26 am		

<u>Parameter</u>	<u>Result</u>	<u>Biological Reference Interval</u>	<u>Method</u>
<b>LIPID PROFILE: SERUM</b>			
			Specimen    Serum
Triglycerides	: 97	BorderLine : 150 - 199 mg/dl High : 200 - 500 mg/dl Normal : < 150 mg/dl	GPO-Trinder End Point
Total Cholesterol	: 148	< 200 mg/dl	CHOD-PAP End Point
HDL Cholesterol	: 44	Undesirable : < 40 Optimal : 40 - 59 Desirable : > 60	
VLDL Cholesterol	: 19	2 - 30 mg/dl	
LDL Cholesterol	: 85	0 - 100 mg/dl	
Cholestrol / HDL Ratio	: 3.36	1.0 - 3.5	
Note	:		
Serum Uric Acid	: 4.8	2.6 - 6.0 mg/dl	Uricase-Peroxidase
Blood Urea Nitrogen(BUN)	: 8.6	6 - 21 mg/dl	GLDH - Urease
Serum Creatinine	: 0.8	0.3 - 1.0 mg/dl	Jaffe Kinetic
<b>LFT- LIVER FUNCTION TESTS</b>			
			Specimen    Serum
Total Bilirubin	: 0.9	0.2 - 1.2 mg/dl	Diazo
Direct Bilirubin	: 0.4	0.0 - 0.3 mg/dl	Diazo
Indirect Bilirubin	: 0.5	0.2 - 0.7 mg/dL	
SGPT	: 16	< 41 IU/L	IFCC - Kinetic
SGOT	: 10	< 40 IU/L	IFCC - Kinetic
AST / ALT -Ratio	: 0.63		

# PACE HOSPITALS

Hitech City: Beside Avasa Hotel, Pillar No. 18, Hyderabad - 81. T: 040 4848 6868  
Miyapur: Beside South India Shopping, Madinaguda, Hyderabad - 50, T:040 48486767

## DEPARTMENT OF BIOCHEMISTRY

Patient Name	: Miss. PAGALA JASMEEN	Age / Sex	: 31 Y(s)/Female
Ref By	: Dr. GENERAL PHYSICIAN	UMR No	: UMR105813
Bill Date	: 10-Aug-24 08:48 am	Bill No	: BIL185889
Lab No	: BIO/24/8/756	Result No	: RES545050
Samp.Coll	: 10-Aug-24 09:13 am	Auth. Tim	: 10-Aug-2024 11:26 am
Reported On	: 10-Aug-24 11:26 am		

<u>Parameter</u>	<u>Result</u>	<u>Biological Reference Interval</u>	<u>Method</u>
Alkaline Phosphatase	: 99	< 105 U/L	AMP Kinetic
Total Protein	: 6.7	6.4 - 8.3 gm/dl	Biuret Method
Serum Albumin	: 4.0	3.5 - 5.2 gm/dl	BCG Dye
Serum Globulin	: 2.7	2.0 - 3.5 g/dL	
Albumin / Globulin Ratio	: 1.48	1.2 - 2.2	
<b>THYROID PROFILE</b>			Specimen Serum
T3-Free (Triiodothyronine-Free)	: 3.3	2.0 - 4.2 pg/mL	C L I A
T4-Free (Thyroxine -Free)	: 15.7	8.9 - 17.2 pg/ml	C L I A
TSH(Thyroid Stimulating Hormone).	: 2.8	0.3 - 4.5 µIU/ml	C L I A
Glycated Haemoglobin - HbA1c	: 5.5	Non Diabetic : < 5.7 Pre Diabetic : 5.7 - 6.4 Diabetic : >= 6.5	Immunoturbidimetry

--- End Of Report ---

PHH8506

Dr.B PRATHYUSHA  
MD BIOCHEMIST  
CONSULTANT BIOCHEMIST

Dr.Y NIHARIKA REDDY  
M.D PATHOLOGY  
CONSULTANT PATHOLOGIST

Dr.SAMATHA  
MD Microbiology  
CONSULTANT MICROBIOLOGIST

# PACE HOSPITALS

Hitech City: Beside Avasa Hotel, Pillar No. 18, Hyderabad - 81. T: 040 4848 6868  
Miyapur: Beside South India Shoping, Madinaguda, Hyderabad - 50, T:040 48486767

## DEPARTMENT OF HAEMATOLOGY

Patient Name	: Miss. PAGALA JASMEEN	Age / Sex	: 31 Y(s)/Female
Ref By	: Dr. GENERAL PHYSICIAN	UMR No	: UMR105813
Bill Date	: 10-Aug-24 08:48 am	Bill No	: BIL185889
Lab No	: HEM/24/8/529	Result No	: RES545004
Samp.Coll	: 10-Aug-24 09:13 am	Auth. Tim	: 10-Aug-2024 10:35 am
Reported On	: 10-Aug-24 10:35 am		

<u>Parameter</u>	<u>Result</u>	<u>Biological Reference Interval</u>	Specimen	
<b>COMPLETE BLOOD PICTURE</b>			Specimen	WHOLE BLOOD
Haemoglobin	: 12.2 gm%	11.0 - 13.0 gm%		
RBC Count	: 4.5 Millions/cumm	4.5-6.5 Millions/cumm		
PCV	: 37 Vol%	38 - 45 Vol%		
Platelet count	: 2.89 Lakhs/Cumm	1.5 - 4.5 Lakhs/Cumm		
WBC Count	: 7,830 cells/cumm	4000 - 11000 cells/cumm		
<b><u>DIFFERENTIAL COUNT</u></b>				
NEUTROPHILS	: 60 %	40-75 %		
LYMPHOCYTES	: 32 %	20 - 45 %		
EOSINOPHILS	: 02 %	2-6 %		
MONOCYTES	: 06 %	2-8 %		
BASOPHILS	: 00 %	0 - 2 %		
<b><u>SMEAR EXAMINATION</u></b>				
RBC	:	Normocytic / Normochromic		
WBC	:	With In Normal Limits		
Platelets	:	Adequate		
<b>BLOOD GROUPING &amp; RH TYPING</b>			Specimen	Blood
BLOOD GROUP	: " O "			Agglutination
RH TYPING	: POSITIVE			

--- End Of Report ---

PHH8624

# PACE HOSPITALS

Hitech City: Beside Avasa Hotel, Pillar No. 18, Hyderabad - 81. T: 040 4848 6868  
Miyapur: Beside South India Shopping, Madinaguda, Hyderabad - 50, T:040 48486767

## DEPARTMENT OF HAEMATOLOGY

Patient Name	: Miss. PAGALA JASMEEN	Age / Sex	: 31 Y(s)/Female
Ref By	: Dr. GENERAL PHYSICIAN	UMR No	: UMR105813
Bill Date	: 10-Aug-24 08:48 am	Bill No	: BIL185889
Lab No	: 185889	Result No	: RES545022
Samp.Coll	: 10-Aug-24 09:13 am	Auth. Tim	: 10-Aug-2024 10:26 am
Reported On	: 10-Aug-24 10:26 am		

<u>Parameter</u>	<u>Result</u>	<u>Method</u>
------------------	---------------	---------------

---

Dr.B PRATHYUSHA  
MD BIOCHEMIST  
CONSULTANT BIOCHEMIST

Dr.Y NIHARIKA REDDY  
M.D PATHOLOGY  
CONSULTANT PATHOLOGIST

Dr.SAMATHA  
MD Microbiology  
CONSULTANT MICROBIOLOGIST

# PACE HOSPITALS

Hitech City: Beside Avasa Hotel, Pillar No. 18, Hyderabad - 81. T: 040 4848 6868  
Miyapur: Beside South India Shoping, Madinaguda, Hyderabad - 50, T:040 48486767

## DEPARTMENT OF CLINICAL PATHOLOGY

Patient Name	: Miss. PAGALA JASMEEN	Age / Sex	: 31 Y(s)/Female
Ref By	: Dr. GENERAL PHYSICIAN	UMR No	: UMR105813
Bill Date	: 10-Aug-24 08:48 am	Bill No	: BIL185889
Lab No	: 185889	Result No	: RES545032
Samp.Coll	: 10-Aug-24 09:13 am	Auth. Tim	: 10-Aug-2024 11:15 am
Reported On	: 10-Aug-24 11:15 am		

<u>Parameter</u>	<u>Result</u>	<u>Biological Reference Interval</u>	<u>Method</u>
<b>COMPLETE URINE EXAMINATION</b>			
			Specimen Urine
<u>PHYSICAL EXAMINATION:</u>			
Colour	: Pale Yellow		
Appearance	: Clear		
pH	: 5.5	5.5 - 7.0	pH indicator
Specific gravity	: 1.010	1.010 - 1.025	Bromthymol blue indicator
<u>CHEMICAL EXAMINATION:</u>			
Urine for Sugar	: Nil	0 - 2.8 mmol/L	GOD-POD
Protein	: Nil	0 - 0.15 g/L	protein error of indicator
Blood	: Nil	0 - 10 Cells/ $\mu$ L	
Bilirubin	: Nil	0 - 0 $\mu$ mol/L	Diazonium method
NITRITE	: Absent	13 - 22 $\mu$ mol/L	
Leukocytes	: Nil	05 - 15 leuko/ $\mu$ L	
Ketone bodies	: Negative	0 - 0 mmol/L	Nitroprusside reaction
<u>MICROSCOPIC EXAMINATION:</u>			
Pus Cells	: 1-2	0 - 5 /HPF	
Epithelial Cells	: 0-1	0 - 8 /HPF	
RBC COUNT	: Nil	0 - 2 /HPF	
Casts	: Nil		
Crystals	: Nil		
Others	:	Nil	
<b>ESR - ERYTHROCYTE SEDIMENT RATE</b>			
			Specimen Blood
ESR - ERYTHROCYTE SEDIMENTATION RATE	: 22	< 15 mm	

--- End Of Report ---

# PACE HOSPITALS

Hitech City: Beside Avasa Hotel, Pillar No. 18, Hyderabad - 81. T: 040 4848 6868  
Miyapur: Beside South India Shopping, Madinaguda, Hyderabad - 50, T:040 48486767

## DEPARTMENT OF CLINICAL PATHOLOGY

Patient Name	: Miss. PAGALA JASMEEN	Age / Sex	: 31 Y(s)/Female
Ref By	: Dr. GENERAL PHYSICIAN	UMR No	: UMR105813
Bill Date	: 10-Aug-24 08:48 am	Bill No	: BIL185889
Lab No	: 185889	Result No	: RES545062
Samp.Coll	: 10-Aug-24 09:13 am	Auth. Tim	: 10-Aug-2024 11:15 am
Reported On	: 10-Aug-24 11:15 am		

<u>Parameter</u>	<u>Result</u>	<u>Biological Reference Interval</u>
------------------	---------------	--------------------------------------

PHH8624

---

Dr.B PRATHYUSHA  
MD BIOCHEMIST  
CONSULTANT BIOCHEMIST

Dr.Y NIHARIKA REDDY  
M.D PATHOLOGY  
CONSULTANT PATHOLOGIST

Dr.SAMATHA  
MD Microbiology  
CONSULTANT MICROBIOLOGIST


# PACE HOSPITALS

Hitech City: Beside Avasa Hotel, Pillar No. 18, Hyderabad - 81. T: 040 4848 6868  
Miyapur: Beside South India Shopping, Madinaguda, Hyderabad - 50, T:040 48486767

## DEPARTMENT OF RADIOLOGY

Patient Name	: Miss. PAGALA JASMEEN	Age / Sex	: 31 Y(s)/Female
Ref By	: Dr. GENERAL PHYSICIAN	UMR No	: UMR105813
Bill Date	: 10-Aug-24 08:48 am	Bill No	: BIL185889
Lab No	: 0	Result No	: RES545154
Samp.Coll	: 10-Aug-24 08:48 am	Auth. Tim	: 10-Aug-2024 1:00 pm
Reported On	: 10-Aug-24 01:00 pm		

FINDINGS : Heart size is normal.  
Both lung fields clear.  
Both hila normal.  
Both CP angles free.  
Soft tissue chest wall and bony cage normal.



Dr. AKHIL REDDY, MBBS, MD  
CONSULTANT RADIOLOGIST

---

Dr.LAKSHMI KUMAR CH  
MBBS,DNB,PDCC,EBIR  
INTERVENTIONAL RADIOLOGIST

## DEPARTMENT OF CARDIOLOGY

<b>Patient Name</b> : Miss. PAGALA JASMEEN	<b>Age /Sex</b> : 31 Y(s)/Female
<b>Ref By</b> : Dr. GENERAL PHYSICIAN	<b>UMR No</b> : UMR105813
<b>Bill Date</b> : 10-Aug-24 08:48 am	<b>Bill No</b> : BIL185889
<b>Lab No</b> : 0	<b>Result No</b> : RES545109
<b>Samp.Coll</b> : 10-Aug-24 08:48 am	<b>Auth. Tim</b> :
<b>Reported On</b> : 10-Aug-24 12:17 pm	

### 2D ECHO / TMT

MITRAL VALVE	:	Normal	
TRICUSPID VALVE	:	Normal	
AORTIC VALVE	:	Trileaflets	
PULMONARY VALVE	:	Normal	
RIGHT ATRIUM	:	Normal	
RIGHT VENTRICLE	:	TAPSE=2.2cm	
LEFT ATRIUM	:	3.2cm	
LEFT VENTRICLE	:	EDD:3.7cm FS:40%	IVS:8mm
LVEF	:	ESD:2.2cm 71%	LVPW:8mm
IAS	:	Intact	
IVS	:	Intact	



## DEPARTMENT OF CARDIOLOGY

<b>Patient Name</b> : Miss. PAGALA JASMEEN	<b>Age /Sex</b> : 31 Y(s)/Female
<b>Ref By</b> : Dr. GENERAL PHYSICIAN	<b>UMR No</b> : UMR105813
<b>Bill Date</b> : 10-Aug-24 08:48 am	<b>Bill No</b> : BIL185889
<b>Lab No</b> : 0	<b>Result No</b> : RES545109
<b>Samp.Coll</b> : 10-Aug-24 08:48 am	<b>Auth. Tim</b> :
<b>Reported On</b> : 10-Aug-24 12:17 pm	

AORTA	:	2.0cm
IVC	:	Collapse
PULMOANRY VEINS	:	Normal
PERICARDIUM	:	No effusion
INTRACARDIAC MASSES	:	Nil
SVC/IVC/CS	:	Normal
PJV	:	0.9m/sec
AJV	:	1.3m/sec
MVF-E	:	1.0m/sec
MVF-A	:	0.6m/sec
NO MR, NO AR, NO TR	:	NO MR/AS/AR/TR/PH,PR+

## DEPARTMENT OF CARDIOLOGY

<b>Patient Name</b> : Miss. PAGALA JASMEEN	<b>Age /Sex</b> : 31 Y(s)/Female
<b>Ref By</b> : Dr. GENERAL PHYSICIAN	<b>UMR No</b> : UMR105813
<b>Bill Date</b> : 10-Aug-24 08:48 am	<b>Bill No</b> : BIL185889
<b>Lab No</b> : 0	<b>Result No</b> : RES545109
<b>Samp.Coll</b> : 10-Aug-24 08:48 am	<b>Auth. Tim</b> :
<b>Reported On</b> : 10-Aug-24 12:17 pm	

IMPRESSION :

NO LV RWMA  
GOOD LV/RV FUNCTION  
NORMAL LV DIASTOLIC FUNCTION  
NO MR/AS/AR/TR/PH  
LEFT AORTIC ARCH; NO CoA  
NO CLOT/PE/VEGETATION

**Dr. DEVUPALLI SRAVAN, DM  
CARDIOLOGY(SJICR)**

**CONSULTANT CARDIOLOGIST**

Page 3 of 3

**DEPARTMENT OF BIOCHEMISTRY**

<b>Patient Name</b> : Miss. PAGALA JASMEEN	<b>Age /Sex</b> : 31 Y(s)/Female
<b>Ref By</b> : Dr.GENERAL PHYSICIAN	<b>UMR No</b> : UMR105813
<b>Bill Date</b> : 10-Aug-24 08:48 am	<b>Bill No</b> : BIL185889
<b>Lab No</b> : BIO/24/8/756	<b>Result No</b> : RES545050
<b>Samp.Coll</b> : 10-Aug-24 09:13 am	<b>Auth. Tim</b> : 10-Aug-2024 4:58 pm
<b>Reported On</b> : 10-Aug-24 04:58 pm	


**BLOOD SUGAR FASTING AND POST PRANDIAL**

<u>Parameter</u>	<u>Result</u>	<u>Biological Reference Interval</u>	<u>Method</u>
Fasting Blood Sugar :	89 mg/dl	60 - 110 mg/dl	GOD-POD
Blood Sugar Post Prandial :	* 104 mg/dl	110 - 140 mg/dl	

--- End Of Report ---

PHH8506

Verified by



**Dr. B PRATHYUSHA, MD BIOCHEMIST**  
**CONSULTANT BIOCHEMIST**

**Dr.B PRATHYUSHA**  
MD BIOCHEMIST  
CONSULTANT BIOCHEMIST

**Dr.Y NIHARIKA REDDY**  
M.D PATHOLOGY  
CONSULTANT PATHOLOGIST

**Dr.SAMATHA**  
MD Microbiology  
CONSULTANT MICROBIOLOGIST

185889  
31 Years

pangala jasmeeen  
Male

10/08/2024 12:08:45 PM  
PACE HOSPITALS

Rate 67 . Sinus rhythm.....normal P axis, V-rate 50- 99

PR 132  
QRSD 89  
QT 382  
QTc 404

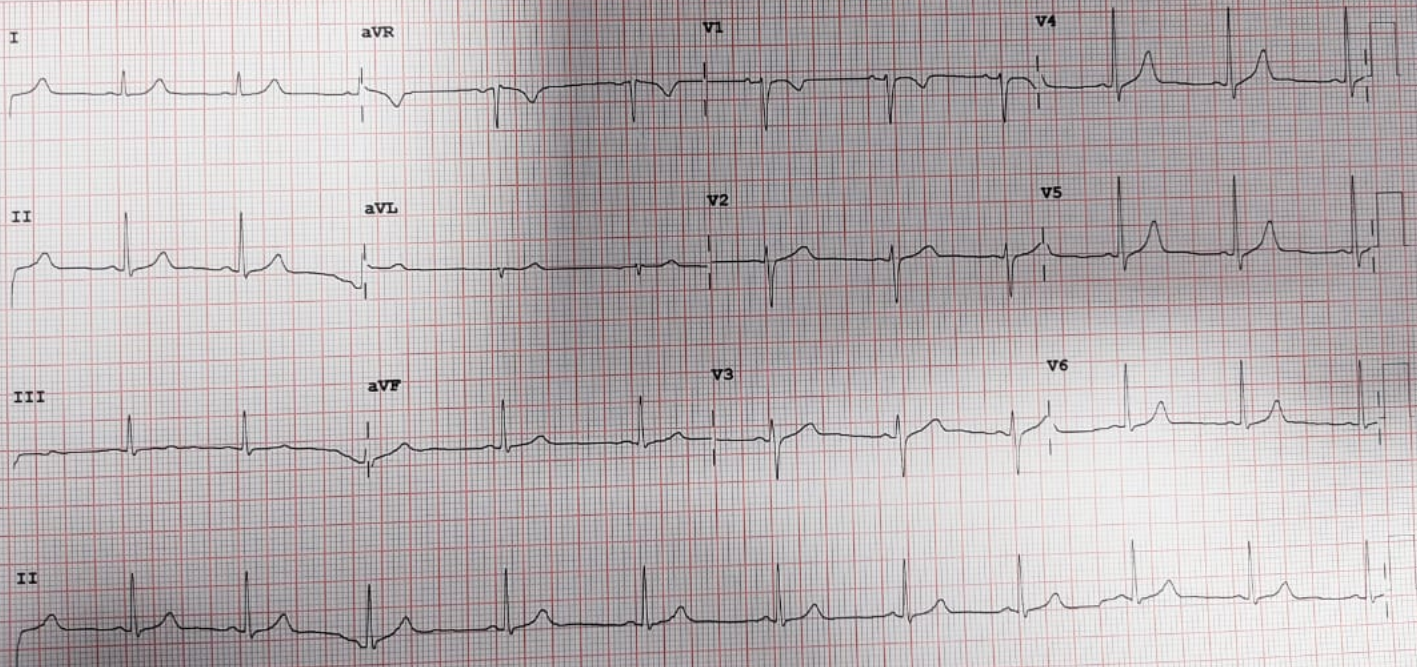
--AXIS--

P 54  
QRS 62  
T 36

- NORMAL ECG -

Unconfirmed Diagnosis

12 Lead; Standard Placement



POCO

SHOT BY MOHINUR

Speed: 25 mm/sec

Limb: 10 mm/mV

Chest: 10.0 mm/mV

F 50- 0.15- 40 Hz

PH100B CL P?

HEWLETT  
PACKARD

REORDER HP M2419

82130

2024/8/10 12:31

## DEPARTMENT OF RADIOLOGY

<b>Patient Name</b> :Miss. PAGALA JASMEEN	<b>Age / Gender</b> : 31 Y(s) / Female
<b>Requested Date</b> :10-Aug-2024 8:48 AM	<b>UMR No</b> : UMR105813
<b>Reported Date</b> :10-Aug-2024 12:02 PM	<b>Result/ Bill No</b> : RES545100 / BIL185889
<b>Referred By</b> :Walk-In	<b>Lab No</b> : 0
<b>Advised By</b> :Dr.GENERAL PHYSICIAN	

### US ABDOMEN AND PELVIS (FEMALE)

#### FINDINGS

LIVER: Enlarged in size (15.7 cm) and normal echotexture. No focal lesions noted. No intra hepatic biliary dilatation. CBD 3 mm and Portal vein 9.5 mm appear normal in course and calibre.

GALL BLADDER: Well distended. No evidence of sludge / calculus. No evidence of wall thickening / pericholecystic collection.

PANCREAS: Normal in size and echotexture. Pancreatic duct appears normal. No peri pancreatic collection.

SPLEEN: Normal in size (8.5 cm) and echotexture.

BOTH KIDNEYS: Right kidney measures: 9.4 x 4 cm noted in right iliac fossa. Left kidney measures: 11.3 x 5.5 cm. Both kidneys are normal in size and echotexture. CMD is maintained. No evidence of calculi. Pelvicalyceal system appears normal on both sides.

Aorta and IVC: Visualized portions are normal.

No evidence of para-aortic or paracaval lymphadenopathy.

URINARY BLADDER: Well distended. Wall thickness is normal.

UTERUS: 6.7 x 3.5 x 4.5 cm. Normal in size and echotexture. Endometrial thickness is 12 mm.

Adnexa appears normal.

OVARIES: Right ovary : 12 cc and shows 27 x 21 mm follicular cyst. ; Left ovary : 6.6 cc. Normal in size and echotexture.



## DEPARTMENT OF RADIOLOGY

<b>Patient Name</b> :Miss. PAGALA JASMEEN	<b>Age / Gender</b> : 31 Y(s) / Female
<b>Requested Date</b> :10-Aug-2024 8:48 AM	<b>UMR No</b> : UMR105813
<b>Reported Date</b> :10-Aug-2024 12:02 PM	<b>Result/ Bill No</b> : RES545100 / BIL185889
<b>Referred By</b> :Walk-In	<b>Lab No</b> : 0
<b>Advised By</b> :Dr.GENERAL PHYSICIAN	

No evidence of ascites.

### IMPRESSION

\* Right ectopic kidney.

\* Hepatomegaly.



*Prashanthi*  
**Dr. K.PRASHANTHI**  
**CONSULTANT RADIOLOGIST**

Page 2 of 2

---

**Dr.LAKSHMI KUMAR CH**  
MBBS,DNB,PDCC,EBIR  
INTERVENTIONAL RADIOLOGIST





EYE CHECKUP

NAME: *Pooja Jainwar* AGE: *51* GENDER: MALE / FEMALE

UMR NO: *(05815)* CONSULTANT NAME: *SAIVENNELAP*

CHIEF COMPLAINTS:

*Grosse Charoverp.*

MEDICAL HISTORY:

*Long mg + 3 yrs Long x 6 months*

REFRACTION & VISION:

<u>UNAIDED</u>	OD	OS	<u>AIDED</u> <i>epf</i>	OD	OS	<u>COLOR VISION</u>	OD	OS		
	DISTANCE:	<i>6/18</i>		<i>6/18</i>	DISTANCE:		<i>6/6</i>	<i>6/6</i>	<i>6/6</i>	<i>6/6</i>
	NEAR:	<i>N6</i>		<i>N6</i>	NEAR:		<i>N6</i>	<i>N6</i>	<i>N6</i>	<i>N6</i>

SUBJECTIVE REFRACTION:

	SPH	CYL	AXIS	ADD	BCVA	BNCVA
OD:	<input type="text"/>	<input type="text"/>	<input type="text"/>	<input type="text"/>	<input type="text"/>	<input type="text"/>
OS:	<input type="text"/>	<input type="text"/>	<input type="text"/>	<input type="text"/>	<input type="text"/>	<input type="text"/>

PLAN OF CARE:

SIGNATURE *[Signature]*

**Hitech City:**  
 Plot No. 23, HUDA Techno Enclave, Patika Nagar, Madhapur,  
 Hyderabad, Telangana - 500081.  
 T: 040 4848 6868 | E: info@pacehospitals.in

ivacainaguda

## DEPARTMENT OF RADIOLOGY

<b>Patient Name</b> : Miss. PAGALA JASMEEN	<b>Age / Gender</b> : 31 Y(s) / Female
<b>Requested Date</b> : 10-Aug-2024 8:48 AM	<b>UMR No</b> : UMR105813
<b>Reported Date</b> : 10-Aug-2024 01:00 PM	<b>Result/ Bill No</b> : RES545154 / BIL185889
<b>Referred By</b> : Walk-In	<b>Lab No</b> : 0
<b>Advised By</b> : Dr.GENERAL PHYSICIAN	

### X-RAY CHEST PA VIEW

#### FINDINGS

Heart size is normal.

Both lung fields clear.

Both hila normal.

Both CP angles free.

Soft tissue chest wall and bony cage normal.



*M. Akhil Reddy*  
Dr. AKHIL REDDY, MBBS, MD  
CONSULTANT RADIOLOGIST

---

Dr.LAKSHMI KUMAR CH  
MBBS,DNB,PDCC,EBIR  
INTERVENTIONAL RADIOLOGIST