

**Health Check up Booking Request(bobS13443),Package Code(PKG1000241),Beneficiary Code(81009)**

1 message

Mediwheel &lt;customercare@policywheel.com&gt;

1 July 2022 at 16:18

To: "vidhidiagnostics@gmail.com" &lt;vidhidiagnostics@gmail.com&gt;

Cc: Mediwheel CC &lt;customercare@mediwheel.in&gt;, Mediwheel CC &lt;mediwheelwellness@gmail.com&gt;

**011-41195959****Email:wellness@mediwheel.in**

Dear Vidhi Diagnostics,  
City : Ahmedabad . Location : .New Wadaj,

We have received the following request for Health Check up from

**Name** : RICHA SRIVASTAVA  
**Age** : 35  
**Gender** : Female  
**Member Relations** : Spouse  
**Package Name** : Medi-Wheel Metro Full Body Health Checkup Female Below 40  
**Package Code** : PKG1000241  
**User Location** : Gujarat,AHMEDABAD,382418  
**Contact Details** : 9620809019  
**Booking Date** : 01-07-2022  
**Appointment Date** : 08-07-2022

Member Information			
Booked Member Name	Age	Gender	Cost(In INR)
RICHA SRIVASTAVA	35	Female	Cashless
<b>Total amount to be paid</b>		<b>Cashless</b>	

Please login to your account to confirm the same. Also you mail us for confirmation

**Package Name** : Medi-Wheel Metro Full Body Health Checkup Female Below 40 - Includes (37 )Tests

Tests included in this Package : Ecg, TSH, X-ray Chest, Stress Test (tmt)/ 2d Echo, Blood Sugar Postprandial, A:g Ratio, Blood Group, Total Cholesterol, Triglycerides, Fasting Blood Sugar, Ultrasound Whole Abdomen , Glycosylated Haemoglobin (hba1c), Hdl, Vldl, Urine Analysis, LDL, Total Protine, General Consultation, HDL/ LDL ratio, GGT(Gamma-glutamyl Transferase), Eye Check-up consultation, ALP (ALKALINE PHOSPHATASE), Uric Acid, AST/ALT Ratio, Serum Protein, CBC with ESR, Stool Analysis, Urine Sugar Fasting, Urine Sugar PP, T3, T4, Cholesterol Total / HDL Ratio, BUN, BUN/Creatinine Ratio, Bilirubin Total & Direct and Indirect, Albumin, Globulin

**Dr. Dinesh S. Modh**

M.D., D.M.R.E. (Radiodiagnosis)  
Consultant Radiologist & Sonologist  
Ex. Junior Lecturer, B.J. Medical College, Civil Hospital, A'bad.  
Panel Doctor of L.I.C.



08/07/2022

Alcha Gajastava  
35 years / Female

Height :- 153 cm

Weight :- 63 kg

BP :- 114/78 mmHg

Pulse :- 80 per min

SpO2 :- 98

T :- @

RS } @

CVS }

Asymptomatic

H/o Thyroid since 6 yr  
taking Tab. Thyronorm 50mg.

NO H/o DM, HTN & TB

Eyecheckup! -

6/6 normal vision in both eye  
N/6 normal vision in both eye  
No night & color blindness

**Vidhi Diagnostics**

L-86, Swatantra-Senani Nagar,  
Opp. Akhbarnagar Bus Terminals,  
Nr. Akhbarnagar Circle,  
New Wadaj, Ahmedabad-13, Vidhi Imaging Center

Dr. Vidhi D. Modh  
MBBS  
Reg. No. G-74540

L-86, Swatantra Senani Nagar, Opp. Akhbarnagar Petrol Pump, Nr. Akhbarnagar Circle, Nava-Vadaj, Ahmedabad - 380 013.

Phone : 079-2762 1406, Mobile : 98799 29406, 98250 09406, E-mail : vidhidiagnostics@gmail.com, Website : www.vidhidiagnostics.com

Time : Mon. to Sat. 9.00 am to 2.00 pm, 5.00 pm to 9.00 pm, Sunday 9.00 am to 12.00 Noon

FACILITIES : Live 3D-4D Sonography | Colour Doppler | Echo Cardiography | Interventional Radiology | Fetal Medicine | Digital X-Ray  
Digital Mammography | Digital OPG / TMJ | ECG / TMT / PFT / EEG / EMG | Pathology Laboratory | Health Check Up Plans | Pre Employment Check Up

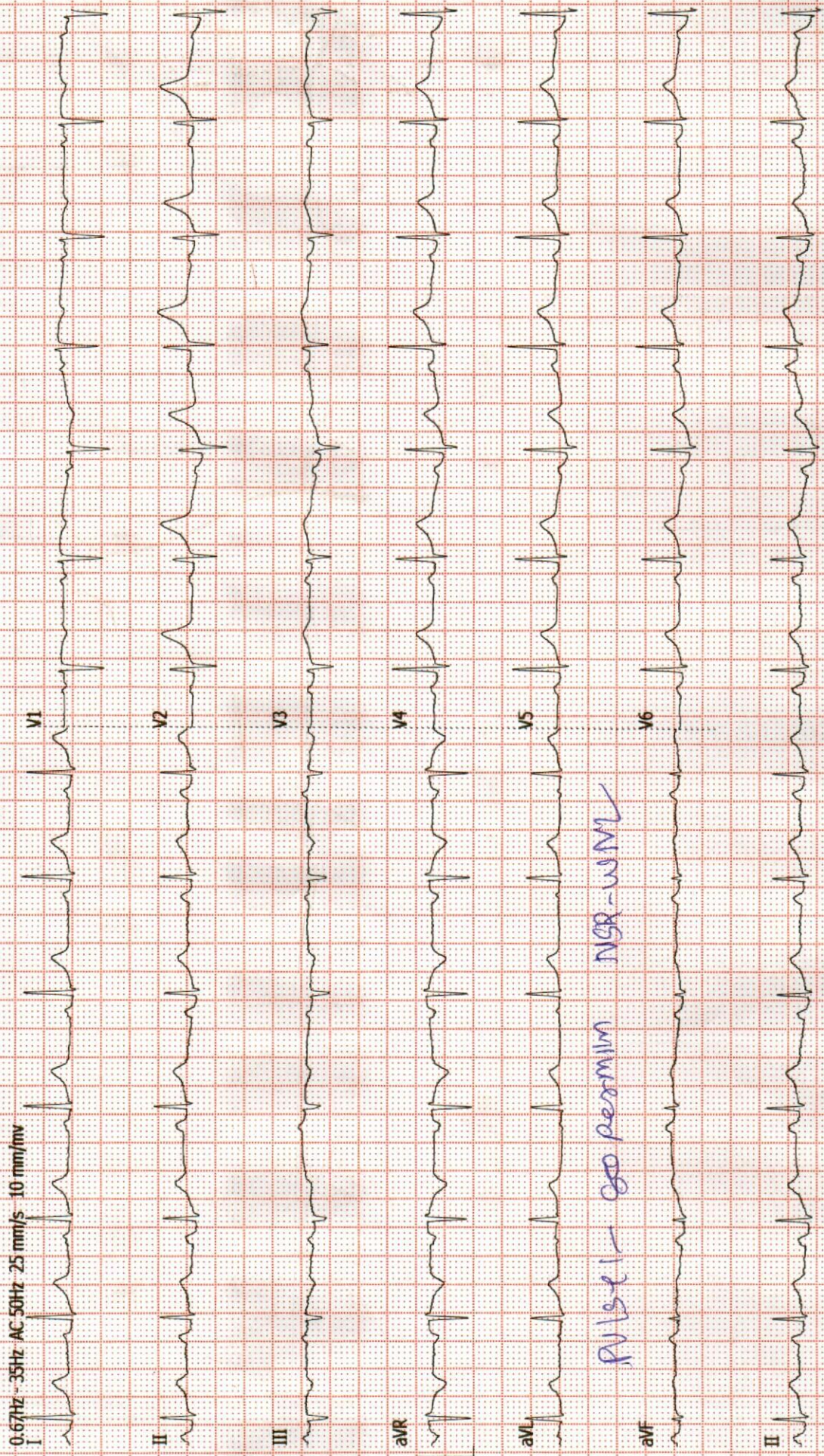
HR : 80 bpm  
 PR : 144 ms  
 QRS : 70 ms  
 QT/QTc : 352/406 ms  
 P/QRS/T : 52/8/20 deg.  
 RV5/SV1 : 0.811/-0.696 mv  
 RV5+SV1 : 1.507 mv

\*\* atypical ECG \*\*  
 Sinus rhythm  
 Low QRS voltage in chest leads

Dr. Avinash Bhaskar  
 MBBS, B Cardiol  
 Reg. No.: G-45946

**Vidhi Diagnostics**  
 I-86, Swatantra-Senani Nagar,  
 Opp. Akhbarnagar Bus Terminals,  
 Nr. Akhbarnagar Circle,  
 Malad West, Mumbai-400052

Need to be confirmed by Doctor. Doctor Name:



Pulse - 80 Permin NGR-WML

## Dr. Dinesh S. Modh

M.D., D.M.R.E. (Radiodiagnosis)

Consultant Radiologist & Sonologist

Ex. Junior Lecturer, B.J. Medical College, Civil Hospital, A'bad.

Panel Doctor of L.I.C.



Patient's name : RICHA SRIVASTAV  
Reg. ID : R-3921-21  
Referred by : Dr. MEDIWHEEL

Age/Sex : 35 Years/Female  
Accession : 17629  
Date : 08/07/2022

### X-RAY CHEST (PA VIEW)

Both lung fields appear normal.  
No e/o consolidation or cavitations is seen.  
Both costo-phrenic angles appear clear.  
Cardiac size is with in normal limits.  
Both domes of diaphragm appear normal.  
Bony thoracic cage appears normal.

Thanks for reference.

  
Dr. Dinesh S. Modh  
MD DMRE (Radiodiagnosis)  
G-23825  
DR DINESH S. MODH  
M.D. DMRE(RADIODIAGNOSIS)

ISO 9001:2015 Certified Diagnostics Center

Vidhi Imaging Center

L-86, Swatantra Senani Nagar, Opp. Akhbarnagar Petrol Pump, Nr. Akhbarnagar Circle, Nava-Vadaj, Ahmedabad - 380 013.

Phone : 079-2762 1406, Mobile : 98799 29406, 98250 09406, E-mail : vidhidiagnostics@gmail.com, Website : www.vidhidiagnostics.com

Time : Mon. to Sat. 9.00 am to 2.00 pm, 5.00 pm to 9.00 pm, Sunday 9.00 am to 12.00 Noon

FACILITIES : Live 3D-4D Sonography | Colour Doppler | Echo Cardiography | Interventional Radiology | Fetal Medicine | Digital X-Ray  
Digital Mammography | Digital OPG / TMJ | ECG / TMT / PFT / EEG / EMG | Pathology Laboratory | Health Check Up Plans | Pre Employment Check Up

## Dr. Dinesh S. Modh

M.D., D.M.R.E. (Radiodiagnosis)

Consultant Radiologist & Sonologist

Ex. Junior Lecturer, B.J. Medical College, Civil Hospital, A'bad.

Panel Doctor of L.I.C.



Patient's name: RICHA SRIVASTAV  
Reg. ID : R-3921-21  
Referred by : Dr. MEDIWHEEL

Age/Sex : 35 Years/Female  
Accession : 17629  
Date : 08/07/2022

### USG ABDOMEN

LIVER: - Liver appears normal in size & show normal echotexture. No evidence of diffuse or focal lesion is seen. Intrahepatic biliary radicals appear normal. Portal vein and CBD appear normal. No e/o calculus is seen in bile duct.

GALL BLADDER: - Gall bladder is distended & appears normal. No evidence of calculus or cholecystitis is seen. No evidence of pericholecystic fluid is seen.

SPLEEN: - Spleen appears normal in size & shows normal echotexture. No evidence of diffuse or focal lesion is seen.

PANCREAS: - Pancreas appears normal size and echopattern. No e/o diffuse or focal lesion is seen. Main pancreatic duct appears normal.

KIDNEY: - Both Kidneys appear normal in size & echotexture.

No e/o calculus or hydronephrosis or hydroureter is seen in either side.

Cortico-medullary differentiation is maintained on either side.

Both suprarenal regions appear normal.

RIF & BOWEL LOOPS (By high frequency probe): - Normal.

No evidence of pre & para aortic lymphadenopathy is seen.

No evidence of free fluid is seen in abdomen.

No evidence of dilated or thickened bowel loops is seen.

Urinary bladder: - appears normal. No e/o calculus or mass lesion is seen in bladder.

Uterus appears normal in size and echopattern.

No evidence of diffuse or focal lesion is seen.

Cervical region appears normal.

Endometrial thickness is 6.4mm.

Both ovaries and adnexal regions appear normal.

No e/o free fluid is seen in pouch of Douglas.

Thanks for reference.

  
Dr. Dinesh S. Modh  
MD DMRE (Radiodiagnosis)  
G-23825

DR DINESH S. MODH

M.D. DMRE(RADIODIAGNOSIS)

ISO 9001:2015 Certified Diagnostics Center

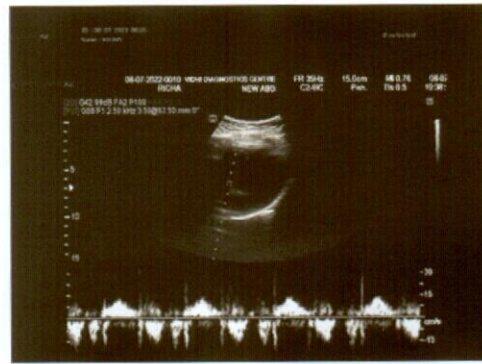
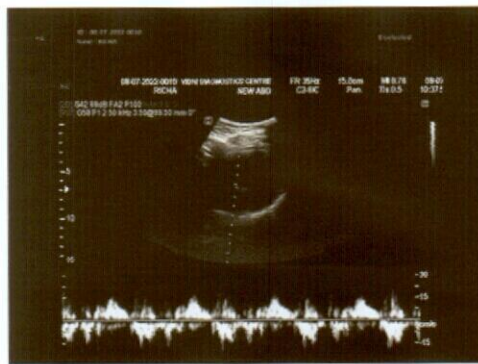
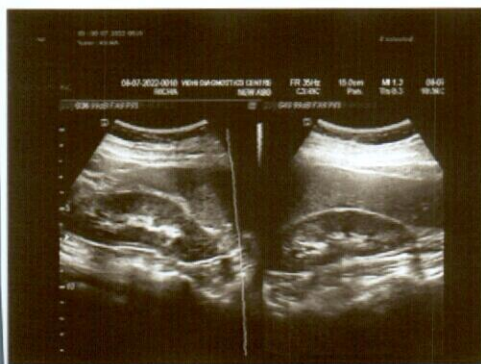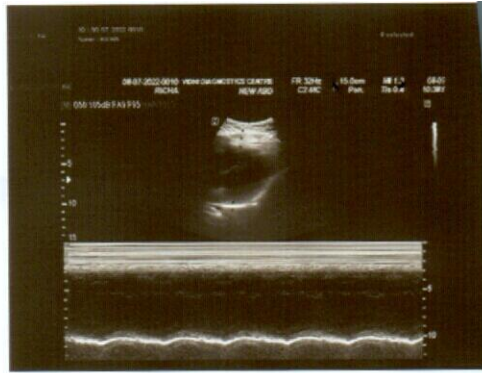
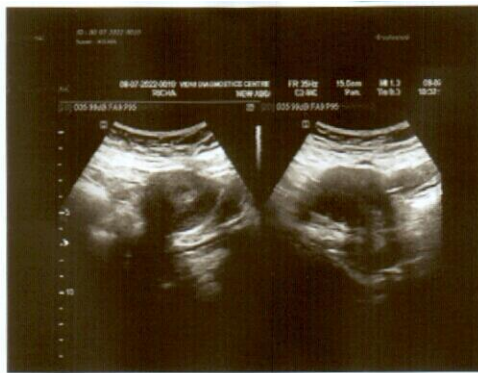
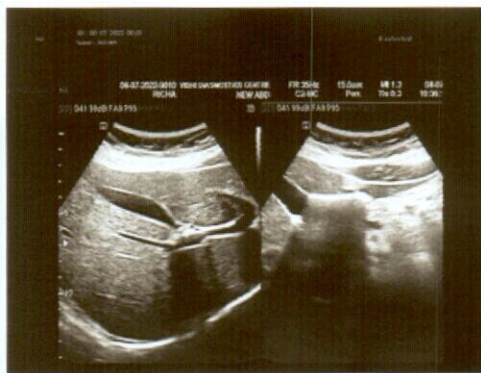
Vidhi Imaging Center

L-86, Swatantra Senani Nagar, Opp. Akhbarnagar Petrol Pump, Nr. Akhbarnagar Circle, Nava-Vadaj, Ahmedabad - 380 013.

Phone : 079-2762 1406, Mobile : 98799 29406, 98250 09406, E-mail : vidhidiagnostics@gmail.com, Website : www.vidhidiagnostics.com

Time : Mon. to Sat. 9.00 am to 2.00 pm, 5.00 pm to 9.00 pm, Sunday 9.00 am to 12.00 Noon

FACILITIES : Live 3D-4D Sonography | Colour Doppler | Echo Cardiography | Interventional Radiology | Fetal Medicine | Digital X-Ray  
Digital Mammography | Digital OPG/TMJ | ECG/TMT/PFT/EEG/EMG | Pathology Laboratory | Health Check Up Plans | Pre Employment Check Up



## Dr. Dinesh S. Modh

M.D., D.M.R.E. (Radiodiagnosis)

Consultant Radiologist & Sonologist

Ex. Junior Lecturer, B.J. Medical College, Civil Hospital, A'bad.

Panel Doctor of L.I.C.



Patient's name: RICHA SRIVASTAV  
Reg. ID : R-3921-21  
Referred by : Dr. MEDIWHEEL

Age/Sex : 35 Years/Female  
Accession : 17629  
Date : 08/07/2022

### 2D- ECHO REPORT

#### FINAL CONCLUSION:

LV IS NORMAL SIZE. GOOD LV SYSTOLIC FUNCTION NO RWMA.  
LVEF - 60%. NO CONCENTRIC LVH.  
NORMAL LV COMPLIANCE.  
LA IS NORMAL SIZE. NO LA CLOT.  
RV IS NORMAL SIZE. GOOD RV SYSTOLIC FUNCTION.  
RA IS NORMAL SIZE.  
MITRAL VALVE IS NORMAL. NO MS. NO MR . NO MVP.  
AORTIC VALVE IS NORMAL. NO AS. NO AR.  
TRICUSPID VALVE IS NORMAL. NO TR. RVSP-24 mmHg. NO PAH.

NO CLOT, NO VEGETATION, NO PERICARDIAL EFFUSION.

#### DIMENSIONS:

AORTA	2.6 C.M
LEFT ATRIUM	2.7 C.M
LVDD	4.1 C.M.
IVSD	1.0 C.M
PWD	1.0 C.M
LVDS	2.6 C.M.

#### COLOUR DOPPLER FINDING:

STRUCTURE	VELOCITY m/sec
	Max
PULMONARY VALVE	0.7
MITRAL VALVE	E : 0.7 A: 0.4
AORTIC VALVE	1.0

*Dr. Avinash Bhaskar*  
MBBS. D Cardio  
Reg. No.: G-45946

**DR AVINASH BHASKAR**

ISO 9001:2015 Certified Diagnostics Center

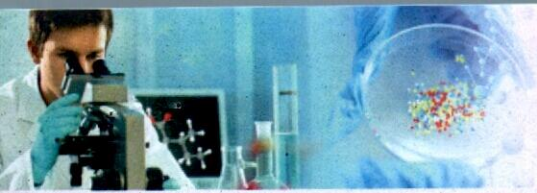Vidhi Imaging Center

L-86, Swatantra Senani Nagar, Opp. Akhbarnagar Petrol Pump, Nr. Akhbarnagar Circle, Nava-Vadaj, Ahmedabad - 380 013.

Phone : 079-2762 1406, Mobile : 98799 29406, 98250 09406, E-mail : vidhidiagnostics@gmail.com, Website : www.vidhidiagnostics.com

Time : Mon. to Sat. 9.00 am to 2.00 pm, 5.00 pm to 9.00 pm, Sunday 9.00 am to 12.00 Noon

FACILITIES : Live 3D-4D Sonography | Colour Doppler | Echo Cardiography | Interventional Radiology | Fetal Medicine | Digital X-Ray  
Digital Mammography | Digital OPG / TMJ | ECG / TMT / PFT / EEG / EMG | Pathology Laboratory | Health Check Up Plans | Pre Employment Check Up



Pathology Department



Patient's name : RICHA SRIVASTAV  
Age/Sex : 35 Years/Female  
Referred by : Dr. MEDIWHEEL  
Collection Time : 09:51

Reg. ID : P-2470-21  
Accession : 17615  
Order Dt/time : 08/07/2022 09:51

**Complete Blood Count**

Sample Type: EDTA

Test Name	Result	Units	Biological Reference Interval
<b><u>Blood Counts</u></b>			
Haemoglobin :	13.1	Gms%	12.5 - 16.0
Total R.B.C. :	<b>4.16</b>	mill/c.mm	4.2 - 5.4
Total W. B. C. :	5,780	/cu mm	4000 - 10500
Platelet Count :	1,68,000	/cu.mm	1,50,000 - 4,50,000
<b><u>Differential Count</u></b>			
Neutrophils :	67	%	40 - 70
Lymphocytes :	28	%	20 - 40
Eosinophils :	03	%	1 - 4
Monocytes :	02	%	2 - 6
Basophils :	00	%	0 - 01
<b><u>Blood Indices</u></b>			
P. C. V :	39.6	%	37 - 47
M. C. V. :	95.2	fl	78 - 100
M.C.H :	<b>31.5</b>	pg	27 - 31
M. C. H. C :	33.1	%	32 - 36
R.D.W :	14.0	%	11.5 - 14.0
<b><u>E.S.R.( Westergren Method )</u></b>			
After one hour :	06	mm/hr	3 - 12

TESTS DONE ON FULLY AUTOMATED HEMATOLOGY ANALYZER.

*Dr. Gayatri M. Mehta*  
M. D. (Patho)

DR. GAYATRI MEHTA  
MD(PATHOLOGY)

DR. ANAND D. PARIKH  
MD(PATHOLOGY)

LAB USE ONLY (Entered by :GM Enter Date/Time:08/07/2022 11:34:00 AM) (Verify by :GM Verify Date/Time:08/07/2022 11:34:00 AM)

ISO 9001:2015 Certified Diagnostics Center  
Vidhi Imaging Center | Pathology Department

L-86, Swatantra Senani Nagar, Opp. Akhbarnagar Petrol Pump, Nr. Akhbarnagar Circle, Nava-Vadaj, Ahmedabad - 380 013.

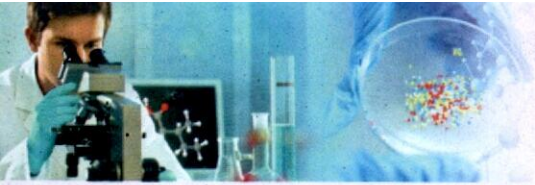Ph. (Pathology) : 079-2764 5405, 8849893954 M. 98799 29406, 98250 09406, E-mail : vidhidiagnostics@gmail.com, Web. : www.vidhidiagnostics.com

Time (Pathology) : Mon. to Sat. 8.30 am to 8.00 pm, Sunday 9 am to 12 Noon

*Pathology means science behind medicine*

**CT SCAN & CBCT FACILITY NOW AVAILABLE**





Pathology Department



Patient's name : RICHA SRIVASTAV  
Age/Sex : 35 Years/Female  
Referred by : Dr. MEDIWHEEL  
Collection Time : 09:51

Reg. ID : P-2470-21  
Accession : 17615  
Order Dt/time : 08/07/2022 09:51

### Blood Group

Sample Type: EDTA sample.

Test Name	Result
BG :	" A "
RH :	NEGATIVE
Remarks	Done by forward grouping method.

### Blood Glucose

Sample Type: Serum

Test Name	Result	Units	Biological Reference Interval
Fasting Blood Glucose : <i>GOD-POD Method.</i>	97.8	mg/dl	70 - 110

*Dr. Gayatri M. Mehta*  
M. D. (Patho)

Reg. No. G-32215  
DR GAYATRI MEHTA  
MD(PATHOLOGY)

DR. ANAND D. PARIKH  
MD(PATHOLOGY)

LAB USE ONLY (Entered by : GM Enter Date/Time:08/07/2022 3:53:00 PM) (Verify by : GM Verify Date/Time:08/07/2022 3:53:00 PM)

ISO 9001:2015 Certified Diagnostics Center  
Vidhi Imaging Center | Pathology Department

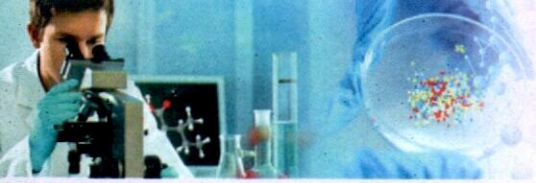L-86, Swatantra Senani Nagar, Opp. Akhbarnagar Petrol Pump, Nr. Akhbarnagar Circle, Nava-Vadaj, Ahmedabad - 380 013.

Ph. (Pathology) : 079-2764 5405, 8849893954 M. 98799 29406, 98250 09406, E-mail : vidhidiagnostics@gmail.com, Web. : www.vidhidiagnostics.com

Time (Pathology) : Mon. to Sat. 8.30 am to 8.00 pm, Sunday 9 am to 12 Noon

*Pathology means science behind medicine*

**CT SCAN & CBCT FACILITY NOW AVAILABLE**



Pathology Department



Patient's name : RICHA SRIVASTAV  
Age/Sex : 35 Years/Female  
Referred by : Dr. MEDIWHEEL  
Collection Time : 09:51

Reg. ID : P-2470-21  
Accession : 17615  
Order Dt/time : 08/07/2022 09:51

### Lipid Profile

Sample Type: Serum

Test Name	Result	Units	Biological Reference Interval
<b>S. Cholesterol :</b> Oxidase-esterase method.	182.0	mg/dl	0 - 200
<b>S. Triglyceride :</b> Enzymatic Colorimetry method	133.4	mg/dL	0 - 200
<b>S. HDL - Cholesterol :</b> Serum by Enzymatic method.	43.2	mg/dL	35 - 65
<b>S. LDL - Cholesterol :</b> Serum by Enzymatic method	112.12	mg/dL	0 - 130
<b>S. VLDL - Cholesterol :</b>	26.68	mg/dL	0 - 30
<b>S. Chole/HDL.Ratio :</b>	4.21		1 - 6
<b>S. LDL / HDL Cholesterol Ratio :</b>	2.6		0 - 3.5

*Dr. Gayatri M. Mehta*  
M. D. (Patho)

Reg. No. G-32215  
DR GAYATRI MEHTA  
MD(PATHOLOGY)

DR. ANAND D. PARIKH  
MD(PATHOLOGY)

LAB USE ONLY (Entered by :GM Enter Date/Time:08/07/2022 3:54:00 PM) (Verify by :GM Verify Date/Time:08/07/2022 3:54:00 PM)

ISO 9001:2015 Certified Diagnostics Center  
Vidhi Imaging Center | Pathology Department

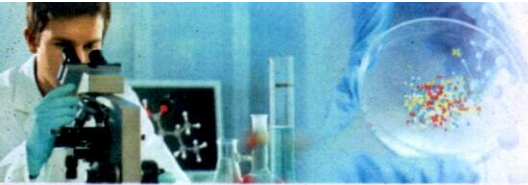L-86, Swatantra Senani Nagar, Opp. Akhbarnagar Petrol Pump, Nr. Akhbarnagar Circle, Nava-Vadaj, Ahmedabad - 380 013.

Ph. (Pathology) : 079-2764 5405, 8849893954 M. 98799 29406, 98250 09406, E-mail : vidhidiagnostics@gmail.com, Web. : www.vidhidiagnostics.com

Time (Pathology) : Mon. to Sat. 8.30 am to 8.00 pm, Sunday 9 am to 12 Noon

*Pathology means science behind medicine*

**CT SCAN & CBCT FACILITY NOW AVAILABLE**



Pathology Department



Patient's name : RICHA SRIVASTAV  
Age/Sex : 35 Years/Female  
Referred by : Dr. MEDIWHEEL  
Collection Time : 09:51

Reg. ID : P-2470-21  
Accession : 17615  
Order Dt/time : 08/07/2022 09:51

### HbA1C

Sample Type: Serum

Test Name	Result	Units	Biological Reference Interval
HbA1C :	4.5	%	Non-diabetic: 4.2-6.2 Pre-diabetic : 6.3-7.2 Diabetic : 7.3-8.2
Mean Blood Glucose of Last 03 months.	82.45	mg/dl	

**Comment**

\*As per the new 2009 update of American Diabetes Association regarding HbA1C & Mean Blood Glucose relationship.

**NOTE:**

This test is used to monitor diabetic patients compliance with the therapeutic regimen and logo It's level is proportional to both the average blood glucose concentration and the life span of the red blood cells (RBC) in circulation. HbA1c values are free of day to day glucose fluctuations and are unaffected by exercise or recent food intake.

*Dr. Gayatri M. Mehta*  
M. D. (Patho)

DR. GAYATRI MEHTA  
MD(PATHOLOGY)

DR. ANAND D. PARIKH  
MD(PATHOLOGY)

LAB USE ONLY (Entered by :GM Enter Date/Time:08/07/2022 3:53:00 PM) (Verify by :GM Verify Date/Time:08/07/2022 3:53:00 PM)

ISO 9001:2015 Certified Diagnostics Center  
Vidhi Imaging Center | Pathology Department

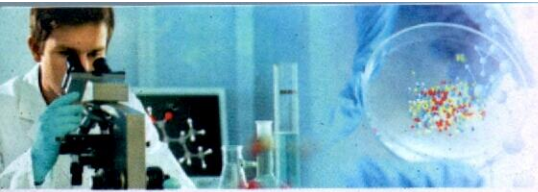L-86, Swatantra Senani Nagar, Opp. Akhbarnagar Petrol Pump, Nr. Akhbarnagar Circle, Nava-Vadaj, Ahmedabad - 380 013.

Ph. (Pathology) : 079-2764 5405, 8849893954 M. 98799 29406, 98250 09406, E-mail : vidhidiagnostics@gmail.com, Web. : www.vidhidiagnostics.com

Time (Pathology) : Mon. to Sat. 8.30 am to 8.00 pm, Sunday 9 am to 12 Noon

*Pathology means science behind medicine*

**CT SCAN & CBCT FACILITY NOW AVAILABLE**



Pathology Department

Patient's name : RICHA SRIVASTAV  
Age/Sex : 35 Years/Female  
Referred by : Dr. MEDIWHEEL  
Collection Time : 09:51

Reg. ID : P-2470-21  
Accession : 17615  
Order Dt/time : 08/07/2022 09:51

**BIOCHEMISTRY**

Sample type :Serum

Test Name	Result	Units	Biological Reference Interval
<b>Urea</b> , (Serum by GLDH method) :	23.8	mg/dl	10 - 50
<b>S.Uric acid</b> , (Serum by Uricase method) :	<b>6.6</b>	mg/dl	2.6-6.0
<b>Bun</b> :	11.1	mg/dl	6-20
<b>Creatinine</b> , (Serum by Enzymatic reaction) :	0.73	mg/dl	0.5-1.2
<b>S.G.P.T (ALT)</b> : (Serum by IFCC method)	14.7	U/L	0 - 40
<b>S.G.O.T (AST)</b> : (Serum by IFCC method)	16.7	U/L	0 - 37
<b>ALK.PHOSPHATASE</b> : (Serum by PNP method)	103.0	U/L	35-104
<b>G.G.T</b> :	10.2	U/L	8 - 78
<b><u>BILIRUBIN</u></b>			
<b>Total</b> :	0.73	mg/dl	Up to 1.2
<b>Direct</b> :	0.31	mg/dl	0-0.7
<b>Indirect</b> :	0.42	mg/dl	0 - 0.5
<b><u>SERUM PROTEINS</u></b>			
<b>Total Protein</b> (Serum by Biuret method) :	7.78	gms/dl	
<b>Albumin</b> (Serum by BCG method) :	4.33	gms/dl	3.97-4.94
<b>Globulins</b> :	3.45	gms/dl	2.3 - 3.5
<b>A/G Ratio</b> :	1.255		0.9 - 2.9

*Dr. Gayatri M. Mehta*  
M. D. (Patho)

Reg. No. G-32215

DR GAYATRI MEHTA  
MD(PATHOLOGY)

DR.ANAND D.PARIKH  
MD(PATHOLOGY)

LAB USE ONLY (Entered by :GM Enter Date/Time:08/07/2022 3:53:00 PM) (Verify by :GM Verify Date/Time:08/07/2022 3:53:00 PM)

ISO 9001:2015 Certified Diagnostics Center  
Vidhi Imaging Center | Pathology Department

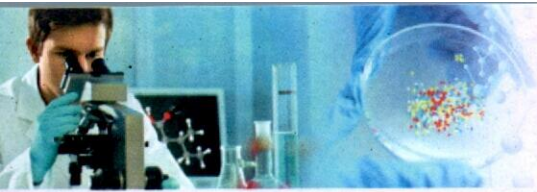L-86, Swatantra Senani Nagar, Opp. Akharnagar Petrol Pump, Nr. Akharnagar Circle, Nava-Vadaj, Ahmedabad - 380 013.

Ph. (Pathology) : 079-2764 5405, 8849893954 M. 98799 29406, 98250 09406, E-mail : vidhidiagnostics@gmail.com, Web. : www.vidhidiagnostics.com

Time (Pathology) : Mon. to Sat. 8.30 am to 8.00 pm, Sunday 9 am to 12 Noon

*Pathology means science behind medicine*

**CT SCAN & CBCT FACILITY NOW AVAILABLE**



Pathology Department



Patient's name : RICHA SRIVASTAV  
Age/Sex : 35 Years/Female  
Referred by : Dr. MEDIWHEEL  
Collection Time : 09:51

Reg. ID : P-2470-21  
Accession : 17615  
Order Dt/time : 08/07/2022 09:51

### Thyroid Function Test

Sample Type: Serum

Test Name	Result	Units	Biological Reference Interval
TOTAL T3 :	1.36	ng/ml	0.84 - 2.0
TOTAL T4 :	10.87	ug/dl	5.1 - 14.0
TSH(Ultra sensitive) :	4.119	mIU/L	0.27 - 4.2
Method	Electrochemiluminescence Immunoassay "ECLIA"		

Test done on Roche Cobas e411 Immunoassay Analyser

*Dr. Gayatri M. Mehta*

M. D. (Patho)

DR. GAYATRI MEHTA  
MD(PATHOLOGY) 82215

DR. ANAND D. PARIKH  
MD(PATHOLOGY)

LAB USE ONLY (Entered by :GM Enter Date/Time:08/07/2022 3:54:00 PM) (Verify by :GM Verify Date/Time:08/07/2022 3:54:00 PM)

ISO 9001:2015 Certified Diagnostics Center

Vidhi Imaging Center | Pathology Department

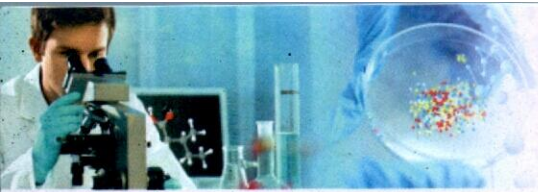L-86, Swatantra Senani Nagar, Opp. Akharnagar Petrol Pump, Nr. Akharnagar Circle, Nava-Vadaj, Ahmedabad - 380 013.

Ph. (Pathology) : 079-2764 5405, 8849893954 M. 98799 29406, 98250 09406, E-mail : vidhidiagnostics@gmail.com, Web. : www.vidhidiagnostics.com

Time (Pathology) : Mon. to Sat. 8.30 am to 8.00 pm, Sunday 9 am to 12 Noon

*Pathology means science behind medicine*

**CT SCAN & CBCT FACILITY NOW AVAILABLE**



Patient's name : RICHA SRIVASTAV  
Age/Sex : 35 Years/Female  
Referred by : Dr. MEDIWHEEL  
Collection Time : 09:51

Reg. ID : P-2470-21  
Accession : 17615  
Order Dt/time : 08/07/2022 09:51

**Urine Analysis**

Sample Type: Urine

Test Name	Result	Units	Biological Reference Interval
<b><u>Physical Examination</u></b>			
Quantity :	30	ml	0 - 500 ml
Colour :	Pale Yellow		Pale Yellow
Transparency :	Slight Turbid.		Clear
Reaction :	Acidic		4.6 - 8.0
Specific Gravity :	1.030		1.016 - 1.022
Sediment :	Present		
<b><u>Chemical Examination</u></b>			
Albumin :	Present (Trace)		Absent
Sugar :	NIL		Absent
Acetone :	Absent		Absent
Bile Salts :	Absent		Absent
Bile Pigments :	Absent		Absent
Urobilogen :	Absent		Absent
Nitrites :	Absent		Absent
<b><u>Microscopic Examination</u></b>			
Red blood Cells :	2-3	/h.p.f	Absent
Pus Cells :	1-2	/h.p.f	Absent
Epithelial Cells :	2-3	/h.p.f	< 10.0
Amorphous :	Absent	/h.p.f	Absent
Bacteria :	Absent	/h.p.f	Absent
Crystals :	Absent	/h.p.f	Absent
Casts :	Absent	/h.p.f	Absent
Fungus :	Not seen	/h.p.f	Absent

*Dr. Gayatri M. Mehta*  
M. D. (Patho)

Reg. No. G-32215

DR GAYATRI MEHTA  
MD(PATHOLOGY)

DR. ANAND D. PARIKH  
MD(PATHOLOGY)

ISO 9001:2015 Certified Diagnostics Center  
LAB USE ONLY (Entered by :GM Enter Date/Time:08/07/2022 3:54:00 PM) (Verify by :GM Verify Date/Time:08/07/2022 3:54:00 PM)

L-86, Swatantra Senani Nagar, Opp. Akharnagar Petrol Pump, Nr. Akharnagar Circle, Nava-Vadaj, Ahmedabad - 380 013.

Ph. (Pathology) : 079-2764 5405, 8849893954 M. 98799 29406, 98250 09406, E-mail : vidhidiagnostics@gmail.com, Web. : www.vidhidiagnostics.com

Time (Pathology) : Mon. to Sat. 8.30 am to 8.00 pm, Sunday 9 am to 12 Noon

*Pathology means science behind medicine*

**CT SCAN & CBCT FACILITY NOW AVAILABLE**



सत्यमेव जयते  
भारत सरकार



आधार

भारतीय विशिष्ट पहचान प्राधिकरण

भारत सरकार

Unique Identification Authority of India  
Government of India

नामांकन क्रमांक/Enrolment No.: 1207/00683/08549

To: Richa Srivastava  
(ऋचा श्रीवास्तव)  
D/O Chanda Srivastava  
958  
deva road  
nanakau kothi  
durga puri  
Nawabganj  
Barabanki  
Uttar Pradesh - 225001

Date: 27/09/2011

Ref. No : 00017768-00089562-00088137-



UB 05322066 6 IN

आपका आधार क्रमांक / Your Aadhaar No. :

**7206 2860 7762**

**आधार — आम आदमी का अधिकार**

*Richa Srivastava*



भारत सरकार  
GOVERNMENT OF INDIA



ऋचा श्रीवास्तव  
Richa Srivastava  
जन्म वर्ष / Year of Birth : 1987  
महिला / Female


7206 2860 7762



Dr. Vidhi D. Modh  
MBBS  
Reg. No. G-74540


**Vidhi Diagnostics**  
L-86, Swatantra-Senani Nagar  
Opp. Akhbarnagar Bus Terminal  
Nr. Akhbarnagar Circle  
New Wadaj, Ahmedabad-13.

**आधार — आम आदमी का अधिकार**



**Vidhi Diagnostics**  
L-56, Swatantra-Senani Nagar,  
Ok Akhbarnagar Bus Terminals,  
Nr. Alhbarnagar Circle,  
New Wadaj, Ahmedabad-13.

Dr. Vidhi D. Modh  
MBBS  
Reg. No. G-74540



KHBAR N.

**Ahmedabad, Gujarat, India**

15, Pragatinagar, Nirnay Nagar, Ahmedabad,  
Gujarat 380061, India

Lat 23.068099°

Long 72.56171°

08/07/22 10:24 AM

Google

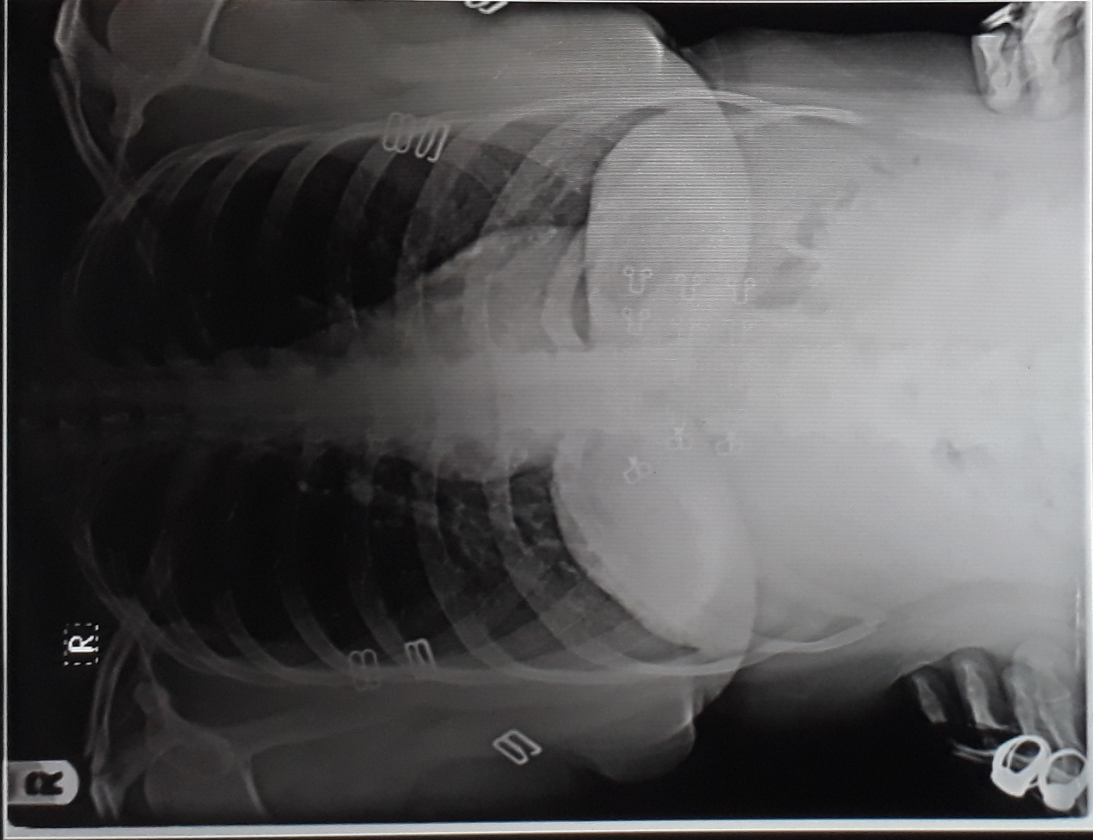
GPS Map Camera

M-Fit 1117



RICHA SRIVASTAVA 35 YRS

08072206



Navigation and control buttons: MA, G+, G-, S, and a zoom-in icon.

Navigation and control buttons: a left arrow, a button with '1 (1)', a right arrow, a red 'X' button, a magnifying glass icon, an 'ALL' button with a circular arrow, a key icon, a square icon, and a zoom-out icon.

DELL

bestel