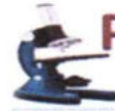

Facilities:

All clinical Biomedical & Hematology Investigations including Bone Marrow Examination
VPT, Podiascan & Complete Foot Care (First Time in Purvanchal)
All Hormonal Investigation by Chemiluminescent Method
Visceral Fat by (AB-140) Ambulatory BP Monitoring
CGMS & Insulin Pump Available
PFT, 2D-ECHO (Color Doppler), Holter, TMT, Cardiac-3 available
VIA, VILI, Colposcopy available
Special Endocrinological Investigation Protocols.



Panacea Pathology

Clinical Reference Lab

Persistence, Preparedness and Precision
EQAS (CMC Vellore Attached) & IQAS System
पूर्वांचल की सर्वोत्तम गुणवत्ता वाली पैथोलॉजी

PATIENT NAME : PRAVEEN ANIL KUMAR

AGE/GENDER : 39YRS/MALE

REFD BY DR. : ARCO FEMI HEALTHCARE LTD.

RECEIVED DATE : 25-01-2023 (10:00 AM)

SAMPLE : BLOOD & URINE

REPORT DATE : 25-01-2023 (06:00 PM)

PATHOLOGY REPORT

COMPLETE BLOOD COUNT (CBC)

TEST	LAB TEST VALUES	NORMAL RANGE
HEMOGRAM		
HEMOGLOBIN (FLOW CYTOMETRY)	14.2	13 – 16 gm/dl
TOTAL LEUCOCYTE COUNT (TLC)	8,500	4000 – 11000
RBC COUNT	4.43	3.5 – 5.5
PCV (HCT)	42.7	37 – 47
MCV	96.3	80 – 95
MCH	32.1	28 – 34
MCHC	33.3	30 – 36
PLATELET COUNT	1,54,000	1,50,000 – 4,00,000
E.S.R. (WINTROBE FIRST HOURS)	10.0	20 mm/1 st hr
DIFFERENTIAL LEUCOCYTE		
NEUTROPHILS	57	40 – 75%
LYMPHOCYTES	38	20 – 45%
EOSINOPHILS	03	.1 – 6%
MONOCYTES	02	2 – 8%
BASOPHILS	00	< 2%

RENAL & KIDNEY PROFILE, SERUM

TEST	LAB TEST VALUES	NORMAL RANGE
RENAL FUNCTION TESTS		
BLOOD UREA NITROGEN (BUN)	12.0	10 – 50 mg/dl
SERUM CREATININE	0.90	0.60 – 1.60 mg/dl
URIC ACID	4.16	3.60 – 7.70 mg/dl
ALKALINE PHOSPHATASE (ALP)	115.6	142 – 353 mg/dl
TOTAL PROTIENS	7.42	0 – 39 mg/dl
ALBUMIN	4.12	3.8 – 5.4 mg/dl
SERUM GLOBULIN	3.30	2.1 – 3.5 mg/dl
CALCIUM	8.9	8.80 – 10.20
PHOSPHORUS	3.04	2.50 – 5.00
SERUM SODIUM NA+	1.005	135.00 – 155.00 mEq/Ltr
SERUM POTASIAM K+	4.12	3.60 – 5.50 mEq/Ltr
ICALCIUM	1.22	1.10 – 1.35 mmol/L
SERUM CHLORIDE CL+	101.3	98.00 – 110.00 mEq/Ltr

PAGE 1

Lab Technician

PANACEA HOSPITAL
UNIT OF AAROH HEALTH CARE PVT. LTD.
REG. NO.: AL-1500
B.30/44, KABIR NAGAR
DURGAKUND, VARANASI

Timing : 8.00 a.m. to 9.00 p.m. (Sunday 8.00 a.m. to 3.00 p.m.)

This Report is not valid for medico legal purpose

Note: These tests have technical limitations. Clinico-pathological interpretation is necessary. In case of any disparity test may be repeated immediately.

Address : 36/44 FK Kabir Nagar, Durgakund, Varanasi – 221005

Email: dramishra@gmail.com, drpallaviojha@gmail.com Website: panaceahospital.org

Facilities:

All clinical Biomedical & Hematology Investigations including Bone Marrow Examination
 VPT, Podiascan & Complete Foot Care (First Time in Purvanchal)
 All Hormonal Investigation by Chemiluminescent Method
 Visceral Fat by (AB-140) Ambulatory BP Monitoring
 CGMS & Insulin Pump Available
 PFT, 2D-ECHO (Color Doppler), Holter, TMT, Cardiac-3 available
 VIA, VILI, Colposcopy available
 Special Endocrinological Investigation Protocols.

ISO 9001:2008 Certified
 Mobile: 9389994334, 9554572190, 9453837595



Panacea Pathology

Clinical Reference Lab

Persistence, Preparedness and Precision
 EQAS (CMC Vellore Attached) & IQAS System
 पूर्वांचल की सर्वोत्तम गुणवत्ता वाली पैथोलॉजी

PATIENT NAME : PRAVEEN ANIL KUMAR	AGE/GENDER : 39YRS/MALE
REFD BY DR. : ARCO FEMI HEALTHCARE LTD.	RECEIVED DATE :25-01-2023 (10:00 AM)
SAMPLE : BLOOD & URINE	REPORT DATE : 25-01-2023 (06:00 PM)

PATHOLOGY REPORT

LIPID PROFILE, SERUM

TEST	LAB TEST VALUES	NORMAL RANGE
BLOOD CHEMISTRY		
TOTAL CHOLESTEROL (SERUM)	178.0	Desirable:- < 200 mg/dl Borderline:- 200 – 239 mg/dl High:- & gt; 240 mg/dl
TRIGLYCERIDES (SERUM)	165.0	35 – 170 mg/dl
HDL CHOLESTEROL (SERUM)	44.0	35.30 – 79.50 mg/dl
LDL CHOLESTEROL (SERUM)	101.0 ✓	< 130 mg/dl
VLDL	33.0	< 40 mg/dl
CHOLESTROL/HDL RATIO	4.04	< 3.0 Low Risk Ratio 3.0 – 5.0 Avg Risk < 5.0 High Risk
LDL/HDL RATIO	2.2	< 3 Ratio

BLOOD GROUP

TEST	LAB TEST VALUES
BLOOD GROUP ABO & RH FACTOR	
BLOOD GROUP	"A"
RH FACTOR	POSITIVE

GLYCOSYLATED HEMOGLOBIN (HBA1C)

TEST	LAB TEST VALUES	NORMAL RANGE
HBA1C	5.9 ✓	Normal : <5.97 % Good Control : 5.97 – 6.81% Fair Control : 6.81 – 7.65% Poor Control : >7.65%

THYROID PROFILE (T3, T4, TSH)

TEST	LAB TEST VALUES	NORMAL RANGE
THYROID FUNCTION TEST		
T3	1.15	0.60 – 1.81 ng/ml
T4	7.24	4.50 – 10.90 ug/dl
TSH	2.74	0.39 – 6.10 uIU/mL

PAGE 2

Lab Technician

PANACEA HOSPITAL
 UNIT OF AARON HEALTH CARE PVT. LTD.)
 REG. NO.: AL-1500
 B.36/44 FK Kabir Nagar, Durgakund, Varanasi
 DURGAKUND, VARANASI

Timing : 8.00 a.m. to 9.00 p.m. (Sunday 8.00 a.m. to 3.00 p.m.)

This Report is not valid for medico legal purpose

Note: These tests have technical limitations. Clinico-pathological interpretation is necessary. In case of any disparity test may be repeated immediately.

Address : 36/44 FK Kabir Nagar, Durgakund, Varanasi – 221005

Email: dramishra@gmail.com, drpallaviojha@gmail.com Website: panaceahospital.org

Facilities:

All clinical Biomedical & Hematology Investigations including Bone Marrow Examination
 VPT, Podiascan & Complete Foot Care (First Time in Purvanchal)
 All Hormonal Investigation by Chemiluminescent Method
 Visceral Fat by (AB-140) Ambulatory BP Monitoring
 CGMS & Insulin Pump Available
 PFT, 2D-ECHO (Color Doppler), Holter, TMT, Cardiac-3 available
 VIA, VILI, Colposcopy available
 Special Endocrinological Investigation Protocols.

ISO 9001:2008 Certified
 Mobile: 9389994334, 9554572190, 9453837595



Panacea Pathology

Clinical Reference Lab

Persistence, Preparedness and Precision
 EQAS (CMC Vellore Attached) & IQAS System
 पूर्वांचल की सर्वोत्तम गुणवत्ता वाली पैथोलॉजी

PATIENT NAME : PRAVEEN ANIL KUMAR
 REFD BY DR. : ARCO FEMI HEALTHCARE LTD.
 SAMPLE : BLOOD & URINE

AGE/GENDER : 39YRS/MALE
 RECEIVED DATE : 25-01-2023 (10:00 AM)
 REPORT DATE : 25-01-2023 (06:00 PM)

PATHOLOGY REPORT

LIVER PROFILE TEST, SERUM

TEST	LAB TEST VALUES	NORMAL RANGE
BIO CHEMISTRY		
TOTAL BILIRUBIN	0.72	0.0 – 1.1 mg/dl
DIRECT BILIRUBIN	0.28	0.0 – 0.2 mg/dl
INDIRECT BILIRUBIN	0.44	< 0.90 mg/dl
SGOT (AST)	19.5	0 – 52 mg/dl
SGPT (ALT)	22.6	0 – 39 mg/dl
GGT (GYT)	24.5	< 55 U/L

URINE ROUTINE EXAMINATION

TEST	LAB TEST VALUES	NORMAL RANGE
PHYSICAL EXAMINATION		
QUANTITY	29	ML
COLOUR	STRAW	PALE YELLOW
APPEARANCE	CLEAR	CLEAR
SPECIFIC GRAVITY	1.005	1.01 – 1.03
PH	6.0	4.7 – 7.5
CHEMICAL EXAMINATION		
GLUCOSE	Not Detected	Not Detected
PROTEIN	NIL	Not Detected
MICROSCOPIC EXAMINATION		
PUS CELLS	1-2	0-5
RBC	Not Detected	Not Detected
EPITHELIAL CELLS	2-3	0-5
CASTS	Not Detected	Not Detected
CRYSTALS	Not Detected	Not Detected
BACTERIA	Not Detected	Not Detected

RANDOM/FASTING BLOOD SUGER

TEST	LAB TEST VALUES	NORMAL RANGE
RBS/FBS		
RANDOM BLOOD SUGAR	103.1	125-140 mg/dl
FASTING BLOOD SUGER	83.2	70-125 mg/dl

----- End of Report -----

Lab Technician

PANACEA HOSPITAL
 UNIT OF AARCHA HEALTH CARE PVT. LT.
 REG. NO. AL-1500
 B.36/44, D-4, Pathology
 DURGAKUND, VARANASI

Timing : 8.00 a.m. to 9.00 p.m. (Sunday 8.00 a.m. to 3.00 p.m.)

This Report is not valid for medico legal purpose

Note: These tests have technical limitations. Clinico-pathological interpretation is necessary. In case of any disparity test may be repeated immediately.

Address : 36/44 FK Kabir Nagar, Durgakund, Varanasi – 221005

Email: dramishra@gmail.com, drpallaviojha@gmail.com Website: panaceahospital.org



PANACEA HOSPITAL

B 36/44 F.K KABIR NAGAR, DURGAKUND
TOLLFREE NO-18001233070.
Whatsapp No - 8795832852
www.piire.org



2

OP Slip

Print Date : 25-Jan-2023 10:18AM



UHID No	:- UD-22230003406	OP No	:- OP-22230012638	OP Date	:- 25 Jan 2023 10:18AM
Patient Name	:- Mr ANIL KUMAR	Age/Sex	:- 39 Y/Male	Mobile No	:- 8934988927
Father	:- BIRAN RAM	Department	:- DIABETES, ENDOCRINOLOGY & METABOLIC PHYSICIAN		
Pay Type	:- Cash	Consultant	:- Dr ASHUTOSH MISHRA (MD(MEDICINE), IMS, BHU)		
Token No	:- NOR. - 5	Paid/Bal	:- 0.00 / 500.00		
Patient Type	:- Normal				
Address	:- FLAT NUM- 403, SAI APARTMENT, SUNDARPUR, varanasi				

BP :- 110/70 **Rx**
 height :- 165
 Weight (kg) :- 78.2
 BMI :-

Δ Prediabetes
Dyslipidemia

STOP SMOKING

Rx.

- Diabetic diet 1400kcal/d
- Exercise 60min/d.
- eg, Diaberm (10) OD
- eg, Roumrey (20) OD

R/A 2month

Tab. Bempedolc and 180mg Ald
All OK (SUNNY)

Printed By : Mr NITIN YADAV

Created By : Mr NITIN YADAV

R/A 2month
for

25mm/s AC50Hz+EMG35Hz

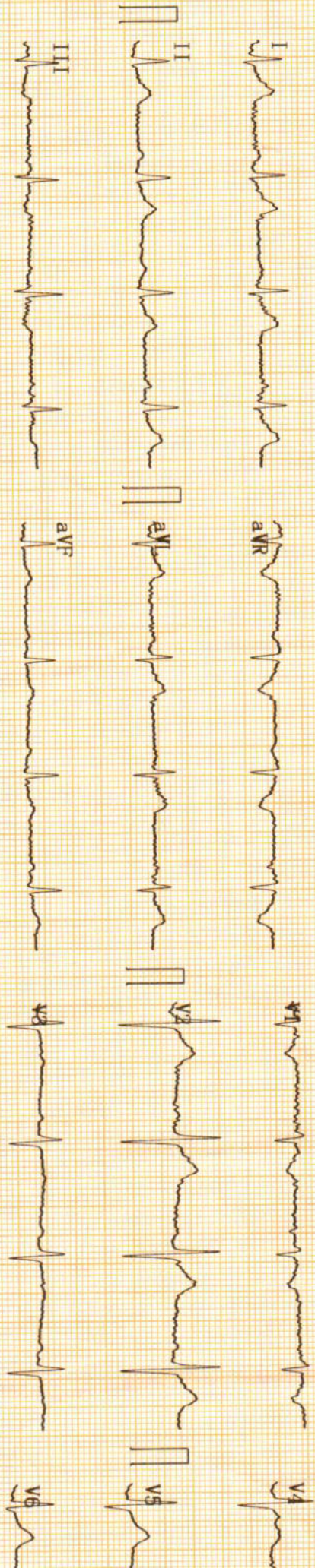
AUTO 10mm/mV

10mm/mV

10mm/mV

10mm/mV

BPL





PANACEA HOSPITAL

Call Now - 1800-123-3070

A shelter for many hearts A Home for many lives

(An ISO 9001:2008 Certified Organisation)

Lab Attached with CMC Vellore Under EQAS Scheme

Name	MR.ANIL KUMAR	Sex /Age	39/M	Date	25/01/2023
Ref. by	Dr.Pallavi Mishra(MD)	BSA - m ²		Echo window	fair


Echo - Cardiography

MITRAL VALVE Doppler	AML - normal morphology MV Flow - E - 0.6 A-0.3 E/A=1.64	PML - normal morphology MVA - 3.0 cm ² Mitral Regurgitation - No
TRICUSPID VALVE Doppler	Normal TV Flow -No	Tricuspid Regurgitation - No
PULMONARY VALVE Doppler	Normal PV Flow -No	Pulmonary Regurgitation - No
AORTIC VALVE Doppler	Trileaflet-No AV Flow - no	Aortic Regurgitation - no
MEASUREMENT	Aorta - 25.1 (20-38) mm IVS ed - 9.7 (6 -12) mm LVID ed - 43.4 (35 - 55) mm LVPW ed - 10.9 (6 -12) mm OA - 7 (> 5) mm	LA - 29.1 (24-32) mm IVS es -13.7 (6 - 12) mm LVID es - 23.4 (24 - 40) mm LVPW es - 14.3 (6 -12) mm EPSS - 6 (< 9) mm

CONCLUSION
All cardiac chamber dimensions are WNL
No valvular abnormalities
Good LV systolic function present Modified Simpson's method (4C, 2C) (LVEF-78%)
No diastolic dysfunction present (E/A = 1.64) by tissue Doppler (E/e'=6.2)
No RWMA
No pericardial effusion
Intact IAS / IV
No PAH
No intra cardiac mass /thrombus /vegetation

IMPRESSION **Normal Echocardiogram**

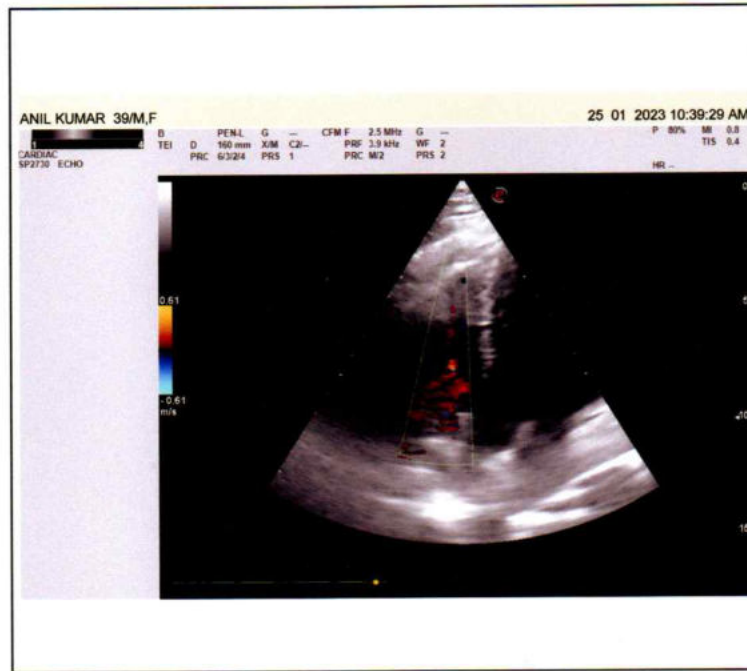
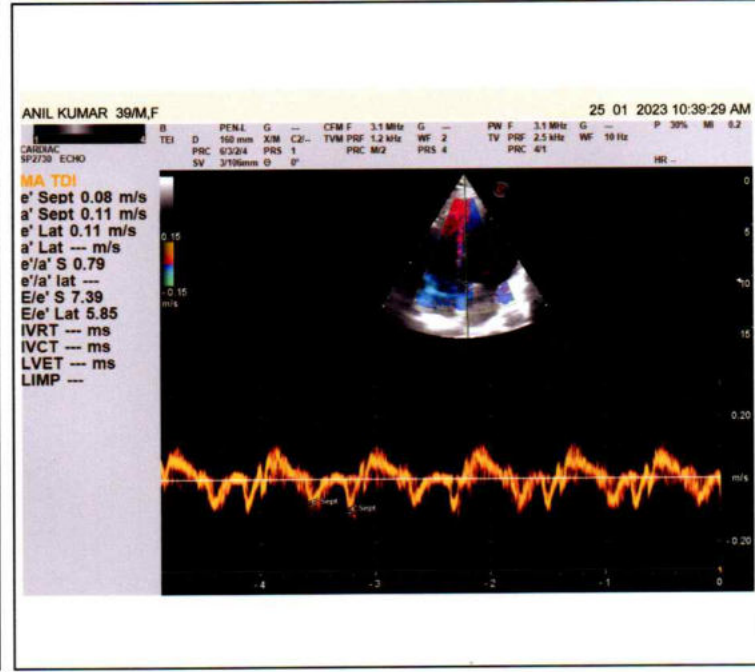
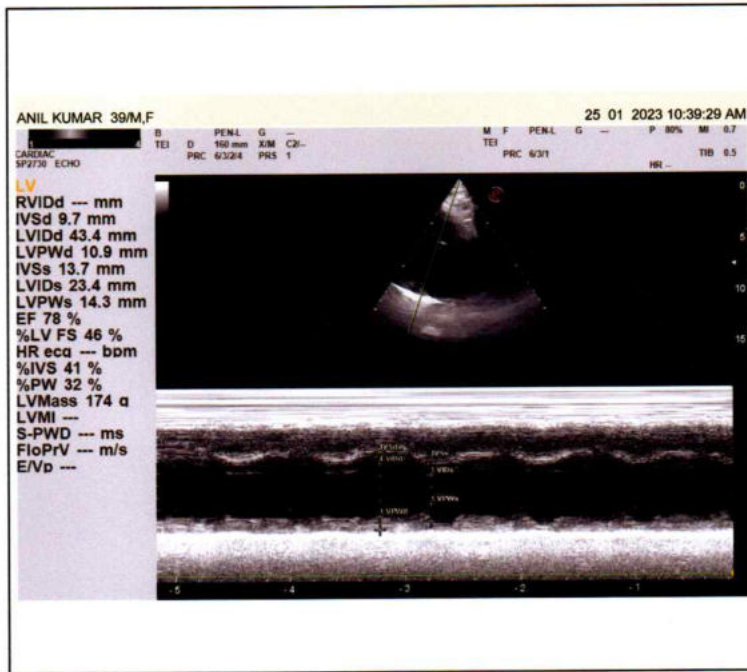
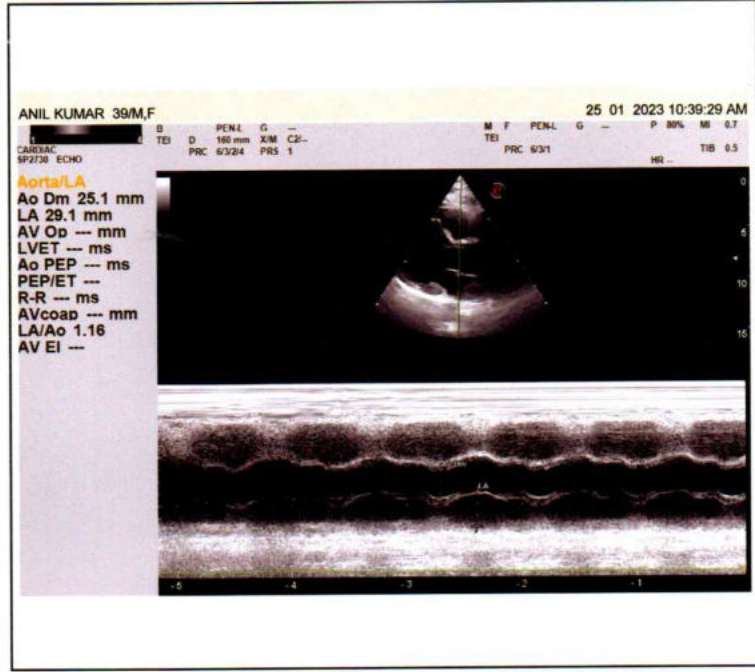
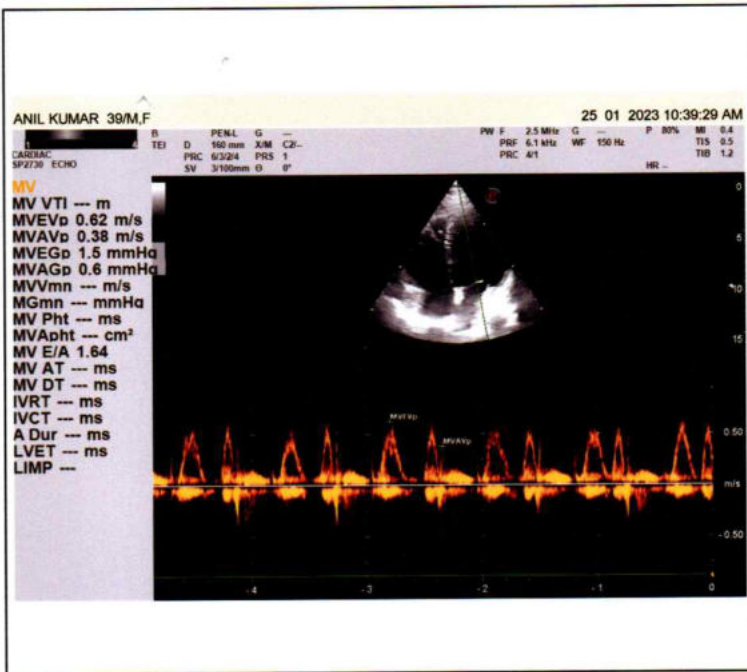

Niraj Mishra
Physician Assistant
(PIIRE)


DR. PALLAVI MISHRA
MBBS, MD (GENERAL MEDICINE)
MCI Reg.No. 52033
Dr. Pallavi Mishra
MBBS, MD (MED) Lucknow
Echocardiography Specialist, MIAE
Non-invasive cardiologist
Women Cardiologist
Diabetocardiologist

Address : Kabir Nagar (Near Sanjay Shiksha Niketan), Durgakund, Varanasi

Mobile : 9554572190 / 9453837595 / Recpn. 9389994334

E-mail : dramishra@gmail.com, drpallaviojha@gmail.com, Website: www.piire.org





PANACEA HOSPITAL

A shelter for many hearts A Home for many lives

(An ISO 9001:2008 Certified Organisation)

Lab Attached with CMC Vellore Under EQAS Scheme

NAME: MR. ANIL KUMAR

AGE/SEX: 39 YRS / MALE

REF BY: DR. ASHUTOSH MISHRA (MD)

DATE: 25/01/2023

ULTRA SOUND WHOLE ABDOMEN REPORT

Liver: Normal in shape and size (11.4 cm) and shows smooth and regular margin.
No diffuse/focal lesion seen.

Gall bladder: Partially distended with normal wall thickness and echo-free lumen.

CBD diameter Visualized part normal in course & caliber.

Pancreas: Normal in size, shape & echogenicity.
Margins are smooth & regular.
No diffuse/ focal lesion seen. Pancreatic tail obscured.

Spleen: Normal in size, shape & echogenicity.
Margins are smooth & regular. No diffuse / focal lesion seen.
Splenic vessels at hilum is normal.

Kidney: Right kidney: 9.4 X 5.1cm
Left kidney: 8.8 X 5.4 cm
Both normal in size, shape, echogenicity & position.
Cortical-medullary differentiation is maintained.
Pelvicalyceal system normal.
No calculus/mass lesion seen.
No hydronephrosis/ hydroureter seen.
No suprarenal mass lesion.

Address : Kabir Nagar (Near Sanjay Shiksha Niketan), Durgakund, Varanasi

Mobile : 9554572190 / 9453837595 / Recpn. 9389994334

E-mail : dramishra@gmail.com, drpallaviojha@gmail.com, **Website:** www.piire.org



PANACEA HOSPITAL

A shelter for many hearts A Home for many lives

(An ISO 9001:2008 Certified Organisation)

Lab Attached with CMC Vellore Under EQAS Scheme

inary bladder: Normally distended, wall thickness is normal.
No echogenic foci lumen or diverticula seen.
Both VUJ appears normal.
No E.R. calculus / mass lesion seen.

Prostate: Normal in size, shape, & echogenicity.
Size 3.5 X 2.2 X 3.8 cm Wt. 16.0 Gm approx.
No calcification or focal cystic lesion seen.
Capsular margins are smooth and regular.
Seminal vesicles appear normal in size, shape & echogenicity.
No diffuse /focal lesion seen.

Others: No free fluid in peritoneal cavity.
No free fluid in bilateral pleural cavity.

IMPRESSION:

- **NO SIGNIFICANT SONOLOGICAL ABNORMALITY DETECTED.**

Please correlate clinically and further investigations.

DR. PALLAVI MISHRA
MBBS, MD (GENERAL MEDICINE)
MCI Reg.No. 52033

DR. PALLAVI MISHRA
MBBS MD(MED) Lucknow
Echocardiography specialist, MIAE
Non invasive cardiologist
Women cardiologist

Radiologist

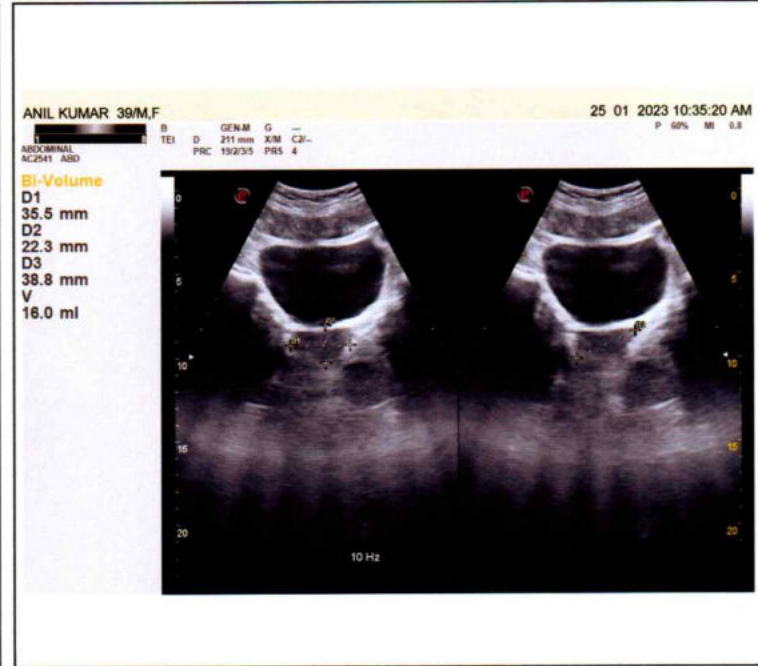
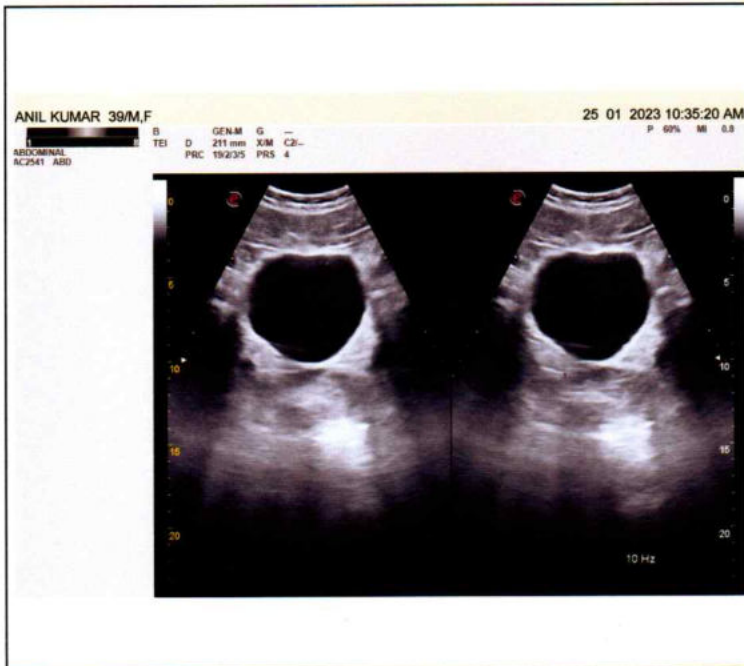
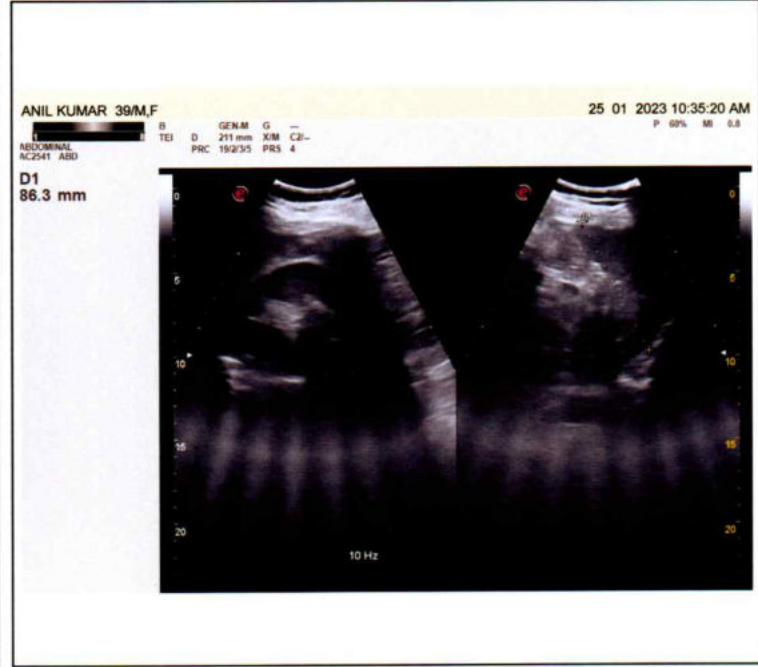
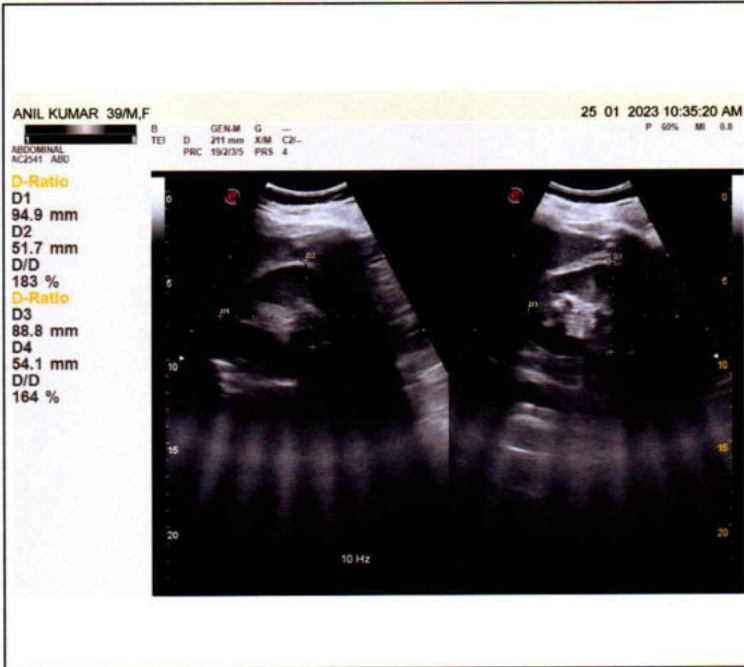
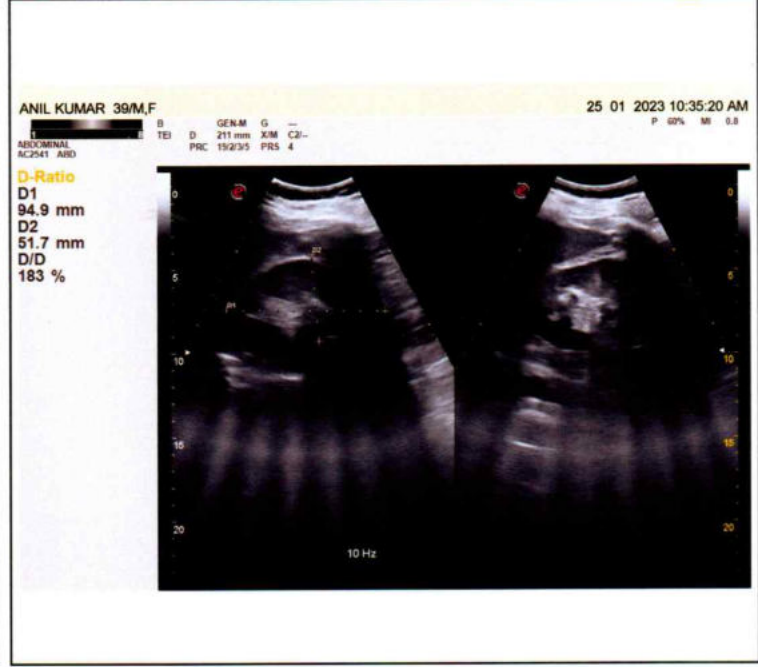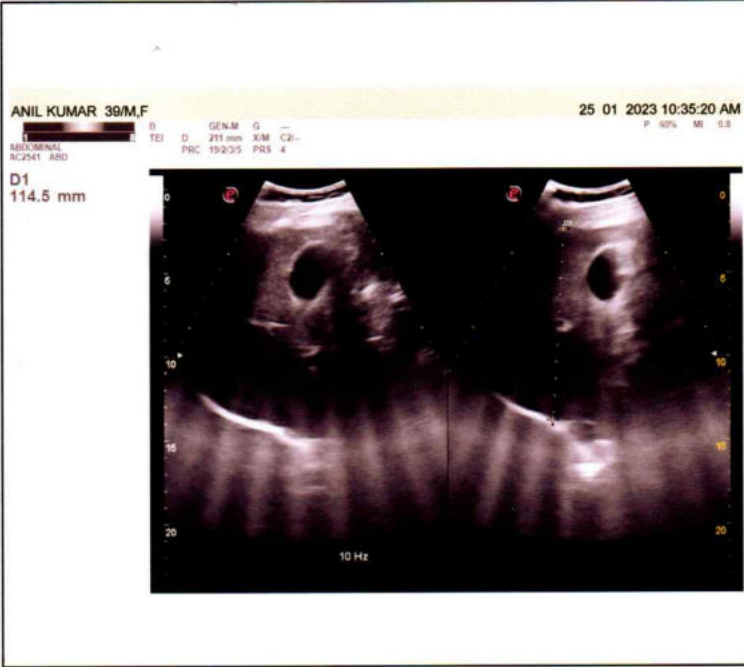
Dr. Tusharika Rai
MBBS MS

NIRAJ MISHRA
(Physician Assistant)
(PIIRE)

Address : Kabir Nagar (Near Sanjay Shiksha Niketan), Durgakund, Varanasi

Mobile : 9554572190 / 9453837595 / Recpn. 9389994334

E-mail : dramishra@gmail.com, drpallaviojha@gmail.com, Website: www.piire.org





PANACEA HOSPITAL

A shelter for many hearts A Home for many lives

(An ISO 9001:2008 Certified Organisation)
Lab Attached with CMC Vellore Under EQAS Scheme

AME: MR. ANIL KUMAR

AGE/SEX: 39 YRS / MALE

EF BY: DR. ASHUTOSH MISHRA (MD)

DATE: 25/01/2023

X-RAY CHEST PA

BOTH LUNG FIELDS AND PLEURAE:

Both lungs show normal bronchovascular pattern.

Right & left hila are normal

No focal mass or calcification is seen

There is no evidence of any fluid in the both the pleural cavities.

Both domes of diaphragms are normal in position.

MEDIASTINUM:

Trachea is central in position.

Cardiac silhouette is of normal size and configuration.

No evidence of pericardial effusion.

No significant lymphadenopathy is seen.

Visualized skeleton is normal.

NO SIGNIFICANT RADIOGRAPHIC ABNORMALITY.

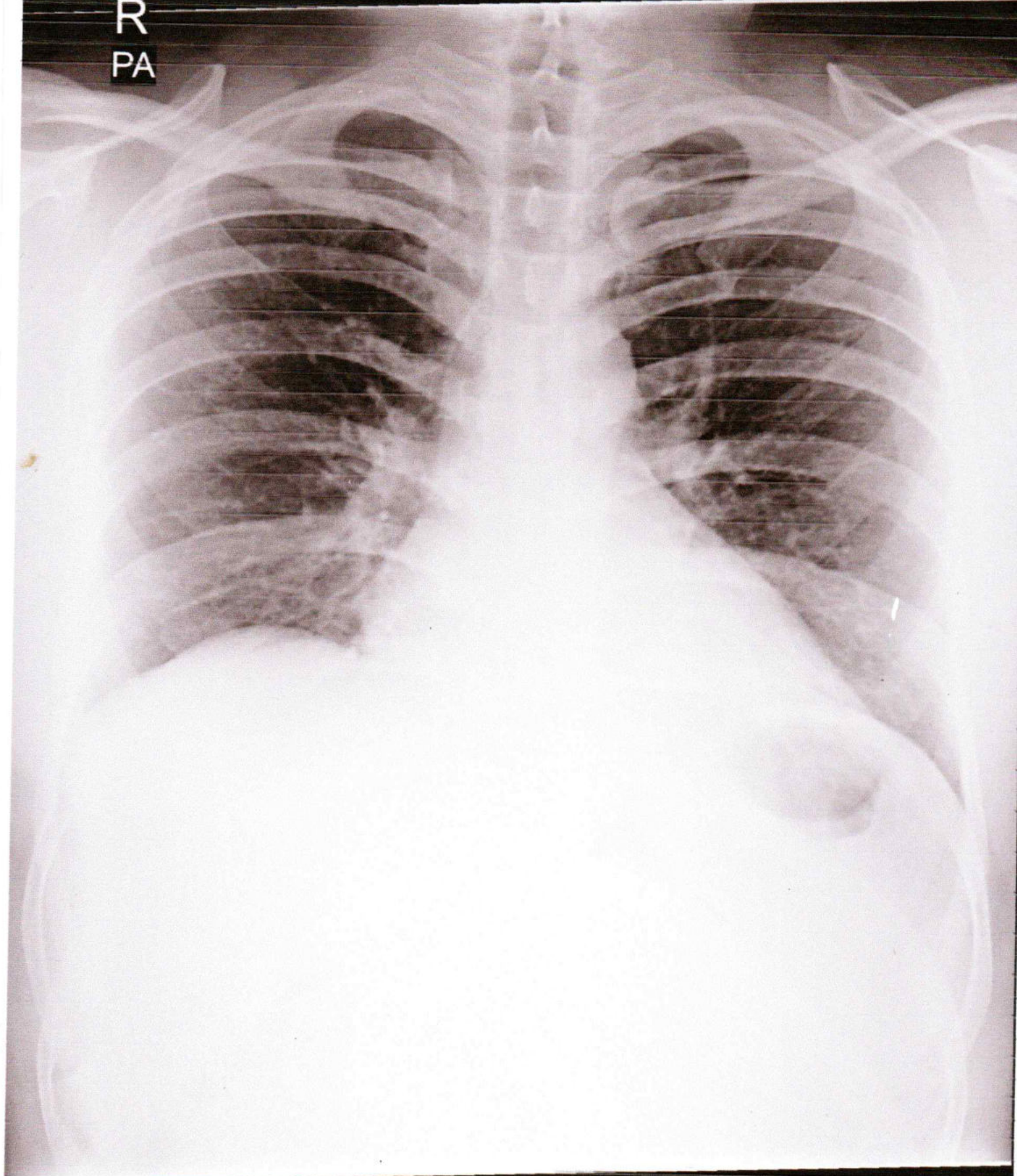

Radiologist

Address : Kabir Nagar (Near Sanjay Shiksha Niketan), Durgakund, Varanasi

Mobile : 9554572190 / 9453837595 / Recpn. 9389994334

E-mail : dramishra@gmail.com, drpallaviojha@gmail.com, **Website:** www.piire.org

R
PA



ANIL KUMAR 39Y/M 3406 O CHEST P.A. 25-Jan-23 10:54 AM

PANACEA HOSPITAL, KABIR NAGAR, DURGAKUND, VARANASI