

Customer Name	MR. R RETHEESH T	Customer ID	MED120924508
Age & Gender	32Y/MALE	Visit Date	26/03/2022
Ref Doctor	MediWheel		

Personal Health Report

General Examination:

Height : 177 cms
 Weight : 82.3 kg
 BMI : 26.2 kg/m²

Systemic Examination:

CVS: S1 S2 heard;
 RS : NVBS +.
 Abd : Soft.
 CNS : NAD

Blood report:

X-Ray Chest – Normal study.

ECG – Normal ECG.

ECHO Cardiography – Normal study. Altered septal motion of LV.


Eye Test – Distant vision defect.

Vision	Right eye	Left eye
Distant Vision	6/9	6/9
Near Vision	N6	N6
Colour Vision	Normal	Normal

Impression & Advice:

Eye Test – Distant vision defect. To consult an ophthalmologist for further evaluation and management.

All other health parameters are well within normal limits.


 DR. NOOR MOHAMMAD RIZWAN A. M.B.B.S, FDM
 MHC Physician Consultant
 A Medall Health Care and Diagnostics Pvt. Ltd.



Customer Name	MR. R RETHEESH T	Customer ID	MED120924508
Age & Gender	32Y/MALE	Visit Date	26/03/2022
Ref Doctor	MediWheel		

DEPARTMENT OF CARDIOLOGY
TRANSTHORACIC RESTING ECHO CARDIOGRAPHY REPORT

**ECHO INDICATION: Assessment
M MODE & 2-D PARAMETERS:**

ACOUSTIC WINDOW : GOOD

LV STUDY

IVS(d)	cm	0.5
IVS(s)	cm	1.0
LPW(d)	cm	0.8
LPW(s)	cm	1.2
LVID(d)	cm	5.6
LVID(s)	cm	4.0
EDV ml		181
ESV ml		66
SV ml		114
EF %		63
FS %		28

DOPPLER PARAMETERS

Parameters		Patient Value
LA	cm	3.0
AO	cm	2.5

Valves	Velocity max(m/sec mm/Hg)
AV	0.6/2 m/s
PV	0.8/3 m/s
MV (E)	0.3 m/s
(A)	0.6 m/s
TV (E)	1.0/4 m/s

FINDINGS:

- ❖ Altered septal motion of LV.
- ❖ No regional wall motion abnormality.
- ❖ Normal left ventricle systolic function. (EF: 63%).
- ❖ Grade - I LV diastolic dysfunction.
- ❖ Normal chambers dimension.
- ❖ Normal valves.
- ❖ Normal pericardium/Intact septae.
- ❖ No clot/aneurysm.

IMPRESSION:

- ▶ **ALTERED SEPTAL MOTION OF LV.**
- ▶ **NO REGIONAL WALL MOTION ABNORMALITY.**
- ▶ **NORMAL LEFT VENTRICLE SYSTOLIC FUNCTION.**

S. Vignesh

**S. VIGNESH M.Sc.
ECHO TECHNICIAN**



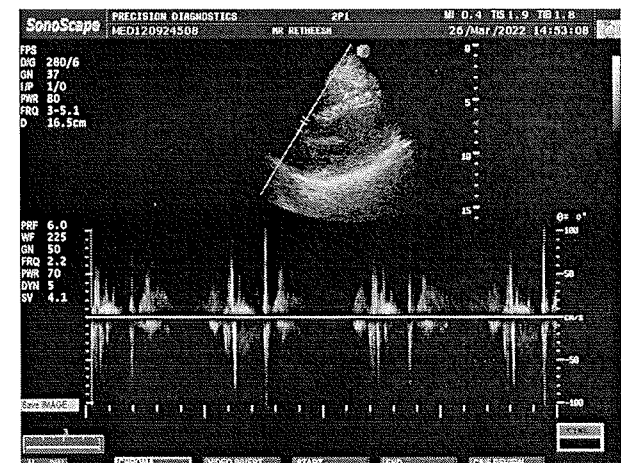
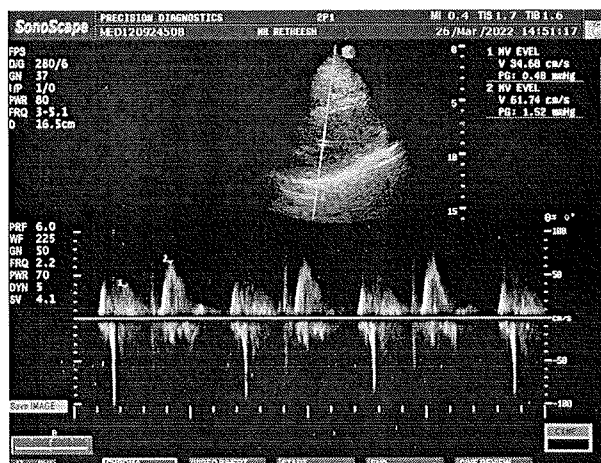
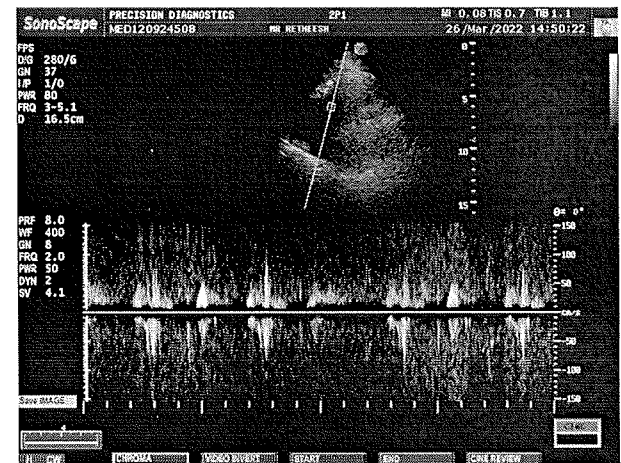
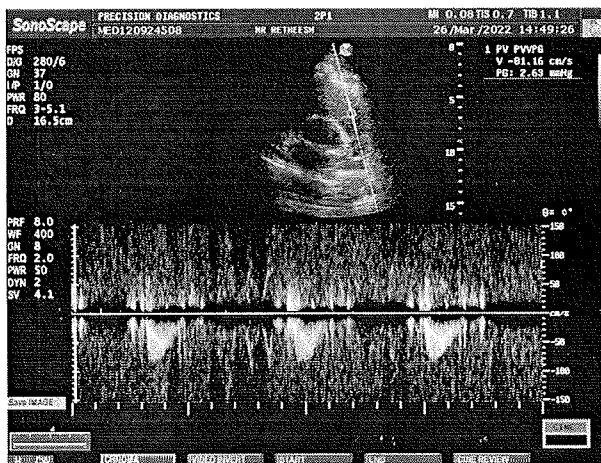
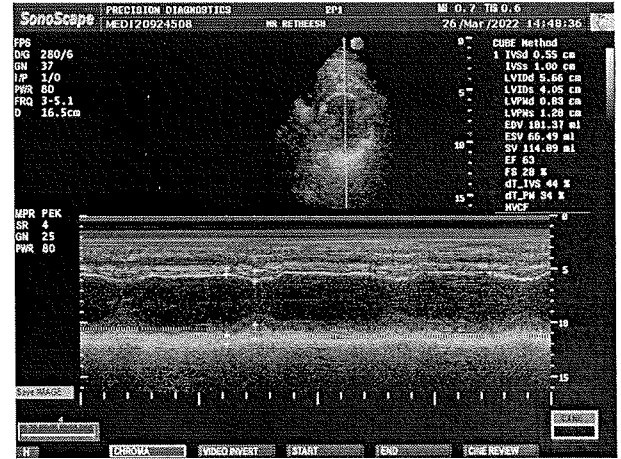
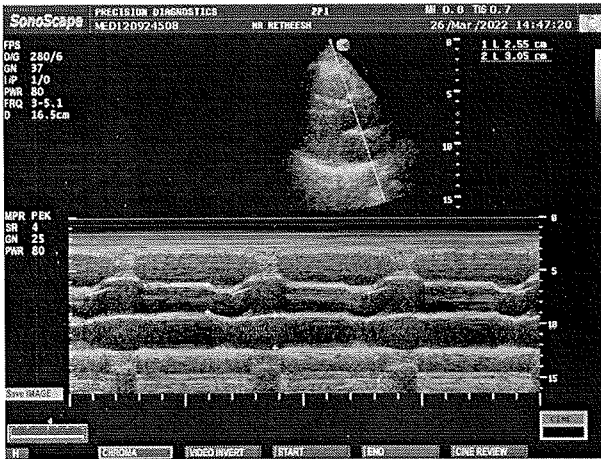


MEDALL

Precision Diagnostics-vadapalani

58/6, Revathy street, Jawarlal nehru road, 100 feet Road, (Former State Election Commission Office),

Customer Name	MR. R RETHEESH T	Customer ID	MED120924508
Age & Gender	32Y/MALE	Visit Date	26/03/2022
Ref Doctor	MediWheel		



You can also conveniently view the reports and trends through our App. Scan QR code to download the App.



Please produce bill copy at the time of collecting the reports. Request you to provide your mobile number or customer id during your subsequent visits.

Name	R RETHEESH T	Customer ID	MED120924508
Age & Gender	32Y/M	Visit Date	Mar 26 2022 12:38PM
Ref Doctor	MediWheel		

X- RAY CHEST PA VIEW

Trachea appears normal.

Cardiothoracic ratio is within normal limits.

Bilateral lung fields appear normal.


Costo and cardiophrenic angles appear normal.

Visualised bony structures appear normal.

Extra thoracic soft tissues shadow grossly appears normal.

IMPRESSION:

- *Chest x-ray shows no significant abnormality.*


**Dr. Rama Krishnan, MD, DNB.,
Consultant Radiologist,
Medall Healthcare Pvt Ltd.**



AGE: Measurement Results: 92 ms
QRS: 404 / 410 ms
QT/QTcB: 146 ms
PR: 92 ms
P: 936 / 965 ms
RR/PP: 187 / 47 50 degrees
P:QRS/T: III +90 II aVF

Interpretation:
Normal interpretation
Normal sinus rhythm
Normal ECG

Unconfirmed report

