



NAME	: MR. DEVBRAT KUMAR	DATE	: 12/1/22
Age Sex	: 28 Years / Male	Inpatient No	:
PERFORMED BY	: Dr. ELA MADAAN	Req . no	: 780804

TRANS THORACIC ECHO CARDIOGRAPHY REPORT

MITRAL VALVE

Morphology AML: **Normal** / Thickening / Calcification / Flutter / Vegetation / Non significant Prolapse / SAM
PML: **Normal** / Thickening / Calcification / Prolapse / Paradoxical Motion / Fixed.
Subvalvular deformity: Present / **Absent**

Doppler **Normal** / Abnormal
Mitral Stenosis Present / **Absent**
Mitral Regurgitation; Absent / Normal / Mild / **Trace** / Moderate / Severe.

TRICUSPID VALVE

Morphology **Normal** / Atresia / Thickening / Calcification / Prolapse / Vegetation / Doming.
Doppler **Normal** / Abnormal
Tricuspid Stenosis: Present / **Absent**.
Tricuspid Regurgitation; **Absent** / Normal / Mild / **Trace** / Moderate / Severe.

PULMONARY VALVE

Morphology **Normal** / Atresia / Thickening / Calcified / Doming / Vegetation.
Doppler **Normal** / Abnormal.
Pulmonary stenosis : Present / **Absent**
Pulmonary regurgitation : Present / **Absent**

AORTIC VALVE

Morphology **Normal** / Thickened / Mildly / Calcified / Flutter / Vegetation / Restricted / Opening
No. of Cusps 1 / 2 / **3** / 4
Doppler **Normal** / Abnormal
Aortic Stenosis : Present / **Absent**
Aortic regurgitation : Present / **Absent** / Mild / Trace

(This is only professional opinion and not the diagnosis, Please correlate clinically)

Q Block South City 11, Sohna Road, Main Sector-47, Gurgaon, Haryana

Ph.: 0124-4900000 (100 Lines) Fax : 0124-2218733 E-mail : parkmedicenters@gmail.com

PARK GROUP OF HOSPITALS : West Delhi • South Delhi • Gurgaon • Karnal • Panipat • Hodal • Ambala • Behl



Park Hospital

GROUP SUPER SPECIALITY HOSPITAL



<u>Measurements</u>	<u>Normal Values</u>	<u>Measurements</u>	<u>Normal Value</u>
IVSD : 1.0cm	(0.6-1.1cm))	LA : 3.7cm	(1.9-4.0cm)
LVID : 5.1cm	(3.7-5.6cm)	LVOT : 1.6cm	
LVPW : 0.9cm	(0.6-1.1cm)	AORTA : 2.4cm	(2.0-3.7cm)
EF : 55%	(55% - 80%)	IVSmotion :	Normal/Flat/Paradoxical
Any Other			


CHAMBERS:-

- LV **Normal** / Enlarged / **Clear** / Thrombus
 Contraction Normal LV shows concentric LVH, no gradient across LVOT /Inetic / Intra capillary
 Regional wall motion abnormality: **Absent**/ Present
- LA **Normal** /Enlarged / Clear /Thrombus / Myxoma; **LAA: Clear** / Thrombus
- RA **Normal** / **Clear** / Thrombus, Dilated.
- RV **Normal** / Enlarged / **Clear** / Thrombus / Hypertrophied/ Dilated.
- PERICARDIUM Normal / Thickening / Calcification / Effusion.

COMMENTS & SUMMARY:-

- All cardiac chambers dimensions are with in normal limits.
- Global LVEF 55%
- No RWMA(Regional wall motion abnormality at rest)
- NORMAL LV FUNCTION
- TRACE MR
- NO AR / NOAS
- TRACE TR
- GOOD RV FUNCTION
- IAS/IVS. No Flow seen across IAS/IVS.
- No Thrombus/Mass in any chamber.
- No Pericardial Effusion.

Please correlate clinically


 Dr. Ela Madaan
 MBBS, PGDCC
 Fellowship in Non Invasive
 Cardiology

Dr. BINAY KUMAR
 M.D. (Medicine) D.M (Cardiology).
 Interventional cardiology.

(This is only professional opinion and not the diagnosis, Please correlate clinically)

Q Block South City 11, Sohna Road, Main Sector-47, Gurgaon, Haryana
 Ph.: 0124-49000000 (100 Lines) Fax : 0124-2218733 E-mail : parkmedicenters@gmail.com

PARK GROUP OF HOSPITALS : West Delhi • South Delhi • Gurgaon • Karnal • Panipat • Hodal • Ambala • Behror

the **health** care providers

the **health** care providers



Patient Name	: Mr.DEVBRAT KUMAR	IP/OP No	:
Age/ Sex	: 28 Years Male	Req No	: 780804
Unit name	: RMO	Report Date/Time	: 12/01/2022
Consultant Nm	: RMO	Patient's Phone	:
Reqdt/Reqtm	: 12/01/2022	Payer Name	: MEDIWHEEL PVT LTD

ULTRA SOUND TEST REPORT

Test Name - USG WHOLE ABDOMEN

USG Whole Abdomen

The real time, B mode, gray scale sonography of the abdominal organs was performed.

LIVER : The liver is mild enlarged in size 15.1cm with fatty infiltration. No evidence of any focal lesion. IHBR is not dilated.

GALL BLADDER : The gall bladder is well distended . No evidence any calculus or mass seen. GB wall thickness with in normal limits.No evidence of pericholecystic fluid is seen.

BILE DUCT :The common bile duct is normal in caliber. No evidence of calculus is noted in common bile duct.

SPLEEN :The spleen is normal in size and shape.Its echotexture is homogeneous.No evidence of focal lesion is noted.

PANCREAS :The pancreas is normal in size, shape, contours and echotexture.No evidence of solid or cystic mass lesion is noted.MPD is not dilated. No evidence of peripancreatic collection.

KIDNEYS :RK: 9.9x5.2cm. LK: 9.3x5.0cm.

The bilateral kidneys are normal in size and echotexture. Cortico-medullary differentiation is maintained.There is no evidence of obvious calculus or hydronephrosis.

URINARY BLADDER :The urinary bladder is well distended.It shows uniformly thin walls and sharp mucosa.No evidence of calculus is seen. No evidence of mass or diverticulum is noted.

PROSTATE: The prostate is normal, size, shape and normal echotexture.

No evidence of ascites or interbowel free fluid is seen.

No evidence of obvious retroperitoneal or mesantric lymphadenopathy is seen.

IMPRESSION- Mild hepatomegaly with fatty liver grade-I

To be correlated clinically.

DR. SAKET RUPRAMKA
MBBS, MD
CONSULTANT RADIOLOGIST

DR.MANJEET SEHRAWAT
MBBS, MD, PDCC
CONSULTANT RADIOLOGIST

DR. BINOD CHOUDHARY
MBBS, MD
CONSULTANT RADIOLOGIST

DR. ANSHU K SHARMA
MBBS, MD
CONSULTANT RADIOLOGIST

(This is only professional opinion and not the diagnosis. Please correlate clinically.)

Gurgaon : Q Block, South City-II, Sohna Road, Sector - 47, Gurugram-122002, (Haryana)

Faridabad : J-Block, Sector - 10, Near Court, Faridabad - 121004, (Haryana)

• Helpline : 0124-4900000

• Helpline : 0129-4200000



Name : Mr.DEVBRAT KUMAR Requisition No. : 780804
 Age / Gender : 28 Years Male UHID Number :
 Referred By : RMO Reporting Date : 12-Jan-2022 01:54:34PM
 Station : Direct Payer Name : MEDIWHEEL PVT LTD
 Date of Collection : 12-JAN-22 11:13 Ward :

**LAB SERVICES - BIOCHEMISTRY
TEST REPORT**

KFT (RENAL PROFILE)

Test	Results	Units	Reference Interval
BLOOD UREA	25	mg/dl	13 – 45
Creatinine.	1.1	mg/dl	0.6 – 1.4
SERUM URIC ACID	9.0	mg/dl	3.6 – 7.2
SERUM SODIUM	141	mmol/Lt	135 – 155
S.POTASSIUM	4.2	mmol/Lt	3.4 – 5.6
S. CALCIUM	8.7	mg/dl	8.4 – 10.4
PHOSPHORUS	3.2	mg/dl	2.5 – 4.5

-----End of Report-----

Dr. PRITI SHAH
Pathologist

Lab Incharge

Page 1 of 1

Dr. PRADIP KUMAR
MICROBIOLOGIST

ANSAR

H= High L=Low P=Panic

(This is only professional opinion and not the diagnosis, Please correlate clinically)

Q Block South City 11, Sohna Road, Main Sector-47, Gurgaon, Haryana
 Ph.: 0124-49000000 (100 Lines) Fax : 0124-2218733 E-mail : parkmedicenters@gmail.com

PARK GROUP OF HOSPITALS : West Delhi • South Delhi • Gurgaon • Karnal • Panipat • Hodal • Ambala • Behror

the **health** care providers

the **health** care providers



Name	: Mr.DEVBRAT KUMAR	Requisition No.	: 780804
Age / Gender	: 28 Years Male	UHID Number	:
Referred By	: RMO	Reporting Date	: 12-Jan-2022 01:55:35PM
Station	: Direct	Payer Name	: MEDIWHEEL PVT LTD
Date of Collection	: 12-JAN-22 11:13	Ward	:

**LAB SERVICES - HAEMATOLOGY
TEST REPORT**

LFT (LIVER FUNCTION TEST)

Test	Results	Units	Reference Interval
BILIRUBIN TOTAL	0.7	mg/dl	0 – 1.2
BILIRUBIN DIRECT	0.3	mg/dl	0 – 0.3
BILIRUBIN INDIRECT	0.4	mg/dl	0 – 0.9
SGOT	34	IU/L	5 – 35
SGPT	45	IU/L	5 – 40
Alkaline Phosphatase	112	IU/L	35 – 135
Total Protein	7.0	g/dL	6.0 – 8.3
ALBUMIN	3.5	g/dl	3.2 – 5.0
GLOBULIN	3.5	gm/dl	1.5 – 3.6
A/G Ratio	1.0		0.9 – 2

-----End of Report-----

Dr. PRITI SHAH	Dr. PRADIP KUMAR	ANSAR
Pathologist	Lab Incharge	MICROBIOLOGIST

H= High L=Low P=Panic

(This is only professional opinion and not the diagnosis, Please correlate clinically)

Q Block South City 11, Sohna Road, Main Sector-47, Gurgaon, Haryana
Ph.: 0124-49000000 (100 Lines) Fax : 0124-2218733 E-mail : parkmedicenters@gmail.com

PARK GROUP OF HOSPITALS : West Delhi • South Delhi • Gurgaon • Karnal • Panipat • Hodal • Ambala • Behror



Name	: Mr.DEVBRAT KUMAR	Requisition No.	: 780804
Age / Gender	: 28 Years Male	UHID Number	:
Referred By	: RMO	Reporting Date	: 15-Jan-2022 02:30:00PM
Station	: Direct	Payer Name	: MEDIWHEEL PVT LTD
Date of Collection	: 12-JAN-22 11:13	Ward	:

**LAB SERVICES - MICROBIOLOGY
TEST REPORT**

URINE C/S

Test	Results	Units	Reference Interval
ORGANISM (S) ISOLATED	Culture sterile after 48 hrs of aerobic incubation at 37 degree C.		

-----End of Report-----

Dr. PRITI SHAH

Pathologist

Lab Incharge

Dr. PRADIP KUMAR

MICROBIOLOGIST

RAMKISHAN

H= High L=Low P=Panic

(This is only professional opinion and not the diagnosis, Please correlate clinically)

Q Block South City 11, Sohna Road, Main Sector-47, Gurgaon, Haryana
Ph.: 0124-49000000 (100 Lines) Fax : 0124-2218733 E-mail : parkmedicenters@gmail.com

PARK GROUP OF HOSPITALS : West Delhi • South Delhi • Gurgaon • Karnal • Panipat • Hodal • Ambala • Behror



Name	: Mr.DEVBRAT KUMAR	Requisition No.	: 780804
Age / Gender	: 28 Years Male	UHID Number	:
Referred By	: RMO	Reporting Date	: 12-Jan-2022 01:56:48PM
Station	: Direct	Payer Name	: MEDIWHEEL PVT LTD
Date of Collection	: 12-JAN-22 11:13	Ward	:

**LAB SERVICES - HAEMATOLOGY
TEST REPORT**

CBC

Test	Results	Units	Reference Interval
HB	12.4	gm/dl	13 -- 17
TLC.	5500	cell/cumm	4000 -- 11000
NEUTROPHILS	60	%	40 -- 75
LYMPHOCYTES	35	%	20 -- 45
MONOCYTES	03	%	2 -- 10
EOSINOPHIL	02	%	1 -- 4
BASOPHIL	00	%	0 -- 1
TOTAL RBC COUNT	6.3	Millions/cumm	3.5 -- 5.5
PCV	51.7	%	35 -- 45
MCV	82.0	fl	76 -- 96
MCH	19.7	pg	27 -- 32
MCHC	24.0	gm/dl	30 -- 36
RDW	14.6	%	11 -- 14
PLATELET COUNT	284	1000/cumm	150 -- 450

-----End of Report-----

Dr. PRITI SHAH

Pathologist

Lab Incharge

Page 1 of 1

Dr. PRADIP KUMAR

MICROBIOLOGIST

ANSAR

H= High L=Low P=Panic

(This is only professional opinion and not the diagnosis, Please correlate clinically)

Q Block South City 11, Sohna Road, Main Sector-47, Gurgaon, Haryana
Ph.: 0124-49000000 (100 Lines) Fax : 0124-2218733 E-mail : parkmedicenters@gmail.com

PARK GROUP OF HOSPITALS : West Delhi • South Delhi • Gurgaon • Karnal • Panipat • Hodal • Ambala • Behror

the **health** care providers

the **health** care providers



Name	: Mr.DEVBRAT KUMAR	Requisition No.	: 780804
Age / Gender	: 28 Years Male	UHID Number	:
Referred By	: RMO	Reporting Date	: 12-Jan-2022 01:55:12PM
Station	: Direct	Payer Name	: MEDIWHEEL PVT LTD
Date of Collection	: 12-JAN-22 11:13	Ward	:

**LAB SERVICES - BIOCHEMISTRY
TEST REPORT**

Test	Results	Units	Reference Interval
BLOOD SUGAR 2 HR. PP	118	mg/dl	80 – 140
BLOOD SUGAR FASTING	97	mg/dl	70 – 110

-----End of Report-----

Dr. PRITI SHAH
Pathologist

Dr. PRADIP KUMAR
MICROBIOLOGIST

ANSAR

Lab Incharge

Page 1 of 1

H= High L=Low P=Panic

(This is only professional opinion and not the diagnosis, Please correlate clinically)

Q Block South City 11, Sohna Road, Main Sector-47, Gurgaon, Haryana
Ph.: 0124-49000000 (100 Lines) Fax : 0124-2218733 E-mail : parkmedicenters@gmail.com

PARK GROUP OF HOSPITALS : West Delhi • South Delhi • Gurgaon • Karnal • Panipat • Hodal • Ambala • Behror



UHID No :		Requestion Date	12/01/2022
Requestion No. :	780804	Sample Date :	12/01/2022 11:13 AM
Patient Name :	Mr.DEVBRAT KUMAR	Sample Receiving	12/01/2022 11:13 AM
Age :	28 Years / Male	Report Date :	12/01/2022 03:45 PM
Requestion Type :	OPD	IP Bill No./Bed No. :	
Doctor Name :	RMO	Ref.By/Company :	MEDIWHEEL PVT LTD
		Floor Name :	

INVESTIGATIONRESULTSREF.RANGE / UNITS

Specimen Type :-Urine

URINE ROUTINE AND MICROSCOPY

Method:- Chemical Examination is perfomes by Regent Strip

PHYSICAL CHARACTERSTICS

Quantity	35ml	
Colour	Pale yellow	Pale Yellow
Turbidity	Clear	
Specific gravity	1.020	1.003--1.030
PH	6.5	4.7--7.0

CHEMICAL EXAMINATION

Urobilnogen	Normal	Normal
Protein	NIL	Nil
Blood	NIL	Nil
Ketone	NIL	Nil
Bilirubin	NIL	
Glucose	NIL	Nil

MICRO.EXAMINATION

Pus Cells	1-2 /HPF	0-3
RBC	NIL /HPF	NIL
Epithelial cells	1-2 /HPF	0-5
Cast	NILI	Nil
Crystals		Nil

OTHERS

-----End Of Report-----

Dr.Pradip Kumar
MicrobiologistDr.Nikita Agrwal
Pathologist

(This is only professional opinion and not the diagnosis, Please correlate clinically)

Q Block South City 11, Sohna Road, Main Sector-47, Gurgaon, Haryana

Ph.: 0124-4900000 (100 Lines) Fax : 0124-2218733 E-mail : parkmedicenters@gmail.com

PARK GROUP OF HOSPITALS : West Delhi • South Delhi • Gurgaon • Karnal • Panipat • Hodal • Ambala • Behror



Name	: Mr.DEVBRAT KUMAR	Requisition No.	: 780804
Age / Gender	: 28 Years Male	UHID Number	:
Referred By	: RMO	Reporting Date	: 12-Jan-2022 01:56:14PM
Station	: Direct	Payer Name	: MEDIWHEEL PVT LTD
Date of Collection	: 12-JAN-22 11:13	Ward	:

**LAB SERVICES - HAEMATOLOGY
TEST REPORT**

BLOOD GROUPING AND RH FACTOR

Test	Results	Units	Reference Interval
BLOOD GROUP ABO Rh	"B" POSITIVE		--
ESR	15	mm/hr	0 - 10

-----End of Report-----

Dr. PRITI SHAH

Pathologist

Lab Incharge

Page 1 of 1

Dr. PRADIP KUMAR

MICROBIOLOGIST

ANSAR

H= High L=Low P=Panic

(This is only professional opinion and not the diagnosis, Please correlate clinically)

Q Block South City 11, Sohna Road, Main Sector-47, Gurgaon, Haryana
Ph.: 0124-49000000 (100 Lines) Fax : 0124-2218733 E-mail : parkmedicenters@gmail.com

PARK GROUP OF HOSPITALS : West Delhi • South Delhi • Gurgaon • Karnal • Panipat • Hodal • Ambala • Behror

the **health** care providers

the **health** care providers



Patient Name	: Mr.DEVBRAT KUMAR	IP/OP No	:
Age/ Sex	: 28 Years Male	Req No	: 780804
Unit name	: RMO	Report Date/Time	: 12/01/2022
Consultant Nm	: RMO	Patient's Phone	:
Reqdt/Reqtm	: 12/01/2022	Payer Name	: MEDIWHEEL PVT LTD

X-RAY TEST REPORT

Test Name - X-RAY CHEST AP/PA

X-RAY CHEST P.A. VIEW

The lungs on the either side show equal translucency.

No focal lung lesion is seen.

The pleural spaces are normal.

Both hila are normal in size, have equal density and bear normal relationship.

The heart and trachea are central in position and no mediastinal abnormality is visible.

The cardiac size is normal for patient age and view.

The domes of the diaphragms are normal in position, and show smooth outline.

IMPRESSION : NORMAL STUDY.

To be correlated clinically

DR. SAKET RUPRAMKA
MBBS, MD
CONSULTANT RADIOLOGIST

DR. MANJEET SEHRAWAT
MBBS, MD, PDCC
CONSULTANT RADIOLOGIST

DR. BINOD CHOUDHARY
MBBS, MD
CONSULTANT RADIOLOGIST

DR. ANSHU K SHARMA
MBBS, MD
CONSULTANT RADIOLOGIST

(This is only professional opinion and not the diagnosis. Please correlate clinically.)

Gurgaon : Q Block, South City-II, Sohna Road, Sector - 47, Gurugram-122002, (Haryana)
Faridabad : J-Block, Sector - 10, Near Court, Faridabad - 121004, (Haryana)

• Helpline : 0124-4900000
• Helpline : 0129-4200000



PARK HOSPITAL

(PARK MULTI SPECIALITY HOSPITAL)
Q-Block South City -II Shona Road Main Sec-47
Gurgaon ,Haryana-122002
Helpline : 0124-4900000(100 Lines)

REQUISITION SLIP / CASH BILL RECEIPT

Req No. : 780804	Date : 12/01/2022 10.18 AM
Name : Mr. DEVBRAT KUMAR	REF.DOCTOR : Corporate/Organisation
Age/Sex : 28 Years11 Months / Male	CONS.DOCTOR : Dr. RMO
	Source : MEDIWHEEL PVT LTD
	PATIENT PHONENO : null

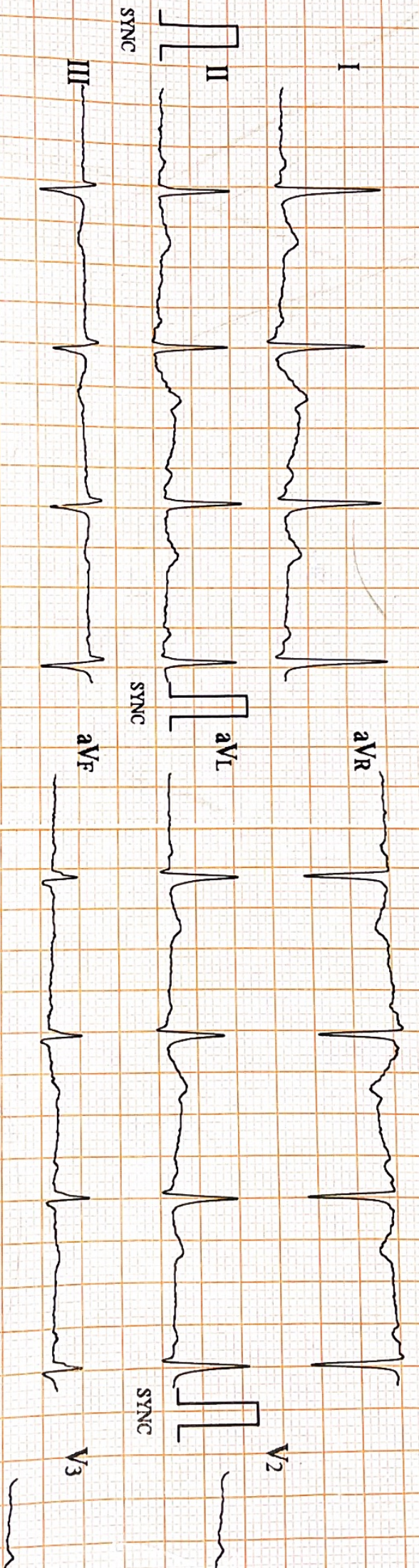
SNo.	Code	Investigation/s	DEPTNM	Rate Rs.
MEDIWHEEL HEALTH CHECKUP MALE BLOW				1,800.00
1	BIOC-	BLOOD SUGAR 2	LAB	
2	BIOC-	BLOOD SUGAR	LAB	
3	PATH-	STOOL ROUTINE	LAB	
4	PATH-	URINE ROUTINE	LAB	
5	HAEM	BLOOD GROUPING	LAB	
6	HAEM	CBC	LAB	
7	HAEM	ESR (WESTERGREN)	LAB	
8	MIBO-	URINE C/S	LAB	
9	USG-1	USG WHOLE	RADIOLOGY	
10	TSH	THYROID PROFILIE	LAB	
11	175	LFT (LIVER	LAB	
12	BIOC-	KFT (RENAL	LAB	
13	1514	LIPID PROFILE	LAB	
14	37	ECG	CARDIOLOGY	
15	XRAY-	X-RAY CHEST AP/PA	RADIOLOGY	
16	TT	TMT/ECHO	CARDIOLOGY	

25mm/s 0.5~25Hz

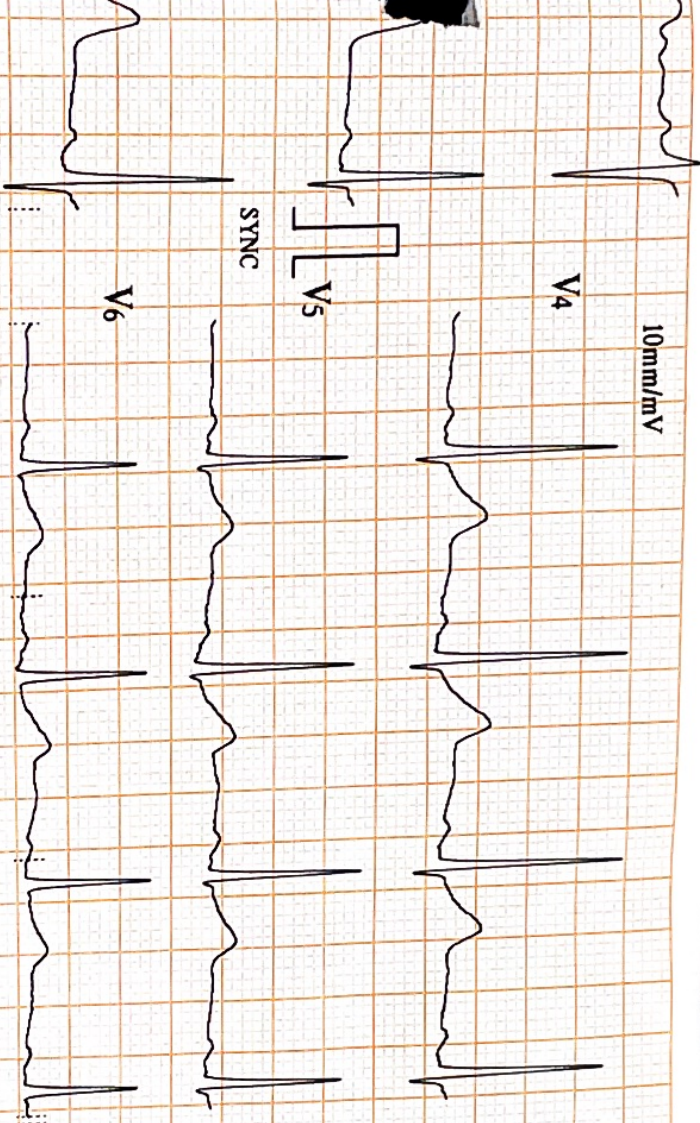
10mm/mV

10mm/mV

10mm/mV



ECG-1203 V2.000(BIOS:V2.000/AMP:V1.001) 2016-01-01 00:42



ID : 0170

HR : 75

bpm

Name:

Mr. Andrew

R-R : 792

ms

QRS : 95

ms

QT/QTc : 373/419

ms

P/QRS/T : 28/12/12

°

RV5/SV1 : 1.440/0.940 mV

mV

RV5+SV1 : 2.380

mV

Age :

28

Sex :

M

Unconfirmed report Verified by:

12/01/2022

Sinus Rhythm

ST Elevation

Marked Counter Clockwise Rotation

Mild Left Axis Deviation