



Report :

TEST OBJECTIVE : ROUTINE CHECK UP
RISK FACTOR : MALE
ACTIVITY : MODERATE ACTIVE
MEDICATION : NONE
REASON FOR TERMINATION : TEST COMPLETE, HEART RATE ACHIEVED
EXERCISE TOLERANCE : GOOD
EXERCISE INDUCED ARRHYTHMIAS : NO
HAEMODYNAMIC RESPONSE : NORMAL
CHRONOTROPIC RESPONSE : NORMAL
FINAL IMPRESSION : STRESS TEST IS NEGATIVE FOR EXERCISE INDUCED ISCHAEMIC HEART DISEASE

DIPAK



981 / DIPAK / 25 Yrs / M / 0 Cms / 0 Kg Date: 28-Jan-2023 Refd By : BOB

Stage	Time	Duration	Belt Speed (mph)	Elevation	METs	Rate	% THR Achieved	BP	RPP	PVC	Comments
Supine	00:11	0:01	00.0	00.0	01.0	84	43 %	120/80	100	00	
Standing	00:36	0:01	00.0	00.0	01.0	81	42 %	120/80	097	00	
HV	01:16	0:01	00.0	00.0	01.0	071	36 %	120/80	085	00	
Warm Up	01:28	0:03	01.7	10.0	01.1	085	44 %	120/80	102	00	
ExStart	01:31	0:06	01.7	10.0	01.1	085	44 %	120/80	102	00	
BRUCE Stage 1	04:31	3:00	01.7	10.0	04.7	108	55 %	128/86	138	00	
BRUCE Stage 2	07:31	3:00	02.5	12.0	07.1	129	66 %	136/92	175	00	
BRUCE Stage 3	10:31	3:00	03.4	14.0	10.2	163	84 %	140/96	228	00	
PeakEx	10:35	0:07	00.0	00.0	10.3	160	82 %	140/96	224	00	
Recovery	11:34	1:00	00.0	00.0	04.3	114	58 %	136/88	155	00	
Recovery	12:34	2:00	00.0	00.0	01.0	119	61 %	130/88	154	00	
Recovery	12:43	2:08	00.0	00.0	01.0	105	54 %	130/88	136	00	

Findings :

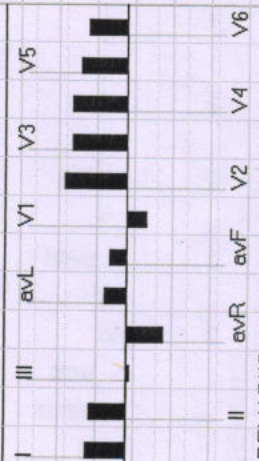
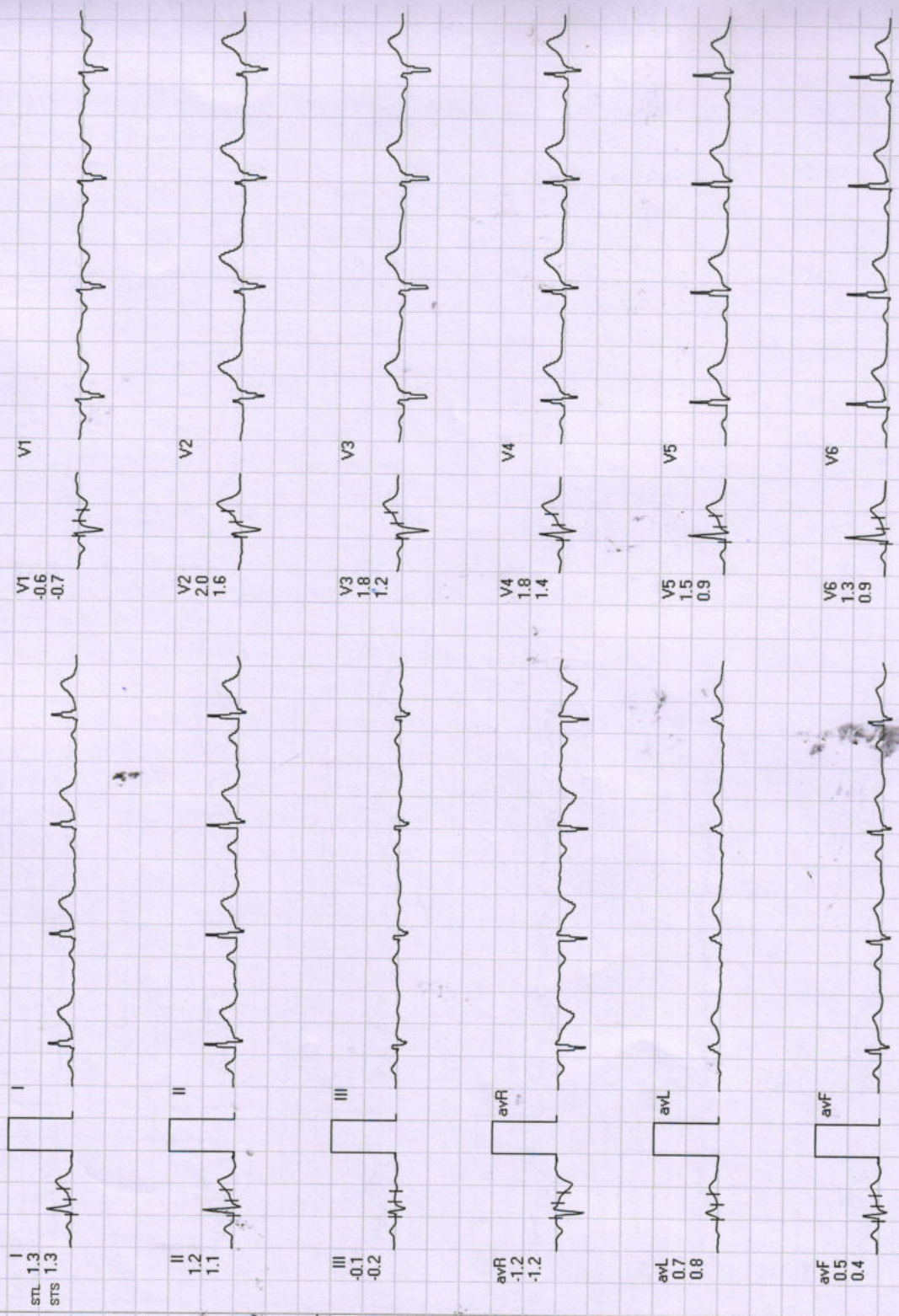Exercise Time : 09:05
 Max HR Attained : 163 bpm 84% of Target 195
 Max BP Attained : (Sys) 140/96
 Max WorkLoad Attained : 10.3 Good response to induced stress
 Test End Reasons : Test Complete, Heart Rate Achieved

Date: 28-Jan-2023 10:23:13 AM METS: 1.0/ 84 bpm 43% of THR BP: 120/80 mmHg Raw ECG/BLC On/ Natch On/ HF 0.05 Hz/LF 20 Hz

ExTime: 00:10 0.0 mph, 0.0%

80 mS Post J

4X

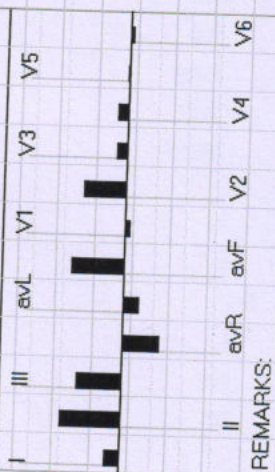
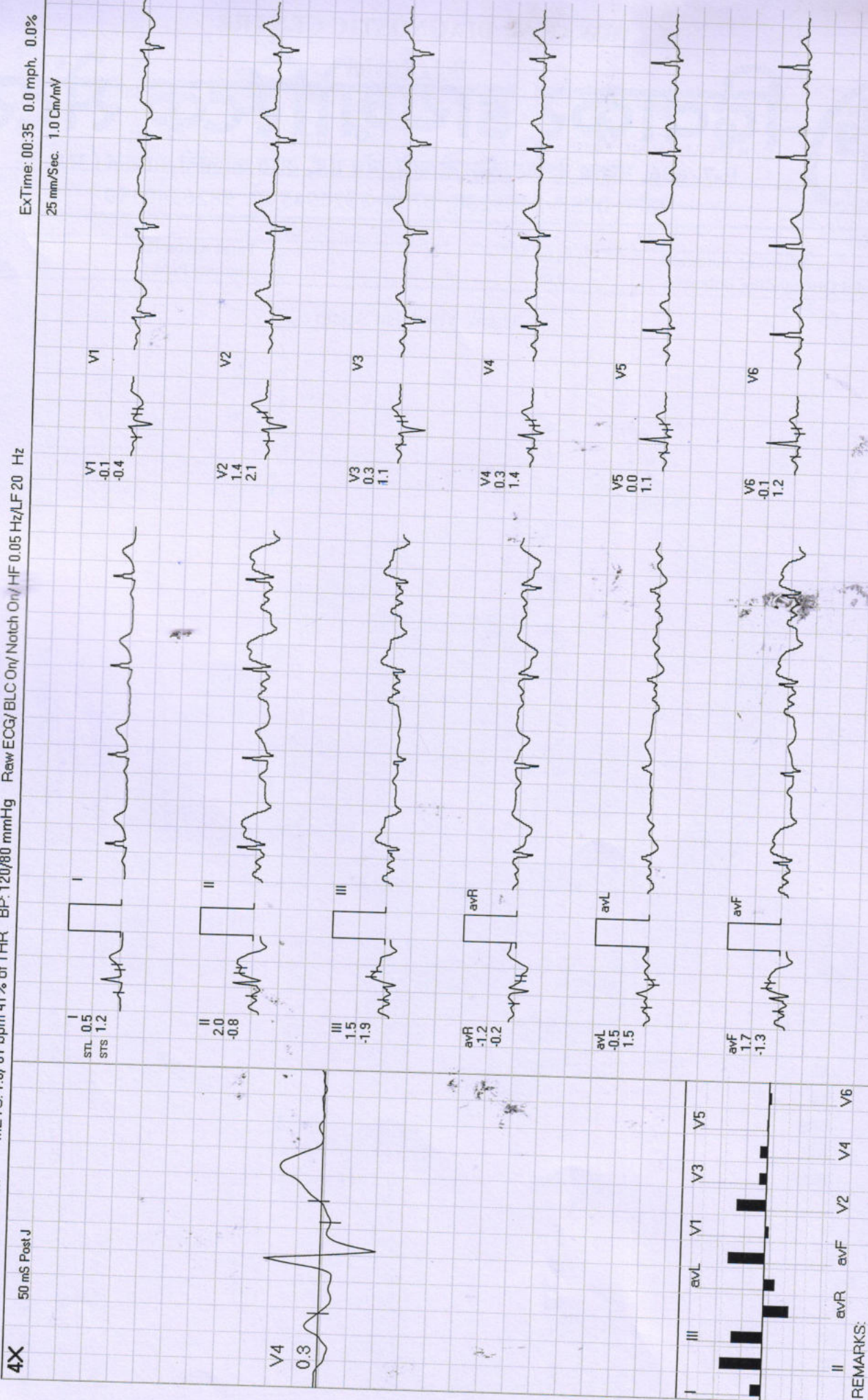


REMARKS:



Date: 28-Jan-2023 10:23:13 AM METS: 1.0/ 81 bpm 41% of THR BP: 120/80 mmHg Raw ECG/BLC On/ Notch On/ HF 0.05 Hz/LF 20 Hz

ExTime: 00:35 0.0 mph, 0.0%
25 mm/Sec. 1.0 Cm/mV



REMARKS:



HV

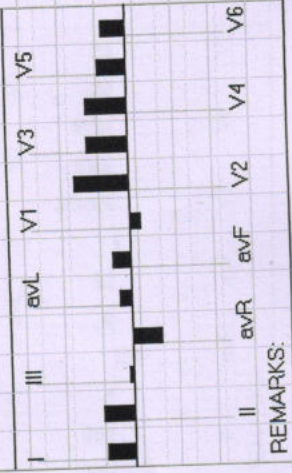
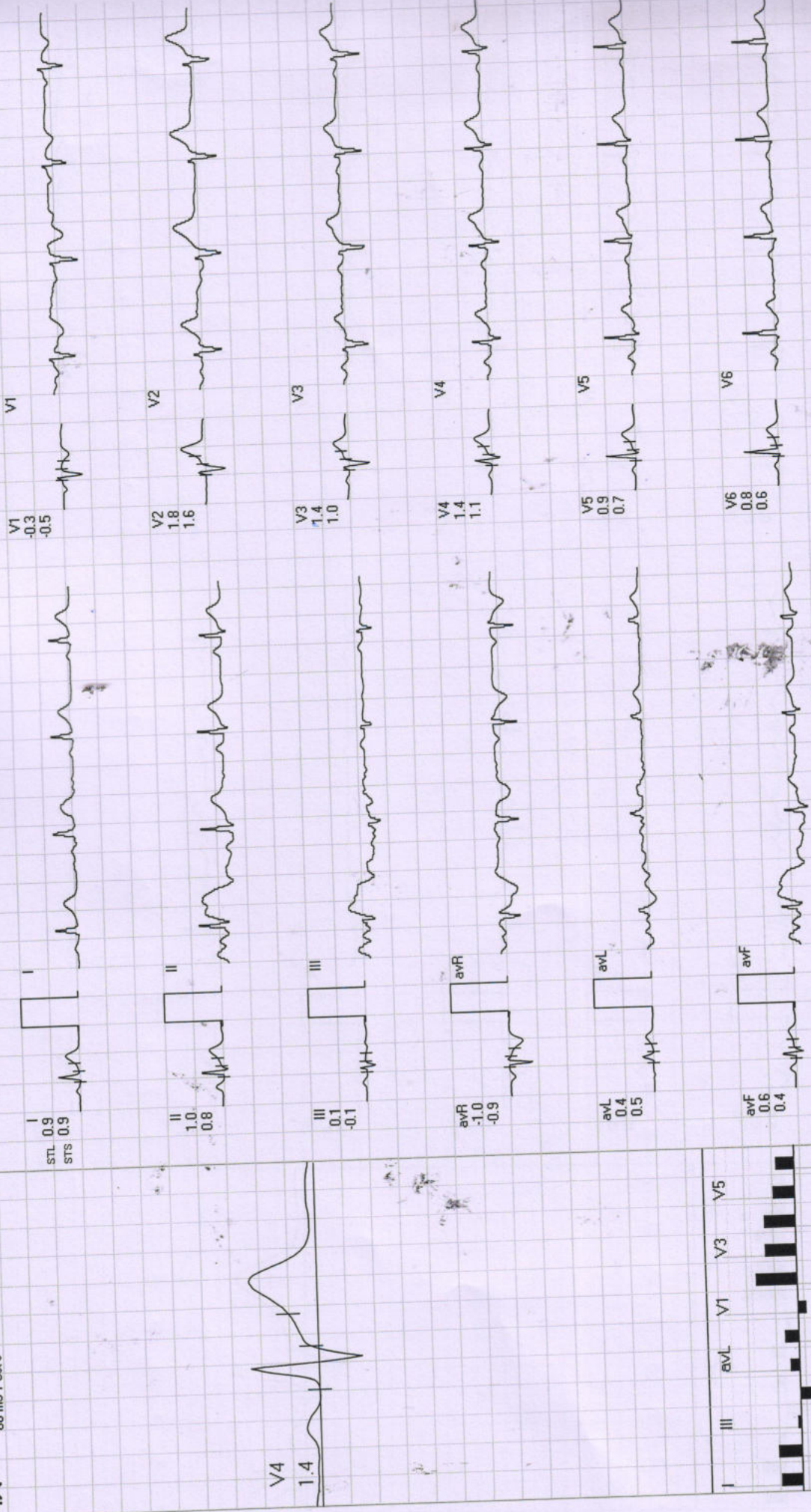
Diwakar Diagnostic Centre

9871 / DIPAK / 25 Yrs / M

ExTime: 01:15 0.0 mph, 0.0%

Date: 28-Jan-2023 10:23:13 AM METS: 1.0/ 71 bpm 36% of THR BP: 120/80 mmHg Raw ECG/BLC On/ Notch On/ HF 0.05 Hz/LF 20 Hz

4X 80 mS Post J



REMARKS:



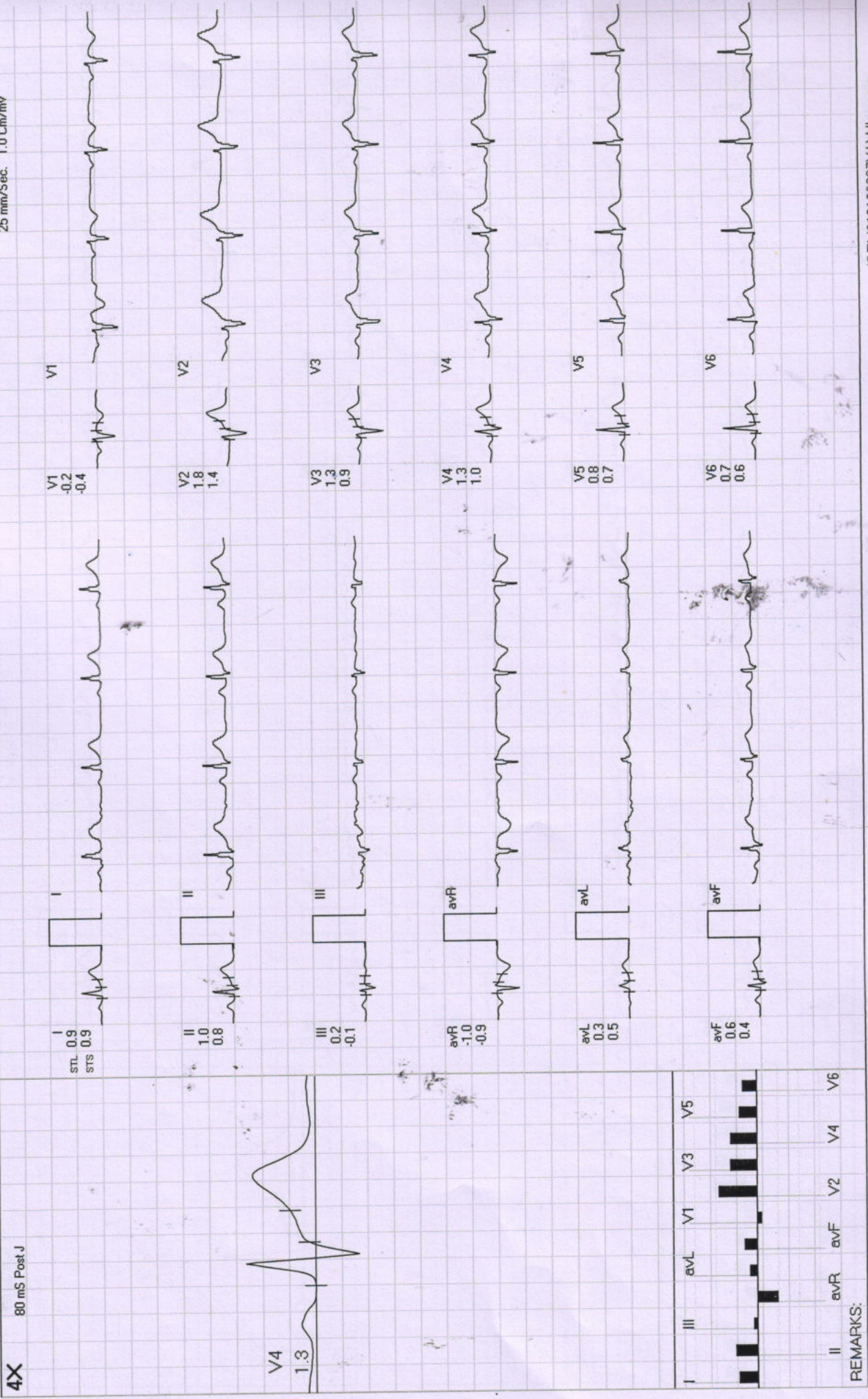
WARM UP

Diwakar Diagnostic Centre

981 / DIRAK / 25 Yrs / M

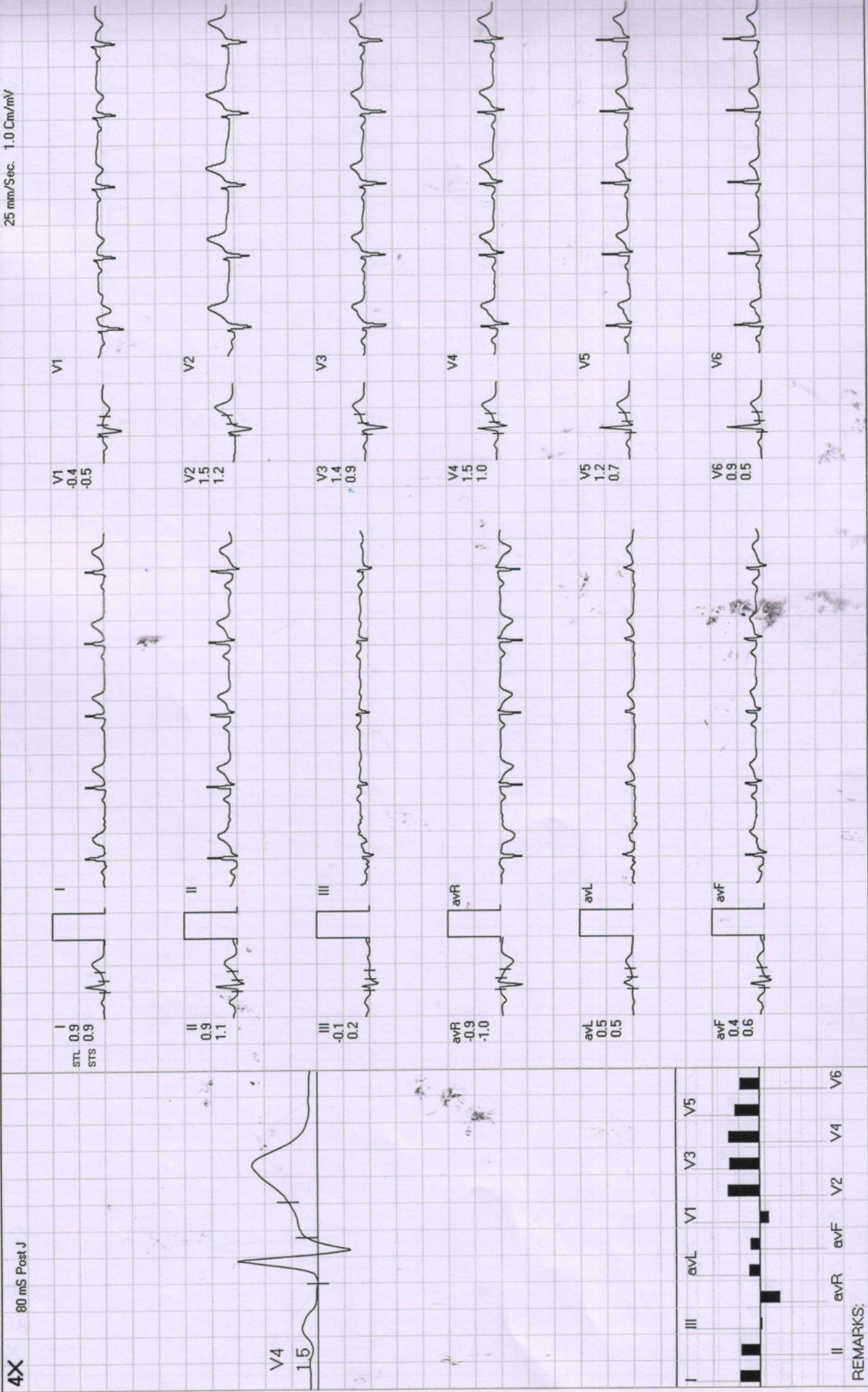
Date: 28-Jan-2023 10:23:13 AM METS: 1.0/78 bpm 40% of THR BP: 120/80 mmHg Raw ECG/BLC On/ Notch On/ HF 0.05 Hz/LF 20 Hz

ExTime: 01:27 1.0 mph, 0.0%
25 mm/Sec. 1.0 Cm/mV





Date: 28-Jan-2023 10:23:13 AM METS: 1.0/85 bpm 43% of THR BP: 120/80 mmHg Raw ECG/BLC On/ Natch On/ HF 0.05 Hz/LF 20 Hz
 ExTime: 00:00 0.0 mph, 0.0%
 25 mm/Sec. 1.0 Cm/mV



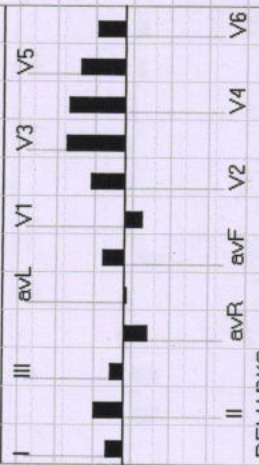

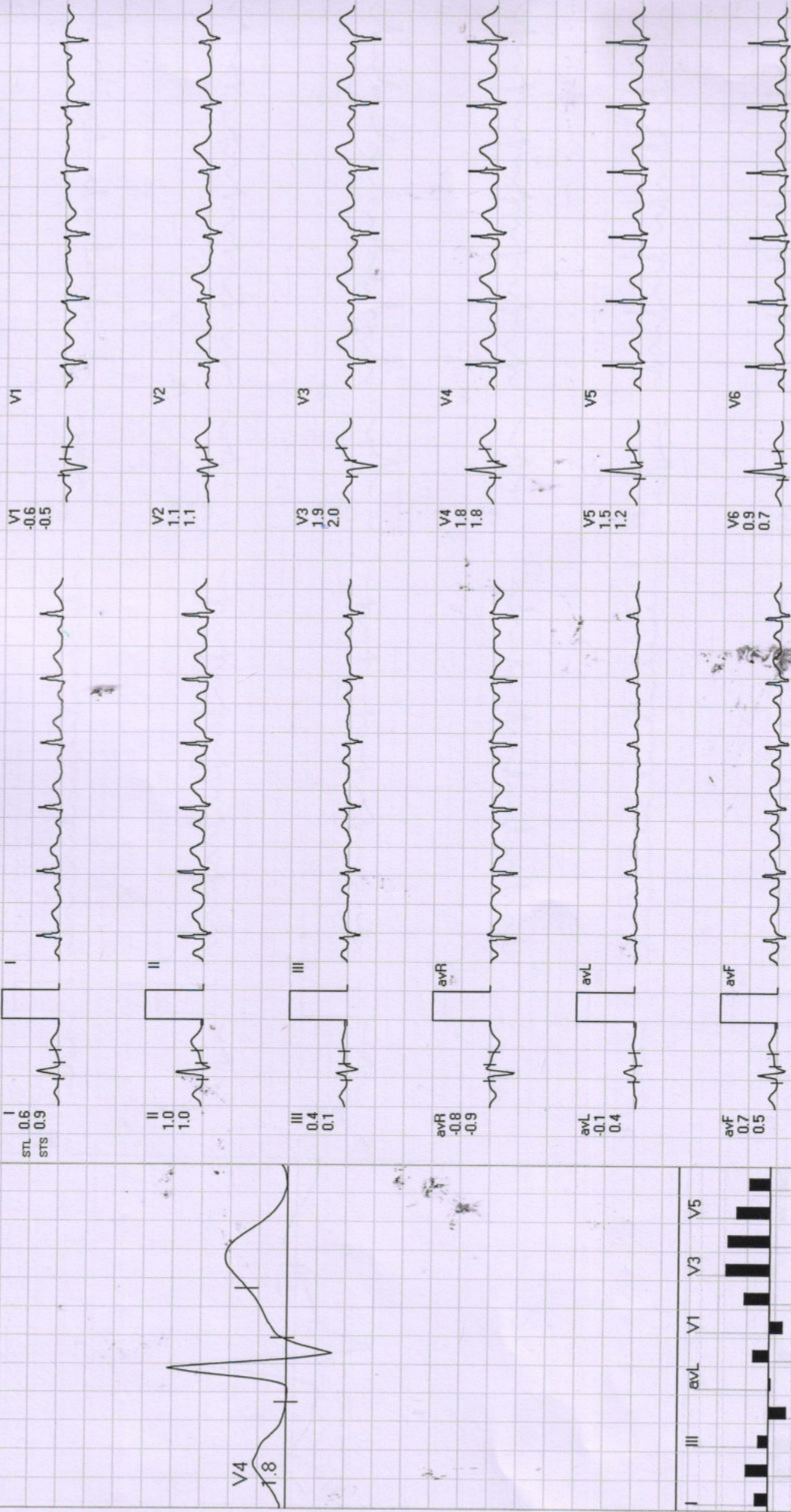
REMARKS:

Date: 28-Jan-2023 10:23:13 AM METS: 4.7/108 bpm 55% of THR BP: 128/86 mmHg Raw ECG/BLC On/ HF 0.05 Hz/LF 20 Hz

4X

80 ms Post J

25 mm/Sec. 1.0 Cm/mV



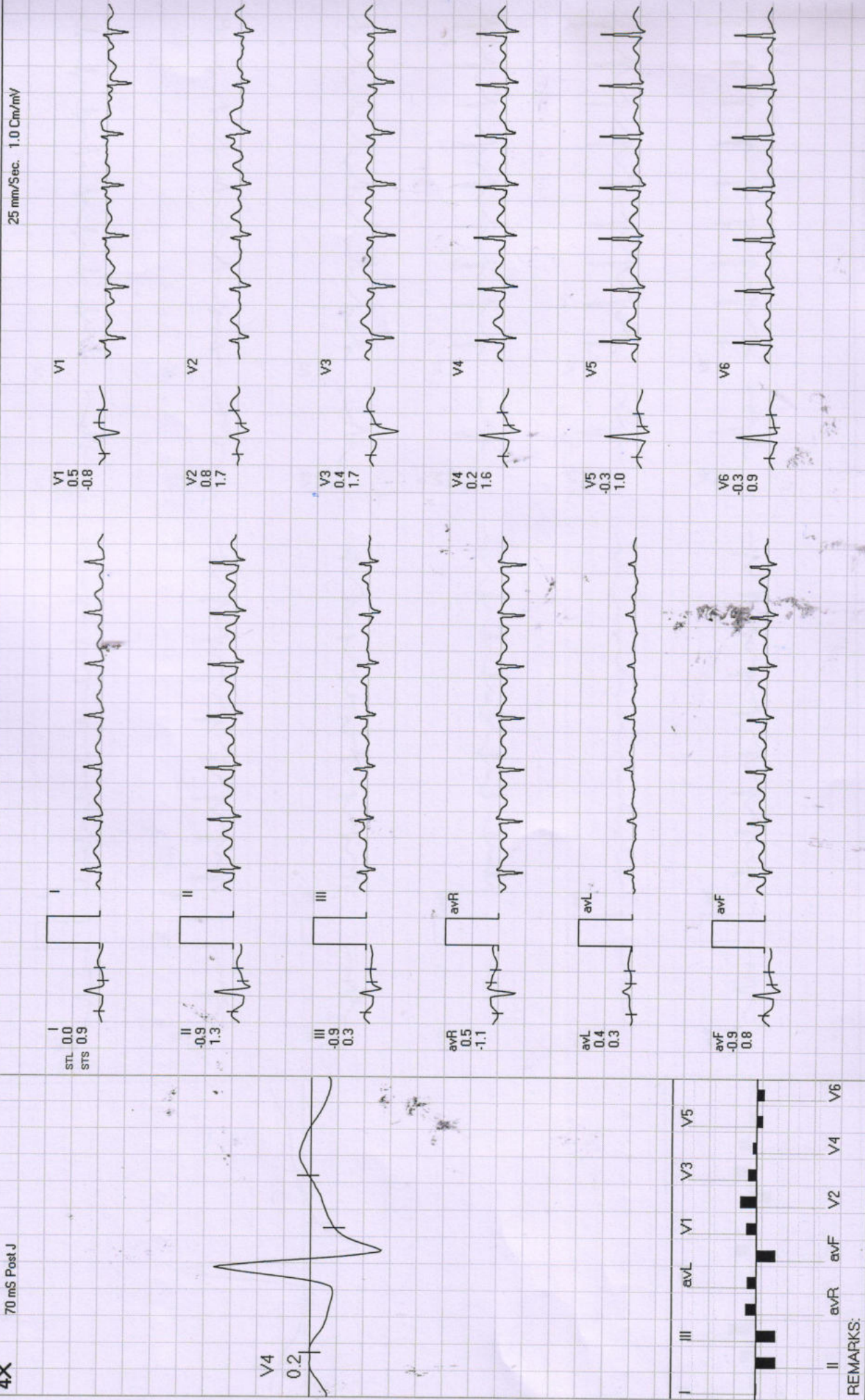
REMARKS:

Date: 29-Jan-2023 10:23:13 AM

METS: 7.1 / 129 bpm 66% of THR BP: 136/92 mmHg Raw ECG/ BLC-Orn/ Notch Onr/ HF 0.05 Hz/LF 20 Hz

ExTime: 06:00 2.5 mph, 12.0%

4X 70 mS Post J



REMARKS:



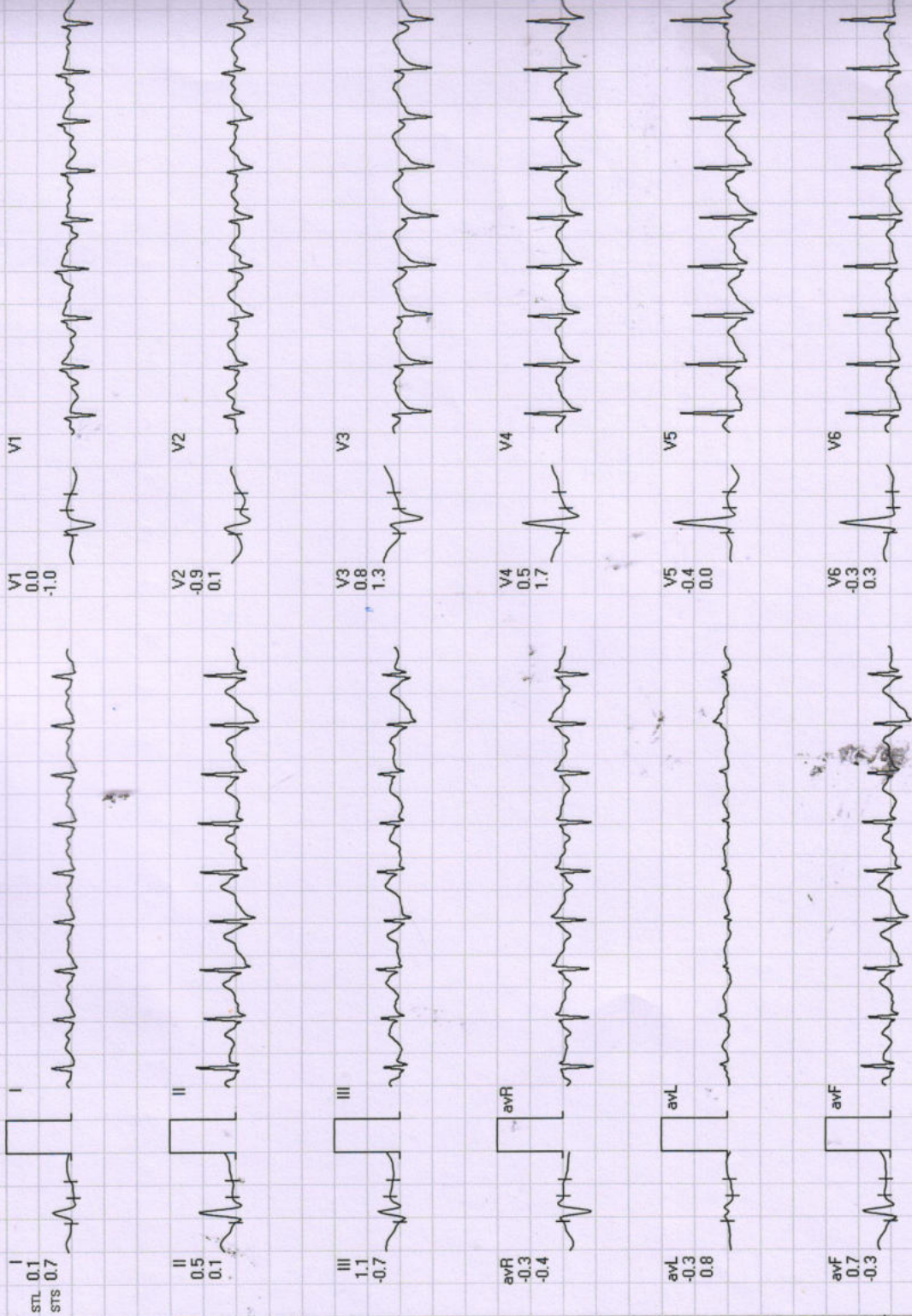
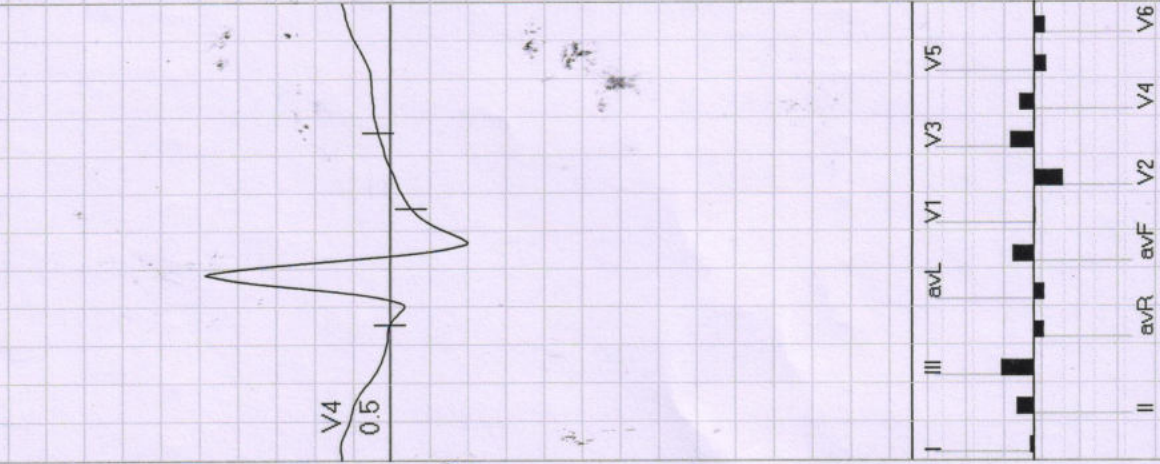
Date: 28-Jan-2023 10:23:13 AM

METS: 10.2/163 bpm 83% of THR BP: 140/96 mmHg Raw ECG/ BLC On/ Notch On/ HF 0.05 Hz/LF 20 Hz

ExTime: 09:00 3.4 mph, 14.0%

4X 60 ms Post J

25 mm/Sec. 1.0 Cm/mV



REMARKS:

Date: 28-Jan-2023 10:23:13 AM



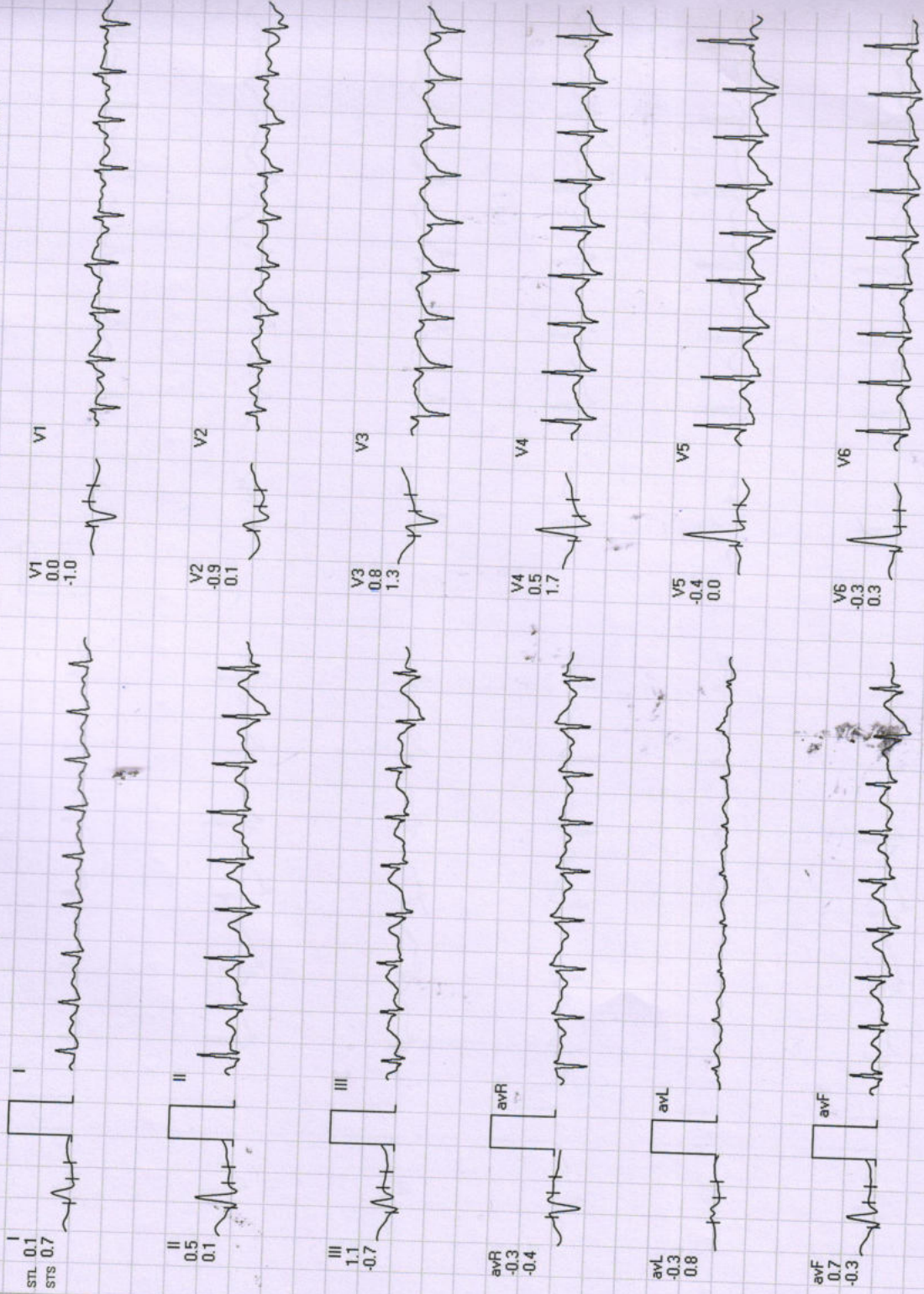
METS: 10.3 / 163 bpm 83% of THR BP: 140/96 mmHg Raw ECG/ BLC On/ Notch On/ HF 0.05 Hz/LF 20 Hz

4X

60 mS Post J

ExTime: 09:04 4.2 mph, 16.0%

25 mm/Sec. 1.0 Cm/mV



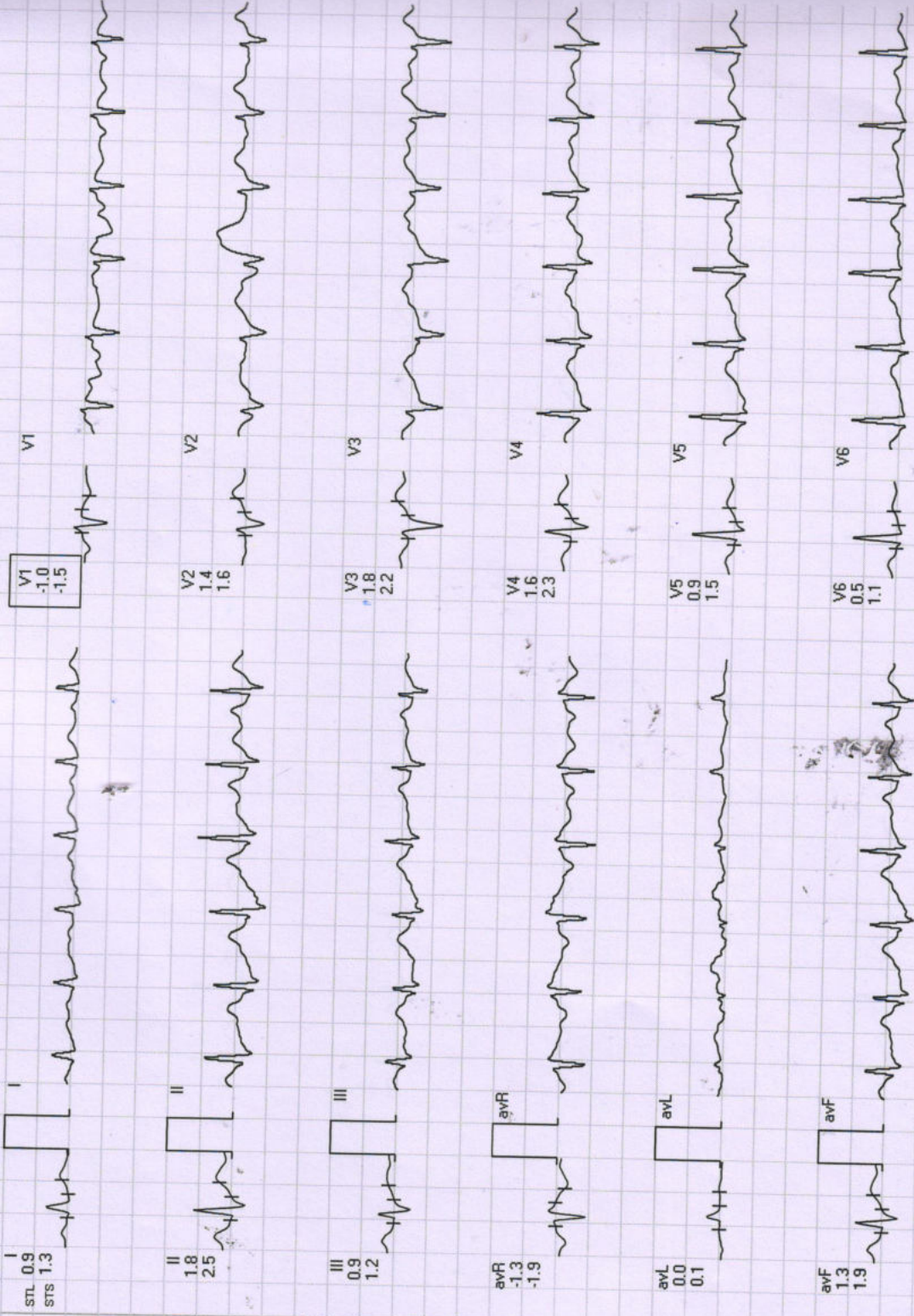


REMARKS:



Date: 28-Jan-2023 10:23:13 AM METS: 4.2/114 bpm 58% of THR BP: 136/88 mmHg Raw ECG/BLC On/ Notch On/ HF 0.05 Hz/LF 20 Hz

4X 70 mS Post J ExTime: 09:04 0.0 mph, 0.0% 25 mm/Sec. 1.0 Cm/mV



REMARKS:

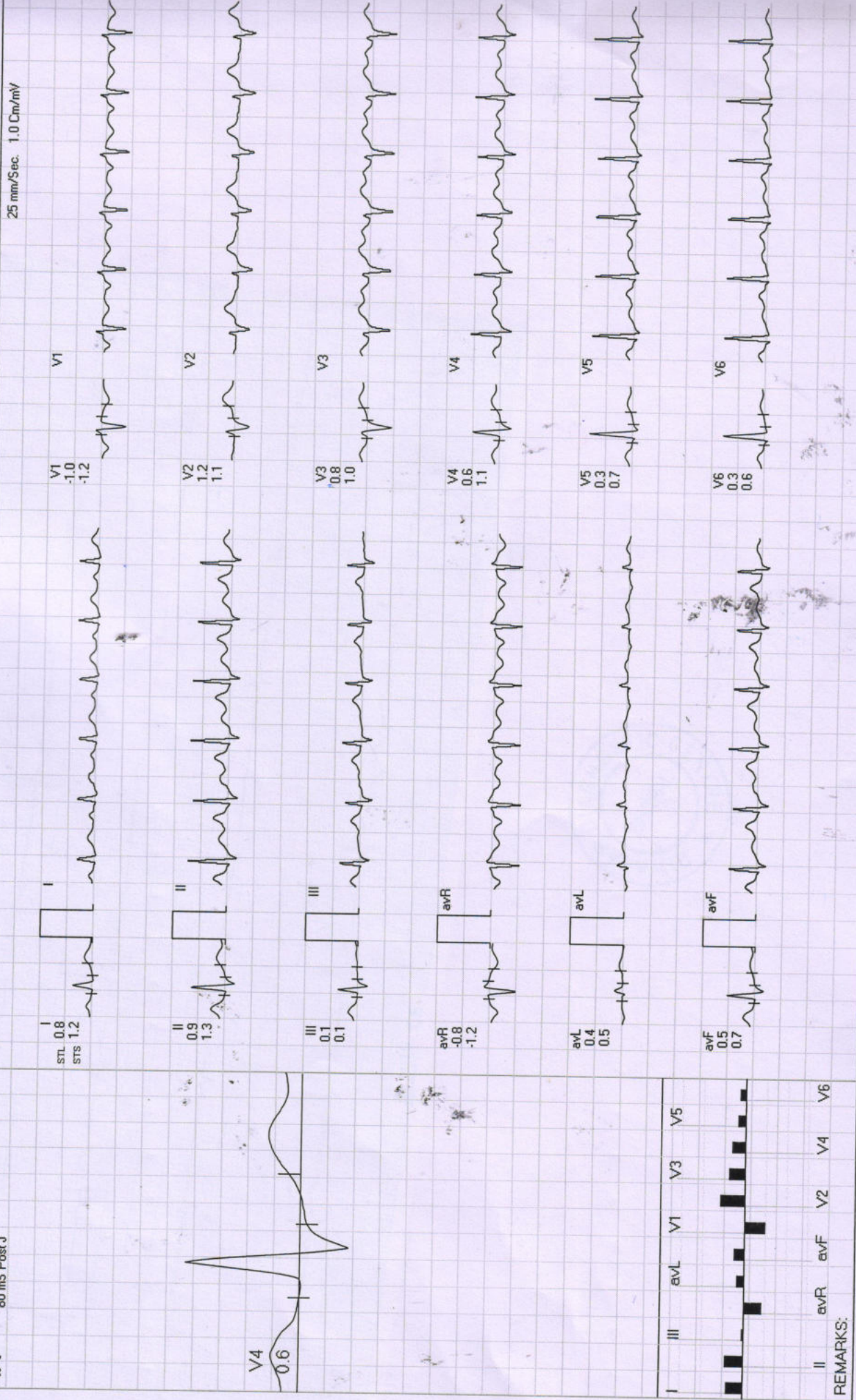
Date: 28-Jan-2023 10:23:13 AM

METS: 1.0/ 119 bpm 61% of THR BP: 130/88 mmHg Raw ECG/ BLC On/ Natch On/ HF 0.05 Hz/LF 20 Hz

4X

ExTime: 09:04 0.0 mph, 0.0%

80 mS Post J

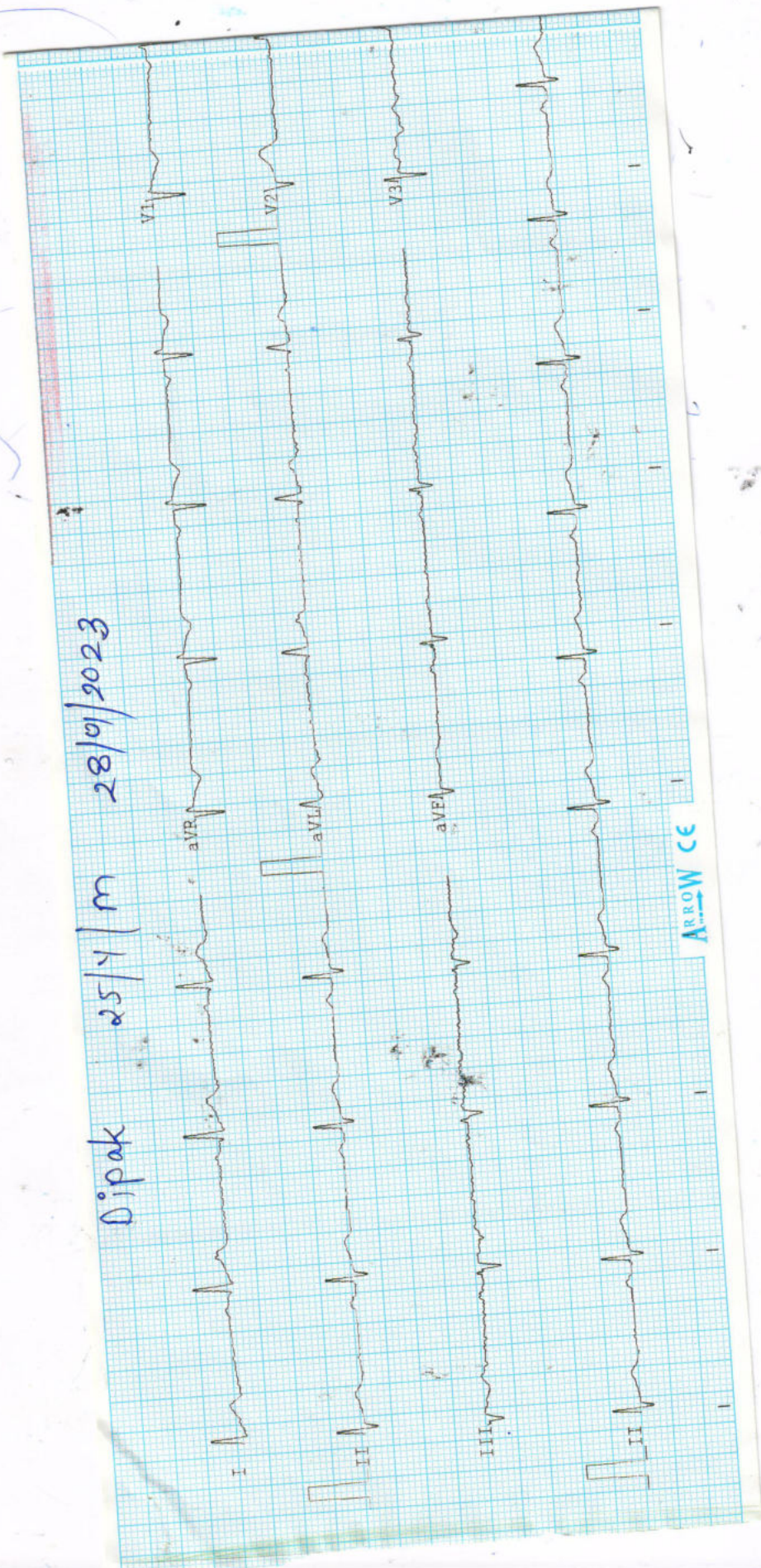


REMARKS:

28/01/2023

25/4/m

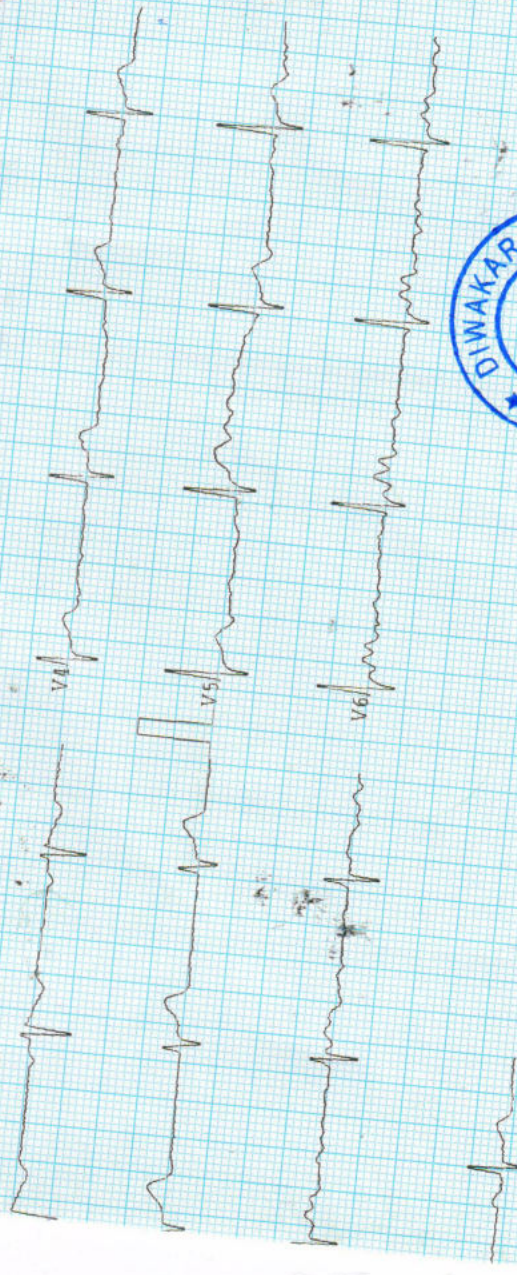
Dipak



ARROW CE

Observations:-

HR :- 63 bpm
R-R :- 938 ms
P-R :- 113 ms
QRS :- 56 ms
QT/QTc :- 325/335 ms
P Axis :- 05 °
R Axis :- 26 °
T Axis :- 32 °



Dumbak

Remarks :-

ARROW confirmed report

Dipak



आपका आधार क्रमांक / Your Aadhaar No. : 4349 6580 9129
VID : 9155 9129 9153 5755
भारत आधार, भरी पहचान

भारत सरकार
Government of India

डीपक
Dipak
लिंग/DOB: 01/01/1997
पुरुष/ MALE



Issue Date: 13/01/2018
Download Date: 16/12/2020

भारत सरकार
Government of India

आपका आधार क्रमांक / Your Aadhaar No. : 4349 6580 9129
VID : 9155 9129 9153 5755
भारत आधार, भरी पहचान



WHOLE ABDOMEN ULTRASOUND REPORT

Indication :

Liver appears normal / enlarged in size and shape with smooth in outline. Normal / increased parenchymal echogenicity is noted. No E/O focal lesion / IHBR dilatation is seen. Hepatic veins and portal veins appear normal.

No E/O Subdiaphragmatic Collection.

Gall Bladder is physiologically well distended / collapsed. No E/O echogenic foci in GB lumen. GB wall is normal / thickened. No E/O pericholecystic collection. common duct reveals normal course and caliber.

Pancreas appear normal in size, shape and echo texture with smooth contour. No peripancreatic pathology seen. (Not seen due to gases) Spleen is normal / enlarged in size and normal in echo texture. IVC and aorta appear to be normal. No evidence of lymphadenopathy is noted. No evidence of free fluid is noted.

Right Kidney is normal in size, shape and position. Corticomedullary differentiation (CMD) is well maintained. Normal cortical thickness is noted. No E/O hydronephrosis or calculus is noted.

PTO

PH

Advised clinical Correlation.

Impression : Normal study. *Left - Results have not changed*
over hydrocephalus

~~Left Ovary appears Enlarged / Normal in size, shape and echo texture.~~

~~Right Ovary appears Enlarged / Normal in size, shape and echo texture.~~

~~normal. Cervical and vaginal shadows appear normal.~~

~~Uterus is ante / retroverted and normal in size, shape and echotexture with smooth outline. No E/O focal lesion is noted, endometrial echo appear~~

~~No E/O focal lesion is noted.~~

~~Prostate is normal in size, shape and echo texture with smooth outline.~~

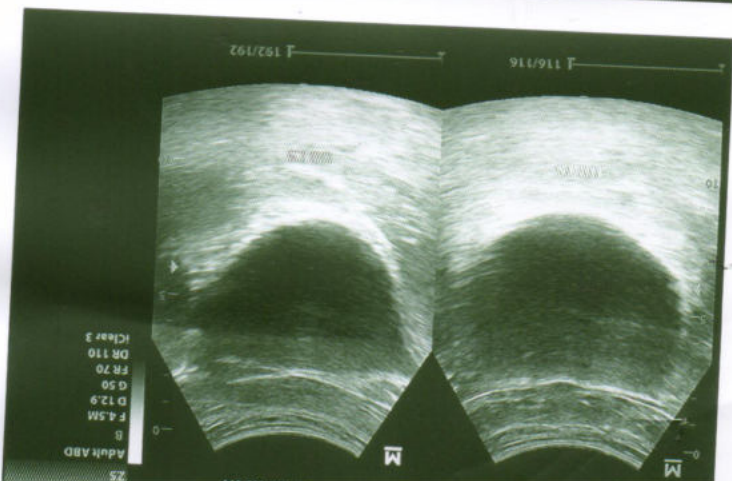
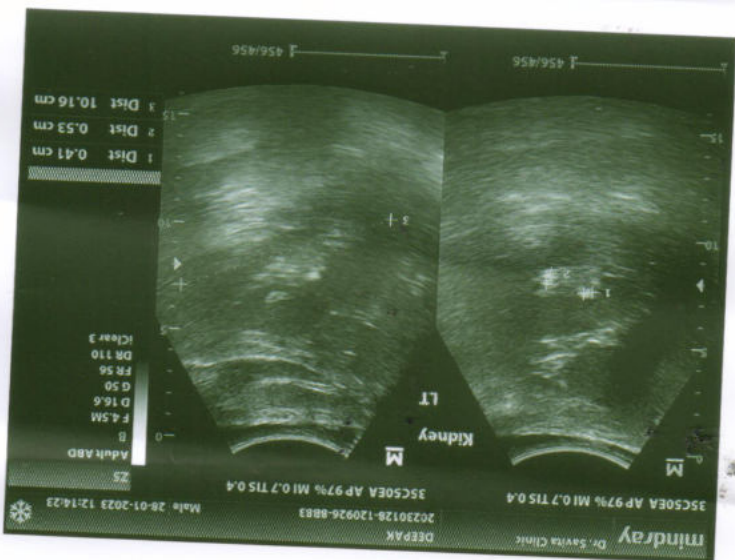
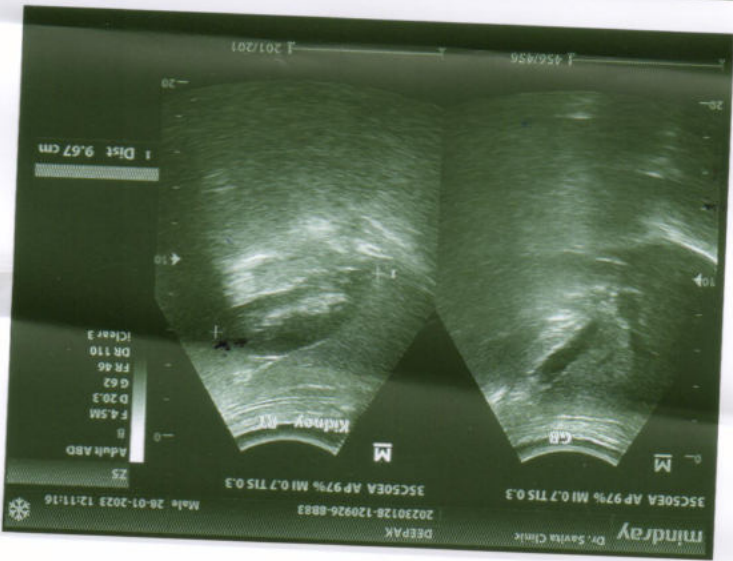
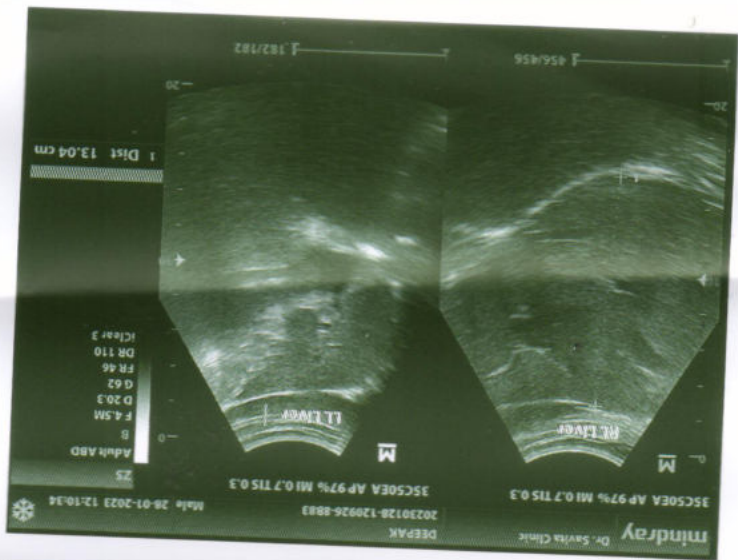
~~insignificant.~~

~~Urinary Bladder is well distended (physiological) / collapsed. Its contents are echo free. No E/O bladder wall thickening is noted. Post-void residue is~~

~~cortical thickness is noted. No E/O hydronephrosis or calculus is noted.~~

~~Left Kidney is normal in size, shape and position. CMD is well maintained. Normal~~

• 41 and 153um Arge. Med cal. 4th row seen. no hydrocephalus





PT Name :- Mr. Dipak

Age :- 25/M

Lab. No. :- 05

Date :- 28/01/2023

EXAMINATION OF BLOOD

TEST	RESULT	NORMAL VALUE
Haemoglobin	14.9gms%	Female 12-16gms%, Male 14-18gms%
Red Cell count	5.26	4.5-5.6 million /cumm
Platelete Count	1.41	1.5-5.6 Lac/cumm
Leucocytes per.cumm	6800/cumm	5000-11000/cumm
Neutrophils	53%	50-70%
Lymphocytes	36%	20-40%
Eosinophils	05%	0-7%
Monocytes	06%	2-8%
PCV	44.9	37-47
MCV	85.4	76-96
MCH	28.3	27-32
MCHC	33.1	31-35
ESR	08	Male 0-9, Female 0-20mm/FHR
Blood Group	"O" Positive	By slide method
Total Serum Cholesterol	178.0	100-250 mg%
Serum Triglyceride	148.0	Up to 150 mg%
Serum Cholesterol HDL	51.0	Up to 65 mg%
Serum Cholesterol LDL	97.4	Up to 125 mg%
VLDL	29.6	Up to 30 mg%
S.Bilirubin(Total)	0.9	0.2-1.0mg/dl
Direct	0.5	0.0-0.25mg/dl
Indirect	0.4	
SGOT	26.0	5-35U/L
SGPT	30.0	8-40U/L
Alk Phosphatase	8.9	3-13 KA units
S. Protein(Total)	7.0	6.0-8.0mg%
Albumin	4.9	3.7-5.3mg%
Globulin	2.4	1.5 to 3.5 mg%
Blood Urea	22.0	Up to 40 mg%
S.Creatine	0.98	0.5-1.4mg/dl
S. Uric Acid	6.0	3.5-7.5mg%
G6TP	24.0	5-35 UL/dl
Fasting Blood Sugar	84.2	Up to 110 mg%
PP Blood Sugar	110.0	Up to 125 mg%
Glycosylated Hemoglobin	5.1	Below - 6.0 % -Non Diabetic control 6-7 % -Excellent control Above- 8 % -Poor control
Thyrod Stimulating Hormone(TSH)	3.9	0.27-4.2

Dr. B. M. Jaiswal
 Pathologist
 MBBS, DCP
 Consultant Pathologist



All test have technical limitation. Collaborative clinic pathological interpretation is mandatory. In case of disparity test may be repeated immediately. Typographical mistakes should be get correct instantly. This report is not valid for medico legal purpose



Pathologist

Dr. B. M. Agarwal
MBBS, DCP
Consultant Pathologist

A. PHYSICAL EXAMINATION	
1. Colour	Pale Yellow
2. Appearance	Clear
3. Specific Gravity	Q.N.S.
B. CHEMICAL EXAMINATION	
1. Reaction	Acidic
2. Albumin	Nil
3. Sugar	Nil
4. Bile Salts	Absent
C. MICROSCOPIC EXAMINATION	
Pus Cells	2-3/HPF
R.B.C.	Nil
Epithelial Cell	2-3/HPF
Cast	Nil
Crystals (Cal. Oxa)	Nil
Bacteria	Nil
Amorphous	Nil
T. Vaginitis	Nil

URINE ANALYSIS

Pt Name :- Mr. Dipak
Age :- 25/M
Lab. No. :- 05
Date :- 28/01/2023



दिवाकर डायग्नोस्टिक सेंटर
E-7/636, पंजाब नेशनल बैंक के पास, मैन रोड, अरुण कॉलोनी, भीपाल (म.प्र.)
फॉन : 9826340190



Radiologist

Dr. B. M. Agarwal
MD, Radiology
Consultant Radiologist

-NO CARDIO PULMONARY PATHOLOGY
-CORRELATE WITH CLINICAL FINDINGS.

IMPRESSION

Both domes and diaphragm normal

Both cp angles clear

Cardiac border normal

Both hilers normal

Both Lungs Field Clear.

Thoracic cage normal

Tricia Central

.....
REPORT

Pt Name :	Mr. Dipak
Age :	25/M
Ref. By :	BOB
Lab. No. :	05
Date :	28/01/2023
Skigram	X Ray Chest PA View
Radiologist	Dr. B. M. Agarwal MD (Radiology)



डिवाकर डायग्नोस्टिक सेंटर
E-7/636, पंजाब नेशनल बैंक के पास, मैन रोड, असेा कॉलोनी, भापाल (म.प्र.)
मॉ : 9826340190