

Facilities:

All clinical Biomedical & Hematology Investigations including Bone Marrow Examination
VPT, Podiascan & Complete Foot Care (First Time in Purvanchal)
All Hormonal Investigation by Chemiluminescent Method
Visceral Fat by (AB-140) Ambulatory BP Monitoring
CGMS & Insulin Pump Available
PFT, 2D-ECHO (Color Doppler), Holter, TMT, Cardiac-3 available
VIA, VILI, Colposcopy available
Special Endocrinological Investigation Protocols.

ISO 9001:2008 Certified
Mobile: 9389994334, 9554572190, 9453837595



Panacea Pathology

Clinical Reference Lab

Persistence, Preparedness and Precision
EQAS (CMC Vellore Attached) & IQAS System
पूर्वांचल की सर्वोत्तम गुणवत्ता वाली पैथोलॉजी

PATIENT NAME : ANUPAM KUMARI

AGE/GENDER : 27YRS/FEMALE

REFD BY DR. : ARCO FEMI HEALTHCARE LTD.

RECEIVED DATE : 17-02-2023(09:30AM)

SAMPLE : BLOOD & URINE

REPORT DATE : 17-02-2023(02:00PM)

PATHOLOGY REPORT

LIPID PROFILE, SERUM

TEST	LAB TEST VALUES	NORMAL RANGE
BLOOD CHEMISTRY		
TOTAL CHOLESTEROL (SERUM)	144.0	Desirable:- < 200 mg/dl Borderline:- 200 – 239 mg/dl High:- > 240 mg/dl
TRIGLYCERIDES (SERUM)	132.0	35 – 170 mg/dl
HDL CHOLESTEROL (SERUM)	38.0	35.30 – 79.50 mg/dl
LDL CHOLESTEROL (SERUM)	89.6	< 130 mg/dl
VLDL	26.4	< 40 mg/dl
CHOLESTROL/HDL RATIO	3.81	< 3.0 Low Risk Ratio 3.0 – 5.0 Avg Risk > 5.0 High Risk
LDL/HDL RATIO	2.10	< 3 Ratio

BLOOD GROUP

TEST	LAB TEST VALUES
BLOOD GROUP ABO & RH FACTOR	
BLOOD GROUP	"B"
RH FACTOR	POSITIVE

GLYCOSYLATED HEMOGLOBIN (HBA1C)

TEST	LAB TEST VALUES	NORMAL RANGE
HBA1C	5.7	Normal : <5.97 % Good Control : 5.97 – 6.81% Fair Control : 6.81 – 7.65% Poor Control : >7.65%

THYROID PROFILE (T3, T4, TSH)

TEST	LAB TEST VALUES	NORMAL RANGE
THYROID FUNCTION TEST		
T3	1.12	0.60 – 1.81 ng/ml
T4	7.56	4.50 – 10.90 ug/dl
TSH	3.18	0.39 – 6.10 uIU/mL

PAGE 2

Lab Technician

PANACEA HOSPITAL
(A UNIT OF ARCO HEALTH CARE PVT. LTD.)
REG. NO.: AL-1500
B.36/44 B-4, KABIR NAGAR
DURGAKUND, VARANASI

Timing : 8.00 a.m. to 9.00 p.m. (Sunday 8.00 a.m. to 3.00 p.m.)

This Report is not valid for medico legal purpose

Note: These tests have technical limitations. Clinico-pathological interpretation is necessary. In case of any disparity test may be repeated immediately.

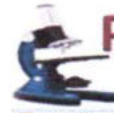Address : 36/44 FK Kabir Nagar, Durgakund, Varanasi – 221005

Email: dramishra@gmail.com, drpallaviojha@gmail.com Website: panaceahospital.org

Facilities:

All clinical Biomedical & Hematology Investigations including Bone Marrow Examination VPT, Podiascan & Complete Foot Care (First Time in Purvanchal) All Hormonal Investigation by Chemiluminescent Method Visceral Fat by (AB-140) Ambulatory BP Monitoring CGMS & Insulin Pump Available PFT, 2D-ECHO (Color Doppler), Holter, TMT, Cardiac-3 available VIA, VILI, Colposcopy available Special Endocrinological Investigation Protocols.

ISO 9001:2008 Certified
Mobile: 9389994334, 9554572190, 9453837595



Panacea Pathology

Clinical Reference Lab

Persistence, Preparedness and Precision
EQAS (CMC Vellore Attached) & IQAS System
पूर्वांचल की सर्वोत्तम गुणवत्ता वाली पैथोलॉजी

PATIENT NAME : ANUPAM KUMARI	AGE/GENDER : 27YRS/FEMALE
REFD BY DR. : ARCO FEMI HEALTHCARE LTD.	RECEIVED DATE : 17-02-2023(09:30AM)
SAMPLE : BLOOD & URINE	REPORT DATE : 17-02-2023(02:00PM)

PATHOLOGY REPORT

LIVER PROFILE TEST, SERUM

TEST	LAB TEST VALUES	NORMAL RANGE
BIO CHEMISTRY		
TOTAL BILIRUBIN	0.70	0.0 – 1.1 mg/dl
DIRECT BILIRUBIN	0.25	0.0 – 0.2 mg/dl
INDIRECT BILIRUBIN	0.45	< 0.90 mg/dl
SGOT (AST)	21.0	0 – 52 mg/dl
SGPT (ALT)	24.0	0 – 39 mg/dl
GGT (GYT)	18.6	< 55 U/L

URINE ROUTINE EXAMINATION

TEST	LAB TEST VALUES	NORMAL RANGE
PHYSICAL EXAMINATION		
QUANTITY	30	ML
COLOUR	STRAW	PALE YELLOW
APPEARANCE	CLEAR	CLEAR
SPECIFIC GRAVITY	1.005	1.01 – 1.03
PH	6.0	4.7 – 7.5
CHEMICAL EXAMINATION		
GLUCOSE	Not Detected	Not Detected
PROTEIN	NIL	Not Detected
MICROSCOPIC EXAMINATION		
PUS CELLS	1-2	0-5
RBC	Not Detected	Not Detected
EPITHELIAL CELLS	2-3	0-5
CASTS	Not Detected	Not Detected
CRYSTALS	Not Detected	Not Detected
BACTERIA	Not Detected	Not Detected

RANDOM/FASTING BLOOD SUGER

TEST	LAB TEST VALUES	NORMAL RANGE
RBS/FBS		
RANDOM BLOOD SUGAR	98.0	125-140 mg/dl
FASTING BLOOD SUGER	64.0	70-125 mg/dl

----- End of Report -----

Lab Technician

PANACEA HOSPITAL
(A UNIT OF ARCO HEALTH CARE PVT. LTD.)
REG. NO.: AL-1500
B.36 M.D. Pathology NAGAR
DURGAKUND, VARANASI

Timing : 8.00 a.m. to 9.00 p.m. (Sunday 8.00 a.m. to 3.00 p.m.)

This Report is not valid for medico legal purpose

Note: These tests have technical limitations. Clinico-pathological interpretation is necessary. In case of any disparity test may be repeated immediately.

Address : 36/44 FK Kabir Nagar, Durgakund, Varanasi – 221005

Email: dramishra@gmail.com, drpallaviojha@gmail.com **Website:** panaceahospital.org



PANACEA HOSPITAL

B 36/44 F.K KABIR NAGAR, DURGAKUND
TOLLFREE NO-18001233070.
Whatsapp No - 8795832852
www.piire.org



OP Slip

Print Date : 17-Feb-2023 08:53AM



UHID No :- UD-22230003653	OP No :- OP-22230013585	OP Date :- 17 Feb 2023 8:53AM
Patient Name :- Mrs Anupam Kumari Bank of Baroda	Age/Sex :- 31 Y/Female	Mobile No :- 7892502380
Husband :- Jha Shankar Kumar	Department :- DIABETES, ENDOCRINOLOGY & METABOLIC PHYSICIAN	
Pay Type :- Cash	Consultant :- Dr ASHUTOSH MISHRA (MD(MEDICINE), IMS, BHU)	
Token No :- NOR. -2	Paid/Bal :- 0.00 /500.00	
Patient Type :- Normal		
Address :- Near Moonstar School Myorpur, SONEBHADRA		

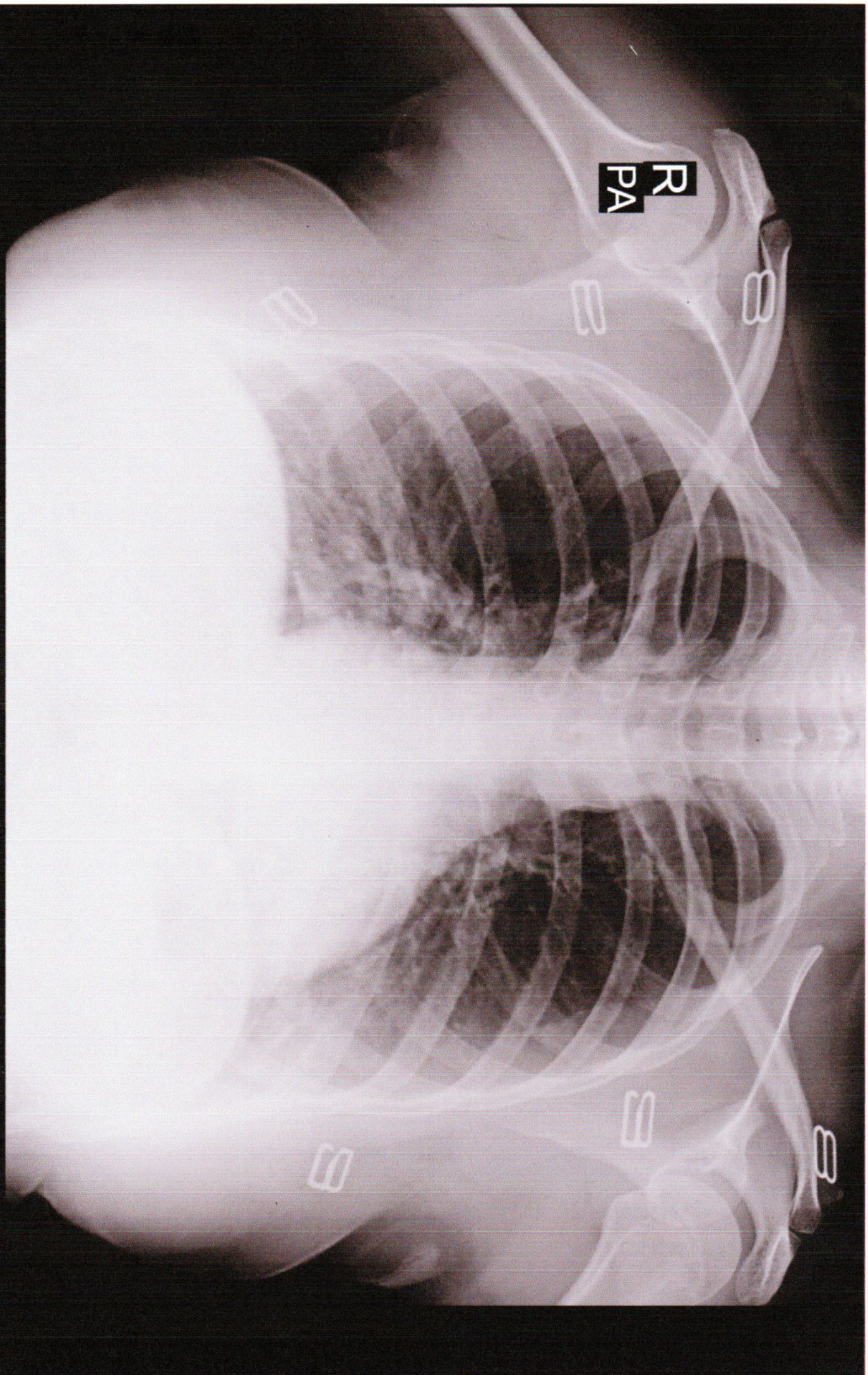
BP :- 100/70
 height :- 157
 Weight (kg) :- 63.3
 BMI :-
 PR :- 71
 SPO₂ :- 97
 RBS :- 101
 PEF R :- 170
 WC :- 98
 NC :- 37

Rx HbA1c = 5.7.

Rx.
 Tab. Thyrox (100) 6:00 AM.
 Gl. Diabemas (10) OD
 Tab. Monkemonax ⁷/₀

R/A 2 month

Printed By : Mr NITIN YADAV
Created By : Mr NITIN YADAV



R
PA

ANUPAM KUMARI 31 YF 3653 O CHEST P.A. 17-Feb-23 10:07 AM
PANACEA HOSPITAL, KABIR NAGAR, DURGAKUND, VARANASI



PANACEA HOSPITAL

A shelter for many hearts A Home for many lives

(An ISO 9001:2008 Certified Organisation)

Lab Attached with CMC Vellore Under EQAS Scheme

NAME: MRS.ANUPMA KUMARI

AGE/SEX: 31 YRS / FEMALE

REF BY: DR. ASHUTOSH MISHRA (MD)

DATE: 17/02/2023

X-RAY CHEST PA

BOTH LUNG FIELDS AND PLEURAE:

Both lungs show normal bronchovascular pattern.

Right & left hila are normal

No focal mass or calcification is seen

There is no evidence of any fluid in the both the pleural cavities.

Both domes of diaphragms are normal in position.

MEDIASTINUM:

Trachea is central in position.

Cardiac silhouette is of normal size and configuration.

No evidence of pericardial effusion.

No significant lymphadenopathy is seen.

Visualized skeleton is normal.

NO SIGNIFICANT RADIOGRAPHIC ABNORMALITY.

REPORTED BY

DR. Rahul Kumar Tiwari

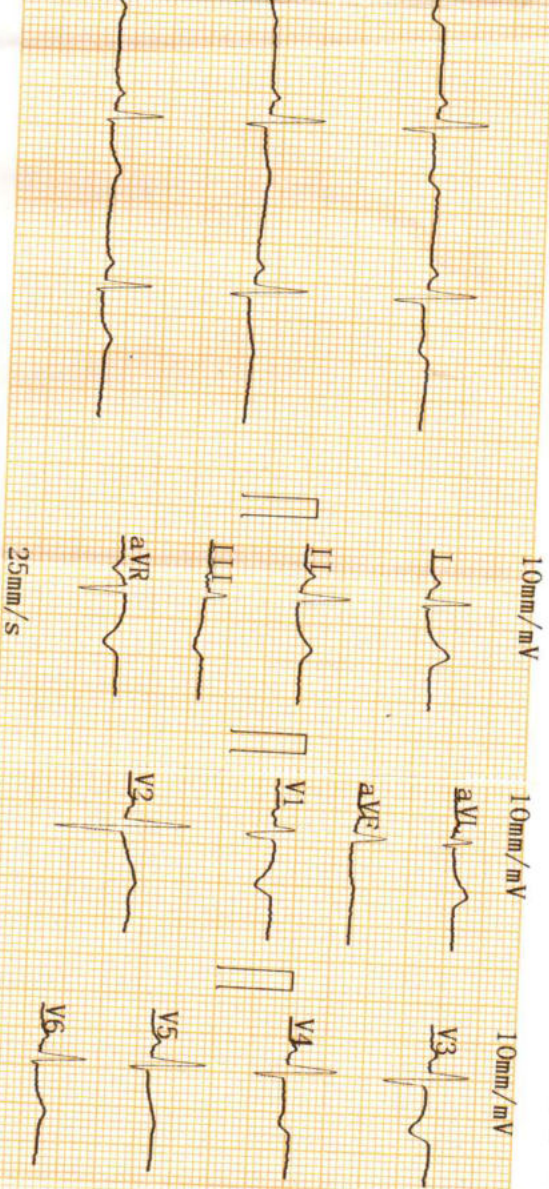
MBBS, MD (Radio Diagnosis)

Reg.No. 57557

Address : Kabir Nagar (Near Sanjay Shiksha Niketan), Durgakund, Varanasi

Mobile : 9554572190 / 9453837595 / Recpn. 9389994334

E-mail : dramishra@gmail.com, drpallaviojha@gmail.com, Website: www.piire.org



2023-02-17 09:22

ID	:	:
Name	:	:
Sex	:	:
Height	:	:
SYS	:	:
DIA	:	:
HR	:	68 bpm
PR Interval	:	142 ms
P Duration	:	111 ms
QRS Duration	:	67 ms
T Duration	:	201 ms
QT/QTc	:	388/413 ms
P/QRS/T Axis	:	38.3/49.8/-3.3 deg
R(V5)/S(V1)	:	0.71/0.36 mV
R(V5)+S(V1)	:	1.07 mV

<< Conclusions >>

Normal Sinus Rhythm,
 Cardiac electric axis normal,
 III aVF V4 V5 Abnormal T wave;

Report need physician confirm

DR. PALLAVI MISHRA
 MBBS, MD (GENERAL MEDICINE)
 MCI Reg. No. 52033

Physician _____

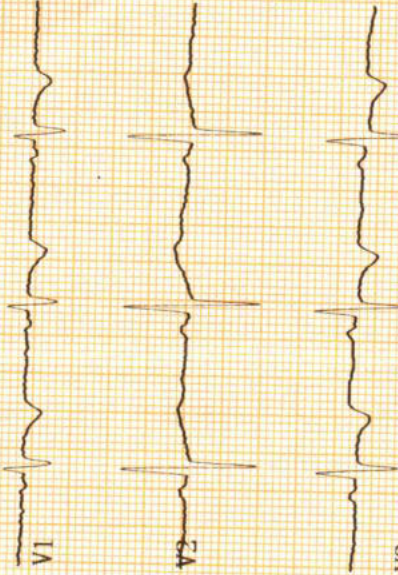
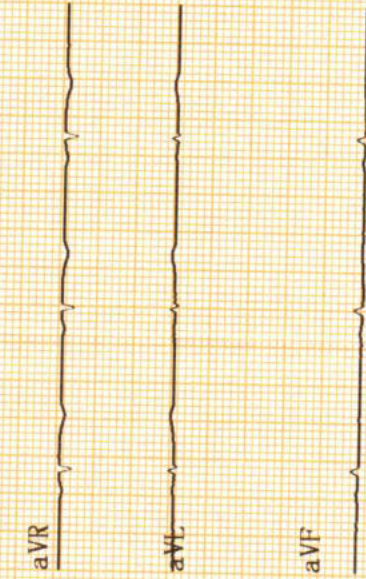
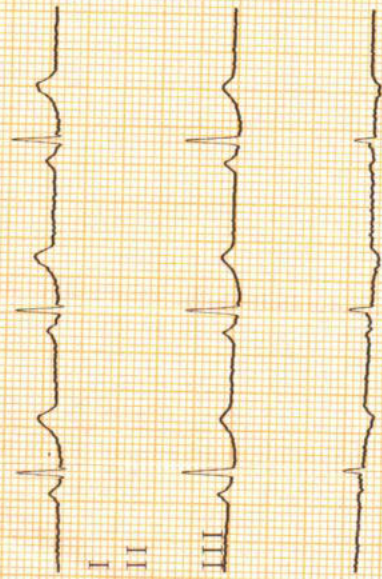
AUTO 10mm/mV

2.5mm/mV

10mm/mV

BPL

10mm/mV



25mm/s AC50Hz+EMG35Hz

CARDIART

02.01.11 11:30 Vm (V) 2 (AV) R

70.11 Vm

11:30:11



PANACEA HOSPITAL

A shelter for many hearts A Home for many lives

(An ISO 9001:2008 Certified Organisation)

Lab Attached with CMC Vellore Under EQAS Scheme

Name	MRS.ANUPMA KUMARI	Sex /Age	31/F	Date	17/02/2023
Ref. by	Dr.Pallavi Mishra(MD)	BSA - m ²		Echo window	fair

Echo - Cardiography


MITRAL VALVE Doppler	AML - normal morphology MV Flow - E - 0.7 A-0.4 E/A=1.66	PML - normal morphology MVA - 3.0 cm ² Mitral Regurgitation - No
TRICUSPID VALVE Doppler	Normal TV Flow -No	Tricuspid Regurgitation - No
PULMONARY VALVE Doppler	Normal PV Flow -No	Pulmonary Regurgitation - No
AORTIC VALVE Doppler	Trileaflet-No AV Flow - no	Aortic Regurgitation - no
MEASUREMENT	Aorta - 22.8 (20-38) mm IVS ed - 11.4 (6 -12) mm LVID ed - 34.3 (35 - 55) mm LVPW ed - 12.6 (6 -12) mm OA - 7 (> 5) mm	LA - 28.0 (24-32) mm IVS es -15.4 (6 - 12) mm LVID es - 23.4 (24 - 40) mm LVPW es - 13.1 (6 -12) mm EPSS - 4 (< 9) mm

CONCLUSION

All cardiac chamber dimensions are WNL
 No valvular abnormalities
 Good LV systolic function present Modified Simpson's method (4C, 2C) (LVEF-61%)
 No diastolic dysfunction present (E/A = 1.66) by tissue Doppler (E/e'=6.2)
 No RWMA
 No pericardial effusion
 Intact IAS / IV
 No PAH
 No intra cardiac mass /thrombus /vegetation

IMPRESSION **Normal Echocardiogram**

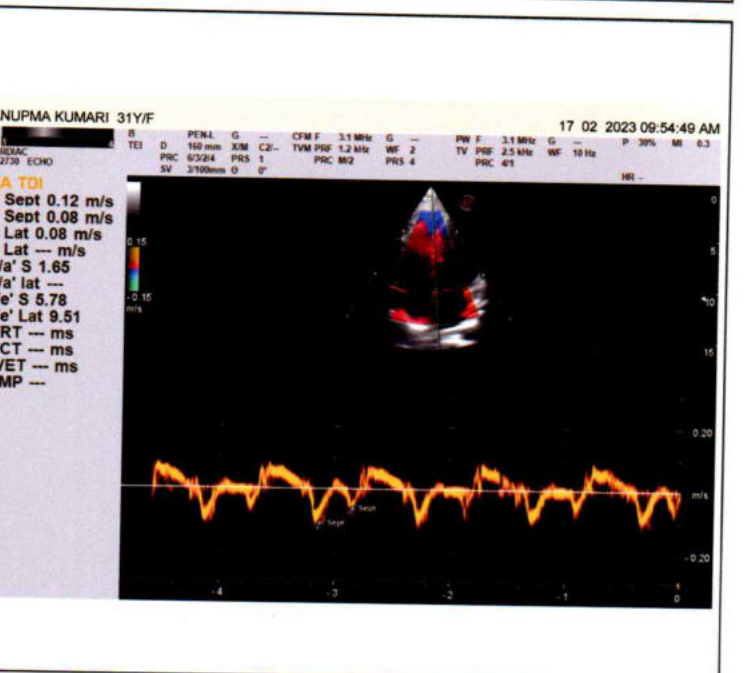
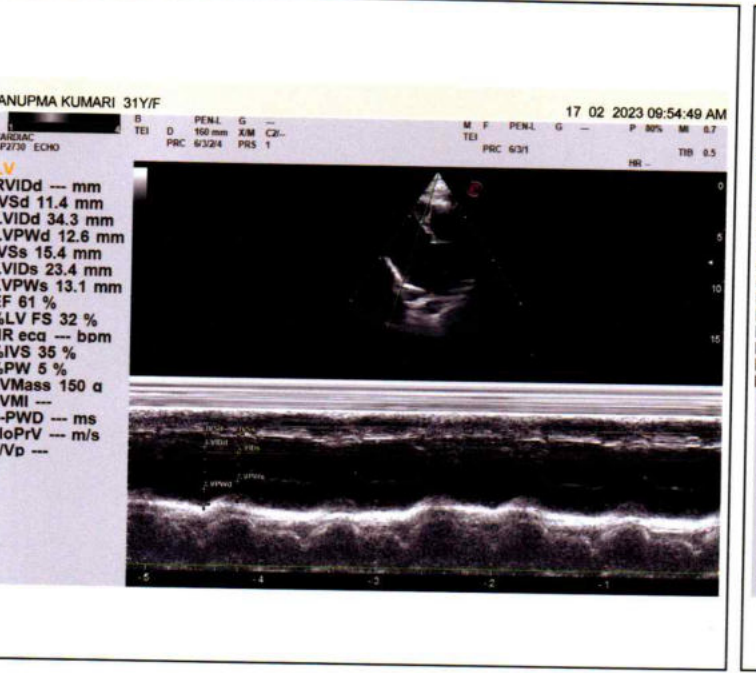
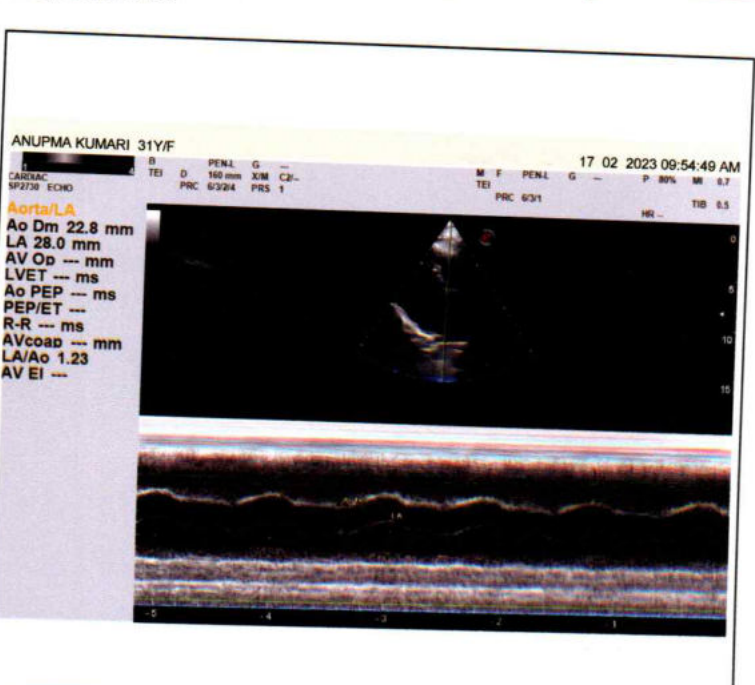
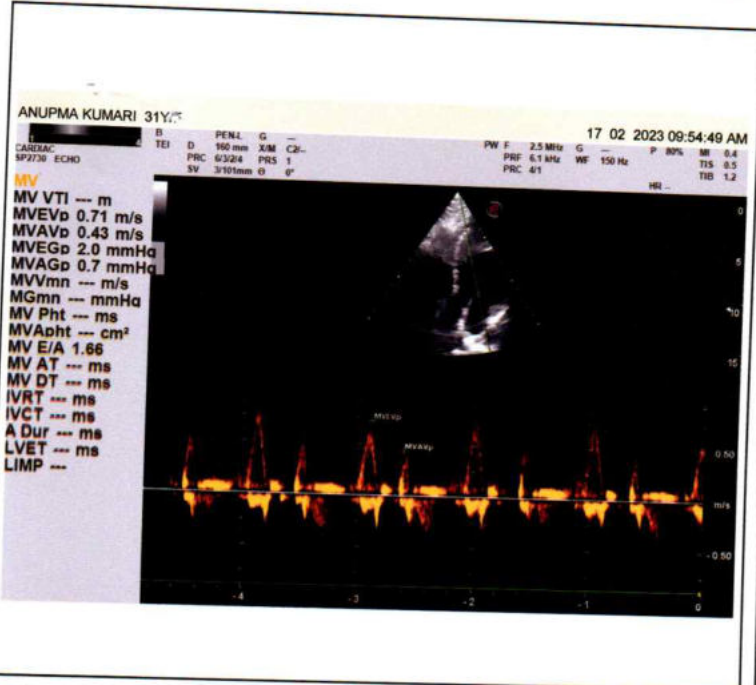

 Niraj Mishra
 Physician Assistant
 (PIIRE)


DR. PALLAVI MISHRA
 MBBS, MD (GENERAL MEDICINE)
 MCI Reg.No. 52033
 Dr. Pallavi Mishra
 MBBS, MD (MED) Lucknow
 Echocardiography Specialist, MIAE
 Non-invasive cardiologist
 Women Cardiologist
 Diabetocardiologist

Address : Kabir Nagar (Near Sanjay Shiksha Niketan), Durgakund, Varanasi

Mobile : 9554572190 / 9453837595 / Recpn. 9389994334

E-mail : dramishra@gmail.com, drpallaviojha@gmail.com, Website: www.piire.org





Call Now - 1800-123-3070

PANACEA HOSPITAL

A shelter for many hearts A Home for many lives

(An ISO 9001:2008 Certified Organisation)

Lab Attached with CMC Vellore Under EQAS Scheme

NAME: MRS.ANUPMA KUMARI

AGE/SEX: 31 YRS / FEMALE

REF BY: DR. ASHUTOSH MISHRA (MD)

DATE: 17/02/2023

ULTRA SOUND WHOLE ABDOMEN REPORT

Liver: Normal in shape and size (9.2 cm) and shows smooth and regular margin.

Gall bladder: Partially distended with normal wall thickness and echo-free lumen.

CBD Visualized part normal in course & caliber.

Pancreas: Normal in size, shape & echogenicity. Margins are smooth & regular. No diffuse/ focal lesion seen.

Spleen: Normal in size shape & echogenicity. Margins are smooth & regular. No diffuse / focal lesion seen. Splenic vessels at hilum is normal.

Kidney: Right kidney: 10.1 X 4.0cm Left kidney: 10.3 X 5.0 cm Normal cortical echogenicity with well maintained Cortical medullary differentiation. Pelvicalyceal system normal. No calculus/mass lesion seen. No hydronephrosis/ hydroureter seen.

Urinary bladder: Minimally distended, wall thickness is normal. **(Needs full bladder review)**

Others: No free fluid in peritoneal cavity. No free fluid in bilateral pleural cavity.

Impression:

- **NO SIGNIFICANT SONOLOGICAL ABNORMALITY DETECTED.**

Please correlate clinically and further investigations.

DR. PALLAVI MISHRA
MBBS, MD (GENERAL MEDICINE)
DR. PALLAVI MISHRA
MCT Reg. No. 52033

MBBS MD(MED) Lucknow
Echocardiography specialist, MIAE
Non invasive cardiologist
Women cardiologist


Radiologist

Dr. Tusharika Rai
MBBS MS


NIBAJ MISHRA
(Physician Assistant)
(PIIRE)

Address : Kabir Nagar (Near Sanjay Shiksha Niketan), Durgakund, Varanasi

Mobile : 9554572190 / 9453837595 / Recpn. 9389994334

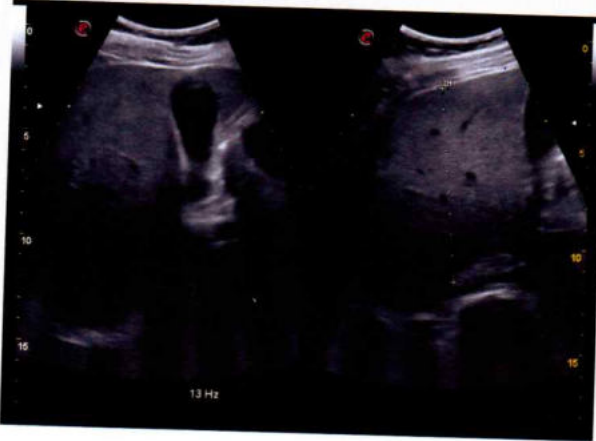E-mail : dramishra@gmail.com, drpallaviojha@gmail.com, Website: www.piire.org

ANUPMA KUMARI 31Y/F

17 02 2023 10:01:19 AM

ABDOMINAL AC2541 KIDNEY
B TEI D GEN.M G
159 mm X/M C1-
PRC 2K2/2/5 PRS 6

D1
92.8 mm

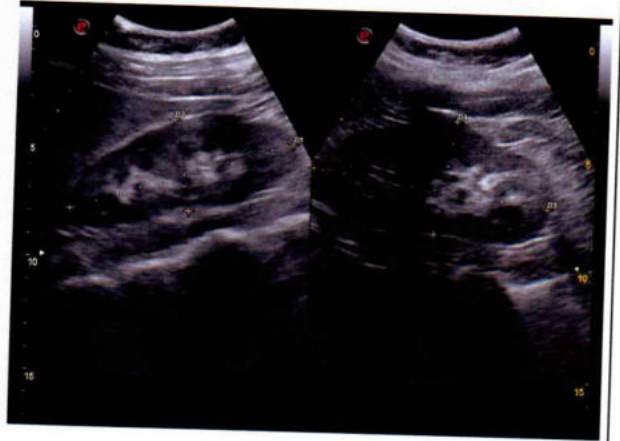

ANUPMA KUMARI 31Y/F

17 02 2023 10:01:19 AM

ABDOMINAL AC2541 NEW
B TEI D GEN.M G
152 mm X/M C1-
PRC 10/9/2/0 PRS 6

D-Ratio
D1
101.8 mm
D2
40.6 mm
D/D
251 %
D-Ratio
D3
103.4 mm
D4
50.7 mm
D/D
204 %

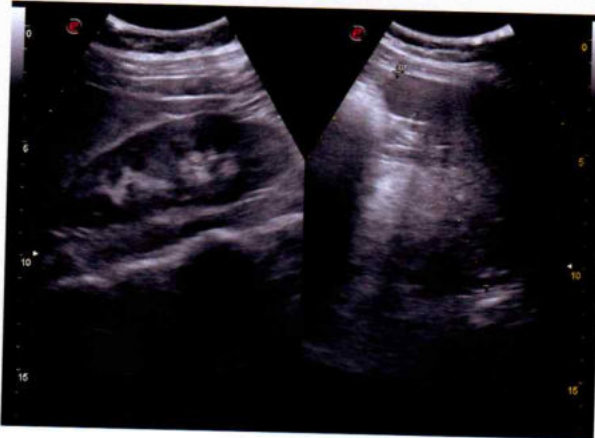

ANUPMA KUMARI 31Y/F

17 02 2023 10:01:19 AM

ABDOMINAL AC2541 NEW
B TEI D GEN.M G
152 mm X/M C1-
PRC 10/9/2/0 PRS 6

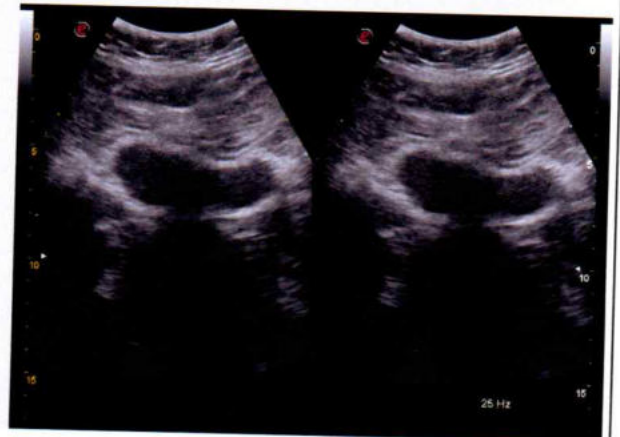D1
101.4 mm



ANUPMA KUMARI 31Y/F

17 02 2023 10:01:19 AM

ABDOMINAL AC2541 NEW
B TEI D GEN.M G
152 mm X/M C1-
PRC 10/9/2/0 PRS 6

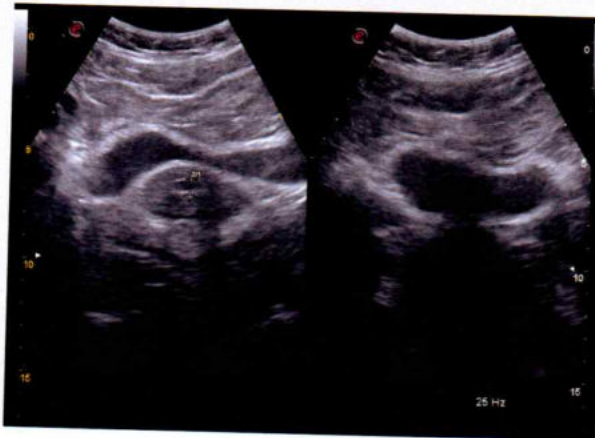

ANUPMA KUMARI 31Y/F

17 02 2023 10:01:19 AM

ABDOMINAL AC2541 NEW
B TEI D GEN.M G
152 mm X/M C1-
PRC 10/9/2/0 PRS 6

D1
7.3 mm



ANUPMA KUMARI 31Y/F

17 02 2023 10:01:19 AM

ABDOMINAL AC2541 NEW
B TEI D GEN.M G
152 mm X/M C1-
PRC 10/9/2/0 PRS 6

