

Pt. Name: MRS.GAYATHRI M	Age/Sex: 50 Y / F
Ref By: H.C	Date: 22 / 07 / 2023

ULTRASOUND ABDOMEN AND PELVIS

- LIVER:** Normal in size measures 11.2 cms, and normal in echotexture. No focal lesion is seen. No IHBR dilatation is seen. Portal vein and CBD are normal.
- GALL BLADDER:** Is well distended with normal wall thickness. No pericholecystic collection is seen. No intraluminal content or calculi are seen.
- PANCREAS:** Normal in size and echotexture. No focal lesion is seen. Peri-pancreatic fat planes are well preserved.
- SPLEEN:** Normal in size measures 9.2 cms and normal in echotexture. No focal lesion is seen. Splenic vein is normal.
- KIDNEYS:** Right Kidney measures 9.3 x 4.1 cms, Left Kidney measures 10.0 x 4.2 cms. Both kidneys are normal in size, shape, position, contour and echotexture. Cortico-medullary differentiation is well maintained. No calculi / hydronephrosis are seen.
- URINARY BLADDER:** Is well-distended with normal wall thickness. No intraluminal content or calculi are seen.
- UTERUS:** Is antverted, Normal in size and echotexture. Normal endomyometrial echoes are seen. No focal lesion is seen.
- OVARIES:** Normal in size and echotexture. No focal lesion is seen.
- Both the adnexa are clear. No lymphadenopathy or ascites are seen.

IMPRESSION: NORMAL STUDY.

Thanks for reference.



Dr. R. K. KALYANI
M.B.B.S., D.N.B.
CONSULTANT RADIOLOGIST

Bp: 148/86 mmHg

NAME: MRS M GAYATHRI

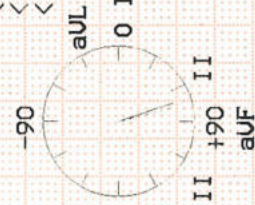
AGE: 50

GENDER: F

Measurement Results:

PRP : 86 ms
 QT/QTcB : 350 / 451 ms
 PR : 110 ms
 P : 84 ms
 RR/PP : 602 / 600 ms
 P/QRS/T : 75/ 70/ 70 degrees
 QT/QTcBD: 70 / 90 ms
 Sokolow : 2.0 mV
 NK : 14


< P
< T
< QRS



Interpretation:

short PR interval
 T-wave near baseline (anterior)
 R/S inversion area between U1 and U2
 probably normal ECG

Unconfirmed report.



TOUCHING LIVES

NAME	MRS. M GAYATHRI		DATE:03/07/2023
AGE	50YRS	KRM NUMBER	125840
GENDER	FEMALE	REFERRED BY	DR.SELF

DIMENSIONS:

AORTA:2.8 cms	IVSD: 1.1 cms	LVDd: 4.3 cms	LVPWD :0.9 cms
LA : 2.6 cms	IVSS : 1.2 cms	LVDs:2.8 cms	LVPWS:1.1 cms
EF : 60%			EDV :62 ML
			ESV :23 ML

VALVES:

MITRAL : NORMAL.
TRICUSPID : NORMAL.
AORTIC : NORMAL.
PULMONARY : NORMAL.

2D – ECHO:

IAS : Intact.
IVS : Intact.
RA : Normal.
RV : Normal.
LA : NORMAL.
LV : NORMAL;
IVC, AORTA AND PULMONARY ARTERY: NORMAL.
PERICARDIUM : NORMAL.

DOPPLER DAT



Mitral valve : E-0.69M/sec A-0.55 m/sec, NO MR.
Tricuspid valve : NO TR
Aortic valve : V max -1.0 m /sec, NO AR.
Pulmonary valve : NO PR.

FINAL IMPRESSION:

NORMAL CHAMBERS AND VALVES

NO LV REGIONAL WALL MOTION ABNORMALITIES AT REST
NORMAL LV & RV SYSTOLIC FUNCTION, EF- 60%
NO PERICARDIAL EFFUSION/CLOT/ VEGETATION.


DR. MOHAN MURALI
Consultant Cardiologist

<ul style="list-style-type: none"> * Restorative Procedures * Root Canal Treatment * Teeth replacement * Oral Surgery * Preventive Dentistry * Orthodontics / Braces * Dental Implants * Pedodontics * Esthetics and Smile design * Periodontics * Veneers * Tooth jewellery 	<p style="text-align: right;">22/7/2022</p> <p>Mrs M Gayathri</p> <p>- 7M7 → NAD</p> <p>- Hard tissue → grossly destructed teeth</p> <p>- Soft tissue → NAD</p> <p>4</p> <p>- Extraction of 50 teeth</p> <p>- Full mouth prosthesis</p> <p>4</p> <p>Divon plus  </p> <p style="margin-left: 100px;">505</p> <div style="text-align: right; font-size: 2em; margin-top: 20px;">A</div>
--	--

Dr. Manaswini Ramachandra, MBBS, MS (ENT)
Consultant ENT and Head & Neck Surgeon
Fellowship in Endoscopic Sinus Surgery
Trained in Allergy (AASC)
Email : manaswiniramachandra@gmail.com



Ms. Sowari
u

22-7-23

① Titration - Eye

RL
u

- PTA

16
u

① U.S. Monitor the level & Tubs.

M/C

22/7/23 Mrs Gayathri Sora
no gynaec complaint
Mm- PANC-segulae IMP-5/1
OBN- P2L2 F1000 UD-2240
Past H - NOS
Family H - NOS
O/E - P/A - 1/1
P/S - Cx 1 @
Vagina 1 @
P/v ut bulky
pap smear taken
rd
also exposed

2