

**Facilities:**  
 All clinical Biomedical & Hematology Investigations  
 including Bone Marrow Examination  
 VPT, Podiascan & Complete Foot Care (First Time in Purvanchal)  
 All Hormonal Investigation by Chemiluminescent Method  
 Visceral Fat by (AB-140) Ambulatory BP Monitoring  
 CGMS & Insulin Pump Available  
 PFT, 2D-ECHO (Color Doppler), Holter, TMT, Cardiac-3 available  
 VIA, VILI, Colposcopy available  
 Special Endocrinological Investigation Protocols.

ISO 9001:2008 Certified  
 Mobile: 9389994334, 9554572190, 9453837595



# Panacea Pathology

## Clinical Reference Lab

Persistence, Preparedness and Precision  
 EQAS (CMC Vellore Attached) & IQAS System  
 पूर्वांचल की सर्वोत्तम गुणवत्ता वाली पैथोलॉजी

PATIENT NAME : AMIT KUMAR GUPTA

AGE/GENDER : 31 YRS/MALE

REFD BY DR. : ARCO FEMI HEALTHCARE LTD.

RECEIVED DATE : 27-05-2023 (10:00AM)

SAMPLE : BLOOD & URINE

REPORT DATE : 27-05-2023 (01:00PM)

### PATHOLOGY REPORT

#### COMPLETE BLOOD COUNT (CBC)

TEST	LAB TEST VALUES	NORMAL RANGE
<b>HEMOGRAM</b>		
HEMOGLOBIN (FLOW CYTOMETRY)	13.7	13 – 16 gm/dl
TOTAL LEUCOCYTE COUNT (TLC)	6,300	4000 – 11000
RBC COUNT	4.88	3.5 – 5.5
PCV (HCT)	43.2	37 – 47
MCV	88.6	80 – 95
MCH	28.0	28 – 34
MCHC	31.6	30 – 36
PLATELET COUNT	1,90,000	1,50,000 – 4,00,000
E.S.R. (WINTROBE FIRST HOURS)	18.0	20 mm/1 <sup>st</sup> hr
<b>DIFFERENTIAL LEUCOCYTE</b>		
NEUTROPHILS	50	40 – 75%
LYMPHOCYTES	46	20 – 45%
EOSINOPHILS	02	1 – 6%
MONOCYTES	02	2 – 8%
BASOPHILS	00	< 2%

#### RANDOM/FASTING BLOOD SUGAR

TEST	LAB TEST VALUES	NORMAL RANGE
<b>RBS/FBS</b>		
FASTING BLOOD SUGAR	76.0	70-140 mg/dl
RANDOM BLOOD SUGAR	123.0	125-140 mg/dl

#### GLYCOSYLATED HEMOGLOBIN (HBA1C)

TEST	LAB TEST VALUES	NORMAL RANGE
HBA1C	6.2	Normal : <5.97 % Good Control : 5.97 – 6.81% Fair Control : 6.81 – 7.65% Poor Control : >7.65%

PAGE 1

Lab Technician

**PANACEA HOSPITAL**  
 (A UNIT OF ARCO HEALTH CARE PVT. LTD.)  
 REG. NO. AL-1500  
 B-36/44, Pathology  
 DURGAKUND, VARANASI

Timing : 8.00 a.m. to 9.00 p.m. (Sunday 8.00 a.m. to 3.00 p.m.)

This Report is not valid for medico legal purpose

**Note:** These tests have technical limitations. Clinico-pathological interpretation is necessary. In case of any disparity test

**Facilities:**  
 All clinical Biomedical & Hematology Investigations  
 including Bone Marrow Examination  
 VPT, Podiascan & Complete Foot Care (First Time in Purvanchal)  
 All Hormonal Investigation by Chemiluminescent Method  
 Visceral Fat by (AB-140) Ambulatory BP Monitoring  
 CGMS & Insulin Pump Available  
 PFT, 2D-ECHO (Color Doppler), Holter, TMT, Cardiac-3 available  
 VIA, VILI, Colposcopy available  
 Special Endocrinological Investigation Protocols.

ISO 9001:2008 Certified  
 Mobile: 9389994334, 9554572190, 9453837595



# Panacea Pathology

## Clinical Reference Lab

Persistence, Preparedness and Precision  
 EQAS (CMC Vellore Attached) & IQAS System  
 पूर्वांचल की सर्वोत्तम गुणवत्ता वाली पैथोलॉजी

PATIENT NAME : AMIT KUMAR GUPTA	AGE/GENDER : 31 YRS/MALE
REFD BY DR. : ARCO FEMI HEALTHCARE LTD.	RECEIVED DATE : 27-05-2023 (10:00AM)
SAMPLE : BLOOD & URINE	REPORT DATE : 27-05-2023 (01:00PM)

### PATHOLOGY REPORT

#### LIPID PROFILE, SERUM

TEST	LAB TEST VALUES	NORMAL RANGE
<b>BLOOD CHEMISTRY</b>		
TOTAL CHOLESTEROL (SERUM)	163.0	Desirable:- < 200 mg/dl Borderline:- 200 – 239 mg/dl High:- > 240 mg/dl
TRIGLYCERIDES (SERUM)	158.0	35 – 170 mg/dl
HDL CHOLESTEROL (SERUM)	42.0	35.30 – 79.50 mg/dl
LDL CHOLESTEROL (SERUM)	89.4	< 130 mg/dl
VLDL	31.6	< 40 mg/dl
CHOLESTROL/HDL RATIO	3.88	< 3.0 Low Risk Ratio 3.0 – 5.0 Avg Risk > 5.0 High Risk
LDL/HDL RATIO	2.12	< 3 Ratio

#### BLOOD GROUP

TEST	LAB TEST VALUES
<b>BLOOD GROUP ABO &amp; RH FACTOR</b>	
BLOOD GROUP	"O"
RH FACTOR	POSITIVE

#### LIVER PROFILE TEST, SERUM

TEST	LAB TEST VALUES	NORMAL RANGE
<b>BIO CHEMISTRY</b>		
TOTAL BILIRUBIN	0.88	0.0 – 1.1 mg/dl
DIRECT BILIRUBIN	0.29	0.0 – 0.2 mg/dl
INDIRECT BILIRUBIN	0.59	< 0.90 mg/dl
SGOT (AST)	24.0	0 – 52 mg/dl
SGPT (ALT)	25.0	0 – 39 mg/dl
GGT (GYT)	15.6	< 55 U/L

#### THYROID PROFILE (T3, T4, TSH)

TEST	LAB TEST VALUES	NORMAL RANGE
<b>THYROID FUNCTION TEST</b>		
T3	1.06	0.60 – 1.81 ng/ml
T4	7.52	4.50 – 10.90 ug/dl
TSH	1.57	0.39 – 6.10 uIU/mL

PAGE 2

Lab Technician

**PANACEA HOSPITAL**  
 (A UNIT OF AARON HEALTH CARE PVT. LTD.)  
 M.D.C. NO. 1500  
 B-36/44, B-4, KABIR NAGAR  
 Durgam Chauraha, Lucknow

Timing : 8.00 a.m. to 9.00 p.m. (Sunday 8.00 a.m. to 3.00 p.m.)

This Report is not valid for legal purpose

**Note:** These tests have technical limitations. Clinico-pathological interpretation is necessary. In case of any disparity test

**Facilities:**  
 All clinical Biomedical & Hematology Investigations  
 including Bone Marrow Examination  
 VPT, Podiascan & Complete Foot Care (First Time in Purvanchal)  
 All Hormonal Investigation by Chemiluminescent Method  
 Visceral Fat by (AB-140) Ambulatory BP Monitoring  
 CGMS & Insulin Pump Available  
 PFT, 2D-ECHO (Color Doppler), Holter, TMT, Cardiac-3 available  
 VIA, VILI, Colposcopy available  
 Special Endocrinological Investigation Protocols.

ISO 9001:2008 Certified  
 Mobile: 9389994334, 9554572190, 9453837595



**Panacea Pathology**  
**Clinical Reference Lab**  
 Persistence, Preparedness and Precision  
 EQAS (CMC Vellore Attached) & IQAS System  
 पूर्वांचल की सर्वोत्तम गुणवत्ता वाली पैथोलॉजी

PATIENT NAME : AMIT KUMAR GUPTA	AGE/GENDER : 31 YRS/MALE
REFD BY DR. : ARCO FEMI HEALTHCARE LTD.	RECEIVED DATE : 27-05-2023 (10:00AM)
SAMPLE : BLOOD & URINE	REPORT DATE : 27-05-2023 (01:00PM)

## PATHOLOGY REPORT

### RENAL & KIDNEY PROFILE, SERUM


TEST	LAB TEST VALUES	NORMAL RANGE
<b>RENAL FUNCTION TESTS</b>		
BLOOD UREA NITROGEN (BUN)	11.6	10 – 50 mg/dl
SERUM CREATININE	0.86	0.60 – 1.60 mg/dl
URIC ACID	3.46	3.60 – 7.70 mg/dl
TOTAL PROTIENS	7.52	0 – 39 mg/dl
ALBUMIN	4.21	3.8 – 5.4 mg/dl
SERUM GLOBULIN	3.31	2.1 – 3.5 mg/dl
AG RATIO	1.27	-

### URINE ROUTINE EXAMINATION

TEST	LAB TEST VALUES	NORMAL RANGE
<b>PHYSICAL EXAMINATION</b>		
QUANTITY	30	ML
COLOUR	STRAW	PALE YELLOW
APPEARANCE	CLEAR	CLEAR
SPECIFIC GRAVITY	1.010	1.01 – 1.03
PH	5.5	4.7 – 7.5
<b>CHEMICAL EXAMINATION</b>		
GLUCOSE	Not Detected	Not Detected
PROTEIN	NIL	Not Detected
<b>MICROSCOPIC EXAMINATION</b>		
PUS CELLS	01-02	0-5
RBC	Not Detected	Not Detected
EPITHELIAL CELLS	01-02	0-5
CASTS	Not Detected	Not Detected
CRYSTALS	Not Detected	Not Detected
BACTERIA	Not Detected	Not Detected

----- End of Report -----

Lab Technician

  
**PANACEA HOSPITAL**  
 (A UNIT OF AAROH HEALTH CARE PVT. LTD)  
 REG. NO. A-1500  
 M.D. Pathology  
 B.36/44, B-4, KABIR NAGAR  
 DURGAKUND, VARANASI

Timing : 8.00 a.m. to 9.00 p.m. (Sunday 8.00 a.m. to 3.00 p.m.)

This Report is not valid for medico legal purpose

**Note:** These tests have technical limitations. Clinico-pathological interpretation is necessary. In case of any disparity test



# PANACEA HOSPITAL

B 36/44 F.K KABIR NAGAR, DURGAKUND  
TOLLFREE NO-18001233070.  
Whatsapp No - 8795832852  
www.piire.org



## OP Slip

Print Date : 27-May-2023 09:42AM



UHID No	:- UD-23240000779	OP No	:- OP-23240002666	OP Date	:- 27 May 2023 9:42AM
Patient Name	:- Mr AMIT KUMAR GUPTA	Age/Sex	:- 31 Y/Male	Mobile No	:- 9155657095
Father	:- GOPAL JI GUPTA	Department	:- DIABETES, ENDOCRINOLOGY & METABOLIC PHYSICIAN		
Pay Type	:- Cash	Consultant	:- Dr ASHUTOSH MISHRA (MD(MEDICINE), IMS, BHU)		
Token No	:- NOR. - 2	Paid/Bal	:- 0.00 / 500.00		
Patient Type	:- Normal				
Address	:- BUXAR, Buxar				

BP :- 110/80  
 height :- 158  
 Weight (kg) :- 71.6  
 BMI :-

Rx

SPO2 98  
 PR 79  
 WC 95  
 NC 38  
 RBS 88  
 PEFr 200

AW  
 c/abdomen  
 30%

Pre-Diabetes  
 COPD

Rx.

Tab. Diabetes (10) ON

Res. Ashu AC (20)

Tab. Doxolin. (AW) ON

R/A. 1 month

Printed By : Ms. RENUKA  
 Created By : Ms. RENUKA

BPL

AUTO 10mm/mV



II



III



aVR



10mm/mV



aVF



V1



V2



10mm/mV



V4



V5



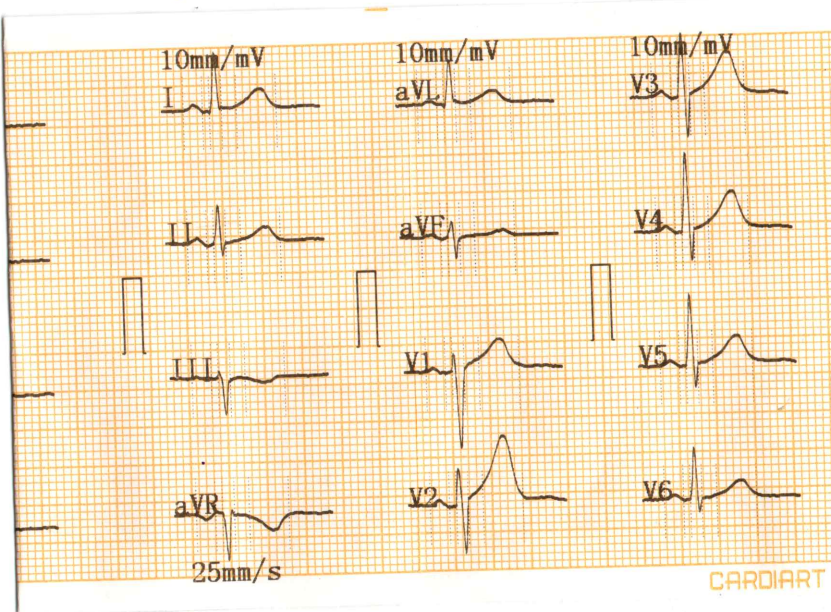
V6



25mm/s AC50Hz+EMG35Hz+DFT

DIART

BPL



2023-05-27 10:18

<< Conclusions >>

ID :  
 Name : *Amit K. Gupta*  
 Sex : *Male* Age : *31 Yrs*  
 Height : \_\_\_\_\_ Weight : \_\_\_\_\_ kg  
 SYS : \_\_\_\_\_  
 DIA : \_\_\_\_\_

Normal Sinus Rhythm;  
 Midding Left axis deviation;

*ECG is within Normal Limit*  
 \*\*Report need physician confirm\*\*

HR [bpm] : 62  
 PR Interval [ms] : 143  
 P Duration [ms] : 104  
 QRS Duration [ms] : 65  
 T Duration [ms] : 214  
 QT/QTc [ms] : 360/365  
 P/QRS/T Axis [deg] : 27.5/-1.2/18.6  
 R(V5)/S(V1) [mV] : 0.94/1.00  
 R(V5)+S(V1) [mV] : 1.95

Physician \_\_\_\_\_

**DR. PALLAVI MISHRA**  
 MBBS, MD (GENERAL MEDICINE)  
 MCI Reg.No. 52033



Call Now - 1800-123-3070

# PANACEA HOSPITAL

*A shelter for many hearts A Home for many lives*

(An ISO 9001:2008 Certified Organisation)

Lab Attached with CMC Vellore Under EQAS Scheme

PATIENT'S NAME : MR.AMIT KUMAR GUPTA

AGE/SEX: 31 Y/M

REF. BY : Dr. ASHUTOSH MISHRA (MD)

Saturday, May 27, 2023

## Echo - Cardiography

MITRAL VALVE Doppler	AML - normal morphology MV Flow - E - 0.6 A-0.5 E/A=1.21	PML - normal morphology MVA - 3.0 cm <sup>2</sup> Mitral Regurgitation - No
TRICUSPID VALVE Doppler	Normal TV Flow -No	Tricuspid Regurgitation -No
PULMONARY VALVE Doppler	Normal PV Flow -No	Pulmonary Regurgitation - No
AORTIC VALVE Doppler	Trileaflet-No AV Flow - no	Aortic Regurgitation - no
MEASUREMENT	Aorta - 32.6 (20-38) mm IVS ed - 10.9 (6-12) mm LVID ed - 37.1 (35-55) mm LVPW ed - 17.1 (6-12) mm OA - 7 (> 5) mm	LA - 28.0 (24-32) mm IVS es -13.7 (6-12) mm LVID es - 26.8 (24-40) mm LVPW es - 17.7 (6-12) mm EPSS - 6 (< 9) mm

## CONCLUSION

All cardiac chamber dimensions are WNL  
No valvular abnormalities  
Good LV systolic function present Modified Simpson's method (4C, 2C) (LVEF-55%)  
No diastolic dysfunction present (E/A = 1.21)  
No RWMA  
No pericardial effusion  
Intact IAS / IV  
No PAH  
No intra cardiac mass /thrombus /vegetation

## IMPRESSION

**Normal Echocardiogram**

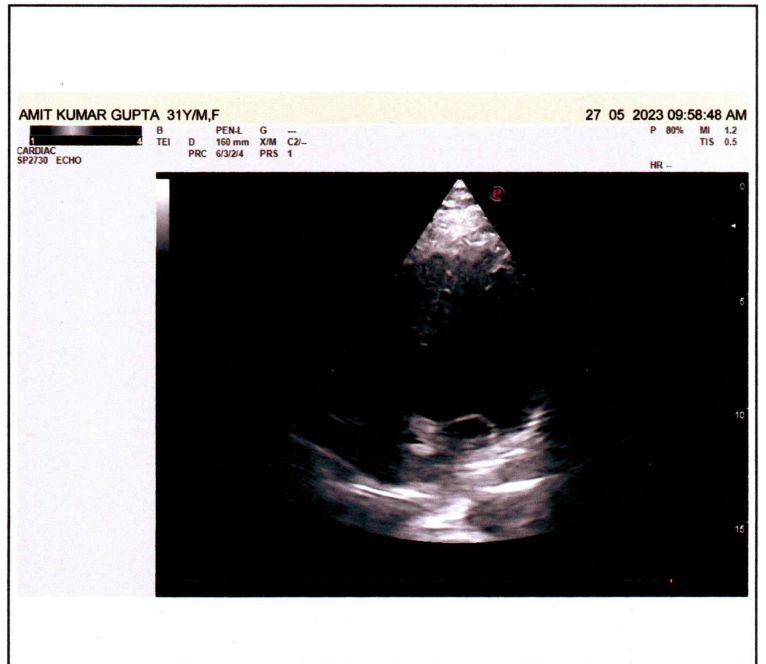
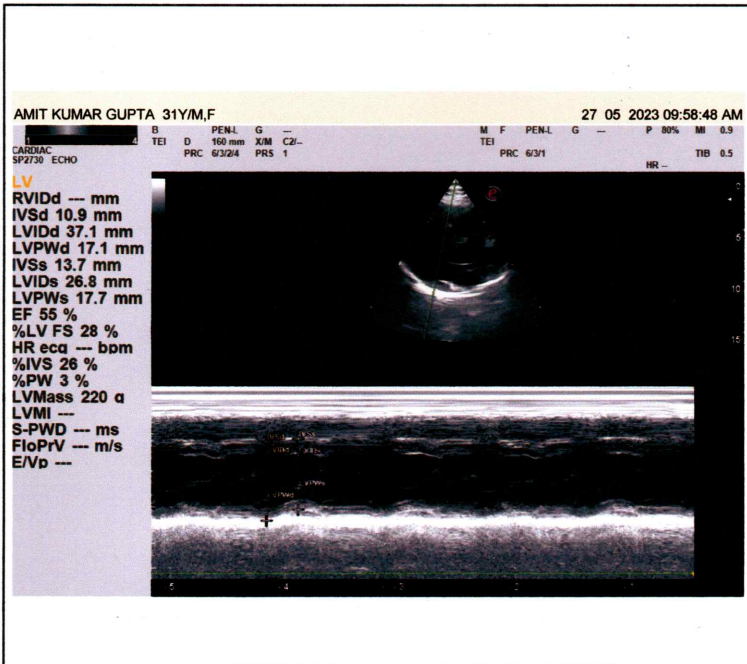
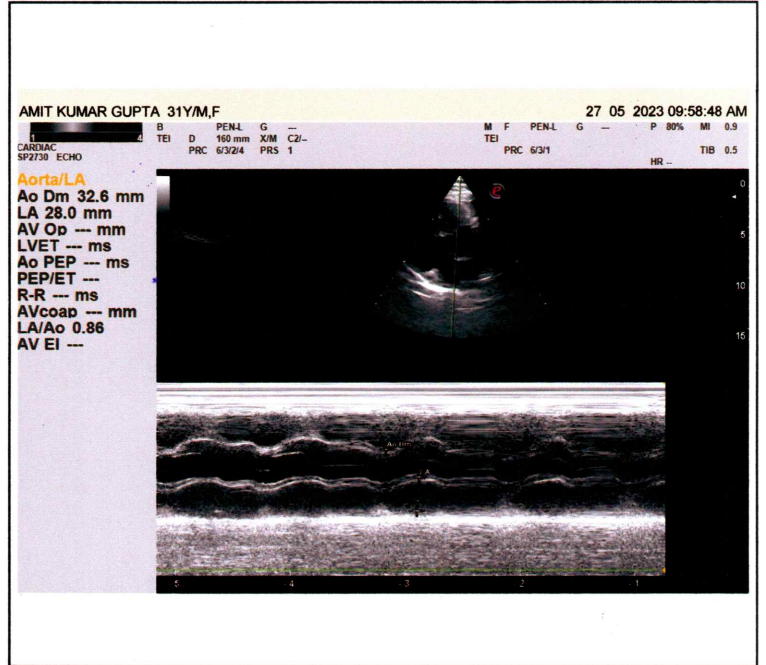
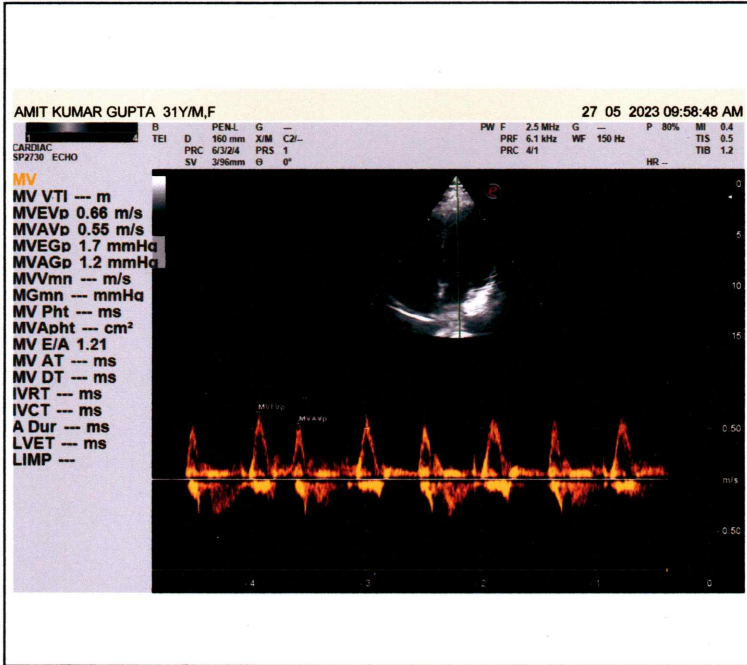
  
Niraj Mishra  
Physician Assistant  
(PIRE)

Dr. Pallavi Mishra  
MBBS, MD (MED) Lucknow  
Echocardiography Specialist, MIAE  
Non-invasive cardiologist  
Women Cardiologist  
Diabetocardiologist

Address : Kabir Nagar (Near Sanjay Shiksha Niketan), Durgakund, Varanasi

Mobile : 9554572190 / 9453837595 / Recpn. 9389994334

E-mail : dramishra@gmail.com, drpallaviojha@gmail.com, Website: www.pire.org






इस कार्ड के खोने / पाने पर कृपया सूचित करें / लौटाएं :

आयकर पैन सेवा इकाई, एन एस डी एल  
तीसरी मंजील, सफायर चेंबर्स,  
बानेर टेलिफोन एक्सचेंज के नजदीक,  
बानेर, पुना - 411 045.

*If this card is lost / someone's lost card is found,  
please inform / return to :*

Income Tax PAN Services Unit, NSDL  
3rd Floor, Sapphire Chambers,  
Near Baner Telephone Exchange,  
Baner, Pune - 411 045.

Tel: 91-20-2721 8080, Fax: 91-20-2721 8081  
e-mail: tininfo@nsdl.co.in

 GPS Map Camera

**Varanasi, Uttar Pradesh, India**

44-B3, Durgakund, Bhelupur, Varanasi, Uttar Pradesh  
221001, India

Lat 25.289209°

Long 82.993307°

27/05/23 09:45 AM GMT +05:30



Google

आयकर विभाग  
INCOME TAX DEPARTMENT



भारत सरकार  
GOVT. OF INDIA

AMIT KUMAR GUPTA

GOPAL GEE GUPTA

10/05/1992

Permanent Account Number

BCYPG5627E

*Amit Kumar Gupta*

Signature



23022012

GPS Map Camera

Varanasi, Uttar Pradesh, India

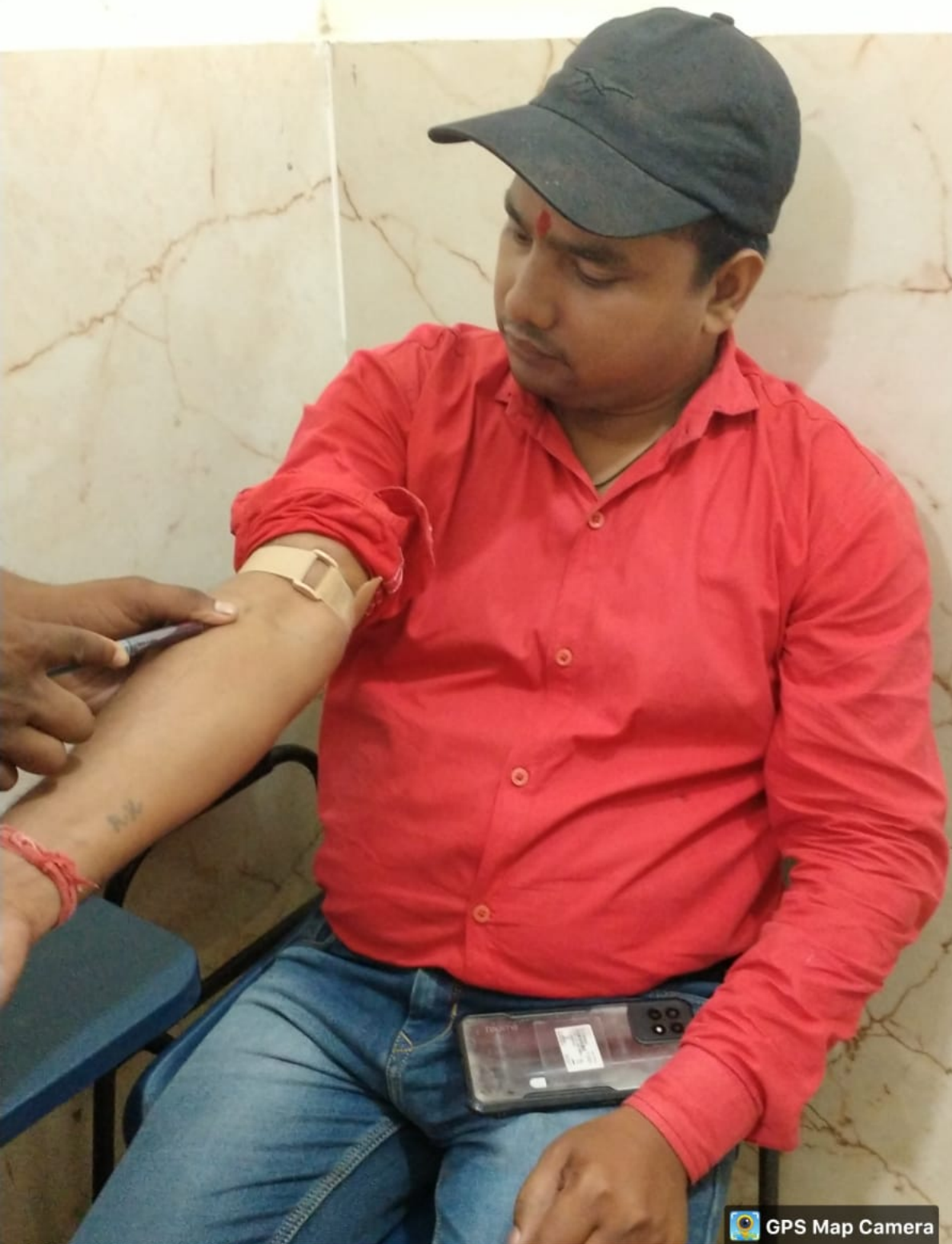44-B3, Durgakund, Bhelupur, Varanasi, Uttar Pradesh  
221001, India


Lat 25.289221°

Long 82.993322°

27/05/23 09:45 AM GMT +05:30





 GPS Map Camera

**Varanasi, Uttar Pradesh, India**

44-B3, Durgakund, Bhelupur, Varanasi, Uttar Pradesh  
221001, India

Lat 25.289223°

Long 82.993309°


27/05/23 09:53 AM GMT +05:30



Google



GPS Map Camera



**Varanasi, Uttar Pradesh, India**  
44-B3, Durgakund, Bhelupur, Varanasi, Uttar Pradesh  
221001, India  
Lat 25.289225°  
Long 82.99332°  
27/05/23 09:46 AM GMT +05:30



Call Now - 1800-123-3070

# PANACEA HOSPITAL

*A shelter for many hearts A Home for many lives*

(An ISO 9001:2008 Certified Organisation)

Lab Attached with CMC Vellore Under EQAS Scheme

PATIENT'S NAME : AMIT KUMAR GUPTA AGE/SEX: 31 Y/M  
REF. BY : Dr. ASHUTOSH MISHRA(MD) Saturday, May 27, 2023

## U/S. WHOLE ABDOMEN

- LIVER** : Liver is normal in size (13.7cm), **Diffuse increased echogenicity of liver parenchyma - Grade I fatty liver.** Intra hepatic biliary radicals are normal. Portal venous channels are normal.
- G. B.** : Gall bladder is normal in size, lumen is clear. Wall thickness normal.
- C.B.D.** : C.B.D. is normal in caliber.
- PANCREAS** : Pancreas is normal in size, shape and echotexture. No evidence of any inflammatory disease or mass.
- SPLEEN** : Spleen is normal in size, shape and echotexture.
- Rt. KIDNEY** : Normal in size, shape and echotexture. Renal sinus is normal  
Cortico medullary differentiation is normal. P. C. system is normal.
- Lt. KIDNEY** : Normal in size, shape and echotexture. Renal sinus is normal  
Cortico medullary differentiation is normal. P. C. system is normal.
- URI. BLADDER** : Urinary bladder is normal in size, position. Wall thickness normal.
- PROSTATE** : Prostate is normal in size.  
No ascites & retro peritoneal lymphadenopathy seen.

**IMPRESSION** :  
❖ **GRADE I FATTY LIVER.**

  
Radiologist

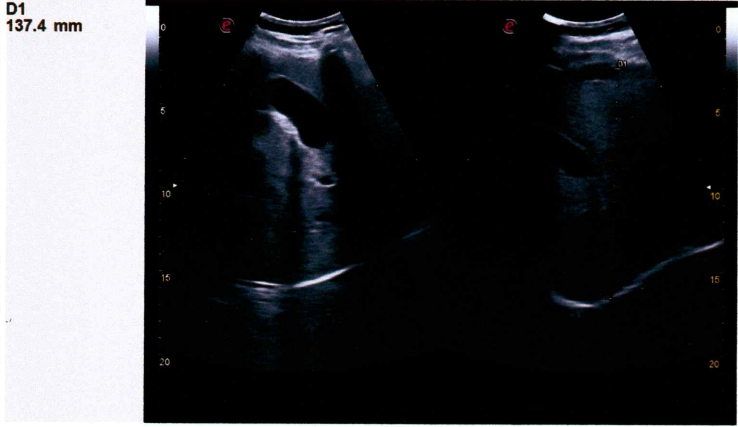*Thanks for reference.*

Address : Kabir Nagar (Near Sanjay Shiksha Niketan), Durgakund, Varanasi

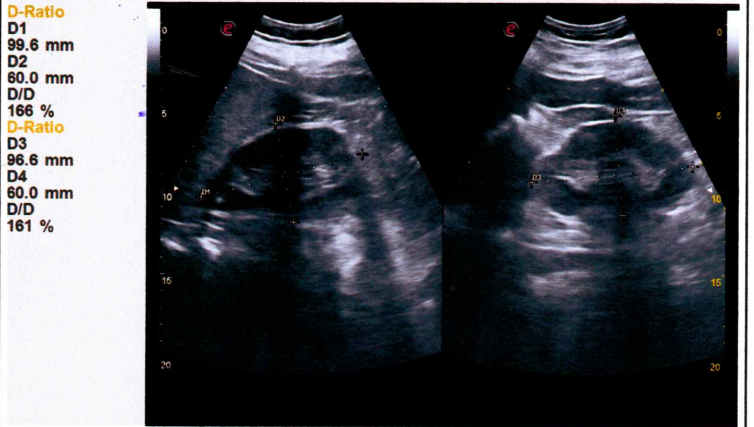
Mobile : 9554572190 / 9453837595 / Recpn. 9389994334

E-mail : dramishra@gmail.com, drpallaviojha@gmail.com, Website: www.piire.org

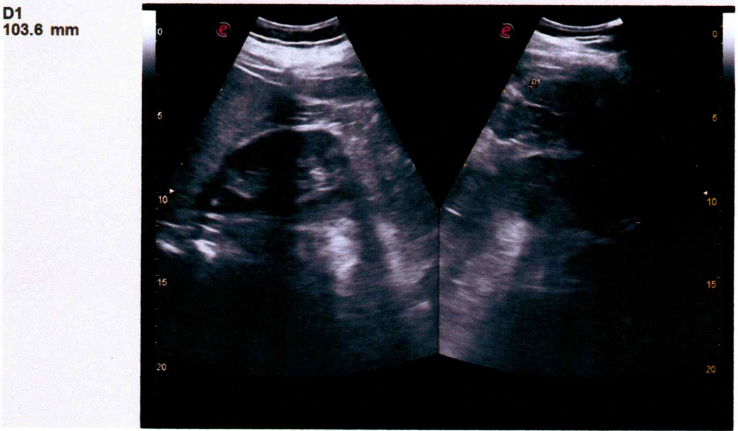
AMIT KUMAR GUPTA 31Y/M,F  
27 05 2023 09:54:37 AM  
P 60% MI 0.8  
GEN-M G --  
D 211 mm XM C2--  
TEI D PRC 19/2/3/5 PRS 4  
ABDOMINAL AC2541 ABD



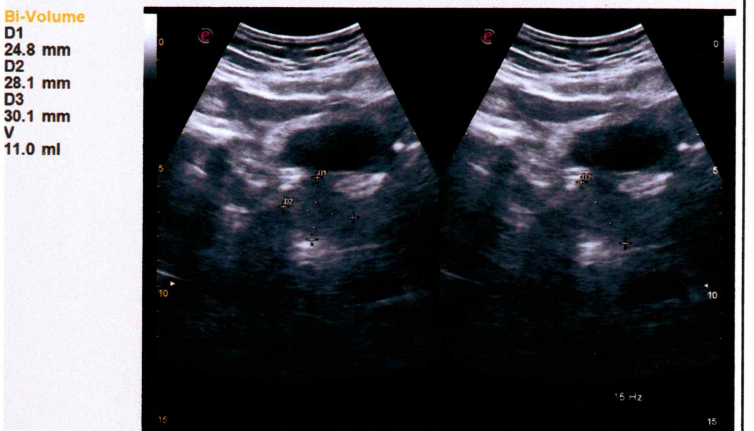
AMIT KUMAR GUPTA 31Y/M,F  
27 05 2023 09:54:37 AM  
P 60% MI 0.8  
GEN-M G --  
D 211 mm XM C2--  
TEI D PRC 19/2/3/5 PRS 4  
ABDOMINAL AC2541 ABD



AMIT KUMAR GUPTA 31Y/M,F  
27 05 2023 09:54:37 AM  
P 60% MI 0.8  
GEN-M G --  
D 211 mm XM C2--  
TEI D PRC 19/2/3/5 PRS 4  
ABDOMINAL AC2541 ABD



AMIT KUMAR GUPTA 31Y/M,F  
27 05 2023 09:54:37 AM  
P 60% MI 0.8  
GEN-M G --  
D 138 mm XM C2--  
TEI D PRC 19/2/3/5 PRS 4  
ABDOMINAL AC2541 ABD





Call Now - 1800-123-3070

# PANACEA HOSPITAL

*A shelter for many hearts A Home for many lives*

(An ISO 9001:2008 Certified Organisation)

Lab Attached with CMC Vellore Under EQAS Scheme

**PATIENT'S NAME : AMIT KUMAR**

**AGE/SEX: 31 Y/M**

**F. BY : Dr. ASHUTOSH MISHRA (MD)**

**Saturday, May 27, 2023**

## X-RAY CHEST (PA VIEW)

### BOTH LUNG FIELDS AND PLEURAE:

Both lungs show normal bronchovascular pattern.

Right & left hila are normal

No focal mass or calcification is seen

There is no evidence of any fluid in the both the pleural cavities.

Both domes of diaphragms are normal in position.

### MEDIASTINUM:

Trachea is central in position.

Cardiac silhouette is of normal size and configuration.

No evidence of pericardial effusion.

No significant lymphadenopathy is seen.

Visualized skeleton is normal.

*Radiologist*

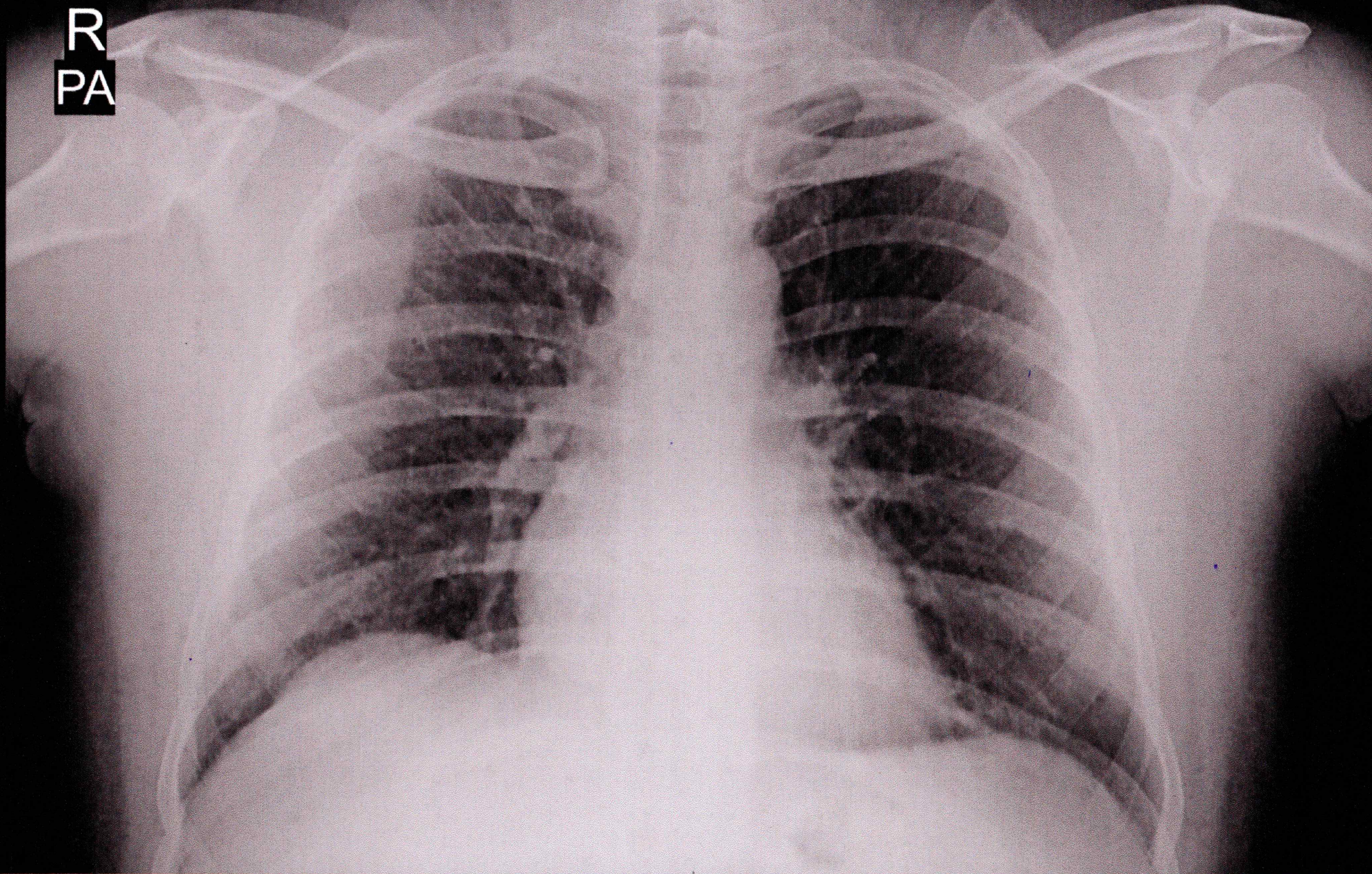
*Thanks for reference.*

**Address : Kabir Nagar (Near Sanjay Shiksha Niketan), Durgakund, Varanasi**

**Mobile : 9554572190 / 9453837595 / Recpn. 9389994334**

**E-mail : dramishra@gmail.com, drpallaviojha@gmail.com, Website: www.piire.org**

R  
PA



AMIT KUMAR GUPTA 31Y/M 0779 O CHEST P.A. 27-May-23 10:14 AM

PANACEA HOSPITAL, KABIR NAGAR, DURGAKUND, VARANASI