

Mr Prashant-Nirmala

29/11/19

Blood + is over
Grade I fatty liver

Daily 30min walking

Decrease Alcohol intake if doing

Repeat urine R/m after 7 days

& follow up

Dr. Milind
Shinde



Dr. MILIND SHINDE
MBBS, DNB Medicine
Reg. No. 2011/05/1544

PUNE LAB ADDRESS: Seraph Centre, Opp. BSNL Exchange, Shahu College Road, Off Pune-Satara Road, Behind Panchami Hotel, Pune - 411009

CENTRAL PROCESSING LAB: 2nd Floor, Aston, Sundervan Complex, Above Mercedes Showroom, Andheri West, Mumbai - 400053

HEALTHLINE - MUMBAI: 022-6170-0000 | OTHER CITIES: 1800-266-4343 | For Feedback - customerservice@suburbandiagnosics.com | www.suburbandiagnosics.com

Brief Disclaimer: (1)Suburban Diagnostics ensures that the tests are conducted with utmost care and safety and are performed on samples received as per the sample collection guide of Suburban Diagnostics.(2)Sample may be rejected if unacceptable for the requested tests.(3)Test results may vary from laboratory to laboratory and also in some parameters from time to time for the same patient.(4)Report must not be copied in part, only in full. (5)This report is not valid for medico-legal purposes.(6)Patient information or data will not be communicated to a third party except in the case of a notifiable disease to a Public Care Unit.(7)Suburban Diagnostics reserves the right to subcontract samples to other laboratories as required.(8)Suburban Diagnostics is not liable for any penalties or liabilities arising out of or relating in any way to these services and/or content or information provided herein.(9) For the elaborated disclaimer, please turn over the page or visit our website.

Age 30 7 27
years months days

Gender Male

Heart Rate 59 bpm

Patient Vitals

BP: NA

Weight: NA

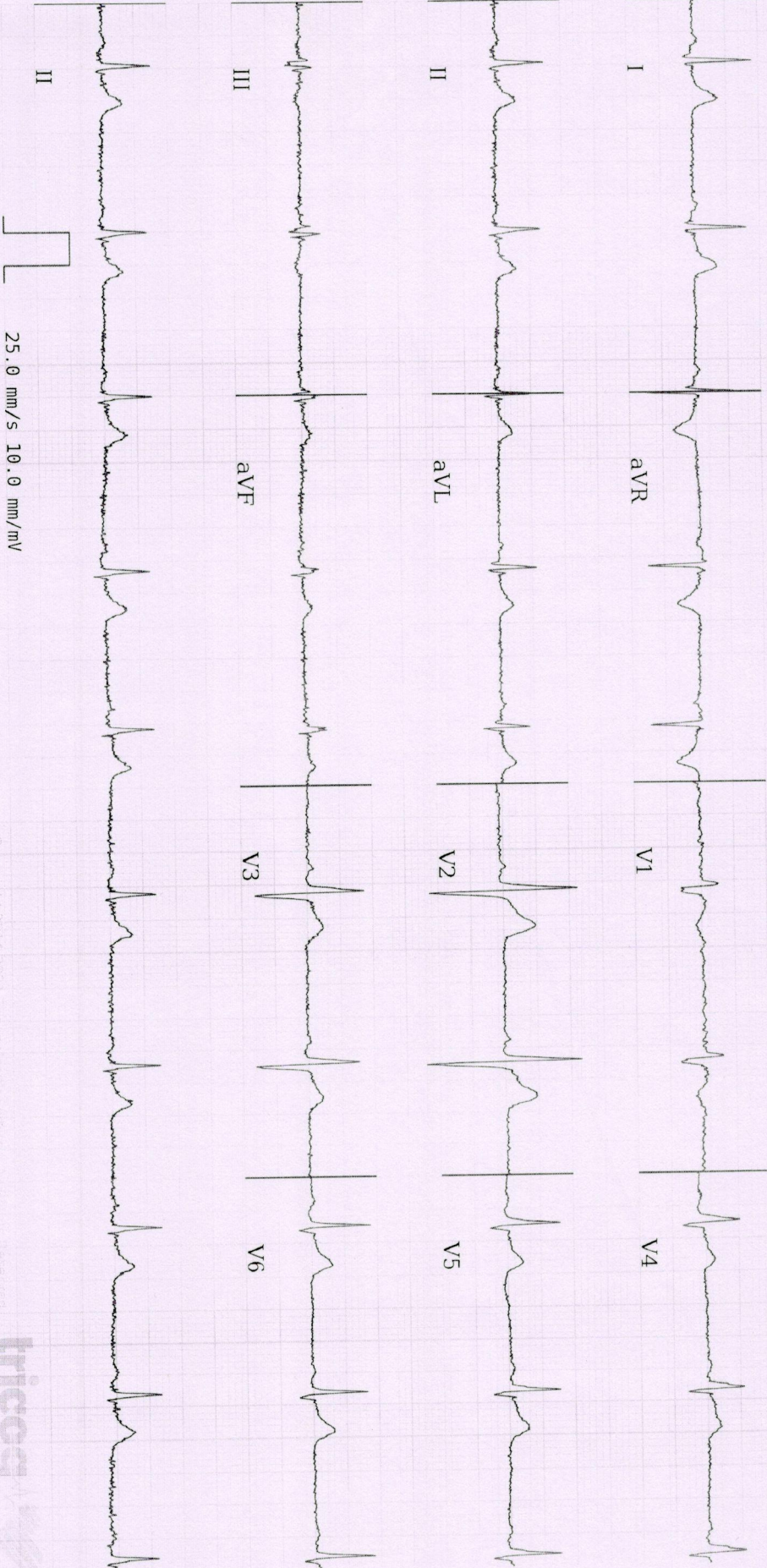
Height: NA

Pulse: NA

Spo2: NA

Resp: NA

Others:



Measurements
 QSRD: 88 ms
 QT: 364 ms
 QTc: 360 ms
 PR: 140 ms
 P-R-T: 3° 31° 22°

ECG Within Normal Limits: Sinus Bradycardia. Please correlate clinically.

REPORTED BY

[Signature]

Dr. Milind Shinde
 MBBS, DNB Medicine
 2011/05/1544

Disclaimer: 1) Analysis in this report is based on ECG alone and should be used as an adjunct to clinical history, symptoms, and results of other invasive and non-invasive tests and must be interpreted by a qualified physician. 2) Patient vitals are as entered by the clinician and not derived from the ECG



CID : 2133132979
Name : Mr PRASHANT NIRMALE
Age / Sex : 30 Years/Male
Ref. Dr :
Reg.Location : Lulla Nagar, Pune Main Centre

Reg. Date : 27-Nov-2021 / 10:10
Report Date : 27-Nov-2021 / 10:11
Printed : 27-Nov-2021 / 10:11

USG (ABDOMEN + PELVIS)

LIVER : The liver is normal in size, shape and smooth margins. It shows raised parenchymal echo pattern s/o grade I fatty infiltration. The intra hepatic biliary and portal radical appear normal. No evidence of any intra hepatic cystic or solid lesion seen. The main portal vein and CBD appears normal.

GALL BLADDER : The gall bladder is physiologically distended. The visualized gall bladder appears normal. No evidence of pericholecystic fluid is seen.

PANCREAS : The pancreas is obscured due to excessive bowel gases.

KIDNEYS : Right kidney measures 8.6 x 3.8 cm. Left kidney measures 8.7 x 4.6 cm. Both the kidneys are normal in size, shape and echotexture. No evidence of any calculus, hydronephrosis or mass lesion seen.

SPLEEN : The spleen is normal in size, shape and echotexture. No evidence of focal lesion is noted.

URINARY BLADDER : The urinary bladder is well distended. It shows thin walls and sharp mucosa. No evidence of calculus is noted. No mass or diverticulum is seen.

PROSTATE : The prostate is normal in size and echotexture.

Gaseous distension of large bowel loops.

There is no evidence of any lymphadenopathy or ascitis.

IMPRESSION :

- Grade I fatty liver.

Advice - Clinical and lab correlation.

-----End of Report-----

R. Rawal
Dr. PALLAVI RAWAL
MBBS, MD Radiology
Reg No 2013/04/1170

CID#	: 2133132979	SID#	: 177801013661
Name	: MR.PRASHANT NIRMALE	Registered	: 27-Nov-2021 / 09:13
Age / Gender	: 30 Years/Male	Collected	: 27-Nov-2021 / 09:13
Ref. Dr	: -	Reported	: 27-Nov-2021 / 11:33
Reg.Location	: Lulla Nagar, Pune (Main Centre)	Printed	: 27-Nov-2021 / 11:34

X-RAY CHEST PA VIEW

The lung fields are clear with no parenchymal lesion.

The cardiothoracic ratio is maintained and the cardiac outline is normal

The domes of the diaphragm are normal.


The cardio and costophrenic angles are clear.

Bony thorax is normal.

IMPRESSION:

No significant abnormality detected.

*** End Of Report ***



Dr.Pallavi Rawal
MD. RADIODIAGNOSIS
RADIOLOGIST

ADDRESS: Seraph Centre, Opp. BSNL Exchange, Shahu College Road, Off Pune-Satara Road, Behind Panchami Hotel, Pune - 411009

CENTRAL PROCESSING LAB: 2nd Floor, Aston, Sundervan Complex, Above Mercedes Showroom, Andheri West, Mumbai - 400053

HEALTHLINE - MUMBAI: 022-6170-0000 | **OTHER CITIES:** 1800-266-4343 | **For Feedback -** customerservice@suburbandiagnosics.com | **www.suburbandiagnosics.com**