

भारत सरकार
Government of India

दीपिकादेवि ललिबहाई गोहिल
Dipikaben Lalibhai Gohil
श्री / त्री / Female

3691 2312 9929

मेरा आधार, मेरी पहचान

Issue Date: 27/03/2014

आधार पहचान का प्रमाण है, नागरिकता का नहीं।
Aadhaar is a proof of identity, not of citizenship.





**Health Check up Booking Confirmed Request(bobS51529),Package Code-PKG10000237,
Beneficiary Code-66382**

1 message

Mediwheel <wellness@mediwheel.in>
To: bhargavgohil13@gmail.com
Cc: customercare@mediwheel.in

Fri, 8 Dec, 2023 at 5:16 pm



Mediwheel
...Your wellness partner



011-41195959

Email:wellness@mediwheel.in

Dear Dipikaben Gohil ,

Please find the confirmation for following request.

Booking Date : 25-11-2023
Package Name : Medi-Wheel Full Body Health Checkup Female Above 40
Name of Diagnostic/Hospital : Savita Superspeciality Hospital
Address of Diagnostic/Hospital : Parivar Char Rasta, Dabhoi - Waghodia Ring Rd, Sarthi Nagar 2, Kendranagar - 390019
Contact Details : 7574078561
City : Vadodara
State : Gujarat
Pincode : 390019
Appointment Date : 09-12-2023
Confirmation Status : Confirmed
Preferred Time : 8:00am-8:30am
Comment : APPOINTMENT TIME 8:30AM

Instructions to undergo Health Check:

1. Please ensure you are on complete fasting for 10-To-12-Hours prior to check.
2. During fasting time do not take any kind of medication, alcohol, cigarettes, tobacco or any other liquids (except Water) in the morning.
3. Bring urine sample in a container if possible (containers are available at the Health Check centre).
4. Please bring all your medical prescriptions and previous health medical records with you.
5. Kindly inform the health check reception in case if you have a history of diabetes and cardiac problems.

For Women:

1. Pregnant Women or those suspecting are advised not to undergo any X-Ray test.
2. It is advisable not to undergo any Health Check during menstrual cycle.

Request you to reach half an hour before the scheduled time.

In case of further assistance, Please reach out to Team Mediwheel.



Savita

Superspeciality Hospital
(A Unit of Solace Healthcare Pvt. Ltd.)

Parivar Char Rasta, Waghodia-Dabhoi Ring Road, Vadodara-390019

0265-2578844 / 2578849 63596 88442

mh@savitahospital.com savitahospital.com

Bill of Supply (Interim-Bill)



Patient ID : 20231206171

Age / Sex : 53y / F

Patient Name : DIPIKABEN . GOHIL

Dr. Name : DR SAURABH JAIN

Referred By : self

City/Village : Vadodara

Class : Contract

PAN Card : AAQCS5566G

Visit No. : OPD20231219773(OPD)

Bill No. : OPD20231219773

Bill Date : N/A

Speciality : Internal Medicine

Company Name : Mediwheel Health Check Up

GSTIN : 24AAQCS5566G2ZW

SAC : 999312 "Medical Service covered under healthcare service"

Mobile No. : 9722697833

Expense Details	Qty	Rate	Gross Amount	Waive	Net Amount
Visit Charge					
09/12/2023 Physician First Consultation OPD	1.0	0.0	0.00	0.0	0.00
Ophthalmologist First Consultation OPD	1.0	0.0	0.00	0.0	0.00
Dentist First Consultation OPD	1.0	0.0	0.00	0.0	0.00
Ob & Gy Surgeon First Consultation OPD	1.0	0.0	0.00	0.0	0.00
Visit Charge (Subtotal)			0.0	0.0	0.00
PATHOLOGY					
09/12/2023 CBC, ESR	1.0			0.0	
Urine R/M	1.0			0.0	
STOOL EXAMINATION ✓	1.0			0.0	
Blood Group	1.0			0.0	
HBA1C	1.0			0.0	
FBS & PPBS	1.0			0.0	
TFT (Thyroid Function Test)	1.0			0.0	
Lipid Profile	1.0			0.0	
RENAL FUNCTION TEST	1.0			0.0	
LFT (Liver Function Test)	1.0			0.0	
MediWheel Full Body Health Check-Up(Female Above 40)	1.0	3000.0	3000.00	0.0	3000.00
PATHOLOGY (Subtotal)			3000.0	0.0	3000.00
Radiology					
09/12/2023 X-RAY CHEST PA ✓	1.0			0.0	
USG WHOLE ABDOMEN SCREENING ✓	1.0			0.0	
Memography	1.0	0.0	0.00	0.0	0.00
X-RAY CHEST PA	1.0	0.0	0.00	0.0	0.00
USG WHOLE ABDOMEN SCREENING	1.0	0.0	0.00	0.0	0.00
Radiology (Subtotal)			0.0	0.0	0.00
Non Invasive Cardiology					
09/12/2023 ECHO COLOUR DOPPLER SCREENING ✓	1.0	0.0	0.00	0.0	0.00
ECG Charge(OPD Base) ✓	1.0	0.0	0.00	0.0	0.00
Non Invasive Cardiology (Subtotal)			0.0	0.0	0.00

Total Bill Amount 3000.00
Net payable amount 3000.00
Bill Outstanding 3000.00

Received With Thanks From DIPIKABEN . GOHIL of Rs 0.0 /-
(Rs Zero Only)

Printed By : (Jahnvi Solanki)
For , Savita Hospital-Live



Female

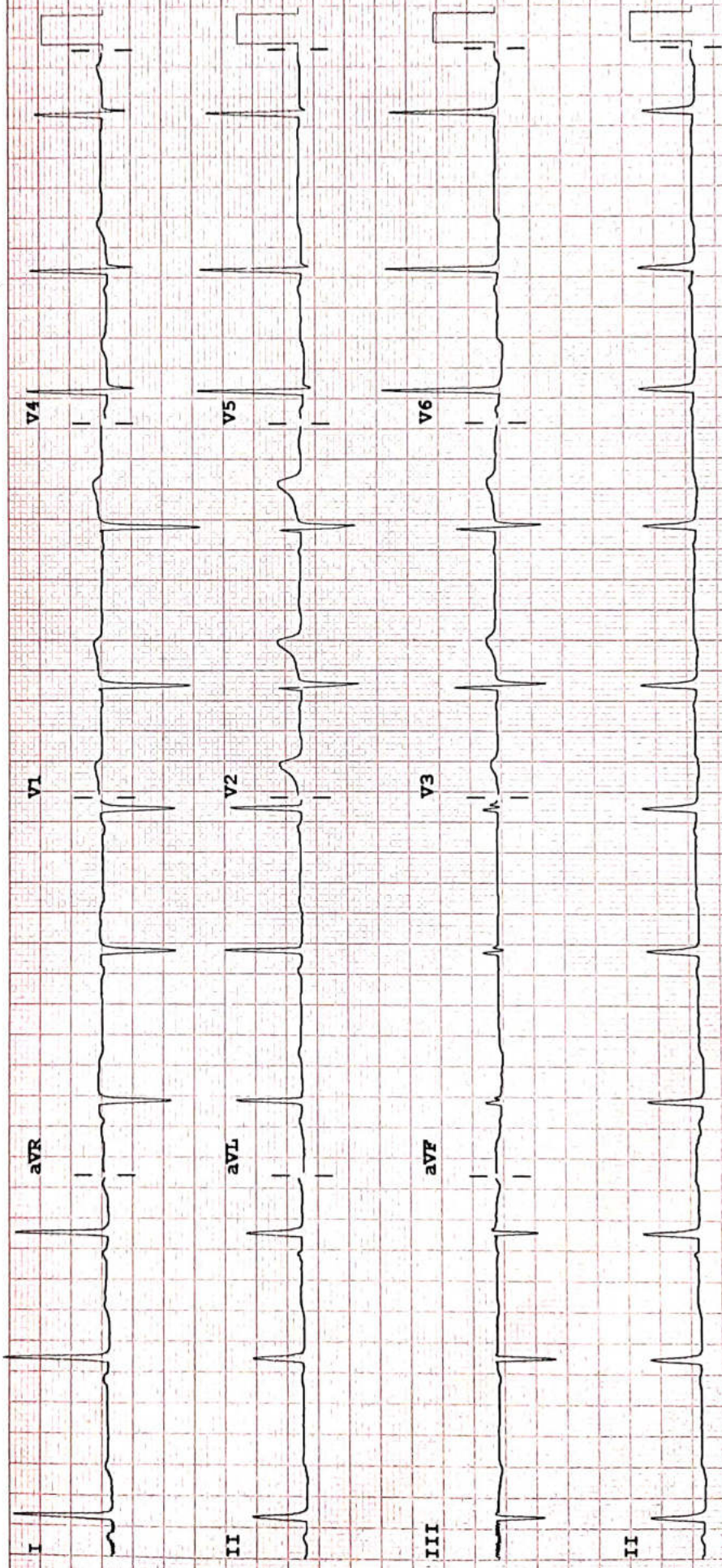
53 Years



Rate 65
 PR 156
 QRSD 76
 QT 408
 QTc 425

--AXIS--
 P -5
 QRS 11
 T 264

12 Lead; Standard Placement



Device:

Speed: 25 mm/sec

Limb: 10 mm/mV

Chest: 10.0 mm/mV

F 50~ 0.50-150 Hz W

PH09

P?



2D-ECHOCARDIOGRAPHY AND COLOR DOPPLER REPORT

NAME: DIPIKABEN GOHIL

DATE: 09/12/2023

AGE/SEX: 53YRS/FEMALE

REF BY: DR. SAURABH JAIN

OBSERVATION:

- NORMAL LV SIZE AND NORMAL LV SYSTOLIC FUNCTION. LVEF = 60% (VISUAL).
- NO RWMA AT REST.
- GRADE II LV DIASTOLIC DYSFUNCTION.
- TRIVIAL MR. NO MS.
- NO AR. NO AS.
- TRIVIAL TR. NO PAH.
- NORMAL SIZED LA, RA & RV WITH NORMAL RV SYSTOLIC FUNCTION.
- NORMAL SIZED MPA, RPA & LPA.
- INTACT IAS & IVS.
- NO E/O INTRACARDIAC CLOT/VEGETATION/PE.
- NORMAL IVC.
- NORMAL PERICARDIUM.

CONCLUSION:

- NORMAL LV/RV SIZE AND SYSTOLIC FUNCTION.
- NO RWMA AT REST.
- LVEF = 60% (VISUAL).



DR. NIRAV BHALANI
[CARDIOLOGIST]

DR. ARVIND SHARMA
[CARDIOLOGIST]



Savita
Superspeciality Hospital
(A Unit of Solace Healthcare Pvt. Ltd.)

Parivar Char Rasta, Waghodia-Dabhol Ring Road, Vadodara-390019
0265-2578844 / 2578849 63596 88442
mh@savitahospital.com savitahospital.com



PATIENT NAME: DIPIKABEN L. GOHIL

AGE/SEX: 53 YRS/F

DATE: Saturday, 09 December 2023

CHEST X-RAY (PA)

Both lung fields appear normal.

Both hila appear normal

Bilateral costo-phrenic angles appear grossly clear

Mediastinum and cardiac shadow appear normal

Bony thorax appears unremarkable

No evidence of free gas under domes of diaphragm

IMPRESSION:

- NO SIGNIFICANT ABNORMALITY NOTED IN PRESENT SCAN



DR SHARAD RUNGTA (MD & DNB)
CONSULTANT RADIOLOGIST

Not all pathologies can be detected on ultrasound in each scan. Further radiographic evaluation is suggested if required.



PATIENT NAME: DIPIKABEN L. GOHIL

AGE/SEX: 53 YRS/F

DATE: Saturday, 09 December 2023

ULTRASOUND OF ABDOMEN & PELVIS

LIVER appears normal in size (11.4 cm) and shows normal parenchymal echogenicity. No evidence of focal lesion. No evidence of dilated IHBR or portal vein. CBD appears normal.

GALL BLADDER is distended. No evidence of abnormal wall thickening or any significant calculus within.

PANCREAS appears normal. MPD is WNL.

SPLEEN appears normal in size (8.0 cm) and shows normal parenchymal echogenicity. No evidence of focal lesion.

BOTH KIDNEYS appear normal in size (RK: 9.0 cm & LK: 9.4 cm), shape and position. Show normal cortical echogenicity. Corticomedullary differentiation is maintained. No evidence of calculus or hydronephrosis on either side.


URINARY BLADDER is partially full. No evidence of abnormal wall thickening or any significant calculus within.

UTERUS appears normal in size and position. CET is WNL. No evidence of focal lesion noted. No evidence of focal or obvious adnexal mass lesion noted.

BOWEL LOOPS appear normal and show normal peristalsis. No evidence of LYMPHADENOPATHY noted. No evidence of ASCITES noted.

IMPRESSION:

- NO SIGNIFICANT ABNORMALITY AT PRESENT SCAN.



DR SHARAD RUNGTA (MD & DNB)
CONSULTANT RADIOLOGIST

Not all pathologies can be detected on ultrasound in each scan. Further radiographic evaluation is suggested if required.



HIRLOKTM DIAGNOSTIC CENTRE

Leading the way!

Digital X-Ray | Sonography | Mammography | Doppler

Dr. Hiral J. Soni
(M.B.B.S., D.M.R.D.)
Consultant Radiologist
Reg No.: G - 15859

MR NO : 9133	DATE : 09.12.23
PATIENT NAME : DIPIKABEN GOHIL	AGE : 53 YRS
REF BY : SAVITA SUPERSPECIALITY HOSPITAL	

BILATERAL MAMMOGRAMS

Dedicated low dose film screen mammography with craniocaudal and mediolateral view was performed.

The mammary parenchyma is inhomogenously dense – because of prominent fibroglandular tissues. **BREAST DENSITY SCALE : B**

Benign calcific foci noted in upper outer quadrant of right breast.

No suspicious lesion is noted in either breast. No evident architectural distortion or skin thickening or nipple retraction noted in both breast as seen on CC and MLO views.

No significant axillary lymphadenopathy on either side.

COMMENTS:

BENIGN CALCIFIC FOCI NOTED IN UPPER OUTER QUADRANT OF RIGHT BREAST.

NORMAL BILATERAL MAMMOGRAM, OTHERWISE

BIRADS [Breast imaging and data system interpretation] CATEGORY : II BENIGN.

To be correlated.

DR HIRAL SONI
CONSULTANT RADIOLOGIST


THANKS FOR REFERENCE

Radiological interpretation is professional and not the final diagnosis. It only helps in diagnosing the disease in correlation of clinical and other related tests. Please see your referring doctor for interpretation of these results.

Not all breast abnormality show up on mammography. The false negative rate of mammography is 10%.

A report that is negative for malignancy should not delay biopsy, if there is clinically suspicious mass. In dense breasts, an underlying mass lesion may be obscured. False positive diagnosis of cancer may occur in small percentage of cases.



Patient Name :	Dipikabon . Gohil	Sample No. :	20231210638
Patient ID :	20231206171		
Age / Sex :	53y/Female	Visit No. :	OPD20231219773
Consultant :	DR SAURABH JAIN	Call. Date :	09/12/2023 08:51
Ward :	-	S. Coll. Date :	09/12/2023 09:42
		Report Date :	09/12/2023 14:31

Urine R/M

Investigation	Result	Normal Value
Quantity - :	20 ml	
Colour - :	Pale Yellow	
Reaction (pH) :	6.0	4.6-8.0
Turbidity :	Clear	
Deposit :	Absent	Absent
Sp.Gravity :	1.030	1.005-1.010
Protein :	Absent	Absent
Glucose :	Absent	Absent
Bile Salts :	Absent	Absent
Bile pigments :	Absent	Absent
Ketones :	Absent	Absent
Urobilinogen :	Absent	
Blood :	Absent	Absent
Pus Cells :	0-1 /hpf	0-5/hpf
Red Blood Cells :	Absent /hpf	Absent
Epithelial Cells :	1-2 /hpf	

Dr. Mehul Desai
M.B.D.C.P
Reg.No.G-9521



Unipath Specialty Laboratory (Baroda) LLP - Platinum Complex, Opp. HDFC Bank, Nr. Radha Krishna char rasta, Akota, Vadodara - 390020
 Unipath Specialty Laboratory (Baroda) LLP - T-5/A35/C32/169, Opp. HDFC Bank, Nr. Radha Krishna char rasta, Akota, Vadodara - 390020
 Mobile: 7228800500 / 8155028222 | Email: info.baroda@unipathllp.in
 Home Visit / OPD Reception : 9998724579



TEST REPORT

Reg. No. : 31201004647 Reg. Date : 09-Dec-2023 12:38 Collected On : 09-Dec-2023 12:38
 Name : Ms. DIPIKABEN GOHIL Approved On : 09-Dec-2023 14:06
 Age : 53 Years Gender : Female Ref. No. : Dispatch At :
 Ref. By : Tele No. :
 Location : SAVITA SUPERSPECIALTY HOSPITAL @ WAGHODIYA ROAD

Test Name	Results	Units	Bio. Ref. Interval
THYROID FUNCTION TEST			
T3 (triiodothyronine) <i>Method:CLIA</i>	1.06	ng/mL	0.6 - 1.81
T4 (Thyroxine) <i>Method:CLIA</i>	6.70	µg/dL	4.5 - 12.6
TSH (ultra sensitive) <i>Method:CLIA</i> Sample Type:Serum	H 4.976	µIU/mL	0.55 - 4.78

Comments:

Thyroid stimulating hormone (TSH) is synthesized and secreted by the anterior pituitary in response to a negative feedback mechanism involving concentrations of FT3 (free T3) and FT4 (free T4). Additionally, the hypothalamic tripeptide, thyrotropin-releasing hormone (TRH), directly stimulates TSH production. TSH stimulates thyroid cell production and hypertrophy, also stimulate the thyroid gland to synthesize and secrete T3 and T4. Quantification of TSH is significant to differentiate primary (thyroid) from secondary (pituitary) and tertiary (hypothalamus) hypothyroidism. In primary hypothyroidism, TSH levels are significantly elevated, while in secondary and tertiary hypothyroidism, TSH levels are low.

TSH levels During Pregnancy :

- First Trimester : 0.1 to 2.5 µIU/mL
- Second Trimester : 0.2 to 3.0 µIU/mL
- Third trimester : 0.3 to 3.0 µIU/mL

Reference : Carl A.Burtis,Edward R.Ashwood,David E.Bruns. Tietz Textbook of Clinical Chemistry and Molecular Diagnostics. 5th Edition. Philadelphia: WB Saunders,2012:2170

End Of Report

This is an electronically authenticated report.

Test done from collected sample.

Printed On: 09-Dec-2023 14:07

We are open 24 x 7 & 365 days

Dr. Vishal Jhaveri
 M.B.B.S, D.C.P
 Reg. G-13041
 LLP Identification Number: AAN-8932
 Page 1 of 1



Patient Name : Dplkaben . Gohil	Sample No. : 20231210638
Patient ID : 20231206171	
Age / Sex : 53y/Female	Visit No. : OPD20231219773
Consultant : DR SAURABH JAIN	Call. Date : 09/12/2023 08:51
Ward : -	S. Coll. Date : 09/12/2023 09:43
	Report Date : 09/12/2023 14:31

LFT (Liver Function Test)

Investigation	Result	Normal Value
Total Bilirubin :	0.5 mg/dl	0.2 to 1.0 mg/dl
Direct Bilirubin :	0.2 mg/dl	0.0 to 0.2 mg/dl
Indirect Bilirubin :	0.3 mg/dl	0.0 to 0.8 mg/dl
AST (SGOT) :	42 U/L [H]	5 to 34 U/L
ALT (SGPT) :	59 U/L [H]	0 to 55 U/L
Total Protein (TP) :	6.7 g/dL	6.4 to 8.3, g/dl
Albumin (ALB) :	3.9 g/dl	3.5 to 5.2 g/dl
Globulin :	2.8 g/dl	2.3 to 3.5 g/dl
A/G Ratio :	1.39	
Alkaline Phosphatase (ALP) :	125 U/L	40 to 150 U/L
GAMMA GT. :	17 U/L	7 to 35 U/L

Dr. Mehul Desai
M.B.D.C.P
Reg.No.G-9521



Patlent Name : Dipikaben . Gohil

Sample No. : 20231210638



Patient ID : 20231206171

Visit No. : OPD20231219773

Age / Sex : 53y/Female

Call. Date : 09/12/2023 08:51

Consultant : DR SAURABH JAIN

S. Coll. Date : 09/12/2023 09:43

Ward : -

Report Date : 09/12/2023 14:31

RENAL FUNCTION TEST

Investigation	Result	Normal Value
Creatinine :	0.8 mg/dl	0.6 - 1.4 mg/dl
Urea :	18 mg/ dl	13 - 45 mg/dl
Uric Acid :	5 mg/dl	3.5 - 7.2 mg/dl
Calcium :	7.9 mg/dl	8.5 - 10.5
Phosphorus :	3.9 mg/dl	1.5 - 6.8

Dr.Mehul Desai
M.B.D.C.P
Reg.No.G-9521



Patient Name : Dipikaben . Gohil

Sample No. : 20231210638



Patient ID : 20231206171

Visit No. : OPD20231219773

Age / Sex : 53y/Female

Call. Date : 09/12/2023 08:51

Consultant : DR SAURABH JAIN

S. Coll. Date : 09/12/2023 09:43

Ward : -

Report Date : 09/12/2023 14:31

Lipid Profile

Investigation	Result	Normal Value
Sample :	Fasting	
Sample Type :	Normal	
Cholesterol (Chol) :	121 mg/dl	Low risk : < 200 Moderate risk : 200 - 239 High risk : > or = 240
Triglyceride :	60 mg/dl	Normal : < 200.0 High : 200 - 499 Very High : > or = 500
HDL Cholesterol :	63 mg/dl	Low risk : >or = 60 mg/dL High risk : Up to 35 mg/dL
LDL :	46 mg/dl [L]	131.0 to 159.0(N) < 130.0(L) > 159.0(H)
VLDL :	12 mg/dl	Up to 0 to 34 mg/dl
LDL/HDL Ratio :	0.73	Low risk : 0.5 to 3.0 Moderate risk : 3.0 to 6.0 Elevted level high > 6.0
Total Chol / HDL Ratio :	1.92	Low Risk : 3.3 to 4.4 Average Risk : 4.4 to 7.1 Moderate Risk : 7.1 to 11.0 High Risk : > 11.0
Total Lipids :	544 mg/dl	400 to 700 mg/dl

Note :- Lipemic samples give high triglyceride value and falsely low LDL value.

Dr.Mehul Desai
M.B.D.C.P
Reg.No.G-9521



Patient Name : Dipikaben . Gohil	Sample No. : 20231210638
Patient ID : 20231206171	
Age / Sex : 53y/Female	Visit No. : OPD20231219773
Consultant : DR SAURABH JAIN	Call. Date : 09/12/2023 08:51
Ward : -	S. Coll. Date : 09/12/2023 09:42
	Report Date : 09/12/2023 14:31

Blood Group

Investigation	Result	Normal Value
BLOOD GROUP :		
ABO	A	
Rh	Positive	

HBA1C


Investigation	Result	Normal Value
Glycosylated Hb :	5 %	Near Normal Glycemia : 6 to 7 Excellent Control : 7 to 8 Good Control : 8 to 9 Fair Control : 9 to 10 Poor Control : > 10
Average Plasma Glucose of Last 3 Months :	96.8	

FBS & PPBS

Investigation	Result	Normal Value
Blood Sugar (FBS) :	104 mg/dl	74 - 100 mg/dl
Urine Sugar (FUS) :	Nil	
Blood Sugar (PP2BS) :	91 mg/dl	70 to 120 mg/dl
Urine Sugar (PP2US) :	Nil	

Dr.Mehul Desai
M.B.D.C.P
Reg.No.G-9521



Patient Name :	Dipikaben . Gohil	Sample No. :	20231210638 
Patient ID :	20231206171	Visit No. :	OPD20231219773
Age / Sex :	53y/Female	Call. Date :	09/12/2023 08:51
Consultant :	DR SAURABH JAIN	S. Coll. Date :	09/12/2023 09:42
Ward :	-	Report Date :	09/12/2023 14:31

CBC, ESR

Investigation	Result	Normal Value
Hemoglobin :	13.6 gm/dl	12.5 to 16.0 gm/dl
P.C.V. :	41.9 %	37.0 to 47.0 %
M.C.V. :	83.1 fL	78 to 100 fL
M.C.H. :	27 pg	27 to 31 pg
M.C.H.C. :	32.5 g/dl	32 to 36 g/dl
RDW :	11.5 %	11.5 to 14.0 %
RBC Count :	5.04 X 10 ⁶ / cumm	4.2 to 5.4 X 10 ⁶ / cumm
Polymorphs :	58 %	38 to 70 %
Lymphocytes :	38 %	15 to 48 %
Eosinophils :	2 %	0 to 6 %
Monocytes :	2 % [L]	3 to 11 %
Basophils :	0 %	0.0 to 1.0 %
Total :	100	< 100 > 100
WBC Count :	7100 /cmm	4000 to 10000 /cmm
Platelets Count :	225000 /cmm	1,50,000 to 4,50,000 /cmm
ESR - After One Hour :	19 mm/hr	1 to 20 mm/hr



Dr. Mehul Desai
M.B.D.C.P
Reg.No.G-9521



Examination by GYNAECOLOGIST


Name:	DIPIKABEN GOHIL	Age:	53/FEMALE
Reg.No:	20231206171	DOE:	9/12/2023

Presenting Complaint:	NO FRESH COMPLAINTS
-----------------------	---------------------

Medical History :	
M/H:	POST MENOPAUSAL 10YRS
O/H:	P2L2 PR 2FTND
OTHER:	

EXAMINATION:	
P/A:	SOFT NOGTR
P/S:	CX VG (H)
P/V:	UTAVNS

IMPRESSION:	NAD
ADVICE:	LIGNOCAINE JELLY


DR KRUPALI PATEL



PHYSICIAN EXAMINATION

Name :	DIPIKABEN GOHIL	Age :	53/FEMALE
Reg.No :	20231206171	DOE :	9/12/2023

Physical Examination:

Height:	159CM	Weight:	67KG	PULSE:	69	Temperature:	NORMAL
BMI :	26.5	BP :	26.5	SPO2	98%		
Chief Complaint :	NO COMPLAINTS						
Past History :	K/C/O DM/HTN & T.MET XL (25) 1-0-1 T.TELMIKIND -AM (40/5) 1-0-0						
General Examination :	NAD						
Systemic Examination :	NAD						
INVESTIGATION :							
ADVICE :	T.TELMIKIND -AM (40/5) 1-0-0 CONT. T.MET XL (25) 1-0-1 } 2MONTH SRD/BP MONITORING						



DR.SAURABH JAIN



EXAMINATION BY DENTAL

Name :	DIPIKABEN GOHIL	Age/Sex:	53/FEMALE
Reg No :	20231206171	DOE:	9/12/2023

Presenting Complaint :	ROUTINE CHECKUP
------------------------	-----------------

Medical History :	NAD
-------------------	-----

Examination :	GENERALIZED ATTRITION
---------------	--------------------------

Impression :	-
--------------	---

Advice :	NIGHT GUARD
----------	-------------



DR RUSDA MALEK



Examination Ophthalmologist

Name :	<u>DIPIKABEN GOHIL</u>	Age :	<u>53/FEMALE</u>
Reg.No :	<u>20231206171</u>	DOE :	<u>9/12/2023</u>

Present Complaints :	-
Medical History :	-
Examination Of Eye :	-

External Examination :		
Ati Seg Examination :	AS	WNL
Schiotz Tonometry IOP :	P	RRRL
Fundus :		

Without Glass	Distant Vision :	
	Near Vision :	
With Glass	Distant Vision :	6/6C-2.0DSPH
	6/6C+2.0DSPH	
	Near Vision : N6C	N6C+3.50DSPH
	+3.50DSPH	BIFOCAL
Colour Vision (With Ishihara Chart) :		WNL
Impression:		
Advice :		


DR PANKTI SHAH



Patient Name :	Dipikaben . Gohil	Sample No. :	20231210697
Patient ID :	20231206171	Visit No. :	OPD20231219773
Age / Sex :	53y/Female	Call. Date :	09/12/2023 08:51
Consultant :	DR SAURABH JAIN	S. Coll. Date :	11/12/2023 11:42
Ward :	-	Report Date :	11/12/2023 11:46

STOOL EXAMINATION

Investigation	Result	Normal Value
Quantity :	5 gm	
Colour :	Brown	
Consistency :	Semi Solid	
Mucus :	Absent	
Blood :	Absent	
Pus :	Absent	
Occult Blood :	Negative	
Pus Cells :	Absent /hpf	
RBCs Cells :	Absent /hpf	
Epithelial Cells :	1-2 /hpf	
Fat Droplets :	Present (+)	
Reducing Sab. :	Positive	

Dr. Mehul Desai
M.B.D.C.P
Reg.No.G-9521