



भारतीय विशिष्ट ओळख प्राधिकरण

भारत सरकार

Unique Identification Authority of India

Government of India

नोंदविण्याचा क्रमांक / Enrollment No 1190/10128/01561

To,
गजेंद्र ब्रम्हदेव तुपसमुद्रे
Gajendra Bramhadeo Tupsamudre
S/O Bramhadeo Tupsamudre
B-10-15/03
near rajeev gandhi stadium sector-4 cbd belapur pin
code-400614
Navi Mumbai
Thane
Maharashtra 400615
9702202937

Ref: 74 / 13E / 145674 / 147630 / P



UE456848014IN



आपला आधार क्रमांक / Your Aadhaar No. :

7013 0395 4774

आधार — सामान्य माणसाचा अधिकार



भारत सरकार
GOVERNMENT OF INDIA





गजेंद्र ब्रम्हदेव तुपसमुद्रे
Gajendra Bramhadeo Tupsamudre
जन्म वर्ष / Year of Birth : 1985
पुरुष / Male



7013 0395 4774

आधार — सामान्य माणसाचा अधिकार


Dr. Mahesh V. Padsalge
MD. (Medicine)
Consultant Physician
Reg. No. 91424 (MMC)


Gajendra

Male

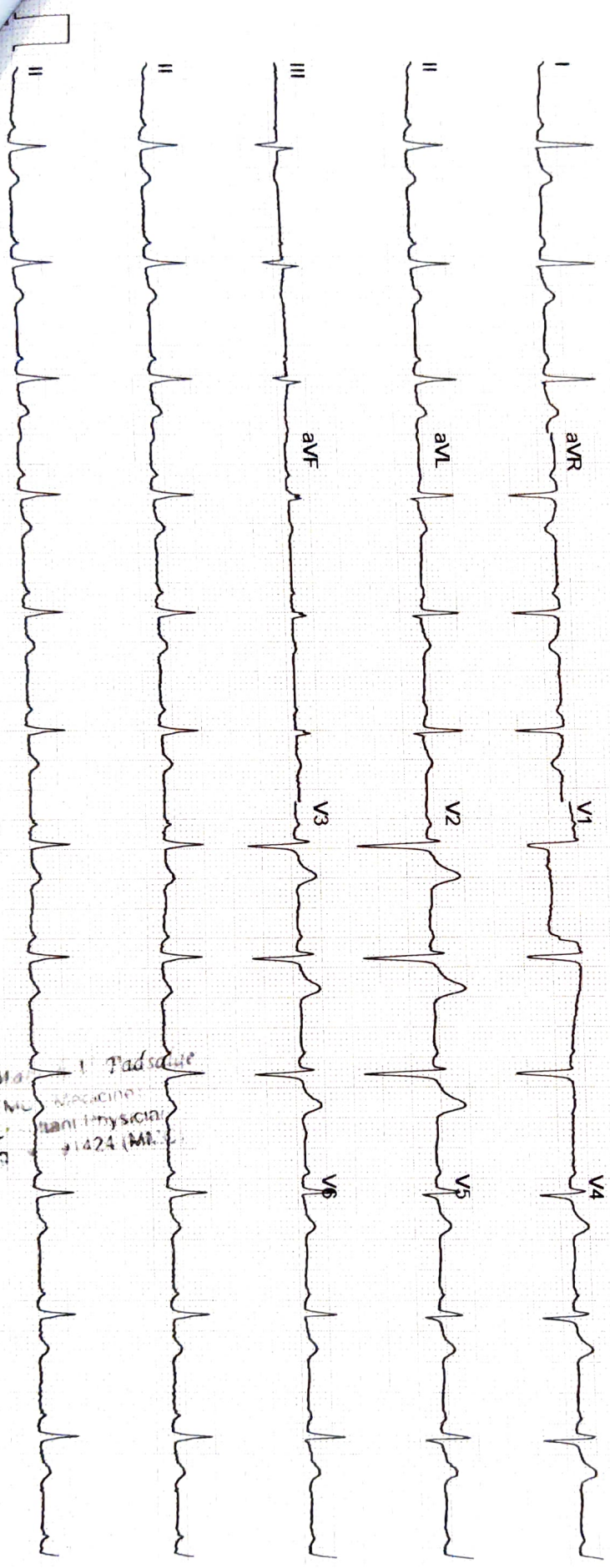
QRS : 80 ms
QT / QTcBaz : 350 / 393 ms
PR : 142 ms
P : 86 ms
RR / PP : 788 / 789 ms
P / QRS / T : 27 / 24 / 19 degrees

Normal sinus rhythm
Normal ECG

Handwritten: Normal ECG

Handwritten signature: Dr. M. V. Padsalge

Dr. M. V. Padsalge
MD. (Medicine)
Consultant Physician
Reg. No. 91424 (M.M.C)



Handwritten: Dr. M. V. Padsalge
MD. (Medicine)
Consultant Physician
Reg. No. 91424 (M.M.C)

06/6/22

Mr Gayendra Tupdamudre
37/M

Six check up

	(A)	(C)
VA	6/6	6/6
	N6	N6
Colour vision	NM	NM
Goldmann Chart	Normal	Normal
RF/seg	NM	NM

ly

ECHO Report

Date: 06/06/2022


Patient Details

Patient ID – 19793
Name- MR GAJENDRA TUPSAMUDRE
Age- 37 YEARS
Gender- MALE
Referral By - MEDIWHEEL

Doctor Incharge DR. MAHESH PADSALGE

Clinical Status of Patient -

- Finding description -
1. Normal cardiac chambers dimensions.
 2. Normal LV systolic function.
 3. No RWMA.
 4. All cardiac valves are structurally normal.
 5. Trivial MR, Trivial PR, NO AR.
 6. No PAH.
 7. Normal RV systolic function.
 8. No clot/vegetation/pericardial effusion.
 9. No coarctation of aorta.



Chamber Dimensions-M mode Findings

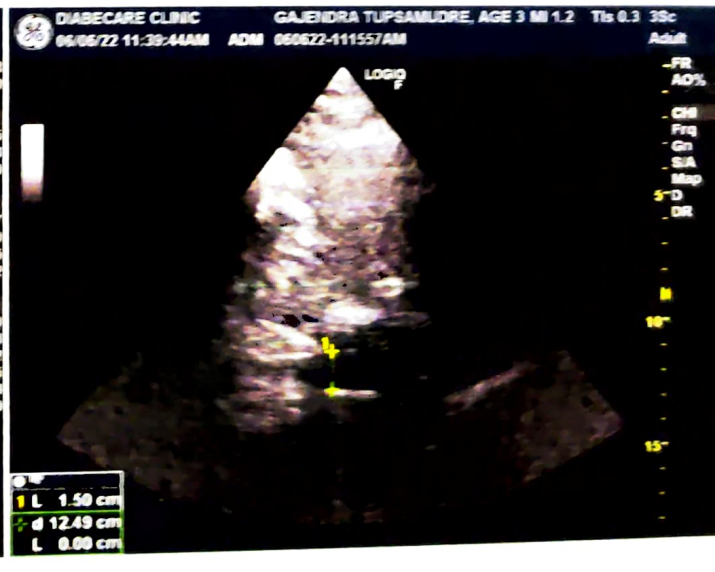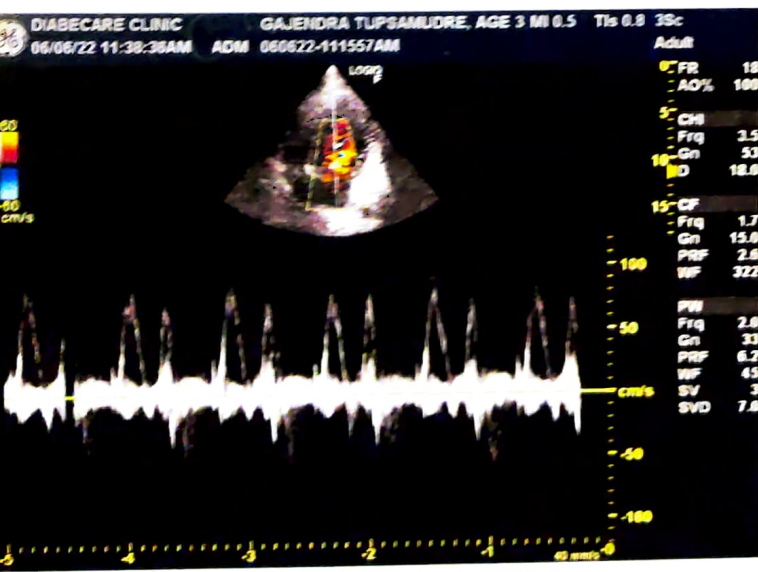
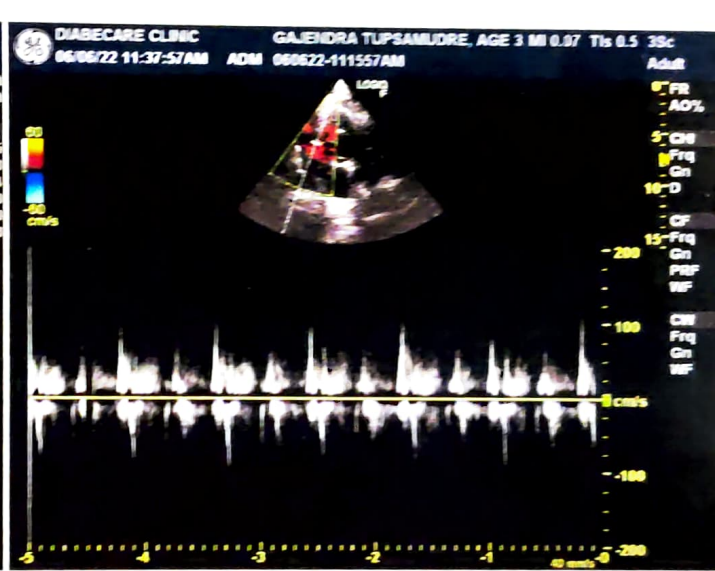
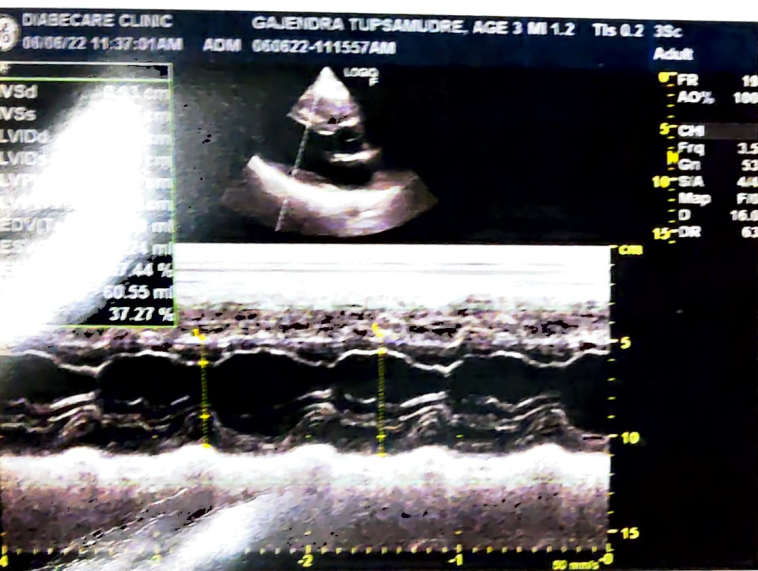
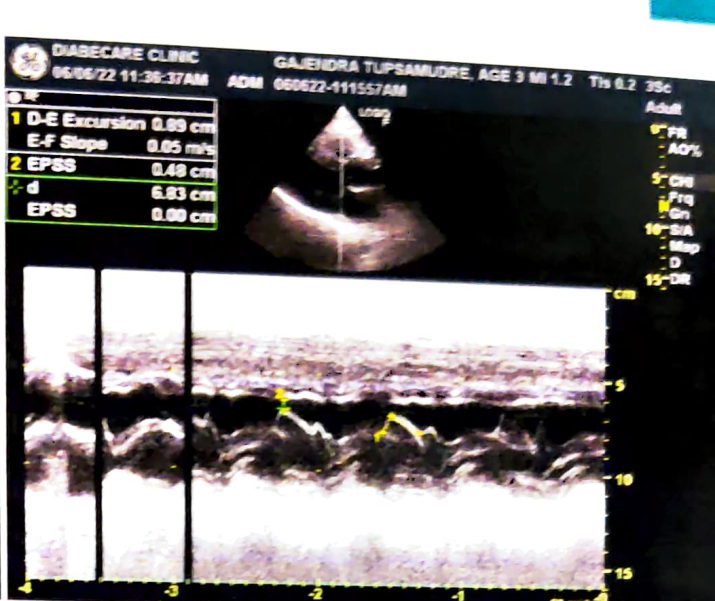
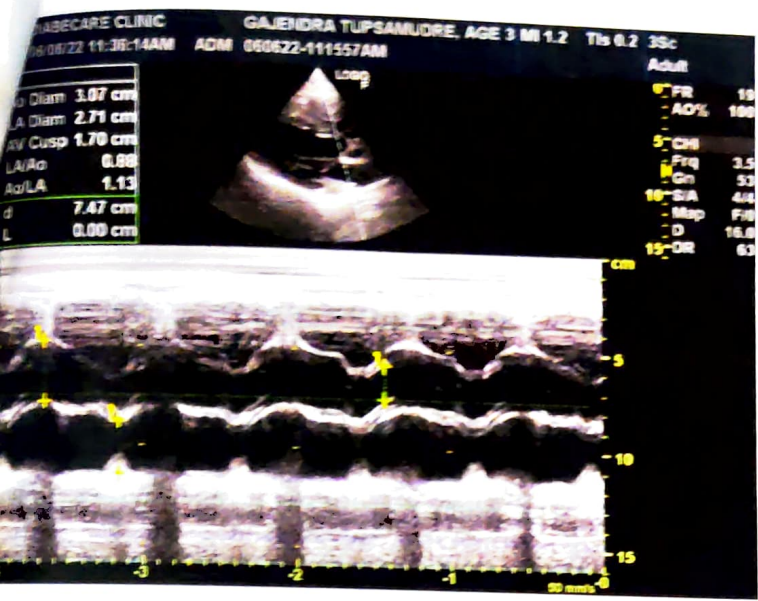
LVID (Diastole)35-56(mm)	- 44.00	LVID(Systole) 24-42(mm)	- 28.00
IVS(Diastole)8-12(mm)	- 9.00	IVS(Systole) 14-42(mm)	- 12.00
LVPWT(Diastole)6-11(mm)	- 9.00	EPSS	- 4.00
LVEF (%)	- 65%	LVFS(%)	- 37.00
LV Volume(Diastolic)(mm ³)		LV Volume (Systolic)(mm ³)	
Meridional Wall Stress in System		Cubed LV Volume in Diastole(mm ³)	
Cubed LV+ myocardial volume(mm ³)		Velocity of circumferential Shortening(mm)	
Aortic root 22-37(mm)	- 30.00	Left Atrium Width(mm)	
Left Atrium Length(mm)	- 27.00	Left Atrium Area(mm ²)	
Left Atrium Volume(mm ³)		RV Function	Normal
RV size	Normal	RA Size	Normal
RV volume(mm ³)		IVC Size(mm) – 15 mm Collapsible	
Pericardium	Normal		
Effusion	None		
Resp Variation	Present		
Predicted RV Systolic Pressure			

Doppler Findings- I



Dr. Mahesh Padsalge

Dr. Mahesh V. Padsalge
MD. (Medicine)
Consultant Physician
Reg. No. 91424 (MMC)





Olive
DIAGNOSTICS

THE HEALTH CHECK UP SPECIALIST

RADIOLOGY REPORT

NAME- GAJENDRA TUPSAMUDRA

DATE- 6/06/2022

AGE- 37/M

X-RAY CHEST PA

The Soft Tissues And Bony Thorax Are Normal.

Both The Costophrenic And Cardiophrenic Angles Are Clear.

The Lung Field Are Normal.

Cardiac Shape And Size Appears Normal.

Both The Hila Are Normal In Density And Position.

Both The Domes Of Diaphragm And Mediastinum Are Normal.

Impression: Normal Chest X-Ray.

For, 

DR MRUDULA BABAR
CONSULTANT RADIOLOGIST

Dr. MRUDULA BABAR
DMRE.CPS Mumbai 2009
(RADIOLOGIST)
Reg. No. 2005/03/2139

Name : MR GAJENDRA TUPSAMUDRE	Age/sex: 37 Yrs. /MALE
Ref by: MEDIWHEEL	Date: 06/06/2022

ULTRASOUND EXAMINATION OF ABDOMEN & PELVIS

Findings-

The Liver is normal in size, shape and echogenicity. No focal lesion is seen. The Hepatic veins appear normal. There is no IHBR dilatation. The portal vein appears normal.

The gall bladder is distended. The proximal C.B.D. is normal caliber

Visualized head of Pancreas appears normal in size and reflectivity. The pancreatic duct is not dilated. Rest of the pancreas and retro peritoneum is obscured by bowel gases

The spleen is normal in size, No focal lesion is seen. Splenic vein is normal at hilum.

Both kidneys are normal in position and size. They show normal cortical reflectivity and cortico-medullary differentiation. There is no evidence of renal calculus, hydronephrosis or mass.

Right kidney measures 10.1 x 3.4 cm

Left kidney measures 10.5 x 4.7cm

The Urinary bladder is well distended. No evidence of any intraluminal mass or calculi.


The visualized Prostate appears normal in size, shape and homogenous echotexture.


There is no free fluid is seen in the pelvis. No probe tenderness in present study.

IMPRESSION :-

➤ NO SIGNIFICANT ABNORMALITY IS SEEN IN PRESENT STUDY.

• Adv : clinical co-relation.




Dr. SIDRAM D. JADHAV
CONSULTANT RADIOLOGIST

Dr. Sidram D. Jadhav
MBBS, DMRE (Radiologist)
Reg. No.: 2004 / 09 / 3526

