



# PARKLINE DIAGNOSTICS PVT. LTD.

L.G. 3, 4 & 5, Bhuvana Towers, S.D. Road, Secunderabad - 500 003.  
Tel : +91 40-2784 5852, 6649 1787, 7995421787, 7093445852, Fax : +91 40 2784 7864  
Email parklinediagnostics@gmail.com www.parklinediagnostics.com



NABL Accredited  
Certificate No.MC-2566

## MEDICAL EXAMINATION REPORT

Name	Mr. Ch. L. V. K. Ravi Kumar		Date :	19/03/2022	
Company	clo: mediwheel		Reg. No. :	1888539	
Contact No.	8024997868		Sex	<input type="checkbox"/> M <input checked="" type="checkbox"/> F	Age : <input type="checkbox"/> 56
Type	Pre-Emp		Emp. No.:	155292	
	Overseas		Height	159cm	
	Annual	<input checked="" type="checkbox"/>	Weight	70kg	
Remarks					
	<p>- Impaired glucose tolerance (+) HbA1c 5.7%. Advice follow up.</p> <p>USG - Grade I prostatomegaly. Advice follow up.</p>				
	<p>DR. PRIYANKA SANNIDHI MBBS Regn. No: 11351</p>				
Fitness Status	Medically Fit / Unfit		Physician's Signature		

# COMPREHENSIVE MEDICAL EXAMINATION REPORT

NAME Mr. Ch. L. V. K. Ravi Kumar

AGE 56 yrs / male

MARITAL STATUS married CHILDREN : M  1 F  1

IDENTIFICATION (IF ANY) A\* mole on the (RT) side of the chest.



## PAST HISTORY

Any family H/o : High Blood Pressure, Heart Disease, Tuberculosis, Diabetes, Asthma, Cancer

Father

Any personal H/o Major illness like : Typhoid.....NIL.....Jaundice.....NIL.....Etc.

Any H/o STD.....Skin infection.....NIL

H/o Blood Transfusion.....Recent Vaccination.....COVISED 2 Dose

H/o Epilepsy.....NIL.....Giddiness.....NIL

H/o Surgery.....Fracture in the past.....NIL

## Any Personal H/O.

High Blood Pressure, Heart Disease Tuberculosis, Diabetes, Asthma, Cancer

not on medication

Drug Abuse, Drug Allergy, Micturition, Bowels, Alcohol, Smoking, Sleep, MC, Wt. Loss/Wt. Gain

Present illness / Medication

## GENERAL EXAMINATION

Conjunctiva :

Skin :

Ears :

Nose :

Throat & Oral Cavity :

NAD

Bone, Joints :

Nutritional Status :

Lymph Nodes :

Edema Feet :

Varicose Veins :

(N)

well nourished

NPD

NIL

NIL

**Distant Vision : Near Vision :**

Right Eye: 6/18 +2.00 sph 6/6

With glasses / Without glasses

left Eye: 6/18 +2.00 sph 6/6

with glasses / without glasses

Colour Vision : BE normal

**Right Ear**

Hearing : (N)

Rinee's Test ;

Weber Test :

Discharge : NIL

Right Eye: No Add +2.50 sph 6/6

With glasses / Without glasses

left Eye : No Add +2.50 sph 6/6

with glasses / without glasses

**Ophthalmologist's Signature**

**DR. KATTA**  
M.B.S., D.O., F.R.R.  
Royal College (AMG)

**Left Ear**

(N)

NIL

**SYSTEMIC EXAMINATION**

Pulse : 80 bpm

B.P. : 140/90 mmHg

Lungs : A. Shape of Chest R/c symmetrical  
B. Breath Sounds R/c - clear ⊕  
C. Adventitious Sounds NO

Heart : A. Sounds S<sub>1</sub> S<sub>2</sub> ⊕  
B. Murmurs NO murmurs

Abdomen : A. Liver NPD  
B. Spleen NPD  
C. Piles NIL  
D. Any Lump NIL

**Nervous System**

A. Higher Function :  
B. Cranial Nerves :  
C. Sensory System : (N)  
D. Motor System :  
E. Jerks :


General : A. Hernia J  
B. Hydrocele NAD  
C. Varicocele J

Breast : Rt \_\_\_\_\_ Lt. \_\_\_\_\_

## CANDIDATE'S DECLARATION

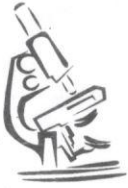I hereby solemnly declare that I am not suffering from Asthma, Hypertension, Diabetes, Occult Psychological disorders or any other ailment which can be suppressed without my voluntary declaration.

Date :

  
\_\_\_\_\_  
Signature

Place :

Note : General Physical Examination and Investigation included in the health check-up Have certain limitations and may not be able to detect all latent and asymptomatic diseases. Any new symptoms developing after the health check-up or persisting thereafter should be brought to the attention of the treating physician.



# PARKLINE DIAGNOSTICS PVT. LTD.

L.G. 3, 4 & 5, Bhuvana Towers, S.D. Road, Secunderabad - 500 003. Tel :+91 40-2784 5852, 6649 1787, 7995421787, 7093445852, Fax : +91 40 2784 7864 Email parklinediagnostics@gmail.com www.parklinediagnostics.com



NABL Accredited  
Certificate No.MC-2566

## ENT CONSULTATION

S.No. 1888539

Emp.No.

Date 19/03/22

Name

Mr. Ch. L.V.K. Ravi  
Kumar

Age 56 Yrs

Sex M/M/F

### EARS :

### Right

### Left

EAC

: patent. no. Cerumen.

-do-

TM

: Contact, pearly white.  
Cone of light (+)

-do-

TFT

: Rinne's +ve

Rinne's +ve.

Weber's - central

### NOSE

: Septum (N). Bil. Tur's (N). Pares (N) non-tender

### THROAT

: Oropharynx (N). Bil. v. c's (N) moving  
upper denture (+) Asymmetry bil.

### NECK

: (N)

### IMPRESSION:

ENT clinically NAD

Dr. D. Hari Krishna Reddy  
MS (ENT)  
Head & Neck Surgeon  
Reg. No: 88379



# SECUNDERABAD DENTAL HOSPITAL

CENTRE FOR ADVANCED DENTAL CARE

19/3/22

## ORAL & MAXILLOFACIAL SURGEONS

**Dr. Kazim Himathi** M.D.S.

**Dr. Gautam Dendukuri**

FDSRCS (Eng), FFDRCS (Ire),  
FFDRCS (OMFS), (Ire)

## PROSTHODONTIST

**Dr. Chandrakanth Reddy** M.D.S.

## ENDODONTIST

**Dr. Ram Narayan Reddy** M.D.S.

## ORTHODONTIST

**Dr. Rajesh Reddy** M.D.S., M.Orth RCS.

**Dr. Sudeep Bhalerao** M.D.S.

## PERIODONTIST

**Dr. Veerendranath Reddy** M.D.S.

## PERIODONTIST

**Dr. Soumya** M.D.S.

**Dr. Mounika** M.D.S.

## DENTAL SURGEONS

**Dr. N. Jagadish Rao** B.D.S.

**Dr. Baisakhi Saha** B.D.S.

Mr. CH. LVK Ravi Kumar  
56 yr/M

Patient requires a ~~general~~ regular  
dental check-up

of E,

1. Recession at 47

2. Pocket (+) at 47

3. Upper & lower complete dentures

## Treatment Plan

Adv. cleaning & maintenance  
of dentures.





# PARKLINE DIAGNOSTICS PVT. LTD.

L.G 3, 4 & 5, Bhuvana Towers, Sarojini Devi Road, Secunderabad - 500 003.  
Tel. +91 40 2784 5852, 6649 1787, 77995421787, 7093445852, Fax : + 91 40 2784 7864  
Email : parklinediagnostics@gmail.com, www.parklinediagnostics.com



NABL Accredited  
Certificate No.: MC-2566

## TEST REPORT

Name : Mr . CH L V K RAVI KUMAR [155792]  
Age / Gender : 56 Years / Male  
Ref.By : Medi Wheel  
Req. No : BIL1888539

TID : UMR0746888  
Registered on : 19-Mar-2022 07:51 AM  
Reported On : 19-Mar-2022 01:35 PM

### Ultrasound Whole Abdomen

**LIVER** is normal shape, size ( 13.0 cms) and has uniform echopattern.  
No evidence of focal lesion. No intrahepatic biliary ductal dilatation.  
Hepatic and portal vein radicals are normal.

**GALL BLADDER** shows normal shape and has clear contents.  
Gall bladder wall is of normal thickness.  
CBD is of normal calibre.

**PANCREAS** has normal shape, size and uniform echopattern.  
No evidence of ductal dilatation or calcification.

**SPLEEN** shows normal shape, size and echopattern.

**KIDNEYS** move well with respiration and have normal shape, size and echopattern.  
Cortico- medullary differentiations are well made out.  
No evidence of calculus or hydronephrosis.  
Right kidney measures 8.7 x 5.1 cms, Left kidney measures 9.5 x 5.2 cms.

**URINARY BLADDER** shows normal shape and wall thickness.  
It has clear contents. No evidence of diverticula.


**PROSTATE** shows enlarged in size and normal echopattern.  
It measures 3.2 x 4.1 x 3.8 cms, Vol 26 cc.

No evidence of free fluid in the abdomen

### IMPRESSION:

\* **Grade I Prostatomegaly.**

Suggested clinical correlation and follow up

  
Dr. Abid Yazden  
Consultant Radiologist

The Test marked with\*are not accredited by NABL

Lab Timings (Weekdays) : 7.00 am to 8.30 pm  
Sundays & Holidays : 7.00 am to 1.00 pm

Radiologists Timings (Weekdays) : 7.30 am to 1.30 pm  
& 5.30 pm to 7.45 pm  
Sundays & Holidays : 7.30 am to 9.30 am



# PARKLINE DIAGNOSTICS PVT. LTD.

L.G. 3, 4 & 5, Bhuvana Towers, Sarojini Devi Road, Secunderabad - 500 003 Tel. +91 40-2784 5852  
6649 1787 Fax :+91 40 2784 7864 Email : parklinediagnostics@gmail.com www.parklinediagnostics.com



NABL Accredited  
Certificate No. MC-2566

## TEST REPORT

Name : Mr . CH L V K RAVI KUMAR [155792]  
Age / Gender : 56 Years / Male  
Ref.By : Medi Wheel  
Req. No : BIL1888539

TID : UMR0746888  
Registered on : 19-Mar-2022 07:51 AM  
Reported On : 19-Mar-2022 11:10 AM

### X-RAY CHEST PA VIEW

Lung fields are clear.

Cardia is normal.

Hila are normal.

C P angles are free.

Bony cage is normal.

Soft tissues are normal.

**IMPRESSION : NORMAL CHEST X-RAY**

Dr. D.J. MOHAN  
MD DMRD  
(Reg No. 8995)  
Consultant Radiologist

The Test marked with\*are not accredited by NABL

Lab Timings (Weekdays) : 7.00 am to 8.30 pm

Sundays & Holidays : 7.00 am to 1.00 pm

Radiologists Timings (Weekdays) : 7.30 am to 1.30 pm

Sundays & Holidays

& 5.30 pm to 7.45 pm

: 7.30 am to 9.30 am



ID: 1888539 19-03-2022 08:05:19 AM

MR.CH.L.V.K.RAVI KUMAR

Male 56Years

CARDIART

HR : 86 bpm  
P : 103 ms  
PR : 132 ms  
QRS : 68 ms  
QT/QTc : 353/423 ms  
P/QRS/T : 46/62/55 °  
RV5/SV1 : 2.052/0.556 mV

NSR

NKC

**Dr. NAVEEN KUMAR .C**  
M.D., D.M.  
Consultant Cardiologist  
Reg. No. 52291

Diagnosis Information:  
Sinus Rhythm  
\*\*\*Normal ECG\*\*\*

Report Confirmed by:

REAL TIME ECG REPORT  
**PATIENT SUMMARY REPORT**

LINE DIAGNOSTICS PVT.LTD

: 1888539  
: MR CH L V K RAVI KUMAR  
SEX : 56 / MALE

HEIGHT (cm) : 159  
WEIGHT (kg) : 70  
PROTOCOL : BRUCE

REF. BY : MEDIWHEEL  
DONE BY : DR NAVEEN KUMAR C  
TECHNICIAN : G.M.SURESH

022, 13:03:0

HISTORY :  
ICATION :

CT OF TEST : Routine Check Up.  
FACTOR : None.  
IVITY : Very Active.  
ER INVESTIGATION : E C G  
ON FOR TERMINATION : THR ACHIEVED  
CISE TOLERANCE : Good (> 10 METS).  
CISE INDUCED ARRHYTHMIAS : No.  
MO RESPONSE : Normal.  
ONO RESPONSE : Normal.

IMPRESSION :  
negative for inducible ischemias  
COMMENTS :

**Dr. NAVEEN KUMAR .C**  
M.D., D.M.  
Consultant Cardiologist  
Reg. No 52291

Confirmed By : \_\_\_\_\_

Signature

