

ECHOCARDIOGRAPHY AND COLOUR DOPPLER IMAGING

NAME:-MRS SHEETAL DESHMUKH

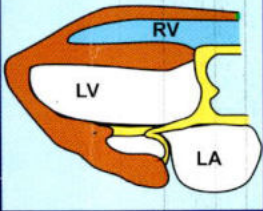
DATE – 01.12.2022

AGE:-YEARS 31 /FEMALE

REF DOCTOR:-HEALTH CHECKUP

REGIONAL ANALYSIS OF THE HEART

PARASTERNAL LONG AXIS

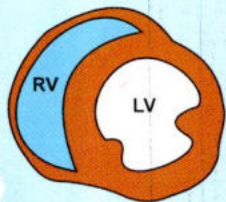


MYXOMATOUS MITRAL VALVE LEAFLETS WITH MILD MVP WITH GOOD LV FUNCTION EF= 60%

LEFT VENTRICLE - NORMAL SIZED
 NO REGIONAL WALL MOTION ABNORMALITY

NO S/O LV HYPERTROPHY IVS = 8mm, PW = 3mm PRESENT
 NO S/O DIASTOLIC DYSFUNCTION.
 OVERALL GOOD LV FUNCTION..EF= 60%

PARASTERNAL SHORT AXIS

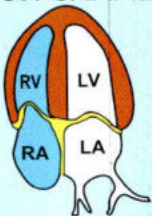


MYXOMATOUS MITRALVALVE LEAFLETS MILD MITRALVALVE PROLAPSE.

LEFT ATRIUM – NORMAL SIZED.

RIGHT ATRIUM /VENTRICLE - NORMAL SIZED
 OVERALL GOOD RV FUNCTION.

APICAL FOUR CHAMBER



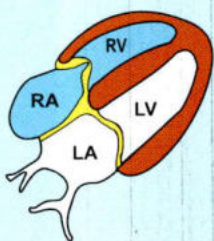
OTHER VALVES- NORMAL.

NO S/O PULMONARY HYPERTENSION PRESENT
PULMONARY ARTERY SYSTOLIC PRESSURE = 25mm Hg

NO S/O PERICARDIAL EFFUSION NOTED.

LVIDS - 23 mm
LVIDD - 36 mm

SUBCOSTAL



DR. RAHUL SHEWALE
 M.D. (Medicine)
 D.M. (Cardiology)
 Consultant Cardiologist
 Regd. No. 2010041390

Dr. MANOJ B. CHOPDA
 M.D. (Medicine) D.M. (Cardiology)
INTERVENTIONAL CARDIOLOGIST

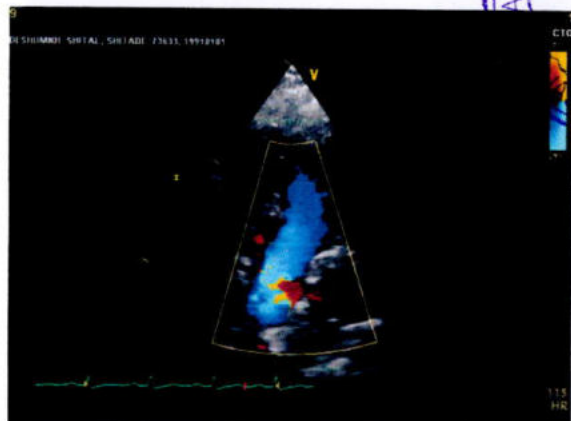
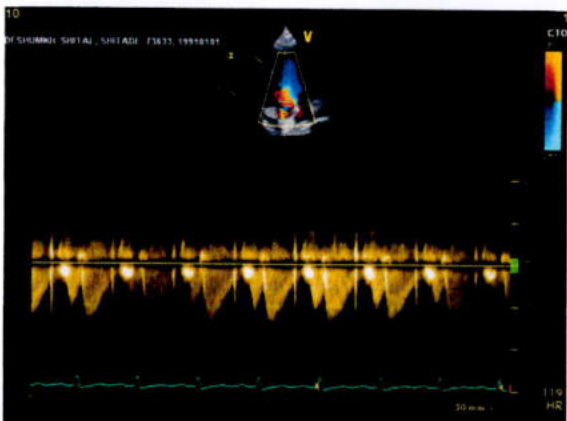

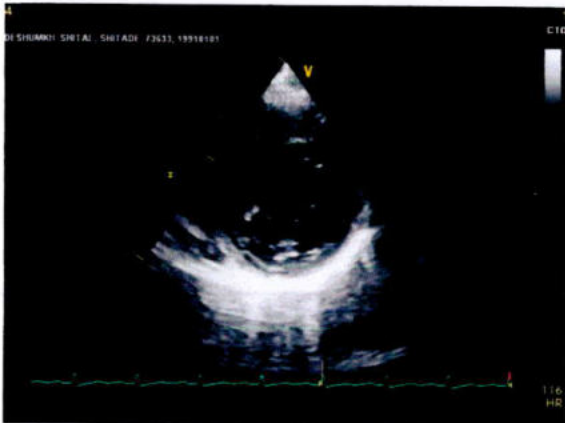
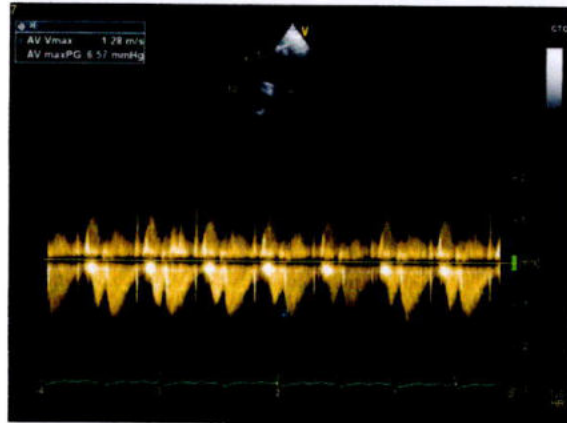
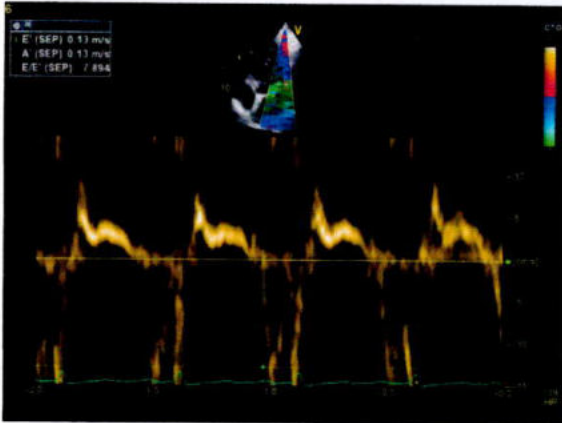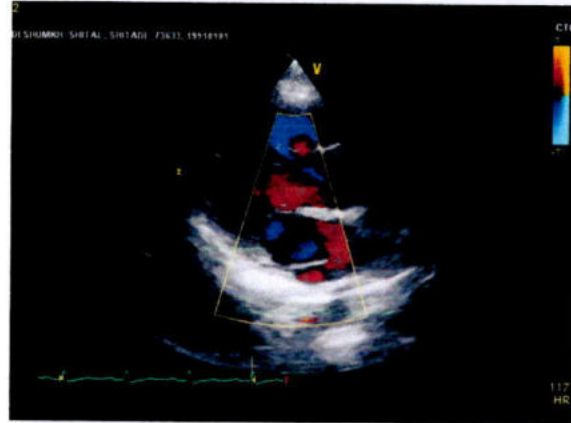
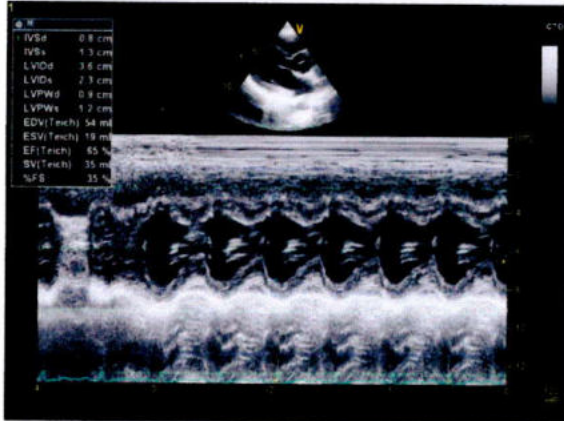
MAGNUM MULTISPECIALITY HOSPITAL NASIK ROAD, NASHIK

Name **SHITAL, DESHUMKH**

Sex **Female**

Age **31**

Date **01/12/2022**





To,

The Coordinator,
Mediwheel (Arcofemi Healthcare Limited)
Helpline number: 011- 41195959

Dear Sir / Madam,

Sub: Annual Health Checkup for the employees of Bank of Baroda

This is to inform you that the following spouse of our employee wishes to avail the facility of Cashless Annual Health Checkup provided by you in terms of our agreement.

PARTICULARS OF HEALTH CHECK UP BENEFICIARY	
NAME	SHITAL MANOJ DESHMUKH
DATE OF BIRTH	15-01-1991
PROPOSED DATE OF HEALTH CHECKUP FOR EMPLOYEE SPOUSE	01-12-2022
BOOKING REFERENCE NO.	22D175206100032188S
SPOUSE DETAILS	
EMPLOYEE NAME	MR. DESHMUKH MANOJ SURESHRAO
EMPLOYEE EC NO.	175206
EMPLOYEE DESIGNATION	BRANCH HEAD
EMPLOYEE PLACE OF WORK	TRYAMBAKESHWAR
EMPLOYEE BIRTHDATE	06-02-1985

This letter of approval / recommendation is valid if submitted along with copy of the Bank of Baroda employee id card. This approval is valid from **30-11-2022** till **31-03-2023**. The list of medical tests to be conducted is provided in the annexure to this letter. Please note that the said health checkup is a **cashless facility** as per our tie up arrangement. We request you to attend to the health checkup requirement of our employee's spouse and accord your top priority and best resources in this regard. The EC Number and the booking reference number as given in the above table shall be mentioned in the invoice, invariably.


We solicit your co-operation in this regard.

Yours faithfully,

Sd/-

**Chief General Manager
HRM Department
Bank of Baroda**

(Note: This is a computer generated letter. No Signature required. For any clarification, please contact Mediwheel (Arcofemi Healthcare Limited))



कूट क्र. | E.C.No. **175206**

नाम | Name **Manoj Suresh Rao Deshmukh**

पदनाम | Desi. **Manager**

धारक के हस्ताक्षर | Signature of Holder

Manoj Deshmukh

01/03/2022

जारी करने की तारीख

Date of Issue

S. P. Deshmukh

जारीकर्ता प्राधिकारी

Issuing Authority



 **भारत सरकार**
Government of India




शितल मनोज देशमुख
Shital Manoj Deshmukh
जन्म तारीख/ DOB: 15/01/1991
महिला / FEMALE



3507 1094 1256




माझे आधार, माझी ओळख

 **भारतीय विशिष्ट ओळख प्राधिकरण**
Unique Identification Authority of India

पत्ता:
W/O मनोज सुरेशराव देशमुख, वकील
पळा, मु/पो-धांदरफळ बु.ता-संगमनेर,
धान्दरफळ बुद्रुक, अहमदनगर,
महाराष्ट्र - 422603

Address:
W/O Manoj Suresh
Deshmukh, Wakil Mala, At/Post-
Dhandarphal Bk, Tal-Sangamner,
Dhandarphal Bk, Ahmadnagar,
Maharashtra - 422603

3507 1094 1256

help@uidai.gov.in www.uidai.gov.in

**MAGNUM MULTISPECIALITY HOSPITAL
NASIK ROAD, NASHIK**

Name **SHITAL, DESHUMKH**

Sex **Female**

Age **31**

Date **01/12/2022**

Operator Name **Default user**

2D

M MODE

IVSd 0.8 cm
LVIDd 3.6 cm
LVPWd 0.9 cm
IVSs 1.3 cm
LVIDs 2.3 cm
LVPWs 1.2 cm
EDV(Teich) 54 ml
ESV(Teich) 19 ml
EF(Teich) 65 %
%FS 35 %
SV(Teich) 35 ml

Dop

MV E Vel 1.02 m/s
MV DecT 97 ms
MV Dec Slope 10.5 m/s²
MV A Vel 0.25 m/s
MV E/A Ratio 4.13
AV Vmax 1.28 m/s
AV maxPG 6.57 mmHg
TR Vmax 1.91 m/s
TR maxPG 14.60 mmHg



Dr. Rahul Shewale
MD (Medicine) , DM (Cadiology)
Interventional Cadiologist

DATE :- 3/12/22

HEIGHT -

WEIGHT :- 61.



MAGNUM NASHIK HEALTHCARE LLP

MAGNUM

MULTISPECIALITY HOSPITAL

Health checkup

S/B DR. JAYDEEP BHAMBARE

PATIENT NAME :- Sheetal Deshmukh

AGE /SEX:- 31/f

126/100/96 @ No symptoms up to

Predominant veg.

Hb 9.8.

occ urine burning.

102/112.

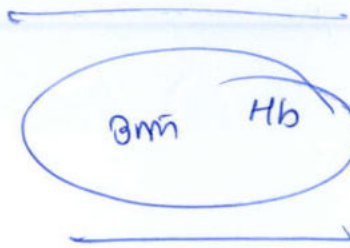
divogen जठमिवादि 1/2 मात्र

5/5

Fluoritis -> 5/5

-x gm

Handroom Hygiene



Patient's Name : Mrs. Shital Deshmukh

Date : 01/12/2022

Ref. By : Dr. Manoj Chopda (MD,DM)


Age/Sex : 31yrs/Female

THYROID FUNCTION TEST REPORT

<u>TEST</u>	<u>OBSERVED VALUE</u>	<u>NORMAL RANGE</u>
T3	1.421 ng/ml	0.69 – 2.15 ng/ml
T4	9.01 ug/dl	5.2 – 12.7 ug/dl
TSH Ultra-Sensitive	2.512 uIU/ml	0.4 – 4.5 uIU/ml

METHOD : By Chemiluminescence System

Pathologist
Dr. Sudhir Sankalecha
MD (Path)
Reg No - 70405





MAGNUM NASHIK HEALTHCARE LLP

MAGNUM

MULTISPECIALITY HOSPITAL

Patient's Name : Mrs. Shital Deshmukh

Date : 01/12/2022

Ref. By : Dr. Manoj Chopda (MD,DM)

Age/Sex : 31 yrs / F

BLOOD EXAMINATION REPORT

(By Fully Automated cell counter)

Haemoglobin : 9.8 gm % (11.0 – 17.0 gm %)

White Blood Cells

Total Count : 4700 / cmm (4500 – 10500 / cmm) [H10 percent vF]

Differential Count

Neutrophils : 52 % (45 – 75 %)
Lymphocytes : 41 % (20 – 48 %)
Eosinophils : 03 % (01 – 04 %)
Monocytes : 04 % (04 – 10 %)
Basophils : 00 % (00 – 01 %)

Platelets : 3.66 Lacs/cmm (1.5 – 4.5 Lacs/cmm)

R.B.C. : 3.32 mil/cmm (4.00 – 6.00 mil/cmm)

Haematocrit (P.C.V.) : 30.1 % (35 - 50 %)

M.C.V. : 91 fL (80 – 99 fL)

M.C.H. : 29.5 pg (27 – 32 pg)

M.C.H.C. : 32.6 g/dl (31.5 – 36 g/dl)

R.D.W. : 16.6 % (10.0 – 15.0 %)

E.S.R : 18 mm/ at the end of 1 hrs 0 - 15 mm/hrs



Pathologist

Dr. Sudhir Sankalecha
MD (Path)

Reg. No. 70405

Patient's Name : Mrs. Shital Deshmukh

Date : 01/12/2022

Ref. By : Dr. Manoj Chopda (MD,DM)

Age/Sex :31 yrs / F

BIOCHEMISTRY REPORT

TEST

OBSERVED VALUE

NORMAL VALUE

LIPID PROFILE

S. Cholesterol	: 175.5 mg/dl	Up to 200 mg/dl
S. Triglyceride	: 73.4 mg/dl	Up to 160 mg/dl
HDL Cholesterol	: 42.0 mg/dl	30 – 65 mg/dl
LDL Cholesterol	: 118.82 mg/dl	75 – 165 mg/dl
VLDL Cholesterol	: 14.68 mg/dl	6.0 – 38.0 mg/dl
LDL/HDL Ratio	: 2.82	2.5 – 4
Chol/HDL Chol Ratio	: 4.17	3 – 5.5



Pathologist
Dr. Sudhir Sankalecha
MD (Path)
Reg. No. 70405

Patient's Name : Mrs. Shital Deshmukh

Date : 01/12/2022

Ref. By : Dr. Manoj Chopda (MD,DM)

Age/Sex :31 yrs / F

BIOCHEMISTRY REPORT

<u>TEST</u>	<u>OBSERVED VALUE</u>	<u>NORMAL RANGE</u>
Blood Urea	: 16.7 mg/dl	15 – 45 mg/dl
S.Creatinine	: 0.88 mg/dl	0.6 – 1.4 mg/dl
S.Uric acid	: 3.5 mg/dl	2.5 – 7.2 mg/dl
LFT :		
S.Bilirubin		
Total	: 0.6 mg/dl	0.2 – 1.1 mg/dl
Direct	: 0.2 mg/dl	0.0 – 0.4 mg/dl
Indirect	: 0.4 mg/dl	0.2 – 0.6 mg/dl
S.G.O.T.	: 34.0 IU/L	8 – 40 IU/L
S.G.P.T.	: 11.4 IU/L	5 – 50 IU/L
S.Alk PO4	: 93.8 IU/L	70 – 306 IU/L
S.Proteins		
Total	: 7.4 g/dl	6 – 7.8 g/dl
Albumin	: 4.1 g/dl	3.2 – 4.6 g/dl
Globulin	: 3.3 g/dl	2.3 – 3.5 g/dl
A/G Ratio	: 1.24	
Gamma –GT	: 21.3 IU/L	0 – 45 IU/L



Pathologist
 Dr. Sudhir Sankalecha
 MD (Path)
 Reg.No 70405

Patient's Name : Mrs. Shital Deshmukh

Date : 01/12/2022

Ref. By : Dr. Manoj Chopda (MD,DM)

Age/Sex : 31 yrs / F

URINE EXAMINATION REPORT

PHYSICAL CHARACTERISTICS

Volume : 20 ml Appearance : Slightly hazy
Colour : Yellow Reaction : Acidic

CHEMICAL EXAMINATION

Albumin : Absent Bile Salts : Absent
Sugar : Absent Bile Pigments : Absent
Ketones : Absent

MICROSCOPIC EXAMINATION

Epithelial Cells : 12 – 15/hpf R.B.C.s : 0 – 2/hpf
Pus Cells : 3 – 5/hpf Casts : Absent
Crystals : Absent Bacilli : Absent
Other : Absent



HS
Pathologist
Dr. Sudhir Sankalecha
MD (Path)
Reg. No. 70405

Patient's Name : Mrs. Shital Deshmukh

Date : 01/12/2022

Ref. By : Dr. Manoj Chopda (MD,DM)

Age/Sex :31 yrs / F

BIOCHEMISTRY REPORT

<u>TEST</u>	<u>OBSERVED VALUE</u>	<u>NORMAL RANGE</u>
Blood Sugar (Fasting):	102.4 mg/dl	60 – 110 mg/dl
Blood Sugar (PP) :	112.3 mg/dl	80 – 140 mg/dl

<u>Test</u>	<u>Result</u>	<u>Reference Range</u>
HBA1C :	5.6 %	
METHOD :	HPLC METHOD	

Performed On : Biorad D 10

Reference Range As per ADA

Normal : Below 5.7%

Pre-Diabetes : 5.7% - 6.4%

Diabetes : \geq 6.5%


Guidance For Known Diabetes

Good Control : Below 6.5%

Fair Control : 6.5% - 7.0%

Unsatisfactory Control : 7.0% - 8.0%

Poor Control : $>$ 8.0%



Pathologist
Dr. Sudhir Sankalecha
MD (Path)
Reg.No - 70405

Patient's Name : Mrs. Shital Deshmukh

Date : 01/12/2022

Ref. By : Dr. Manoj Chopda (MD,DM)

Age/Sex :31 yrs / F

BLOOD EXAMINATION REPORT

Test

Result

Blood Group

: ' O '

Rh Factor

: Positive



Pathologist
Dr. Sudhir Sankalecha
MD (Path)
Reg. No. 70405

ID: 0

01-12-2022 09:29:06 AM

SHEETAL DESHMUKH

Female 31 Years

Department:

Diagnosis Information:

Sinus tachycardia

Inferior/lateral ST-T abnormality is borderline for age and gender

Borderline ECG

HR : 118 bpm

P : 112 ms

PR : 146 ms

QRS : 74 ms

QT/QTc : 308/432 ms

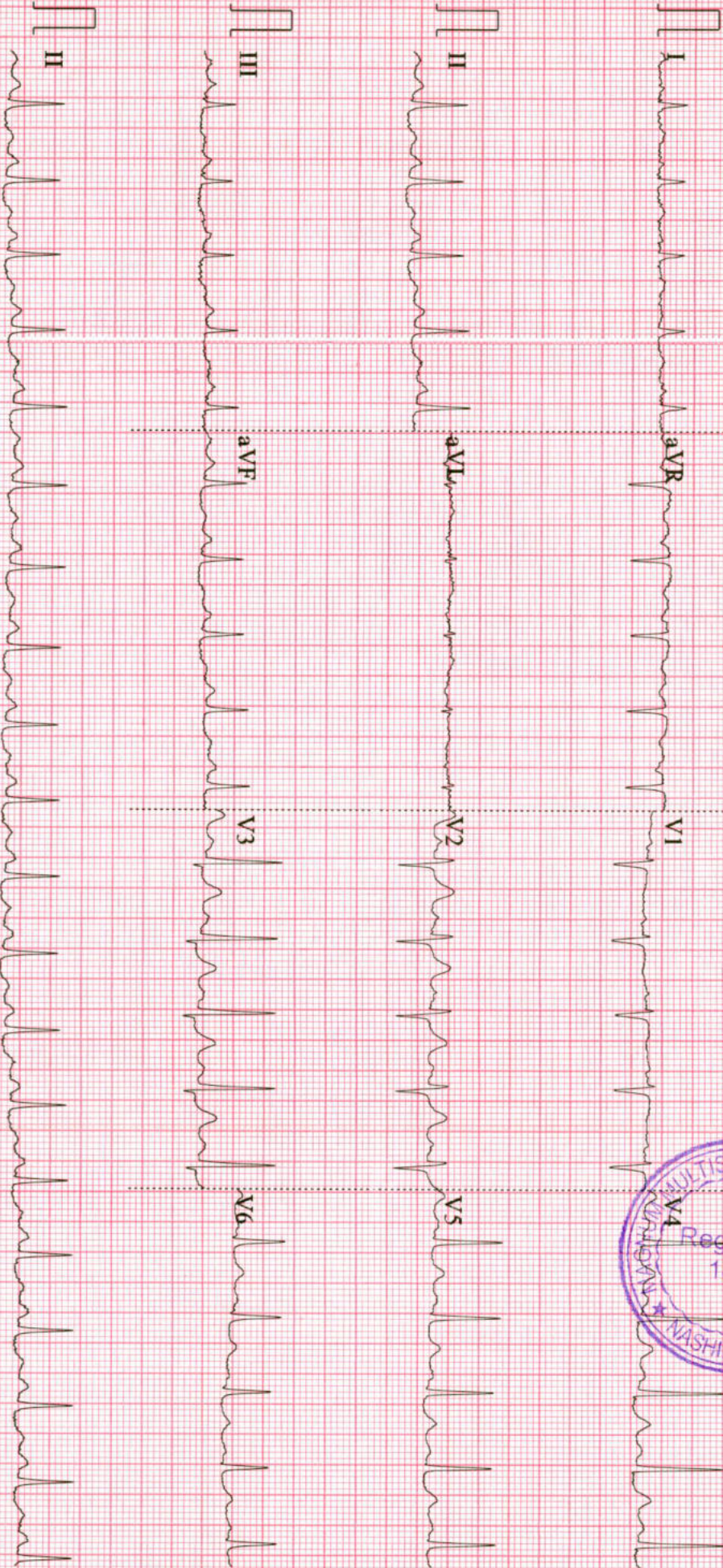
P/QRST : 76/65/9 °

RV5/SV1 : 1.077/0.515 mV

Report Confirmed by:



ST 2022





NAME: MRS. SHITAL DESHMUKH	DATE: 01/12/2022
AGE/ SEX: 31 YEARS/ FEMALE	REFERRED BY: DR. MANOJ CHOPDA (MEDIWHEEL HEALTH CHECKUP)

XRAY CHEST PA (VIEW)

Clinical profile- Health checkup.

Both the lungs are clear and do not show any obvious focal lesion.

Bilateral costo-phrenic and cardio-phrenic angles appear clear.

There is no evidence of pleural effusion or pneumothorax on either side.

Both the hilum appear normal.


Domes of diaphragm have normal contours and positions.

Visualised bones and soft tissues reveal no abnormality.

CONCLUSION:

- No significant abnormality is seen.




DR TRIPTI PAREEK
(DNB RADIODIAGNOSIS)

ULTRASOUND ABDOMEN & PELVIS

NAME: MRS.SHITAL DESHMUKH	DATE: 01/12/2022
AGE/ SEX: 31 YEARS/ FEMALE	REFERRED BY: DR. MANOJ CHOPDA (MEDIWHEEL HEALTH CHECKUP)

Clinical profile- Health check up.

Liver: Normal in size, shape and shows normal echotexture. No evidence of any space occupying lesion seen. Intrahepatic biliary radicals are not dilated. Portal vein is normal in caliber.

Gallbladder: GB is collapsed. CBD is normal in caliber.

Pancreas: Visualized in its entire extent and appears normal in bulk & echotexture.

Spleen: Appears normal in size, shape and echotexture. No calcification or mass is seen.

Kidneys: Right kidney – 9.5 x 3.4 cm. Left kidney –10 x 5.6 cm.

Both kidneys are normal in shape, positions and echotexture. Bilateral corticomedullary differentiation appears normal. No hydronephrosis seen. No evidence of any calculus or mass lesion seen.

Urinary Bladder: is well distended. No evidence of calculus/ wall thickening noted.

Uterus measures 9 x 6.3 x 3.9 cm appears normal in size, shape and echotexture. Endometrium appears normal measuring 3.9 mm. No evidence of adnexal abnormality.

Right ovary measures 6 cc. Left ovary measures 3 cc

Bilateral ovaries appears normal in size and echotexture.

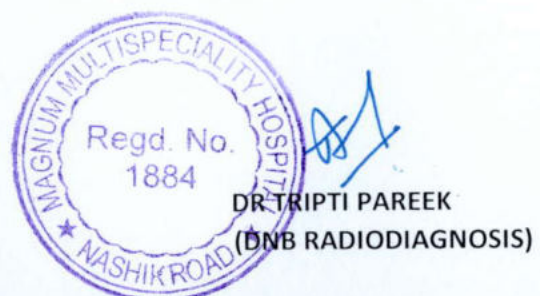Lymphadenopathy: No significant lymphadenopathy noted.

Free fluid: No evidence of any free fluid in peritoneal cavity.

IMPRESSION:

- No significant abnormality seen in present scan.

Clinical correlation is suggested.



**MAGNUM MULTISPECIALITY HOSPITAL
NASIK ROAD, NASHIK**

Name **DESHMUKH, SHITAL**

Sex **Female**

Age **31**

Date **01/12/2022**

