

Blood Pressure : 110/76 mm of Hg

Height : 150 cm

Weight : 50 Kg

Body Mass Index : 22.2

EMERGENCY

ACCIDENT & TRAUMA LINE



Medicine Delivery at Your Doorstep Call.:
07720965555

Dr. Dipti Shende

MS (Obstetrics & Gynecology)
DNB (Obstetrics & Gynecology)
Consultant - Obstetrics & Gynaecology
Regd. No.: 2009031429

Date: 11/2/23

Name:

Rutuja Sarder.

UHID:

Primary Diagnosis:

Age: 33y

Chief Complaints:

for pap smear.

Rx

LMP: - 4/2/23

P/S:- Cx 1/9 (G).

Asb=

- pap smear collected.

T-Afebril / Febrile	___ OF
P-	___ / min
R-	___ / min
B.P.-	___ / ___ mmHg
Pain - Yes / No	___
Fall Risk : Yes / No	___

Shende.

FOLLOW-UP AFTER
___ DAYS



WOCKHARDT HOSPITALS, NAGPUR

1643, North Ambazari Road, Nagpur - 440 010. Tel : (0712) 6624444, 6624100

Fax : (0712) 2261266 Website : www.wockhardthospitals.com

Registered Office Address :- Wockhardt Towers , BKC , Bandra (East) Mumbai 400051

CIN: U85100MH1991PLC063096

Patient Name : MRS. RUTUJA VIJAY SARDAR

Age/Sex : 33 Yrs / Female

Order Date : 11/02/2023 10:04 AM

UHID : WHN2.0000334242

Referred by :

Reporting Date : 11/02/2023 03:02 PM

Order No. : 1568

Bill No. : OCR3/23/0000296

CHEST X-RAY PA VIEW :

Both lung fields are clear.

The costophrenic angles and domes of diaphragm appear normal.

No hilar or mediastinal lesion seen.

Cardiac silhouette is within normal limits.

Visualised bony thorax and soft tissues appear normal.

Impression:

Normal Chest X-Ray.

Preeti

DR. PREETI CHOUDHARY JAIN
M.B.B.S., D.M.R.E.
RADIOLOGIST



WOCKHARDT HOSPITALS, NAGPUR

1643, North Ambazari Road, Nagpur - 440 010. Tel : (0712) 6624444, 6624100

Fax : (0712) 2261266 Website : www.wockhardthospitals.com

Registered Office Address :- Wockhardt Towers, BKC, Bandra (East) Mumbai 400051

CIN: U85100MH1991PLC063096

Patient Name : MRS. RUTUJA VIJAY SARDAR

Age/Sex : 33 Yrs / Female

UHID : WHN2.0000334242

Reporting Date : 11/02/2023 02:17 PM

Bill No. : OCR3/23/0000298

Order Date : 11/02/2023 10:04 AM

Referred by :

Order No. : 1568

USG ABDOMEN WITH PELVIS :

Real time sonography of the abdomen and pelvis was performed .

The liver is normal in size and echotexture. No focal parenchymal lesion noted. Intrahepatic biliary tree and venous radicles are normal.

The portal vein and CBD appear normal in course and calibre.

The gall bladder is normal in size with a normal wall thickness and there are no calculi noted within.

The pancreas is normal in size and echotexture. No evidence of focal lesion or calcification or duct dilatation seen.

The spleen is normal in size and echotexture.

Both kidneys are normal in size, position and echogenicity.

Cortical thickness and corticomedullary differentiation are normal.

No hydronephrosis or calculi noted.

The bladder is normal in contour, capacity and wall thickness.

No vesical calculi noted.

The uterus is normal in size and RETROverted in position.

Myometrial echotexture is homogenous. No focal lesions seen.

Endometrial echocomplex is central in position and 6 mm in thickness.

Both ovaries are normal in size and echogenicity.

No adnexal mass lesion seen.

There is no evidence of free fluid in pouch of Douglas.

There is no evidence of ascites.

Impression :

No significant abnormality noted on this study.

Preeti

DR. PREETI CHOUDHARY JAIN

M.B.B.S., D.M.R.E.

RADIOLOGIST



WOCKHARDT HOSPITALS, NAGPUR

1643, North Ambazari Road, Nagpur - 440 010. Tel : (0712) 6624444, 6624100

Fax : (0712) 2261266 Website : www.wockhardthospitals.com

Registered Office Address :- Wockhardt Towers, BKC, Bandra (East) Mumbai 400051

CIN: U85100MH1991PLC063096

HEMATOLOGY

Patient Name : MRS. RUTUJA VIJAY SARDAR
 Age / Sex : 33 Years / Female
 UHID : WHN2.0000334242
 Primary Consultant : DR. WOCKHARDT DOCTOR
 Order No. : 4151
 Bill No. : OCR3/23/0000298
 Order Date : 11/02/2023 10:04 AM
 Sample Collection : 11/02/2023 11:06 AM
 Report Date : 11/02/2023 12:42 PM
 Specimen : EDTA Blood

PARAMETER	METHOD	RESULT	UNIT	B.R.I
MEDIWHEEL FULL BODY HCU MALE AND FEMALE BELOW 40				
Complete Blood Count (With ESR)- EDTA Blood				
Haemoglobin	SLS Method	12.0	g%	11-15
Haematocrit	RBC Pulse Height Detection	40.1	%	40 - 50
MCV	Calculated	72.6	fl	83-101
MCH	Calculated	21.7	pg	27-32
MCHC	Calculated	29.9	g/dl	32-35
RBC Count	DC Detection	5.52	Million/ul	3.8-4.8
RDW-CV	Calculated	17.1	%	12-14
WBC Total Count (TLC)	Electrical Impedance	7700	Cells/cumm	4000 - 10000
Neutrophils	Hydrodynamic Focussing And Microscopy	57	%	40-80
Lymphocytes	Hydrodynamic Focussing And Microscopy	34	%	28-48
Monocytes	Hydrodynamic Focussing And Microscopy	06	%	2-10
Eosinophils	Hydrodynamic Focussing And Microscopy	03	%	0-6
Basophils		0	%	0-2
Platelet Count	Hydrodynamic Focusing DC	330	Thou/Cumm	150-450
MPV		10.0	Calculated	9.4-12.3
Neutrophil Lymphocyte Ratio		1.67		
Blood ESR	Westergres Method	43	mm/hr	0-20



DEPARTMENT OF LABORATORY MEDICINE

HEMATOLOGY

WOCKHARDT
HOSPITALSLIFE
WINS
Final Report


Patient Name	: MRS. RUTUJA VIJAY SARDAR	Order Date	: 11/02/2023 10:04 AM
Age / Sex	: 33 Years / Female	Sample Collection	: 11/02/2023 11:06 AM
UHID	: WHN2.0000334242	Report Date	: 11/02/2023 12:42 PM
Primary Consultant	: DR. WOCKHARDT DOCTOR	Specimen	: EDTA Blood
Order No.	: 4151		
Bill No.	: OCR3/23/0000298		

<u>PARAMETER</u>	<u>METHOD</u>	<u>RESULT</u>	<u>UNIT</u>	<u>B.R.I</u>
------------------	---------------	---------------	-------------	--------------

MEDIWHEEL FULL BODY HCU MALE AND FEMALE BELOW 40**Complete Blood Count (With ESR)- EDTA Blood**

--- END OF REPORT ---

JWALA GAJBHIYE
Verified By


Dr. ALKA THOOL
Consultant Pathologist
M.B.B.S, MD PATH

Partial reproduction of report not permitted. This report relates to sample received by laboratory
* B.R.I : BIOLOGICAL REFERENCE INTERVAL ** Test not in Scope of Accreditation

**WOCKHARDT HOSPITALS, NAGPUR**

1643, North Ambazari Road, Nagpur - 440 010, Tel : (0712) 6624444, 6624100

Fax : (0712) 2261266 Website : www.wockhardthospitals.com

Registered Office Address :- Wockhardt Towers , BKC , Bandra (East) Mumbai 400051


CIN: U85100MH1991PLC063096

Patient Name : MRS. RUTUJA VIJAY SARDAR
 Age / Sex : 33 Years / Female
 UHID : WHN2.0000334242
 Primary Consultant : DR. WOCKHARDT DOCTOR
 Order No. : 4151
 Bill No. : OCR3/23/0000298
 Order Date : 11/02/2023 10:04 AM
 Sample Collection : 11/02/2023 11:06 AM
 Report Date : 11/02/2023 01:00 PM
 Specimen : EDTA Blood

PARAMETER	METHOD	RESULT	UNIT	B.R.I
MEDIWHEEL FULL BODY HCU MALE AND FEMALE BELOW 40				
Glycosylated Haemoglobin- EDTA Blood				
Glycosylated Haemoglobin	HPLC	5.5	%	Action required: 7.0-8.0% Good control: 6.5-7.0% Normal control: 4.8-6.4% Poor control: >8.0%
Estimated Mean glucose	Calculated	118.50	mg/dL	

--- END OF REPORT ---

J WALA GAJBHIYE
Verified By


Dr. ALKA THOOL
Consultant Pathologist
M.B.B.S, MD PATH

Partial Reproduction of Report not permitted. This Report Relates to Sample received by Laboratory
 * B.R.I : BIOLOGICAL REFERENCE INTERVAL ** Test not in Scope of Accreditation




Patient Name : MRS. RUTUJA VIJAY SARDAR
Age / Sex : 33 Years / Female
UHID : WHN2.0000334242
Primary Consultant : DR. WOCKHARDT DOCTOR
Order No. : 4151
Bill No. : OCR3/23/0000298
Order Date : 11/02/2023 10:04 AM
Sample Collection : 11/02/2023 11:34 AM
Report Date : 11/02/2023 01:00 PM
Specimen : Fluoride Plasma

PARAMETER	METHOD	RESULT	UNIT	B.R.I
MEDIWHEEL FULL BODY HCU MALE AND FEMALE BELOW 40				
Plasma Glucose- Post Glucose		93	mg/dL	70-140
Urine Sugar Post Prandial	Double Sequential Enzyme Reaction - GOD/ POD	NA		

--- END OF REPORT ---

WALA GAJBHIYE
 Verified By


Dr. ALKA THOOL
 Consultant Pathologist
 M.B.B.S, MD PATH

Partial Reproduction of Report not permitted. This Report Relates to Sample received by Laboratory
 * B.R.I : BIOLOGICAL REFERENCE INTERVAL ** Test not in Scope of Accreditation

DEPARTMENT OF LABORATORY MEDICINE

WOCKHARDT
HOSPITALS

LIFE
WINS
Final Report

BIOCHEMISTRY

Patient Name : MRS. RUTUJA VIJAY SARDAR
 Age / Sex : 33 Years / Female
 UHID : WHN2.0000334242
 Primary Consultant : DR. WOCKHARDT DOCTOR
 Order No. : 4151
 Bill No. : OCR3/23/0000298
 Order Date : 11/02/2023 10:04 AM
 Sample Collection : 11/02/2023 11:06 AM
 Report Date : 11/02/2023 01:00 PM
 Specimen : Serum

PARAMETER	METHOD	RESULT	UNIT	B.R.I
MEDIWHEEL FULL BODY HCU MALE AND FEMALE BELOW 40				
Serum Urea	Urease-GLDH	14	mg/dL	1-50
Blood Urea Nitrogen	Calculated	6.6	mg/dL	6-20
Creatinine- Serum				
Creatinine	Enzymatic colorimetric	0.53	mg/dL	0.51-0.95
Plasma Glucose				
Random Sugar		88.39	mg/dl	
Uric Acid- Serum				
Uric Acid	Enzymatic colorimetric	4.6	mg/dL	2.4-5.7
Cholesterol	Colorimetric - Cholesterol Oxidase	130.04	mg/dL	0-200
Triglycerides	Enzymatic colorimetric	77.3	mg/dL	0-150
HDL Cholesterol - Direct	Direct Homogenous Enzymatic Colorimetric	43.2		>65: No risk <45-65: Moderate risk <45: High risk
LDL-Cholesterol -Direct	Direct Homogenous Enzymatic Colorimetric	71.38	mg/dL	0-100
VLDL Cholesterol	Calculated	15.46	mg/dL	10-35
Chol/HDL Ratio		3.01		0-3



DEPARTMENT OF LABORATORY MEDICINE

BIOCHEMISTRY



Patient Name : MRS. RUTUJA VIJAY SARDAR
 Age / Sex : 33 Years / Female
 UHID : WHN2.0000334242
 Primary Consultant : DR. WOCKHARDT DOCTOR
 Order No. : 4151
 Bill No. : OCR3/23/0000298
 Order Date : 11/02/2023 10:04 AM
 Sample Collection : 11/02/2023 11:06 AM
 Report Date : 11/02/2023 01:00 PM
 Specimen : Serum

PARAMETER	METHOD	RESULT	UNIT	B.R.I
-----------	--------	--------	------	-------


MEDIWHEEL FULL BODY HCU MALE AND FEMALE BELOW 40

Liver Function Test (L.F.T.)

Alkaline Phosphatase	Colorimetric IFCC	73.1	U/L	35-104
S.G.O.T (AST)	IFCC Without Pyridoxal 5 Phosphate	13.1	U/L	0-32
S.G.P.T (ALT)	IFCC Without Pyridoxal 5 Phosphate	8.4	U/L	0-35
Total Protein (Serum)	Colorimetric - Biuret Method	7.27	g/dL	6.4-8.3
Albumin, BCG	Colorimetric - Bromo-Cresol Green	3.98	g/dL	3.5-5.2
Globulin	Calculated	3.29	g/dL	1.9-3.5
Albumin/Globulin Ratio	Calculated	1.20		0.9-2
Serum Total Bilirubin	Colorimetric Diazo	0.3	mg/dL	0-1.2
Serum Direct Bilirubin	Colorimetric Diazo	0.1	mg/dL	0-0.4
Serum Indirect Bilirubin	Calculated	0.2	mg/dL	0-1

--- END OF REPORT ---

JWALA GAJBHIYE
 Verified By


 Dr. ALKA THOOL
 Consultant Pathologist
 M.B.B.S, MD

Partial reproduction of Report not permitted. This Report Relates to Sample received by Laboratory
 * B.R.I : BIOLOGICAL REFERENCE INTERVAL ** Test not in Scope of Accreditation



DEPARTMENT OF LABORATORY MEDICINE

IMMUNOLOGY

WOCKHARDT HOSPITALS


LIFE WINS
Final Report

Patient Name : MRS. RUTUJA VIJAY SARDAR
 Age / Sex : 33 Years / Female
 UHID : WHN2.0000334242
 Primary Consultant : DR. WOCKHARDT DOCTOR
 Order No. : 4151
 Bill No. : OCR3/23/0000298
 Order Date : 11/02/2023 10:04 AM
 Sample Collection : 11/02/2023 11:06 AM
 Report Date : 11/02/2023 11:55 AM
 Specimen : Serum

PARAMETER	METHOD	RESULT	UNIT	B.R.I
MEDIWHEEL FULL BODY HCU MALE AND FEMALE BELOW 40				
TOTAL T3	ECLIA	127.0	ng/dl	80-200
TOTAL T4	ECLIA	9.33	ug/dl	4.5-11.7
TSH	ECLIA	1.62	μIU/mL	0.27-4.2

--- END OF REPORT ---

JWALA GAJBHIYE
Verified By


Dr. ALKA THOOL
Consultant Pathologist
M.B.B.S, MD PATH

Partial reproduction of Report not permitted. This Report Relates to Sample received by Laboratory
 * B.R.I : BIOLOGICAL REFERENCE INTERVAL ** Test not in Scope of Accreditation



WOCKHARDT HOSPITALS, NAGPUR

1643, North Ambazari Road, Nagpur -440 010, Tel : (0712) 6624444, 6624100

Fax : (0712) 2261266 Website : www.wockhardthospitals.com

Registered Office Address :- Wockhardt Towers , BKC , Bandra (East) Mumbai 400051

CIN: U85100MH1991PLC063096

DEPARTMENT OF LABORATORY MEDICINE



CLINICAL PATHOLOGY

Patient Name	: MRS. RUTUJA VIJAY SARDAR	Order Date	: 11/02/2023 10:04 AM
Age / Sex	: 33 Years / Female	Sample Collection	: 11/02/2023 11:06 AM
UHID	: WHN2.0000334242	Report Date	: 11/02/2023 12:31 PM
Primary Consultant	: DR. WOCKHARDT DOCTOR	Specimen	: Urine
Order No.	: 4151		
Bill No.	: OCR3/23/0000298		

<u>PARAMETER</u>	<u>METHOD</u>	<u>RESULT</u>	<u>UNIT</u>	<u>B.R.I</u>
------------------	---------------	---------------	-------------	--------------

MEDIWHEEL FULL BODY HCU MALE AND FEMALE BELOW 40

Urine Routine

Physical Examination

Colour	Pale Yellow		
Appearance	Clear		
Urinalyser (Roche UriSys 1100)			
Specific Gravity	1.020		1.003 - 1.035
Reaction (pH)	5		
Leukocytes, microscopy	NIL	/hpf	
Erythrocytes, microscopy	NIL	/hpf	
Nitrite, urinalyser	Negative		
Protein, urinalyser	Negative		
Glucose, urinalyser	Negative		
Ketone, urinalyser	Negative		

--- END OF REPORT ---

JIWALA GAJBHIYE
Verified By


Dr. ALKA THOOL
Consultant Pathologist
M.B.B.S, MD PATH

Partial reproduction of Report not permitted. This Report Relates to Sample received by Laboratory
* B.R.I : BIOLOGICAL REFERENCE INTERVAL ** Test not in Scope of Accreditation



WOCKHARDT HOSPITALS, NAGPUR

1643, North Ambazari Road, Nagpur - 440 010, Tel : (0712) 6624444, 6624100

Fax : (0712) 2261266 Website : www.wockhardthospitals.com

Registered Office Address :- Wockhardt Towers , BKC , Bandra (East) Mumbai 400051

CIN: U85100MH1991PLC063096

2D ECHOCARDIOGRAPHY & DOPPLER REPORT

Name	: Mrs. Rutuja Sardar	Age / Sex	: 32 yrs / Female
Done by	: Dr. Nitin Tiwari	Date	: February 11, 2023
OPD		UHID	: 334242

Comments :

Sector echo done in plax, psax, apical 4 & 5 chambers, subcostal view shows:

Normal morphology of aortic, mitral, tricuspid and pulmonary valves.

The left atrium, left ventricle, right atrium and right ventricle are normal in dimension and morphology. There is no regional wall motion abnormality of left ventricle at rest. The left ventricular systolic function is **good**. The global left ventricular ejection fraction is 65 %.

The IAS and IVS are intact.

The pericardium is normal. There is no pericardial effusion.

There is no clot or vegetation seen.

CW, PW and Colour Doppler: Transmitral flow is suggestive of left ventricular diastolic dysfunction present. There is no evidence of pulmonary hypertension.

Impression:

Normal cardiac valves and chamber dimensions

No regional wall motion abnormality of left ventricle at rest

Good left ventricular systolic function. LVEF – 65 %

LV diastolic dysfunction present.

No pulmonary hypertension

Dr. Nitin Tiwari
MD, DNB (Med.), DM, DNB (Card.),
MNAMS, MAPSIC
Sr. Interventional Cardiologist



WOCKHARDT HOSPITALS, NAGPUR

1643, North Ambazari Road, Nagpur - 440 010. Tel : (0712) 6624444, 6624100

Fax : (0712) 2261266 Website : www.wockhardthospitals.com

Registered Office Address :- Wockhardt Towers , BKC , Bandra (East) Mumbai 400051

CIN: U85100MH1991PLC063096

Name : <i>Rutuja Sarda</i>	Age/ Sex : yrs /	Date:
----------------------------	------------------	-------

Fundus Examination
(Direct Ophthalmoscopy)

	Right	Left
Media	<i>Cu</i>	<i>Cu</i>
Optic Disc		
Colour		
Size		
Shape		
Margin		
NRR		
C:D	<i>0.3:1</i>	<i>0.3:1</i>

Blood Vessels
A:V ratio
Abnormalities

Macula
FR
Abnormalities

+ +

Periphery

(BB) full view

Impression

↓

✓ **Dr. NITIN DHOK**
9096377550
Consultant Ophthalmology

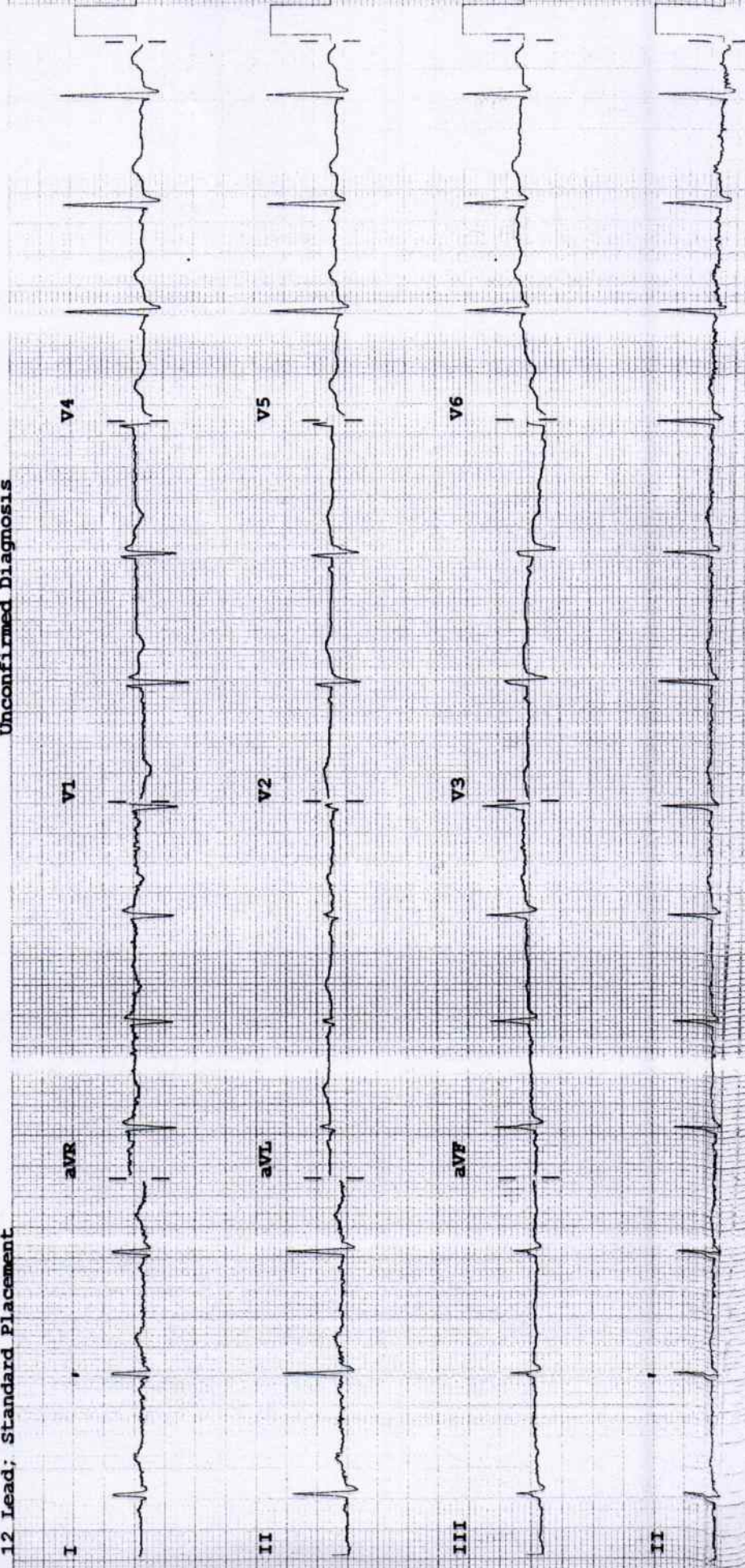


Rate 79 . Age not entered, assumed to be 50 years old for purpose of ECG interpretation
 . Sinus rhythm.....normal P axis, V-rate 50- 99
 PR 104 . Short PR interval.....PR <110ms
 QRSD 103 . RSR' in V1 or V2, right VCD or RVH.....QRS area positive & R' V1/V2
 QT 366
 QTc 420

--AXIS--
 P 13
 QRS 54
 T 25
 - - BORDERLINE ECG - -

12 Lead; Standard Placement

Unconfirmed Diagnosis



Device: Speed: 25 mm/sec Limb: 10 mm/mV Chest: 10.0 mm/mV F 60~0.15-100 Hz PH100B CL P?