



A.L.C. Advance Imaging Diagnostics

ISO 9001:2015 Certified center

(A Unit of P.K.Arogyam Health & Wellness Center)

E-95, P.C. Colony, Near Sai Netryalaya Transformer, Kankarbagh, Patna - 20

alcdiagnostics@gmail.com

www.alhealthcheckup.in

7050037694, 8271206196

OPINION Request code - bobE1187 Package code - PKG10000227 Beneficiary code - 18405 BOB E C No - 101336 LEGAL PURPOSE

Request code - bobE1187 Package code - PKG10000227 Beneficiary code - 18405 BOB E C No - 101336

Pt. Name :- UJJWAL KUMAR SINGH
Ref. By :- DR. / MEDIWHEEL

Date:- 30-May-21
Age / Sex - 26 Yrs. M.

Thanks for your kind referral

X-RAYCHEST (P.A.VIEW)

The lungs on the either side show equal translucency.

The peripheral pulmonary vasculature is normal.

No focal lung lesion is seen.

The pleural spaces are normal.

Both hila are normal in size, have equal density and bear normal relationship.

The heart and trachea are central in position and no mediastinal abnormality is visible.

The cardiac size is normal.

The domes of the diaphragms are normal in position, and show smooth outline.

IMPRESSION

- **NO EVIDENCE OF PULMONARY OR CARDIAC PATHOLOGY IS NOTED.**

Consultant Radiologist

ESTB BY:-

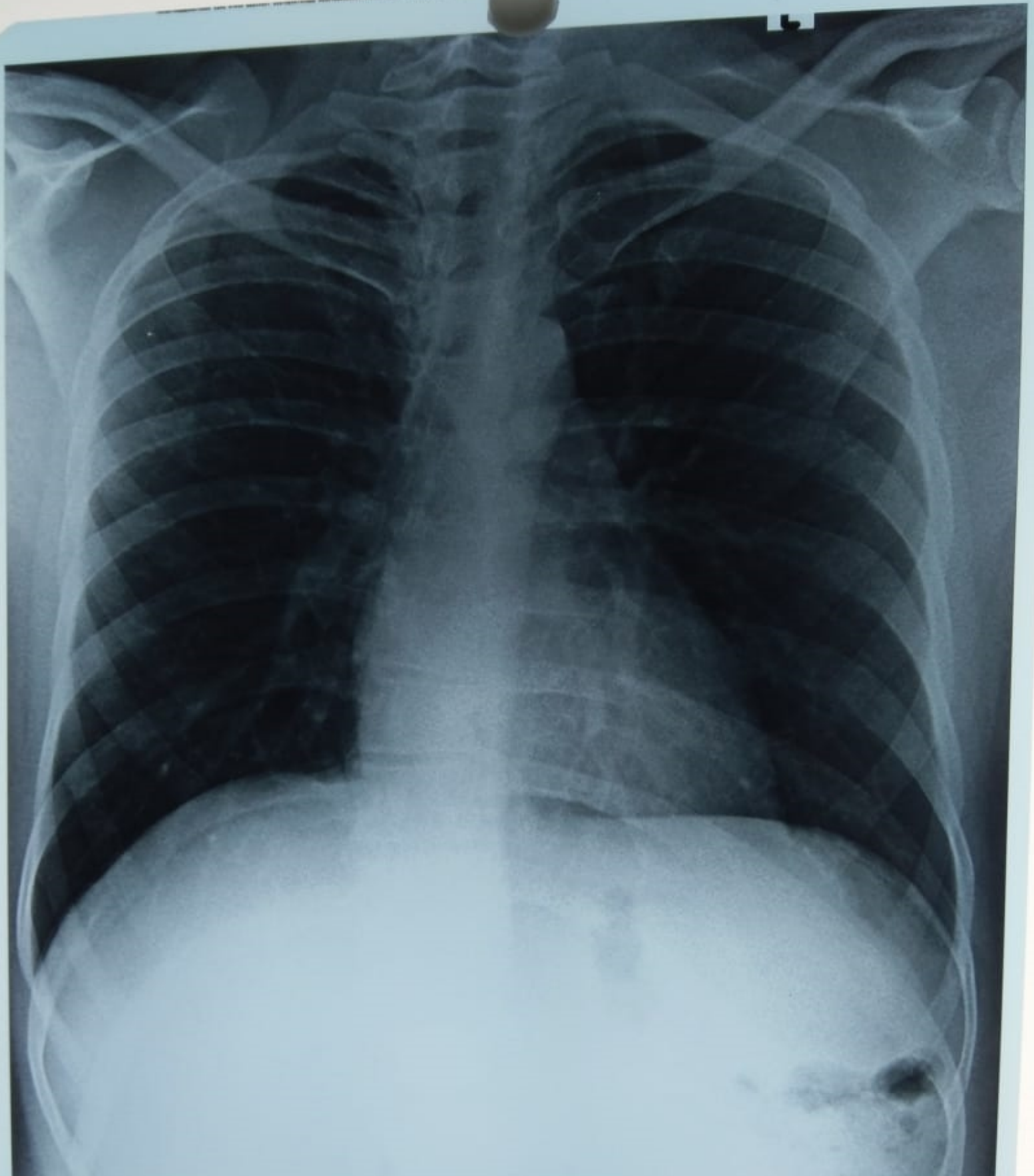
Dr. P. K. Tiwari
MD, BRIT (Radio Imaging)
Consultant Imagionologist

Dr. S. Kumar
MD (Pat)
Consultant Pathologist

Dr. Abhishek Kumar
MBBS, MD
Consultant Neuropatho Physiologist

Dr. Anjali
MBBS, MD
Consultant(TMT,EEG Specialist)

Dr. Kumari Suman
MBBS, DGO, MD
Consultant (TVS & HSG Specialist)



UJJWAL KUMAR SINGH AGE 26 YEAR 546 BY MEDIWHEEL TPA BOB CHEST,FRN P->A
A.L.C. Advance Imaging Dignostics Centre PATNA-20

ID: 521 CASE: 1 UJJWAL KUMAR SINGH 26/05/2021 13:31:36
 AGE: 26Y 05M 23D MALE ALC ADVANCE IMAGING DIAGNOSTICS
 165Cms 84Kg E95 PC COLONY KANKARBAGH PATNA

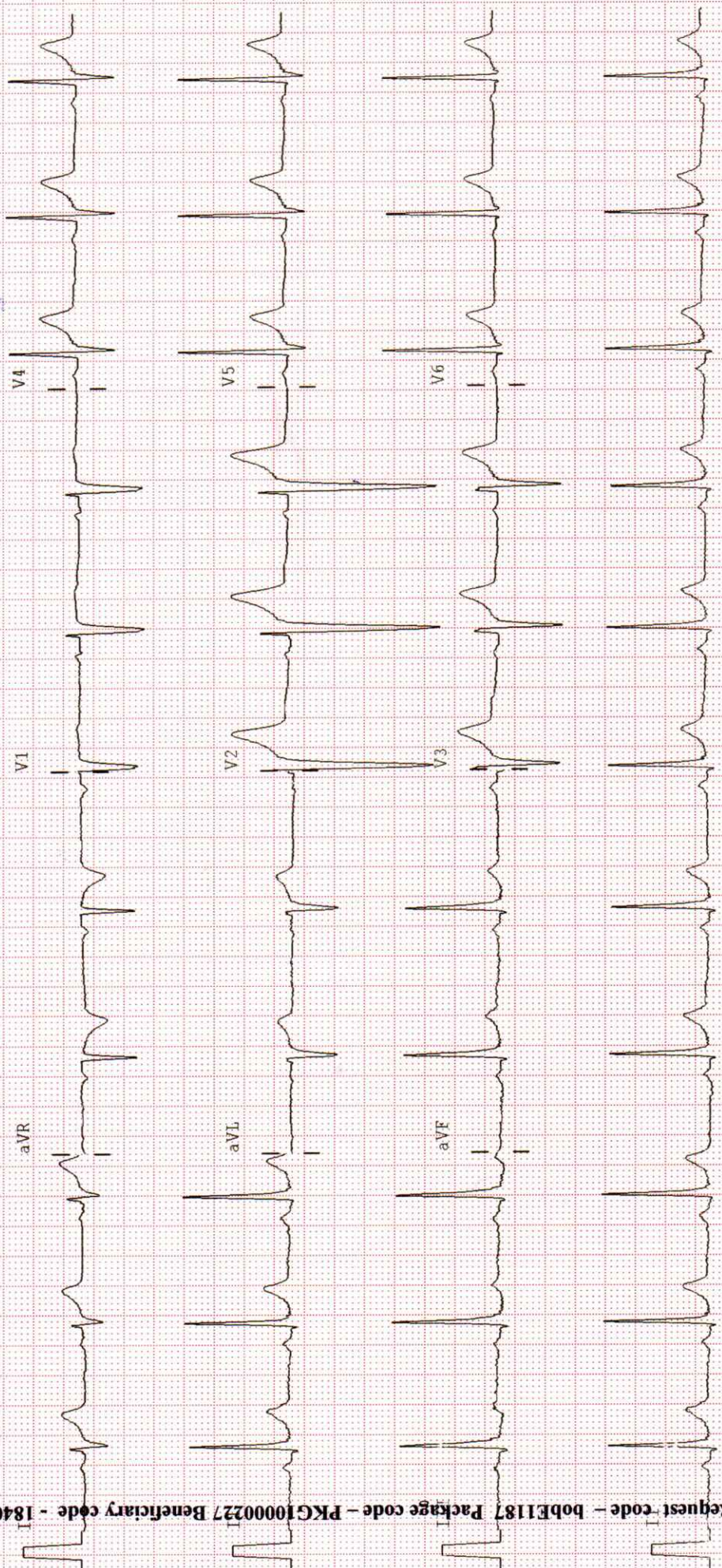


Dr. DR ABHISHEK KUMAR MBBS MD

RATE : 66 bpm SINUS RHYTHM
 R-R : 906 ms
 P-R : 152 ms
 QRS : 100 ms
 QT : 362 ms
 QTc : 373 ms
 P : 62°
 QRS : 86°
 T : 30°
 NORMAL ECG

REF: MEDIWHEEL, TPA BOB

12 LEAD REPORT FORMAT: 3x4+1L SQ



Request code - bobE1187 Package code - PKG10000227 Beneficiary code - 18405



A.L.C. Advance Imaging Diagnostics

ISO 9001:2015 Certified center

(A Unit of P.K.Arogyam Health & Wellness Center)

E-95, P.C. Colony, Near Sai Netryalaya Transformer, Kankarbagh, Patna - 20

alcdiagnostics@gmail.com

www.alhealthcheckup.in

7050037694, 8271206196

OPINION MUST BE CORRELATES WITH CLINICALLY & OTHER INVESTIGATION FOR FINAL DIAGNOSIS. NOT FOR MEDICO LEGAL PURPOSE

PATIENT NAME : Mr. UJJWAL KR SINGH PATIENT ID: 546
COL DATE : 26/05/2021 REPORTING DATE: 26/05/2021 AGE SEX:- 26 YRS/M
REF.BY : DR. / MEDIWHEEL TPA BOB.

Request code – bobE1187 Package code – PKG10000227 Beneficiary code – 18405 BOB E C No -101336

TEST NAME	RESULT	Unit	REF.RANGE
ESR	15 mm/hr		<20 mm/hr
CBC			
Total W.B.C. Count	7100 /cumm		4000-11,000 /cumm
R B C COUNT	5.4 Million/ CUmm		4-7 Million/ CUmm
Platelets count	1.66 Lakh/ cumm		1.5-5.0 Lakh/ cumm
Differential Count of W.B.C.			
Neutrophils	54 %		40-70%
Lymphocytes	31 %		25-40%
Eosinophils	04 %		01-05%
Mnonocytes	01 %		00-02%
Basophiles	00 %		00-0%
HAEMOGLOBIN	15.5 gm/dl (106.1 %)		14.6 gm/dl = 100%
PCV	45.8 %		35-47 %
MCV	83.8 fl		76-96 fl
MCH	28.3 pg		29-35 pg
MCHC	33.8 %		30-38 %



Consultant Radiologist

ESTB BY:-

Dr. P. K. Tiwari
MD, BRIT (Radio Imaging)
Consultant Imagonologist

Dr. S. Kumar
MD (Pat)
Consultant Pathologist

Dr. Abhishek Kumar
MBBS, MD
Consultant Neuropatho Physiologist

Dr. Anjali
MBBS, MD
Consultant(TMT,EEG Specialist)

Dr. Kumari Suman
MBBS, DGO, MD
Consultant (TVS & HSG Specialist)

PRINTING MISTAKE SHOULD BE REPORTED BACK IMMEDIATELY/ यहाँ जन्म से पहले भ्रुण का लिंग जाँच नहीं होता है ।



A.L.C. Advance Imaging Dignostics

ISO 9001:2015 Certified center

(A Unit of P.K.Arogyam Health & Wellness Center)

E-95, P.C. Colony, Near Sai Netryalaya Transformer, Kankarbagh, Patna - 20

alcdiagnostics@gmail.com

www.alhealthcheckup.in

7050037694, 8271206196

OPINION MUST BE CORRELATES WITH CLINICALLY & OTHER INVESTIGATION FOR FINAL DIAGNOSIS. NOT FOR MEDICO LEGAL PURPOSE

Request code – bobE1187 Package code – PKG10000227 Beneficiary code - 18405 BOB E C No -101336

PATIENT NAME : Mr. UJJWAL KR SINGH

PATIENT ID: 546

COL DATE : 26/05/2021 REPORTING DATE: 26/05/2021 AGE SEX : 26 YRS/M

REF.BY : DR. /MEDIWHEEL TPA B.O.B.

TEST NAME	RESULT	Unit	REF.RANGE
-----------	--------	------	-----------

BLOOD SUGAR (F)	91.0 mg/dl		70-110 mg/dl
-------------------	------------	--	--------------

BLOOD SUGAR (PP)	118.0 mg/dl		70-140 mg/dl
--------------------	-------------	--	--------------

LIPID PROFILE:-

TOTAL CHOLESTROL	212.4 mg/dl		130-250 mg/dl
------------------	-------------	--	---------------

TRIGLYCERIDE	181.6 mg/dl		50-160 mg/dl
--------------	-------------	--	--------------

HDL CHOLESTROL	48.0 mg/dl		30- 60 mg/dl
----------------	------------	--	--------------

LDL CHOLESTROL	128.1 mg/dl		80-130 mg/dl
----------------	-------------	--	--------------

VLDL CHOLESTROL	36.3 mg/dl		15-40 mg/dl
-----------------	------------	--	-------------

T.CH./HDL RATIO	4.4:1		
-----------------	-------	--	--

LDL./HDL RATIO	2.6:1		
----------------	-------	--	--



Consultant Radiologist

ESTB BY:-

Dr. P. K. Tiwari
MD, BRIT (Radio Imaging)
Consultant Imagonologist

Dr. S. Kumar
MD (Pat)
Consultant Pathologist

Dr. Abhishek Kumar
MBBS, MD
Consultant Neuropatho Physiologist

Dr. Anjali
MBBS, MD
Consultant(TMT,EEG Specialist)

Dr. Kumari Suman
MBBS, DGO, MD
Consultant (TVS & HSG Specialist)

PRINTING MISTAKE SHOULD BE REPORTED BACK IMMEDIATELY/ यहाँ जन्म से पहले भ्रुण का लिंग जाँच नहीं होता है ।



A.L.C. Advance Imaging Diagnostics

ISO 9001:2015 Certified center

(A Unit of P.K.Arogyam Health & Wellness Center)

E-95, P.C. Colony, Near Sai Netryalaya Transformer, Kankarbagh, Patna - 20

alcdiagnostics@gmail.com

www.alchealthcheckup.in

7050037694, 8271206196

OPINION MUST BE CORRELATES WITH CLINICALLY & OTHER INVESTIGATION FOR FINAL DIAGNOSIS. NOT FOR MEDICO LEGAL PURPOSE

Request code – bobE1187 Package code – PKG10000227 Beneficiary code - 18405 BOB E C No -101336

PATIENT NAME : Mr. UJJWAL KR SINGH

PATIENT ID: 546

COL DATE : 26/05/2021 REPORTING DATE: 26/05/2021 AGE SEX : 26 YRS/M

REF.BY : DR./ MEDIWHEEL TPA. B.O.B.

Investigation	Result	Normal Range
Total Triiodothyronin T3	129.2 μ ng/dl	70 -200 μ ng/dl
Total Thyroxin T4	7.23 μ ug/dl	4.8 -13.5 μ ug/dl
Serum TSH	2.101 μ U/ml	0.39 -6.16 μ U/ml

THYROID DISORDER (>: Increase: < Decrease: n Normal

1. T3(n) T4(n) TSH(n) :EUTHYROID STATE:
2. T3(>) T4(>) TSH(<): HYPERTHYROIDISM:
3. T3(<)T4(<) TSH(>): HYPOTHYROIDISM:
4. T3(n)T4(n) TSH(>) : SUB-CLINICAL HYPO-THYROIDISM:
5. T3(n)T4(n) TSH(<): SUB-CLINICAL HYPER-THYROIDISM:
6. T3(>) T4(n) TSH(<): T3 THYROTOXICOSIS:

Total T3/T4 level is dependent on Level:

So determination of free T3/T4is a better MARKER of Thyroid Function.

*FREE T3/T4 ESTIMATION FACILITY IS AVAILABALE ON REQUEST.:



Consultant Radiologist

ESTB BY:-

Dr. P. K. Tiwari
MD, BRIT (Radio Imaging)
Consultant Imagionologist

Dr. S. Kumar
MD (Pat)
Consultant Pathologist

Dr. Abhishek Kumar
MBBS, MD
Consultant Neuropatho Physiologist

Dr. Anjali
MBBS, MD
Consultant(TMT,EEG Specialist)

Dr. Kumari Suman
MBBS, DGO, MD
Consultant (TVS & HSG Specialist)



A.L.C. Advance Imaging Dignostics

ISO 9001:2015 Certified center

(A Unit of P.K.Arogyam Health & Wellness Center)

E-95, P.C. Colony, Near Sai Netryalaya Transformer, Kankarbagh, Patna - 20

alcdiagnostics@gmail.com

www.alhealthcheckup.in

7050037694, 8271206196

OPINION MUST BE CORRELATES WITH CLINICALLY & OTHER INVESTIGATION FOR FINAL DIAGNOSIS. NOT FOR MEDICO LEGAL PURPOSE

PATIENT NAME : Mr. UJJWAL KR SINGH

PATIENT ID: 546

COL DATE : 26/05/2021 REPORTING DATE: 26/05/2021 AGE SEX:- 26 YRS/M

REF.BY : DR / MEDIWHEAL TPA B.O.B.

Request code - bobE1187 Package code - PKG10000227 Beneficiary code - 18405 BOB E C No -101336

TEST NAME RESULT Unit REF.RANGE

LFT:-

GGT	22.0 IU/L	8 - 38 IU/L
SGPT	38.1 IU/L	5 - 40 IU/L
S G O T	44.0 IU/L	5 - 40 IU/L
ALKALINE PHOSPHATASE	91.7 IU/L	25-147 IU/L
SERUM ALBUMIN	4.7 g/dl	3.5 --5.4 g/dl
SERIUM GLUBLINE	2.9 g/dl	2.3 -- 3.6 g/dl
A/G RATIO	1.6 : 1	1.0—2.3 g/dl

BILIRUBIN

TOTAL	0.8 mg/dl	0.1- 1.0mg/dl
DIRECT	0.3 mg/dl	0.0- 0.3mg/dl
INDIRECT	0.5 mg/dl	0.0- 0.7 mg/dl

KFT/RFT

URIC ACID	6.1 mg/dl	3.2—7.0 mg/dl
TOTAL PROTIN	7.6 g/dl	6.0--8.7 g/dl
SERUM CREATNINE	0.8 mg/dl	0.6-1.5 mg/dl
BLOOD UREA	33.6 mg/dl	5 - 45 mg/dl
BLOOD URIA NITROZEN(BUN).	15.6 mg/dl	13- 39 mg/dl
BUN/CREATININE RATIO	19.5:1	



ESTB BY:-

Consultant Radiologist

Dr. P. K. Tiwari
MD, BRIT (Radio Imaging)
Consultant Imagionologist

Dr. S. Kumar
MD (Pat)
Consultant Pathologist

Dr. Abhishek Kumar
MBBS, MD
Consultant Neuropatho Physiologist

Dr. Anjali
MBBS, MD
Consultant(TMT,EEG Specialist)

Dr. Kumari Suman
MBBS, DGO, MD
Consultant (TVS & HSG Specialist)



A.L.C. Advance Imaging Diagnostics

ISO 9001:2015 Certified center

(A Unit of P.K.Arogyam Health & Wellness Center)

E-95, P.C. Colony, Near Sai Netryalaya Transformer, Kankarbagh, Patna - 20

alcdiagnostics@gmail.com

www.alchealthcheckup.in

7050037694, 8271206196

OPINION MUST BE CORRELATES WITH CLINICALLY & OTHER INVESTIGATION FOR FINAL DIAGNOSIS. NOT FOR MEDICO LEGAL PURPOSE

PATIENT NAME : Mr . UJJWAL KUMAR SINGH PATIENT ID: 546

COL DATE : 26/05/2021 REPORTING DATE: 26/05/2021 AGE SEX:- 26 YRS/M

REF.BY : DR./MEDIWHEEL TPA B.O.B.

Request code – bobE1187 Package code – PKG1000227 Beneficiary code - 18405 BOB E C No -101336

Request code – bobE1187 Package code – PKG1000227 Beneficiary code – 18405 BOB E C No –101336

ROUTINE EXAMINATION OF URINE

PHYSICAL EXAMINATION

Volume 30 ml

Colour Straw

Appearance Clear

Sediments Nil

Specific Gravity 1.020

CHEMICAL EXAMINATION

PH 5.0

Reaction ACIDIC

Sugar NIL

Albumin NIL

Phosphate.... Nil

Nitrite Not done

MICROSCOPIC EXAMINATION

Erythrocytes.... Nil

Pus cells 1-3 / HPE

Epithelial Cells A, Few

Other Nil

ESTB BY:-

Consultant Radiologist

Dr. P. K. Tiwari

MD, BRIT (Radio Imaging)
Consultant Imagionologist

Dr. S. Kumar

MD (Pat)
Consultant Pathologist

Dr. Abhishek Kumar

MBBS, MD
Consultant Neuropatho Physiologist

Dr. Anjali

MBBS, MD
Consultant(TMT,EEG Specialist)

Dr. Kumari Suman

MBBS, DGO, MD
Consultant (TVS & HSG Specialist)




 बैंक ऑफ़ बड़ोदा
Bank of Baroda



नाम
Name UJJWAL KUMAR SINGH

कर्मचारी कूट क.
E.C. NO. 101336


जारीकर्ता प्राधिकारी
Issuing Authority



धारक के हस्ताक्षर
Signature of Holder



भारत सरकार
Government of India



उज्जवल कुमार सिंह
Ujjwal Kumar Singh
जन्म तिथि/DOB: 05/02/1995
पुरुष/ MALE

8316 2599 5885
VID: 9127 6426 3657 5570



मेरा आधार, मेरी पहचान

Ujjwal
26/5/21



भारतीय विशिष्ट चिह्न प्राधिकरण
Unique Identification Authority of India

आधार कार्ड: विशिष्ट चिह्न प्रमाण, भारत = 38 ए अक्षांश कोक्षात्
 यहाँ प्रदर्शित है: विशिष्ट चिह्न प्रमाण, भारत, गुजरात।
 पिन कोड - 800023

Address:
 S/O: Ritesh Kumar Singh, house no 38 A
 adarsh colony panch mukhi chaur near
 Bandh, west Patel nagar, Phulwari, Patna,
 Bihar - 800023

8316 2599 5885
 VID: 9127 6426 3657 5570

QR Code with Photograph

पिछो-पु, सुरक्षा के लिए
सुरक्षा प्रशासन (गृह)
 के लिए वापस, कृपया वापस करें - 400 051, गुजरात
 को 91 22 6698 5196 फोन करें 91 22 2652 5747

If found, please return to
 Asst. General Manager (Security)
 Bank of Baroda, Baroda Corporate Centre
 C-26, G-Block, Bandra-Kurla Complex, Mumbai-400 051, India
 Phone 91 22 6698 5196 Fax 91 22 2652 5747

यदि खोए / Blood Group O+
 वापस करें / Identification Marks A MOLE ON FACE LEFT SIDE



A.L.C. Advance Imaging Dignostics

ISO 9001:2015 Certified center

(A Unit of P.K.Arogyam Health & Wellness Center)

E-95, P.C. Colony, Near Sai Netryalaya Transformer, Kankarbagh, Patna - 20

alcdiagnostics@gmail.com

www.alhealthcheckup.in

7050037694, 8271206196

OPINION MUST BE CORRELATES WITH CLINICALLY & OTHER INVESTIGATION FOR FINAL DIAGNOSIS. NOT FOR MEDICO LEGAL PURPOSE

Request code – bobE1187 Package code – PKG10000227 Beneficiary code - 18405 BOB E C No -101336

PATIENT NAME : Mr. UJJWAL KUMAR SINGH PATIENT ID: 546
COL DATE : 26/05/2021 REPORTING DATE: 26/05/2021 AGE SEX : 26 YRS/M
REF.BY : DR. / MEDIWHEEL TPA B.O.B.

GLYCOSYLATED HEMOGLOBIN

TEST NAME	RESULT	Unit	REF.RANGE
HbA1c	3.7 %		Below 5.7 % : Normal 5.7 – 6.4 % : Prediabetic > = 6.5 % : Diabetic
AVERAGE PLASMA GLUCOSE	100.0 mg/dl		90 – 120 mg/dl : Good Control 121– 150 mg/dl : Fair Control 151- 180 mg/dl: Unsatisfactory Control >180 mg/dl : Poor Control

BLOOD GROUP : 'O'
Rh Typing : POSITIVE

Note: Do always cross – matching before blood transfusion

ESTB BY:-

Dr. P. K. Tiwari
MD, BRIT (Radio Imaging)
Consultant Imagionologist

Dr. S. Kumar
MD (Pat)
Consultant Pathologist

Dr. Abhishek Kumar
MBBS, MD
Consultant Neuropatho Physiologist

Dr. Anjali
MBBS, MD
Consultant(TMT,EEG Specialist)

Dr. Kumari Suman
MBBS, DGO, MD
Consultant (TVS & HSG Specialist)



Consultant Radiologist



A.L.C. Advance Imaging Diagnostics

ISO 9001:2015 Certified center

(A Unit of P.K.Arogyam Health & Wellness Center)

E-95, P.C. Colony, Near Sai Netryalaya Transformer, Kankarbagh, Patna - 20

alcdiagnostics@gmail.com

www.alhealthcheckup.in

7050037694, 8271206196

OPINION MUST BE CORRELATES WITH CLINICALLY & OTHER INVESTIGATION FOR FINAL DIAGNOSIS. NOT FOR MEDICO LEGAL PURPOSE

Request code – bobE1187 Package code – PKG10000227 Beneficiary code - 18405 BOB E C No -101336

Pt. Name :- **UJJAWAL KUMAR SINGH**

Date:- **26-5-2021**

Ref. By :- **DR. MEDI WHEEL**

Age / Sex – **26 Yrs. M.**

REAL TIME U.S.G. OF WHOLE ABDOMEN

Thanks for your kind referral

(Report.)

LIVER :- Measures 16.25 cm. Mild Enlarged in shape , size and echo texture fatty change seen in liver parenchyma .I.H.B.R. are not dilated.

Hepatic veins are normal. No SOL seen.

G.BL. :- Lumen is echo free. Wall thickness appears normal.

C.B.D. :- Measures 3.5 mm in diameter with echo free lumen. No calculi or mass seen.

P.V. :- Measures 7.7 mm in diameter. Appears normal. No thrombus seen.

PANCREAS :- Normal in shape, size and echo texture. No calcification mass seen.

SPLEEN :- Measures 11.56 cm. Normal in shape, size and echo texture.
No SOL seen.

KIDNEY :- Both kidney shows normal shape, size & echotexture. C.M.D.intact.
P.C.S.is not dilated.

Right Kidney :- Measures 10.70 X 3.50 cm.

Left Kidney :- Measures 10.60 X 3.50 cm.

URETER :- Not dilated .No apparent calculi seen.

U.BLADDER:- Shows normal in outline with echo free lumen. No calculi or mass seen.

Pre void – 320 ml. Post void – is in significant

PROSTATE :- Measures 18 gms.(approx). Appears Normal in size, shape, and echo texture.
No calcification , mass ,growth seen. capsule is intact.

R.I.F. :- Son graphically no appendicular mass or collection seen.

OTHERS :-No Ascites . no Lymph Adenopathy. No pleural effusion seen on either side .

IMPRESSION

- **Mild Hepatomegaly With fatty liver G-I**
- **Adv:- Further work up other investigation**
Otherwise son graphically normal scan. of rest organs



ESTB BY:-

Consultant Radiologist

Dr. P. K. Tiwari
MD, BRIT (Radio Imaging)
Consultant Imagonologist

Dr. S. Kumar
MD (Pat)
Consultant Pathologist

Dr. Abhishek Kumar
MBBS, MD
Consultant Neuropatho Physiologist

Dr. Anjali
MBBS, MD
Consultant(TMT,EEG Specialist)

Dr. Kumari Suman
MBBS, DGO, MD
Consultant (TVS & HSG Specialist)

FUJI PRINTER

P K Arogyam ALC Advance Ujjawal kumar singh 26 y , DR / MI MI 0.7
26/05/21 01:37:45 PM ADM 546

Tis 0.1 4C
Abdomen

1 L 16.25 cm
d 18.21 cm
L 0.00 cm

LIVER RT LOBE LT LOBE

B CH1
Frq 4.0 MHz
Gn 82
E/A 1/2
Map DI00
D 28.0 cm
DR 72
FR 13 Hz
AO 100 %

P K Arogyam ALC Advance Ujjawal kumar singh 26 y , DR / MI MI 0.7
26/05/21 01:38:08 PM ADM 546

Tis 0.1 4C
Abdomen

GB CBD PV

B CH1
Frq 4.0 MHz
Gn 82
E/A 1/2
Map DI00
D 28.0 cm
DR 72
FR 13 Hz
AO 100 %

P K Arogyam ALC Advance Ujjawal kumar singh 26 y , DR / MI MI 0.7
26/05/21 01:38:41 PM ADM 546

Tis 0.1 4C
Abdomen

1 L 11.56 cm

PANCREAS SPLEEN

B CH1
Frq 4.0 MHz
Gn 82
E/A 1/2
Map DI00
D 28.0 cm
DR 72
FR 13 Hz
AO 100 %

P K Arogyam ALC Advance Ujjawal kumar singh 26 y , DR / MI MI 0.7
26/05/21 01:39:09 PM ADM 546

Tis 0.1 4C
Abdomen

1 L 10.74 cm
2 L 10.82 cm

RT KID LT KID

B CH1
Frq 4.0 MHz
Gn 82
E/A 1/2
Map DI00
D 28.0 cm
DR 72
FR 13 Hz
AO 100 %

P K Arogyam ALC Advance Ujjawal kumar singh 26 y , DR / MI MI 0.7
26/05/21 01:39:36 PM ADM 546

Tis 0.1 4C
Abdomen

UBL UBL

B CH1
Frq 4.0 MHz
Gn 82
E/A 1/2
Map DI00
D 28.0 cm
DR 72
FR 13 Hz
AO 100 %

P K Arogyam ALC Advance Ujjawal kumar singh 26 y , DR / MI MI 0.7
26/05/21 01:39:51 PM ADM 546

Tis 0.1 4C
Abdomen

RIF LIF

B CH1
Frq 4.0 MHz
Gn 82
E/A 1/2
Map DI00
D 28.0 cm
DR 72
FR 13 Hz
AO 100 %