



A.L.C. Advance Imaging Dignostics

ISO 9001:2015 Certified center

(A Unit of Subham Imaging P.K. Arogyam Health & Wellness Center)

E-95, P.C. Colony, Near Sai Netryalaya Transformer, Kankarbagh, Patna - 20

alcdiagnostics@gmail.com

www.pkarogyamhealthcheckup.com

7050037694, 8271206196

OPINION MUST BE CORRELATES WITH CLINICALLY & OTHER INVESTIGATION FOR FINAL DIAGNOSIS. NOT FOR MEDICO LEGAL PURPOSE

PATIENT NAME : Mrs. SUSHMITA

PATIENT ID: 2640

COL DATE : 10/12/2022 REPORTING DATE: 10/12/2022 AGE SEX : 33 YRS/F

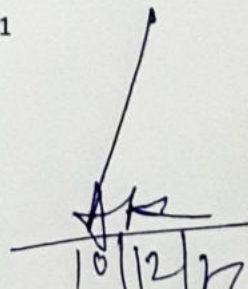
REF.BY : DR. /MEDIWHEEL.

TEST NAME	RESULT	Unit	REF.RANGE
BLOOD SUGAR (F)	76.0 mg/dl		70 - 110 mg/dl

LIPID PROFILE:-

TOTAL CHOLESTROL	199.0 mg/dl		130 -250 mg/dl
TRIGLYCERIDE	124.0 mg/dl		50 -160 mg/dl
HDL CHOLESTROL	47.0 mg/dl		30 - 60 mg/dl
LDL CHOLESTROL	127.2 mg/dl		80 -130 mg/dl
VLDL CHOLESTROL	24.8 mg/dl		15 - 40 mg/dl
T.CH./HDL RATIO	4.2 : 1		Upto 5:1
LDL./HDL RATIO	2.7 : 1		2 - 4:1




10/12/22
Consultant Radiologist

ESTB BY:-

Dr. P. K. Tiwari
MD, M.Sc (Radio Imaging)
Ph.D (Alt Nuclear Medicine)
Consultant Imagiologist & Sonologist

Dr. S. Kumar
MD (Pat)
Consultant Pathologist

Dr. Abhishek Kumar
MBBS, MD
Consultant Neuropathology Physiologist

Dr. Kumari Suman
MBBS, DGO, MD
Consultant (TVS & HSG Specialist)

Dr. A. K. Singh
MBBS, PGDMCH
Consultant Radiologist & Sonologist

PRINTING MISTAKE SHOULD BE REPORTED BACK IMMEDIATELY/ यहाँ जन्म से पहले भ्रुण का लिंग जाँच नहीं होता है ।



A.L.C. Advance Imaging Dignostics

ISO 9001:2015 Certified center

(A Unit of Subham Imaging P.K. Arogyam Health & Wellness Center)

E-95, P.C. Colony, Near Sai Netryalaya Transformer, Kankarbagh, Patna - 20

alcdiagnostics@gmail.com

www.pkarogyamhealthcheckup.com

7050037694, 8271206196

OPINION MUST BE CORRELATES WITH CLINICALLY & OTHER INVESTIGATION FOR FINAL DIAGNOSIS. NOT FOR MEDICO LEGAL PURPOSE

PATIENT NAME : Mrs. SUSHMITA

PATIENT ID: 2640

COL DATE : 10/12/2022 REPORTING DATE: 10/12/2022 AGE SEX:- 33 YRS/F

REF.BY : DR./ MEDIWHEEL..

TEST NAME	RESULT	Unit	REF.RANGE
LFT:-			
SGPT	22.3	IU/L	5 - 48 IU/L
SGOT	33.4	IU/L	5 - 40 IU/L
ALKALINE PHOSPHATASE	77.6	IU/L	25 - 147 IU/L
TOTAL PROTIN	7.5	g/dl	6.0 - 8.7 g/dl
SERUM ALBUMIN	4.6	g/dl	3.5 - 5.4 g/dl
SERIUM GLUBLINE	2.9	g/dl	2.3 - 3.6 g/dl
AG RATIO	1.5 : 1		1.0 - 2.3 g/dl
BILIRUBIN			
TOTAL	0.51	mg/dl	0.1 - 1.1 mg/dl
IRECT	0.20	mg/dl	0.0 - 0.32 mg/dl
INDIRECT	0.31	mg/dl	0.0 - 0.78 mg/dl
GGTP (GGT)	19.1	iu/L	8 - 38 iu/L
KFT/RFT			
URIC ACID	3.9	mg/dl	3.2 - 7.0 mg/dl
SERUM CREATNINE	0.7	mg/dl	0.6 - 1.5 mg/dl
BLOOD URIA	28.5	mg/dl	5 - 45 mg/dl
BLOOD URIA NITROZEN(BUN).	13.3	mg/dl	5 - 24 mg/dl



AK
10/12/22

Consultant Radiologist

ESTB BY:-

Dr. P. K. Tiwari
MD, M.Sc (Radio Imaging)
Ph.D (All Nuclear Medicine)
Consultant Imaginologist & Sonologist

Dr. S. Kumar
MD (Pat)
Consultant Pathologist

Dr. Abhishek Kumar
MBBS, MD
Consultant Neuropatho Physiologist

Dr. Kumari Suman
MBBS, DGO, MD
Consultant (TVS & HSG Specialist)

Dr. A. K. Singh
MBBS, PGDMCH
Consultant Radiologist & Sonologist

PRINTING MISTAKE SHOULD BE REPORTED BACK IMMEDIATELY/ यहाँ जन्म से पहले भ्रूण का लिंग जाँच नहीं होता है ।



A.L.C. Advance Imaging Dignostics

ISO 9001:2015 Certified center

(A Unit of Subham Imaging P.K. Arogyam Health & Wellness Center)

E-95, P.C. Colony, Near Sai Netryalaya Transformer, Kankarbagh, Patna - 20

alcdiagnostics@gmail.com

www.pkarogayamhealthcheckup.com

7050037694, 8271206196

OPINION MUST BE CORRELATES WITH CLINICALLY & OTHER INVESTIGATION FOR FINAL DIAGNOSIS. NOT FOR MEDICO LEGAL PURPOSE

PATIENT NAME : Mrs. SUSHMITA

PATIENT ID: 2640

COL DATE : 10/12/2022 REPORTING DATE: 10/12/2022 AGE SEX:- 33 YRS/F

REF.BY : DR. / MEDIWHEEL.

TEST NAME	RESULT	Unit	REF.RANGE
ESR	15 mm/hr		<20 mm/hr
CBC			
Total W.B.C. Count	5,700 /cumm		4000 -11,000 /cumm
R B C COUNT	4.23 Million/ CUmm		4 - 7 Million/ CUmm
Platelets count	1.97 Lakh/ cumm		1.5-5.0 Lakh/ cumm
Differential Count of W.B.C.			
Neutrophils	70 %		40-70%
Lymphocytes	25 %		25-40%
Eosinophils	04 %		01-05%
Mnonocytes	01 %		00-02%
Basophiles	00 %		00-0%
HAEMOGLOBIN	13.6 gm/dl (93.1 %)		14.6 gm/dl = 100%
PCV	39.7 %		35-47 %
MCV	93.8 fl		76-96 fl
MCH	32.2 pg		29-35 pg
MCHC	34.3 %		30-38 %

ESTB BY:-

Dr. P. K. Tiwari
MD, M.Sc (Radio Imaging)
Ph.D (Ab Nuclear Medicine)
Consultant Imagionologist & Sonologist

Dr. S. Kumar
MD (Pat)
Consultant Pathologist

Dr. Abhishek Kumar
MBBS, MD
Consultant Neuropatho Physiologist

Dr. Kamari Suman
MBBS, DGO, MD
Consultant (TVS & HSG Specialist)

Dr. A. K. Singh
MBBS, PGDMCH
Consultant Radiologist & Sonologist



Consultant Radiologist

AS
10/12/22

PRINTING MISTAKE SHOULD BE REPORTED BACK IMMEDIATELY/ यहाँ जन्म से पहले भ्रुण का लिंग जाँच नहीं होता है ।



A.L.C. Advance Imaging Diagnostics

ISO 9001:2015 Certified center

(A Unit of Subham Imaging P.K. Arogyam Health & Wellness Center)

E-95, P.C. Colony, Near Sai Netryalaya Transformer, Kankarbagh, Patna - 20

alcdiagnostics@gmail.com

www.pkarogyamhealthcheckup.com

7050037694, 8271206196

OPINION MUST BE CORRELATES WITH CLINICALLY & OTHER INVESTIGATION FOR FINAL DIAGNOSIS. NOT FOR MEDICO LEGAL PURPOSE

PATIENT NAME : Mrs. SHUSHMITA PATIENT ID: 2640
COL DATE : 10/12/2022 REPORTING DATE: 10/12/2022 AGE SEX : 33 YRS/F
REF.BY : DR./ MEDIWHEEL.

GLYCOSYLATED HEMOGLOBIN

TEST NAME	RESULT	Unit	REF.RANGE
HbA1c	3.4 %		Below 5.7 % : Normal 5.7 – 6.4 % : Prediabetic > = 6.5 % : Diabetic
AVERAGE PLASMA GLUCOSE	89.0 mg/dl		90 – 120 mg/dl : Good Control 121 – 150 mg/dl : Fair Control 151- 180 mg/dl: Unsatisfactory Control >180 mg/dl : Poor Control

ESTB BY:-

Dr. P. K. Tiwari

MD, M.Sc (Radio Imaging)

Ph.D (Alt Nuclear Medicine)

Consultant Imigionologist & Sonologist

Dr. S. Kumar

MD (Pat)

Consultant Pathologist

Dr. Abhishek Kumar

MBBS, MD

Consultant Neuropatho Physiologist

Dr. Kumari Suman

MBBS, DGO, MD

Consultant (TVS & HSG Specialist)

Consultant Radiologist

Dr. A. K. Singh

MBBS, PGDMCH

Consultant Radiologist & Sonologist



PRINTING MISTAKE SHOULD BE REPORTED BACK IMMEDIATELY/यहाँ जन्म से पहले भ्रुण का लिंग जाँच नहीं होता है ।



A.L.C. Advance Imaging Diagnostics

ISO 9001:2015 Certified center

(A Unit of Subham Imaging P.K. Arogyam Health & Wellness Center)

E-95, P.C. Colony, Near Sai Netryalaya Transformer, Kankarbagh, Patna - 20

alcdiagnostics@gmail.com

www.pkarogyamhealthcheckup.com

7050037694 8271206196

OPINION MUST BE CORRELATES WITH CLINICALLY & OTHER INVESTIGATION FOR FINAL DIAGNOSIS. NOT FOR MEDICO LEGAL PURPOSE

PATIENT NAME : Mrs. SUSHMITA PATIENT ID: 2640
COL DATE : 10/12/2022 REPORTING DATE: 10/12/2022 AGE SEX : 33 YRS/F
REF.BY : DR. / MEDIWHEEL..

TEST NAME	RESULT	Unit	REF.RANGE
Total Triiodothyronin T3	1.31	ng/mL	0.80 -2.00 ng/mL
Total Thyroxin T4	8.74	µg/dL	5.10 -14.10 µg/dL
Serum TSH	2.40	µIU/mL	0.27 - 4.20 µIU/mL

THYROID DISORDER (>: Increase: < Decrease: n Normal

1. T3(n) T4(n) TSH(n) :EUTHYROID STATE:
2. T3(>) T4(>) TSH(<): HYPERTHYROIDISM:
3. T3(<)T4(<) TSH(>): HYPOTHYROIDISM:
4. T3(n)T4(n) TSH(>) : SUB-CLINICAL HYPO-THYROIDISM:
5. T3(n)T4(n) TSH(<): SUB-CLINICAL HYPER-THYROIDISM:
6. T3(>) T4(n) TSH(<): T3 THYROTOXICOSIS:

Total T3/T4 level is dependent on Level:

So determination of free T3/T4is a better MARKER of Thyroid Function.

ESTB BY:-

Dr. P. K. Tiwari
MD, M.Sc (Radio Imaging)
Ph.D (Ab Nuclear Medicine)
Consultant Imaginologist & Sonologist

Dr. S. Kumar
MD (Pat)
Consultant Pathologist

Dr. Abhishek Kumar
MBBS, MD
Consultant Neuropatho Physiologist

Dr. K. Suman
MBBS, D.O., MD
Consultant (TVS & HSG Specialist)

Dr. A. K. Singh
MBBS, PGDARCH
Consultant Radiologist & Sonologist



10/12/22

Consultant Radiologist

PRINTING MISTAKE SHOULD BE REPORTED BACK IMMEDIATELY/ यहाँ जन्म से पहले भ्रूण का लिंग जाँच नहीं होता है ।



A.L.C. Advance Imaging Dignostics

ISO 9001:2015 Certified center

(A Unit of Subham Imaging P.K. Arogyam Health & Wellness Center)

E-95, P.C. Colony, Near Sai Netryalaya Transformer, Kankarbagh, Patna - 20

alcdiagnostics@gmail.com

www.pkarogyamhealthcheckup.com

7050037694, 8271206196

OPINION MUST BE CORRELATES WITH CLINICALLY & OTHER INVESTIGATION FOR FINAL DIAGNOSIS. NOT FOR MEDICO LEGAL PURPOSE

PATIENT NAME : Mrs.SUSHMIT A PATIENT ID: 2640
 COL DATE : 10/12/2022 REPORTING DATE: 10/12/2022 AGE SEX:- 33 YRS/F
 REF.BY : DR. / MEDIWHEEL.

TEST NAME	RESULT	Unit	REF.RANGE
-----------	--------	------	-----------

BLOOD GROUP	: ' B '		
Rh Typing	: POSITIVE		

Note: Do always cross – matching before blood transfusion



10/12/22
Consultant Radiologist

ESTB BY:-
Dr. P. K. Tiwari MD, M.Sc (Radio Imaging) Ph.D (AI) Nuclear Medicine Consultant Imagonologist & Sonologist
Dr. S. Kumar MD (Pat) Consultant Pathologist
Dr. Abhishek Kumar MBBS, MD Consultant Neuropatho Physiologist
Dr. Kumari Suman MBBS, DGO, MD Consultant (TVS & HSG Specialist)
Dr. A. K. Singh MBBS, PGDMCH Consultant Radiologist & Sonologist

PRINTING MISTAKE SHOULD BE REPORTED BACK IMMEDIATELY/ यहाँ जन्म से पहले भुण का लिंग जाँच नहीं होता है ।



A.L.C. Advance Imaging Dignostics

ISO 9001:2015 Certified center

(A Unit of Subham Imaging P.K. Arogyam Health & Wellness Center)

E-95, P.C. Colony, Near Sai Netryalaya Transformer, Kankarbagh, Patna - 20

alcdiagnostics@gmail.com

www.pkrogyamhealthcheckup.com

7050037694, 8271206196

OPINION MUST BE CORRELATES WITH CLINICALLY & OTHER INVESTIGATION FOR FINAL DIAGNOSIS. NOT FOR MEDICO LEGAL PURPOSE

PATIENT NAME : Mrs .SUSHMITA

PATIENT ID: 2640

COL DATE : 10/12/2022 REPORTING DATE: 10/12/2022 AGE SEX:- 33 YRS/F

REF.BY : DR. /MEDIWHEEL.

ROUTINE EXAMINATION OF URINE

PHYSICAL EXAMINATION

Quantity	20 ml	Colour... .	Straw
Appearance...	Clear	Sediment ...	Nil
Specific gravity....	1.010		

CHEMICAL EXAMINATION

Reaction	6.0	Nitrite.....	Not done
Sugar	Nil	Bile Pigment	Not done
Albumin	Nil	Urobilinogen....	Not done
Excess of Phosphate....	Nil	Chile.....	Not done
Bile Salt	Not Done	Acetone...	Not done

MICROSCOPIC EXAMINATION

Erythrocytes....	Nil	Casts	Nil
Leucocytes	1-3 / HPE	Crystals....	Nil
Epith. Cell	A, Few	Others	Nil

AR
10/12/22

Consultant Radiologist

ESTB BY:-

Dr. P. K. Tiwari
MD, M.Sc (Radio Imaging)
Ph.D (Ali Nuclear Medicine)
Consultant Imagnonologist & Sonologist

Dr. S. Kumar
MD (Pat)
Consultant Pathologist

Dr. Abhishek Kumar
MBBS, MD
Consultant Neuropatho Physiologist

Dr. K. Suman
MBBS, MD
Consultant (TVS & HSG Specialist)

Dr. A. K. Singh
MBBS, PGDMCH
Consultant Radiologist & Sonologist



PRINTING MISTAKE SHOULD BE REPORTED BACK IMMEDIATELY/ यहाँ जन्म से पहले भुण का लिंग जाँच नहीं होता है ।

TD: 2640 CASE:
AGE: 33Y 0M 0D
Cms K9

SUSHMITA
FEMALE

10/12/2022 10:50:02
ALC ADVANCE IMAGING DIAGNOSTICS
E95 PC COLONY KANKARBAGH PATNA

RATE : 72 bpm SINUS RHYTHM
R-R : 831 ms LEAD(S) UNSUITABLE FOR ANALYSIS: V1
P-R : 136 ms
QRS : 76 ms
QT : 386 ms
QTc : 407 ms



--AXIS--

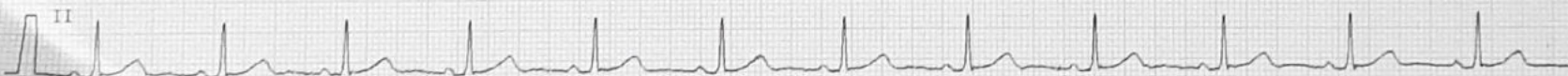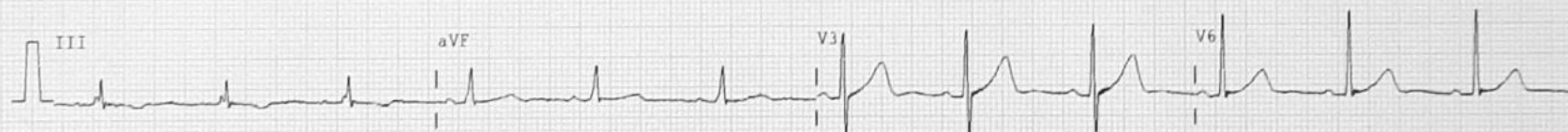
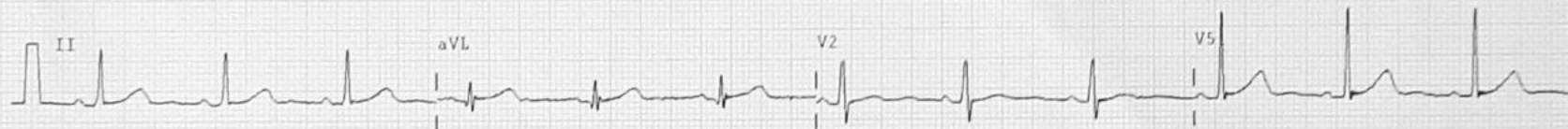
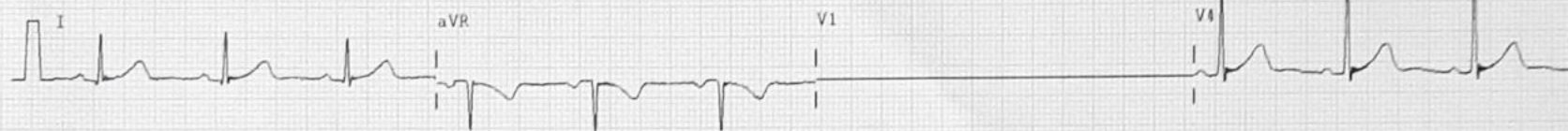
P : 26°
QRS : 48°
T : 20°

NORMAL ECG BASED ON AVAILABLE LEADS

12 SL: REPORT FORMAT-3x4+1L SO

REF: DR B O B

Dr. DR ABHISHEK KUMAR





A.L.C. Advance Imaging Dignostics

ISO 9001:2015 Certified center

(A Unit of Subham Imaging P.K. Arogyam Health & Wellness Center)

E-95, P.C. Colony, Near Sai Netryalaya Transformer, Kankarbagh, Patna - 20

alcdiagnostics@gmail.com

www.pkarogyamhealthcheckup.com

7050037694, 8271206196

OPINION MUST BE CORRELATES WITH CLINICALLY & OTHER INVESTIGATION FOR FINAL DIAGNOSIS. NOT FOR MEDICO LEGAL PURPOSE

ECHOCARDIOGRAPHY & COLOR DOPPLER REPORT

Patient's Name : Mr.SUSMITA

Age/Sex : 33 Yrs /F

Ref. by : DR./ MEEDIWHEEL

Date : 11-Dec-22

ECHOCARDIOGRAPHIC WINDOW: Fair

2D & M MODE ECHOCARDIOGRAPHY

Left ventricle

EDD:	25	mm (20 - 28 mm / m ²)	ESD:	20	mm(13 - 21 mm / m ²)
IVS :	9	mm (6 - 11 mm)	PW:	10	mm(6 -11 mm)
Ejection fraction:	60% (61 ± 8%)		FS:	37	%(34 - 44 %)
IVS:	Intact		LV clot	Absent	

Left atrium/ Aorta 34/31 mm

Right ventricle Normal

Right atrium Normal

Pericardium Normal with no pericardial effusion

2D:

Normal LA/LV Size and normally contracting left ventricle. No RWMA, concentric LVH

Mitral valve

AML/ PML: Normal

Tricuspid valve Normal

Aortic valve Normal

Pulmonary valve Normal

Continuous & Pulse Wave Doppler study

Valve	Velocity (m/sec)			Gradient (mmHg)			Valve area (PHT Method)	Regurg.
	Peak	Mean	EDV	Peak	Mean	EDG		
Mitral	E=07 A=0.6			2.3	2.0			Nil
Tricuspid	E=0.5 A=0.3			1.9	0.2			Nil
Aortic	1.12			5.0	2.5			Nil
Pulmonary	0.9			3.5	1.7			Nil

ESTB BY:-

Consultant Radiologist

Dr. P. K. Tiwari

MD, M.Sc (Radio Imaging)
Ph.D (Ait Nuclear Medicine)
Consultant Imagonologist & Sonologist

Dr. S. Kumar

MD (Pat)
Consultant Pathologist

Dr. Abhishek Kumar

MBBS, MD
Consultant Neuropatho Physiologist

Dr. Kymari Suman

MBBS, DGO, MD
Consultant GYN & HSG Specialist

Dr. A. K. Singh

MBBS, PGDMCH
Consultant Radiologist & Sonologist

PRINTING MISTAKE SHOULD BE REPORTED BACK IMMEDIATELY/ यहाँ जन्म से पहले भ्रुण का लिंग जाँच नहीं होता है ।

A.L.C. Advance Imaging Dignostics

ISO 9001:2015 Certified center

(A Unit of Subham Imaging P.K. Arogyam Health & Wellness Center)

E-95, P.C. Colony, Near Sai Netryalaya Transformer, Kankarbagh, Patna - 20

alcdiagnostics@gmail.com

www.pkarogyamhealthcheckup.com

7050037694, 8271206196

OPINION MUST BE CORRELATES WITH CLINICALLY & OTHER INVESTIGATION FOR FINAL DIAGNOSIS. NOT FOR MEDICO LEGAL PURPOSE

Colour Flow Imaging

No TR, No MR/PR, No AR

No flow shunt

COMMENTS :

- ◆ Normal size all chamber
- ◆ Normal LV filling Pressure
- ◆ No RWMA
- ◆ Normal LV systolic function
- ◆ Grade I LV diastolic dysfunction.
- ◆ Global LVEF = 60%
- ◆ All cardiac valves are normal
- ◆ No PAH, Mild concentric LVH
- ◆ No MS / TS / AS / PS / PR
- ◆ No clot / vegetation / pericardial effusion.

IMPRESSION:

All chambers are normal

No RWMA, No PAH

Grade I LV diastolic dysfunction.

Normal LV systolic function, LVEF – 63%

Please correlate clinically

DR. SANDEEP KUMAR MBBS MD

ESTB BY:-

Dr. P. K. Tiwari
MD, M.Sc (Radio Imaging)
Ph.D (Al Nuclear Medicine)
Consultant Imacionologist & Sonologist

Dr. S. Kumar
MD (Pat)
Consultant Pathologist

Dr. Abhishek Kumar
MBBS, MD
Consultant Neuropatho Physiologist

Dr. Kumari Suman
MBBS, DGO, MD
Consultant (TVS & HSG Specialist)

Consultant Radiologist

Dr. A. K. Singh
MBBS, PGDMCH
Consultant Radiologist & Sonologist



R

SUSHMITA 33 YEARS 2640 DR BO B CHEST,FRN P->A 12/09/2022
A.L.C. Advance Imaging Diagnostics Centre PATNA - 20



A.L.C. Advance Imaging Diagnostics

ISO 9001 2015 Certified center

(A Unit of Subham Imaging P.K. Arogyam Health & Wellness Center)

E-95, P.C. Colony, Near Sai Netryalaya Transformer, Kankarbagh, Patna - 20

alcdiagnostics@gmail.com

www.pkarogyamhealthcheckup.com

7050037694, 8271206196

OPINION MUST BE CORRELATES WITH CLINICALLY & OTHER INVESTIGATION FOR FINAL DIAGNOSIS. NOT FOR MEDICO LEGAL PURPOSE

Pt. Name :- SUSMITA

Ref. By :- DR./MEEDIWHEEL

Date:- 11-Dec-22

Age / Sex – 33 Yrs. F.

Thanks for your kind referral

X-RAYCHEST (P.A.VIEW)

The lungs on the either side show equal translucency.

The peripheral pulmonary vasculature is normal.

No focal lung lesion is seen.

The pleural spaces are normal.

Both hila are normal in size, have equal density and bear normal relationship.

The heart and trachea are central in position and no mediastinal abnormality is visible.

The cardiac size is normal.

The domes of the diaphragms are normal in position, and show smooth outline.

IMPRESSION

- NO EVIDENCE OF PULMONARY OR CARDIAC PATHOLOGY IS NOTED.



ESTD BY:-

Consultant Radiologist

Dr. P. K. Tiwari
MD, M.Sc (Radio Imaging)
Ph.D (Alt Nuclear Medicine)
Consultant Imagionologist & Sonologist

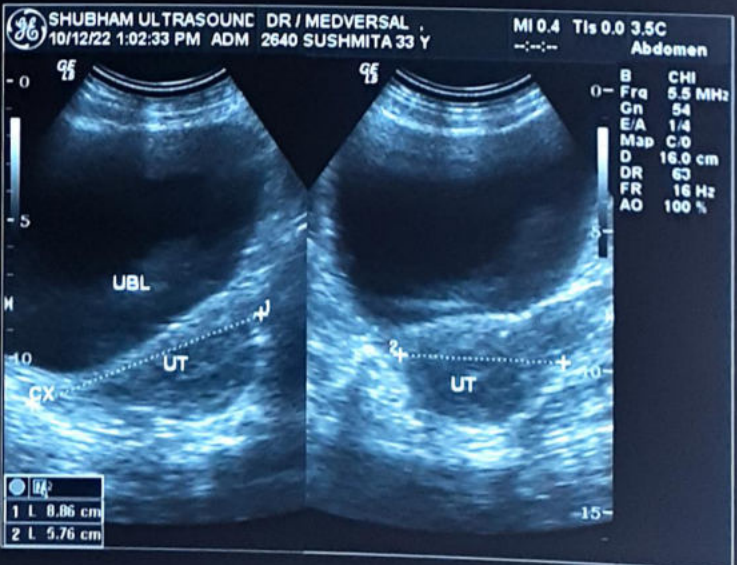
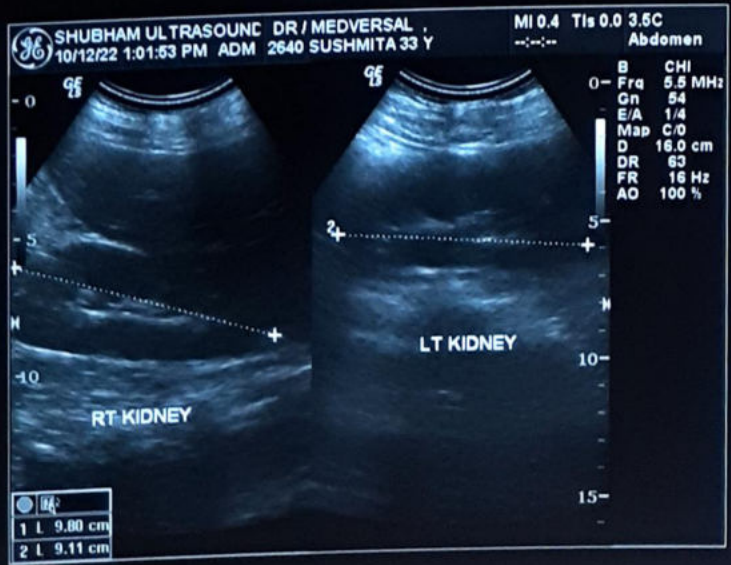
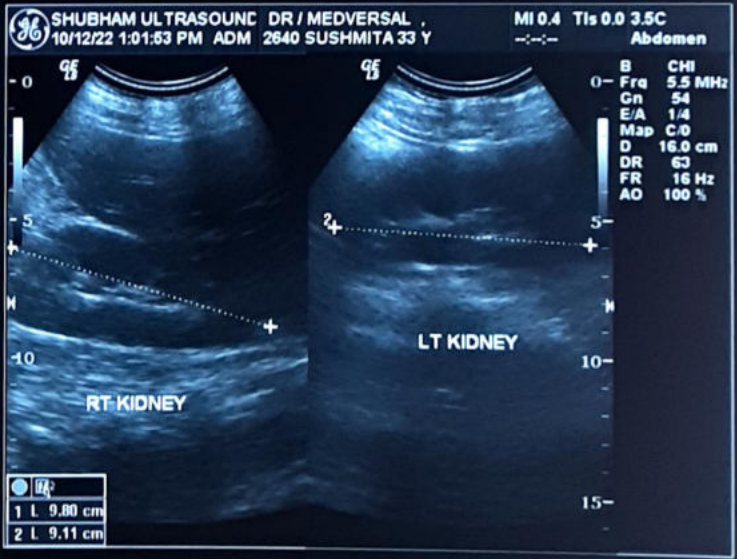
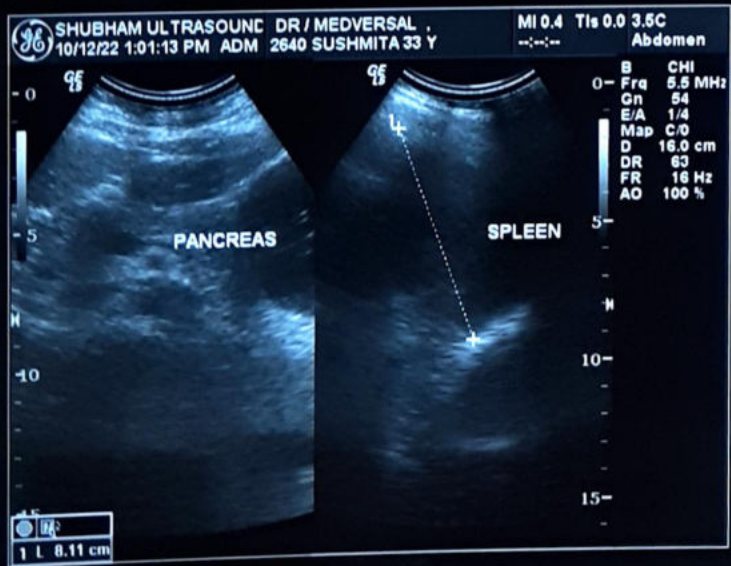
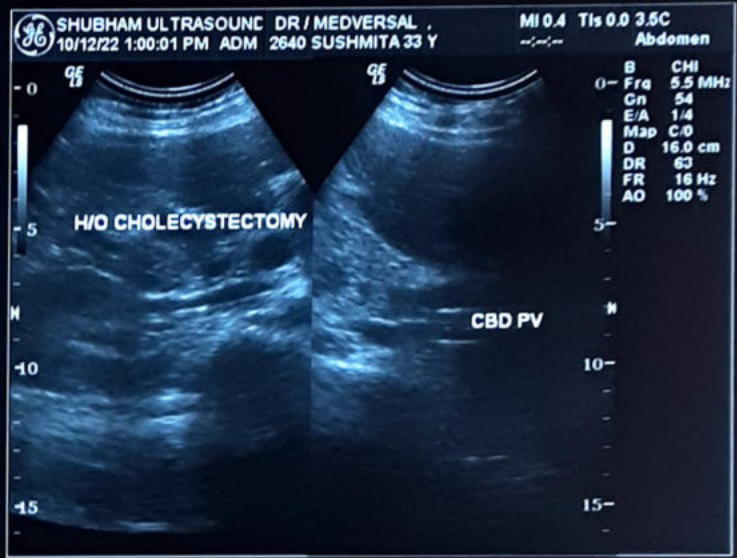
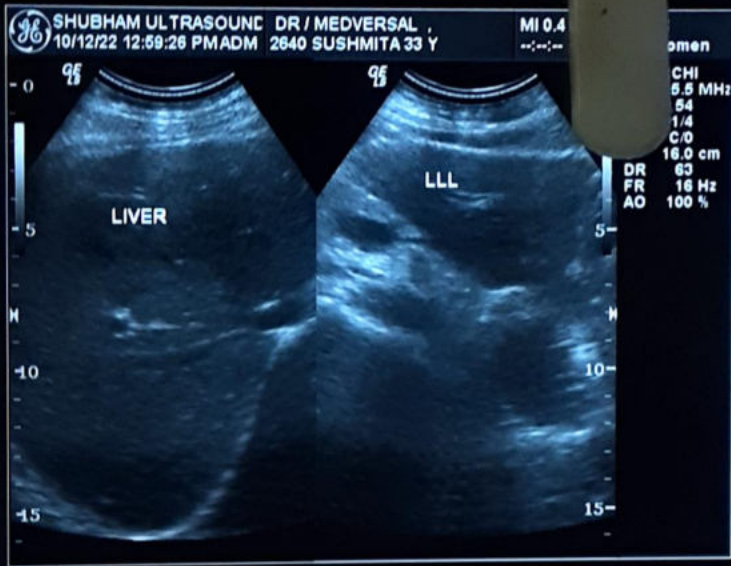
Dr. S. Kumar
MD (Pat)
Consultant Pathologist

Dr. Abhishek Kumar
MBBS, MD
Consultant Neuropatho Physiologist

Dr. Kumari Suman
MBBS, DGO, MD
Consultant (TVS & HSG Specialist)

Dr. A. K. Singh
MBBS, PGDMCH
Consultant Radiologist & Sonologist

PRINTING MISTAKE SHOULD BE REPORTED BACK IMMEDIATELY/यहाँ जन्म से पहले भ्रुण का लिंग जाँच नहीं होता है ।





A.L.C. Advance Imaging Dignostics

ISO 9001:2015 Certified center

(A Unit of Subham Imaging P.K. Arogyam Health & Wellness Center)

E-95, P.C. Colony, Near Sai Netryalaya Transformer, Kankarbagh, Patna - 20

alcdiagnostics@gmail.com

www.pkarogayamhealthcheckup.com

7050037694, 8271206196

OPINION MUST BE CORRELATES WITH CLINICALLY & OTHER INVESTIGATION FOR FINAL DIAGNOSIS. NOT FOR MEDICO LEGAL PURPOSE

Pt. Name :- **SUSHMITA**

Date:- **10-Dec-22**

Ref. By :- **DR./MEEDIWHEEL**

Age / Sex :- **33 Yrs. F.**

REAL TIME U.S.G. OF WHOLE ABDOMEN

Thanks for your kind referral

(Report.)

LIVER :- Measures 12.10 cm. Normal in shape, size and echo texture. I.H.B.R. are not dilated. Hepatic veins are normal. No SOL seen.

G.BL. :- **H/O Cholecystectomy.**

C.B.D. :- Measures 3.5 mm in diameter with echo free lumen. No calculi or mass seen.

P.V. :- Measures 7.6 mm in diameter. Appears normal. No thrombus seen.

PANCREAS :- Normal in shape, size and echo texture. No calcification mass seen.

SPLEEN :- Measures 8.11 cm. Normal in shape, size and echo texture. No SOL seen.

KIDNEY :- Both kidney shows normal shape, size & echotexture. C.M.D.intact. P.C.S.is not dilated. No calculi, cyst or hydronephrosis seen on either side.

Right Kidney :- Measures 9.80 X 4.2 cm.

Left Kidney :- Measures 9.11 X 4.3 cm.

URETER :- Not dilated. No apparent calculi seen.

U.BLADDER:- Shows normal in outline with echo free lumen. No calculi or mass seen.

Pre void -310 ml. Post void - is in significant

UTERUS :- Is Normal in size, shape & Anteverted in position measuring 8.86 X 5.76 cm. Endometrial and Myometrial appears normal in limits. No focal mass lesion seen cervix appear normal.

ADNEXA :- Both ovary appears normal in size and shape. Rt Ovary Measures - 2.10 cm Lt Ovary Measures 2.30 cm

P.O.D :- No collection seen in P.O.D.

R.I.F. :- Son graphically no appendicular mass or collection seen.

OTHERS :- **No Ascites. no Lymph Adenopathy. No pleural effusion seen on either side.**

IMPRESSION

➤ **Son graphically normal scan no detectable lesion seen**



10/12/22

ESTB BY:-

Consultant Radiologist

Dr. P. K. Tiwari
MD, M.Sc (Radio Imaging)
Ph.D (Ab Nuclear Medicine)
Consultant Imaginologist & Sonologist

Dr. S. Kumar
MD (Pat)
Consultant Pathologist

Dr. Abhishek Kumar
MBBS, MD
Consultant Neuropathologist

Dr. Kumari Suman
MBBS, DGO, MD
Consultant (TVS & HSG Specialist)

Dr. A. K. Singh
MBBS, PGDMCH
Consultant Radiologist & Sonologist