

Facilities:
 All clinical Biomedical & Hematology Investigations
 including Bone Marrow Examination
 VPT, Podiascan & Complete Foot Care (First Time in Purvanchal)
 All Hormonal Investigation by Chemiluminescent Method
 Visceral Fat by (AB-140) Ambulatory BP Monitoring
 CGMS & Insulin Pump Available
 PFT, 2D-ECHO (Color Doppler), Holter, TMT, Cardiac-3 available
 VIA, VILI, Colposcopy available
 Special Endocrinological Investigation Protocols.

ISO 9001:2008 Certified
 Mobile: 9389994334, 9554572190, 9453837595



Panacea Pathology Clinical Reference Lab

Persistence, Preparedness and Precision
 EQAS (CMC Vellore Attached) & IQAS System
 पूर्वांचल की सर्वोत्तम गुणवत्ता वाली पैथोलॉजी

PATIENT NAME : DEVESH SHAHPURI	AGE/GENDER : 31 YRS/MALE
REFD BY DR. : ARCO FEMI HEALTHCARE LTD.	RECEIVED DATE : 10-12-2022 (10:15 AM)
SAMPLE : BLOOD & URINE	REPORT DATE : 10-12-2022 (18:15 PM)

PATHOLOGY REPORT

COMPLETE BLOOD COUNT (CBC)

TEST	LAB TEST VALUES	NORMAL RANGE
HEMOGRAM		
HEMOGLOBIN (FLOW CYTOMETRY)	13.8	13 – 16 gm/dl
TOTAL LEUCOCYTE COUNT (TLC)	6600	4000 – 11000
RBC COUNT	5.16	3.5 – 5.5
PCV (HCT)	42.3	37 – 47
MCV	82.1	80 – 95
MCH	26.7	28 – 34
MCHC	32.3	30 – 36
PLATELET COUNT	1,62,000	1,50,000 – 4,00,000
E.S.R. (WINTROBE FIRST HOURS)	12.0	20 mm/1 st hr
DIFFERENTIAL LEUCOCYTE		
NEUTROPHILS	57	40 – 75%
LYMPHOCYTES	31	20 – 45%
EOSINOPHILS	05	1 – 6%
MONOCYTES	07	2 – 8%
BASOPHILS	00	< 2 %

RENAL & KIDNEY PROFILE, SERUM

TEST	LAB TEST VALUES	NORMAL RANGE
RENAL FUNCTION TESTS		
BLOOD UREA NITROGEN (BUN)	13.0	10 – 50 mg/dl
SERUM CREATININE	1.12	0.60 – 1.60 mg/dl
URIC ACID	4.1	3.60 – 7.70 mg/dl
ALKALINE PHOSPHATASE (ALP)	102.00	142 – 353 mg/dl
TOTAL PROTIENS	7.50	0 – 39 mg/dl
ALBUMIN	4.21	3.8 – 5.4 mg/dl
SERUM GLOBULIN	3.29	2.1 – 3.5 mg/dl
CALCIUM	10.0	8.80 – 10.20
PHOSPHORUS	3.42	2.50 – 5.00
SERUM SODIUM NA+	140.8	135.00 – 155.00 mEq/Ltr
SERUM POTASIUM K+	4.08	3.60 – 5.50 mEq/Ltr
ICALCIUM	1.25	1.10 – 1.35 mmol/L
SERUM CHLORIDE CL+	104.3	98.00 – 110.00 mEq/Ltr

PAGE 1

Lab Technician

M.D., Pathology

Timing : 8.00 a.m. to 9.00 p.m. (Sunday 8.00 a.m. to 3.00 p.m.)

This Report is not valid for medico legal purpose

Note: These tests have technical limitations. Clinico-pathological interpretation is necessary. In case of any disparity test may be repeated immediately.

Address : 36/44 FK Kabir Nagar, Durgakund, Varanasi – 221005

Email: dramishra@gmail.com, drpallaviojha@gmail.com Website: panaceahospital.org

Facilities:
 All clinical Biomedical & Hematology Investigations
 including Bone Marrow Examination
 VPT, Podiascan & Complete Foot Care (First Time in Purvanchal)
 All Hormonal Investigation by Chemiluminescent Method
 Visceral Fat by (AB-140) Ambulatory BP Monitoring
 CGMS & Insulin Pump Available
 PFT, 2D-ECHO (Color Doppler), Holter, TMT, Cardiac-3 available
 VIA, VILI, Colposcopy available
 Special Endocrinological Investigation Protocols.

ISO 9001:2008 Certified
 Mobile: 9389994334, 9554572190, 9453837595



Panacea Pathology
Clinical Reference Lab

Persistence, Preparedness and Precision
 EQAS (CMC Vellore Attached) & IQAS System
 पूर्वांचल की सर्वोत्तम गुणवत्ता वाली पैथोलॉजी

PATIENT NAME : RAKESH MEHTA	AGE/GENDER : 50 YRS/MALE
REFD BY DR. : ARCO FEMI HEALTHCARE LTD.	RECEIVED DATE : 28-11-2022 (10:15 AM)
SAMPLE : BLOOD & URINE	REPORT DATE : 28-11-2022 (18:15 PM)

PATHOLOGY REPORT

LIPID PROFILE, SERUM

TEST	LAB TEST VALUES	NORMAL RANGE
BLOOD CHEMISTRY		
TOTAL CHOLESTEROL (SERUM)	168.0	Desirable:- < 200 mg/dl Borderline:- 200 – 239 mg/dl High:- > 240 mg/dl
TRIGLYCERIDES (SERUM)	154.0	35 – 170 mg/dl
HDL CHOLESTEROL (SERUM)	42.0	35.30 – 79.50 mg/dl
LDL CHOLESTEROL (SERUM)	95.2	< 130 mg/dl
VLDL	30.8	< 40 mg/dl
NON HDL	70.6	0.00 – 100.00 mg/dl
CHOLESTROL/HDL RATIO	4.00	< 3.0 Low Risk Ratio 3.0 – 5.0 Avg Risk < 5.0 High Risk
LDL/HDL RATIO	2.26	< 3 Ratio

GLYCOSYLATED HEMOGLOBIN (HBA1C)

TEST	LAB TEST VALUES	NORMAL RANGE
HBA1C	6.6	Normal : <5.97 % Good Control : 5.97 – 6.81% Fair Control : 6.81 – 7.65% Poor Control : >7.65%

THYROID PROFILE (T3, T4, TSH)

TEST	LAB TEST VALUES	NORMAL RANGE
THYROID FUNCTION TEST		
T3	0.88	0.60 – 1.81 ng/ml
T4	7.16	4.50 – 10.90 ug/dl
TSH	1.91	0.39 – 6.10 uIU/mL

PAGE 2

Lab Technician

M.D., Pathology

Timing : 8.00 a.m. to 9.00 p.m. (Sunday 8.00 a.m. to 3.00 p.m.)

This Report is not valid for medico legal purpose

Note: These tests have technical limitations. Clinico-pathological interpretation is necessary. In case of any disparity test may be repeated immediately.

Address : 36/44 FK Kabir Nagar, Durgakund, Varanasi – 221005

Email: dramishra@gmail.com, drpallaviojha@gmail.com Website: panaceahospital.org

PATIENT NAME : RAKESH MEHTA	AGE/GENDER : 50 YRS/MALE
REFD BY DR. : ARCO FEMI HEALTHCARE LTD.	RECEIVED DATE : 28-11-2022 (10:15 AM)
SAMPLE : BLOOD & URINE	REPORT DATE : 28-11-2022 (18:15 PM)

PATHOLOGY REPORT

LIVER PROFILE TEST, SERUM

TEST	LAB TEST VALUES	NORMAL RANGE
BIO CHEMISTRY		
TOTAL BILIRUBIN	0.71	0.0 – 1.1 mg/dl
DIRECT BILIRUBIN	0.21	0.0 – 0.2 mg/dl
INDIRECT BILIRUBIN	0.50	< 0.90 mg/dl
SGOT (AST)	28.0	0 – 52 mg/dl
SGPT (ALT)	25.6	0 – 39 mg/dl
GGT (GYT)	22.0	< 55 U/L
AG RATIO	1.96	-

URINE ROUTINE EXAMINATION

TEST	LAB TEST VALUES	NORMAL RANGE
PHYSICAL EXAMINATION		
QUANTITY	30	ML
COLOUR	STRAW	PALE YELLOW
APPEARANCE	CLEAR	CLEAR
SPECIFIC GRAVITY	1.030	1.01 – 1.03
PH	6.0	4.7 – 7.5
CHEMICAL EXAMINATION		
GLUCOSE	Not Detected	Not Detected
PROTEIN	NIL	Not Detected
MICROSCOPIC EXAMINATION		
PUS CELLS	3-4	0-5
RBC	Not Detected	Not Detected
EPITHELIAL CELLS	1-2	0-5
CASTS	Not Detected	Not Detected
CRYSTALS	Not Detected	Not Detected
BACTERIA	Not Detected	Not Detected

BLOOD GROUP

TEST	LAB TEST VALUES
BLOOD GROUPING	
SAMPLE WHOLE BLOOD EDTA	" A " POSITIVE

PAGE 3

Lab Technician

M.D., Pathology

Timing : 8.00 a.m. to 9.00 p.m. (Sunday 8.00 a.m. to 3.00 p.m.)

This Report is not valid for medico legal purpose

Note: These tests have technical limitations. Clinico-pathological interpretation is necessary. In case of any disparity test may be repeated immediately.

Address : 36/44 FK Kabir Nagar, Durgakund, Varanasi – 221005

Email: dramishra@gmail.com, drpallaviojha@gmail.com Website: panaceahospital.org

Facilities:
All clinical Biomedical & Hematology Investigations
including Bone Marrow Examination
VPT, Podiascan & Complete Foot Care (First Time in Purvanchal)
All Hormonal Investigation by Chemiluminescent Method
Visceral Fat by (AB-140) Ambulatory BP Monitoring
CGMS & Insulin Pump Available
PFT, 2D-ECHO (Color Doppler), Holter, TMT, Cardiac-3 available
VIA, VILI, Colposcopy available
Special Endocrinological Investigation Protocols.

ISO 9001:2008 Certified
Mobile: 9389994334, 9554572190, 9453837595



Panacea Pathology Clinical Reference Lab

Persistence, Preparedness and Precision
EQAS (CMC Vellore Attached) & IQAS System
पूर्वांचल की सर्वोत्तम गुणवत्ता वाली पैथोलॉजी

PATIENT NAME : RAKESH MEHTA	AGE/GENDER : 50 YRS/MALE
REFD BY DR. : ARCO FEMI HEALTHCARE LTD.	RECEIVED DATE : 28-11-2022 (10:15 AM)
SAMPLE : BLOOD & URINE	REPORT DATE : 28-11-2022 (18:15 PM)

FASTING/RANDOM BLOOD SUGER

TEST	LAB TEST VALUES	NORMAL RANGE
FBS/RBS		
FASTING BLOOD SUGER	105.0	110-125 mg/dl
RANDOM BLOOD SUGER	135.0	125-140 mg/dl

----- End of Report -----

Lab Technician

M.D., Pathology

Timing : 8.00 a.m. to 9.00 p.m. (Sunday 8.00 a.m. to 3.00 p.m.)

This Report is not valid for medico legal purpose

Note: These tests have technical limitations. Clinico-pathological interpretation is necessary. In case of any disparity test may be repeated immediately.

Address : 36/44 FK Kabir Nagar, Durgakund, Varanasi – 221005

Email: dramishra@gmail.com, drpallaviojha@gmail.com Website: panaceahospital.org



shwasti
shamirga

PANACEA HOSPITAL

B 36/44 F.K KABIR NAGAR, DURGAKUND
TOLLFREE NO-18001233070.
Whatsapp No - 8795832852
www.piire.org



OP Slip

Print Date : 10-Dec-2022 08:48AM



UHID No	:- UD-22230002872	OP No	:- OP-22230010793	OP Date	:- 10 Dec 2022 8:47AM
Patient Name	:- Mr DEVESH SHAHAPURI	Age/Sex	:- 31 Y/Male	Mobile No	:- 9616480004
Father	:- DEEPAK SHAHAPURI	Department	:- DIABETES, ENDOCRINOLOGY & METABOLIC PHYSICIAN		
Pay Type	:- Cash	Consultant	:- Dr ASHUTOSH MISHRA (MD(MEDICINE), IMS, BHU)		
Token No	:- NOR. -6	Paid/Bal	:- 0.00 /500.00		
Patient Type	:- Normal				
Address	:- SUSUWAHI ,varanasi				

BP :- 120/75
 height :- 172
 Weight (kg) :- 87.3
 BMI :- 29.5

Rx

HbA1c = 6.6
 F = RBS = 105.

Diabetic (T2DM)

NC - 38
 WC - 96
 SpO2 - 99
 PR - 61

Rx
 1 bookult (t.
 Diabetic diet & exercise)

Tab. Diabemso (10) OD
 Avand (60) AD x 10
 ↓
 SWHITW.

Dr. Pallavi

Tab Remy Longum

Mr. Path

Printed By : Mr NITIN YADAV
 Created By : Mr NITIN YADAV

AUTO 10mm/mV

10mm/mV

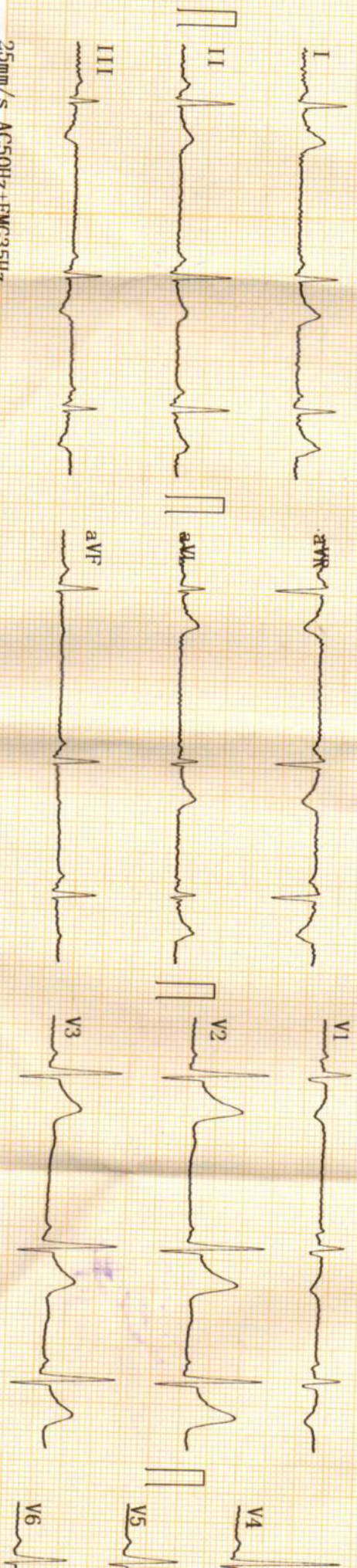
10mm/mV

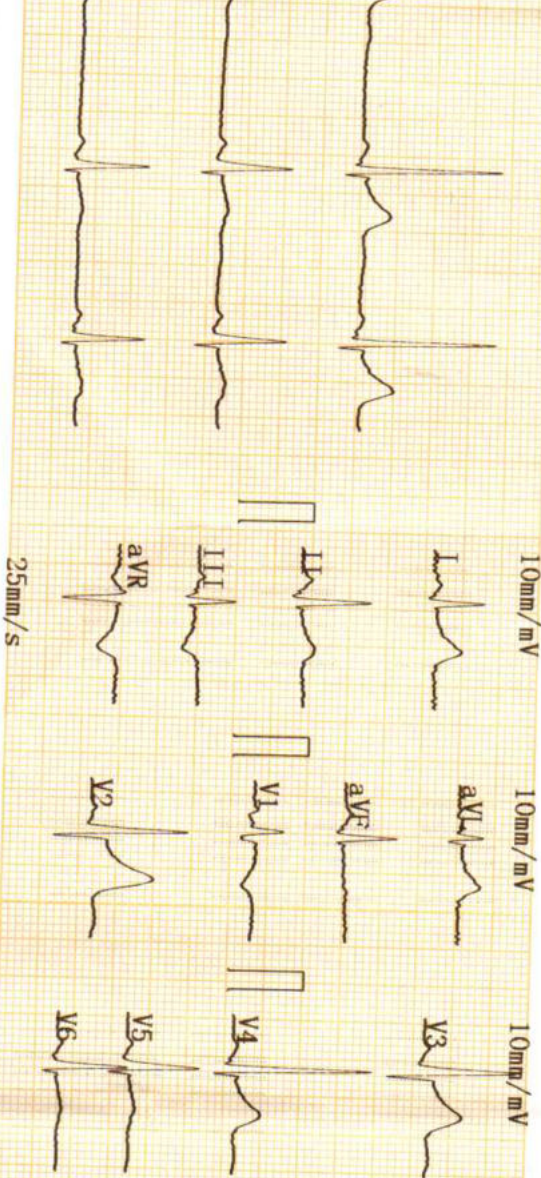
10mm/mV

25mm/s AC50Hz+EMG35Hz

CARDIART

BpL





2022-12-10 09:44

ID : _____
 Name : Devesh
 Sex : m
 Height : _____
 SYS : _____
 DIA : _____

HR : 56 bpm
 PR Interval : 144 ms
 P Duration : 120 ms
 QRS Duration : 84 ms
 T Duration : 205 ms
 QT/QTc : 375/363 ms
 P/QRS/T Axis : 68.9/50.2/12.1 deg
 R (V5) / S (V1) : 1.00/0.15 mV
 R (V5) + S (V1) : 1.15 mV

CARDIART

Physician

<< Conclusions >>

Sinus mode Bradycardia;
 Cardiac electric axis normal;
 III aVF V1 V6 Abnormal T wave;

Report need physician confirm

DR. PALLAVI MISHRA
 L.RBS.MD (GENERAL MEDICINE)
 MCI Reg.No. 52033



PANACEA HOSPITAL

A shelter for many hearts A Home for many lives

(An ISO 9001:2008 Certified Organisation)

Lab Attached with CMC Vellore Under EQAS Scheme

ame	MR.DEVESH SHAHPURI	Sex /Age	31/M	Date	10/12/2022
Ref. by	Dr.Pallavi Mishra(MD)	BSA - m ²		Echo window	fair

Echo - Cardiography

MITRAL VALVE Doppler	AML - normal morphology MV Flow - E - 0.7 A-0.5 E/A=1.48	PML - normal morphology MVA - 3.0 cm ² Mitral Regurgitation - No
TRICUSPID VALVE Doppler	Normal TV Flow -No	Tricuspid Regurgitation -No
PULMONARY VALVE Doppler	Normal PV Flow -No	Pulmonary Regurgitation - No
AORTIC VALVE Doppler	Trileaflet-No AV Flow - no	Aortic Regurgitation - no
MEASUREMENT	Aorta - 28.6 (20-38) mm IVS ed - 12.0 (6 -12) mm LVID ed - 26.3 (35 - 55) mm LVPW ed - 18.8 (6 -12) mm OA - 7 (> 5) mm	LA - 37.7 (24-32) mm IVS es -15.4 (6 - 12) mm LVID es - 18.3 (24 - 40) mm LVPW es - 17.1 (6 -12) mm EPSS - 5 (< 9) mm

CONCLUSION

All cardiac chamber dimensions are WNL
No valvular abnormalities
Good LV systolic function present Modified Simpson's method (4C, 2C) (LVEF-60%)
No diastolic dysfunction present (E/A = 1.48) by tissue Doppler (E/e'=7.2)
No RWMA
No pericardial effusion
Intact IAS / IV
No PAH
No intra cardiac mass /thrombus /vegetation

IMPRESSION

Normal Echocardiogram


Niraj Mishra
Physician Assistant
(PIIRE)

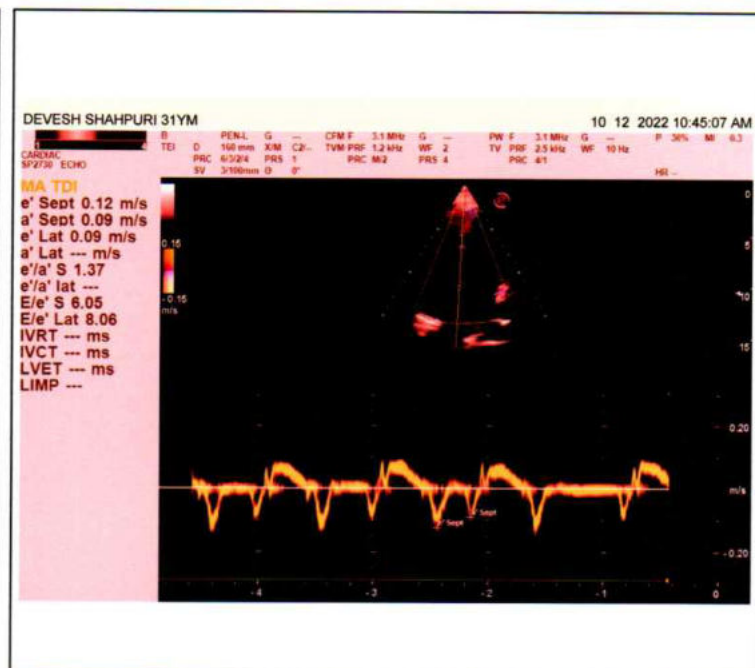
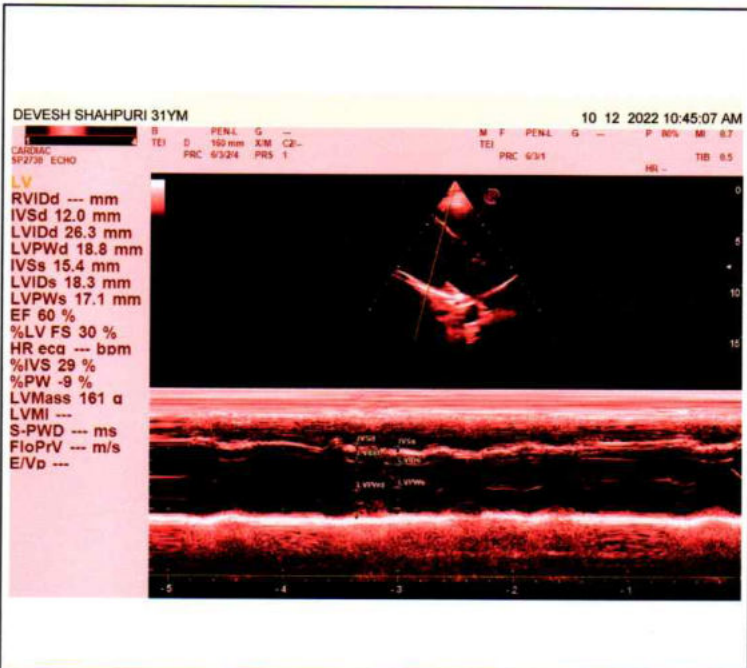
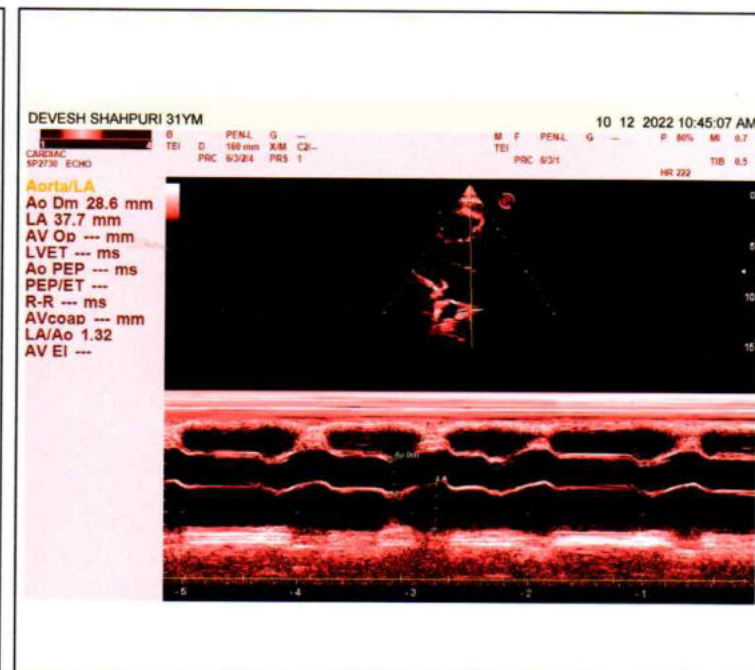
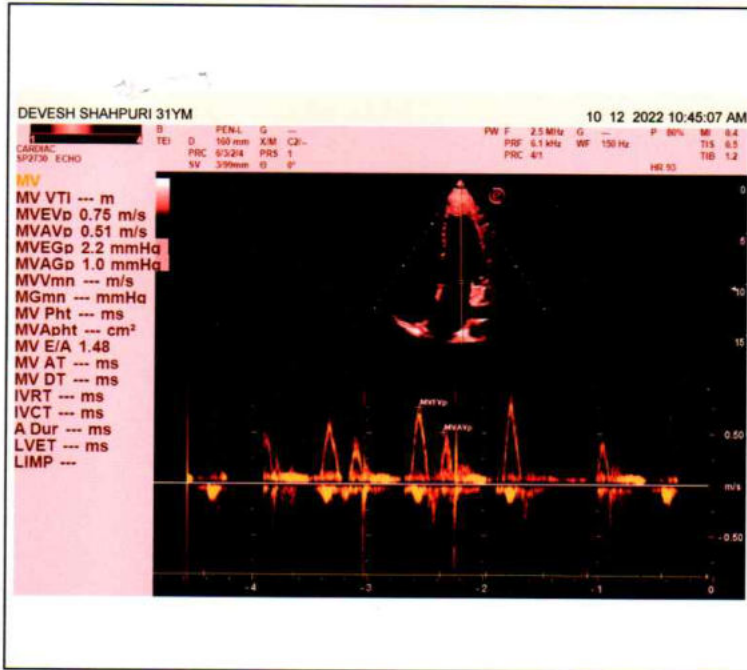

DR. PALLAVI MISHRA
MBBS, MD (GENERAL MEDICINE,
MCI Reg.No. 52033

Dr. Pallavi Mishra
MBBS, MD (MED) Lucknow
Echocardiography Specialist, MIAE
Non-invasive cardiologist
Women Cardiologist
Diabetocardiologist

Address : Kabir Nagar (Near Sanjay Shiksha Niketan), Durgakund, Varanasi

Mobile : 9554572190 / 9453837595 / Recpn. 9389994334

E-mail : dramishra@gmail.com, drpallaviojha@gmail.com, Website: www.piire.org





PANACEA HOSPITAL

A shelter for many hearts A Home for many lives

(An ISO 9001:2008 Certified Organisation)

Lab Attached with CMC Vellore Under EQAS Scheme

AME: MR.DEVESH SHAHPURI

AGE/SEX: 31 YRS / MALE

REF BY: DR. ASHUTOSH MISHRA (MD)

DATE: 10/12/2022

ULTRA SOUND WHOLE ABDOMEN REPORT

Liver: *Normal in shape and size(12.3 cm) and shows mildly increased echogenicity.*
Margins are smooth and regular. No focal lesion seen.

Gall bladder: Partially distended with normal wall thickness and echo-free lumen.

CBD diameter Visualized part normal in course & caliber.

Pancreas: Normal in size, shape & echogenicity.
Margins are smooth & regular.
No diffuse/ focal lesion seen. Pancreatic tail obscured.

Spleen: Normal in size,(10.6 cm) shape & echogenicity.
Margins are smooth & regular. No diffuse / focal lesion seen.
Splenic vessels at hilum is normal.

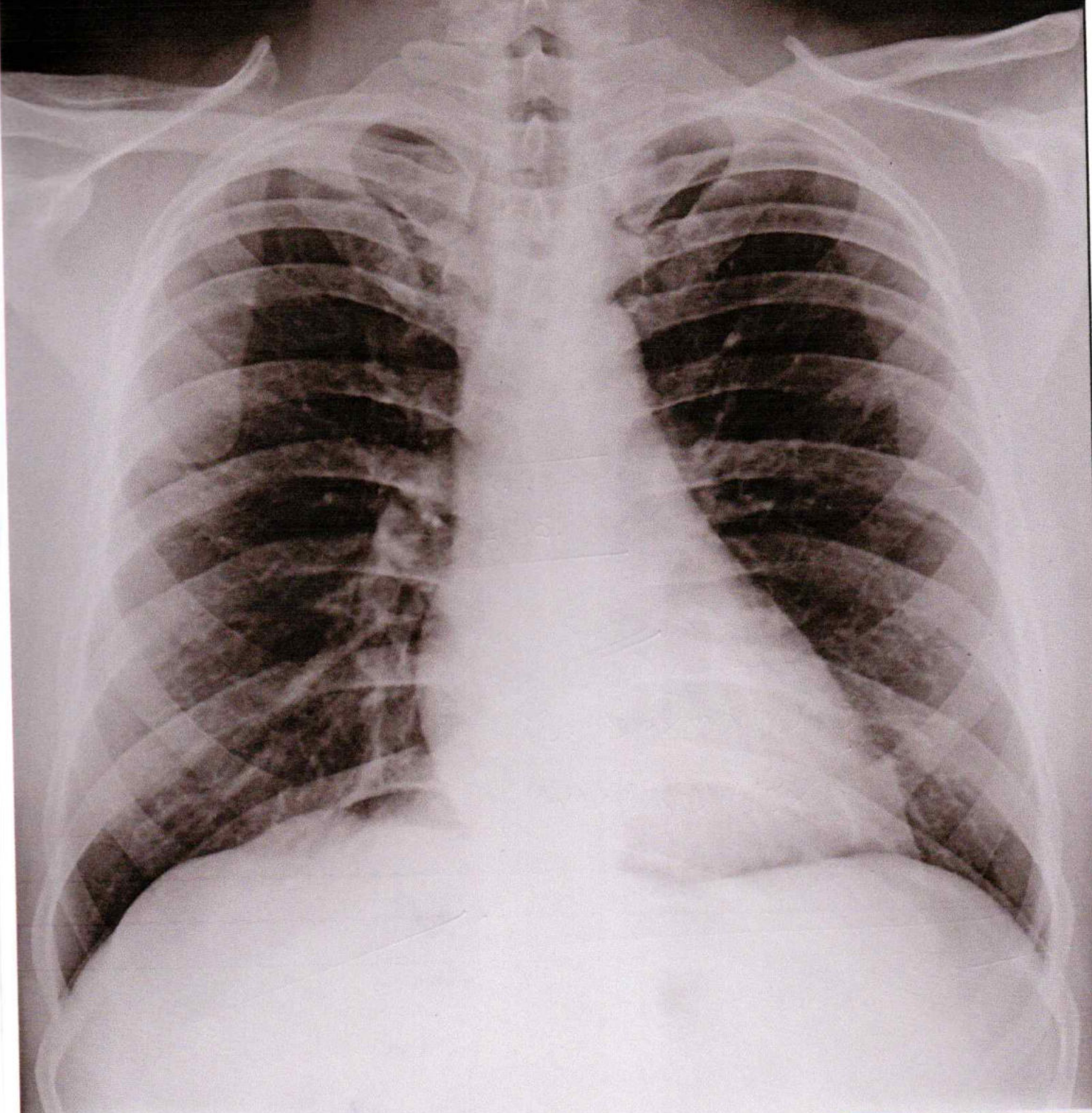
Kidney: Right kidney: 9.1 X 4.1cm
Left kidney: 9.1 X 3.6 cm
Both normal in size, shape, echogenicity & position.
Cortical-medullary differentiation is maintained.
Pelvicalyceal system normal.
No calculus/mass lesion seen.
No hydronephrosis/ hydroureter seen.
No suprarenal mass lesion.

Address : Kabir Nagar (Near Sanjay Shiksha Niketan), Durgakund, Varanasi

Mobile : 9554572190 / 9453837595 / Recpn. 9389994334

E-mail : dramishra@gmail.com, drpallaviojha@gmail.com, **Website:** www.paire.org

R



DEVESH SHAHAPURI 31Y/M 2872 O CHEST P.A. 10-Dec-22 11:00 AM

PANACEA HOSPITAL, KABIR NAGAR, DURGAKUND, VARANASI



PANACEA HOSPITAL

A shelter for many hearts

A Home for many lives

(An ISO 9001:2008 Certified Organisation)

Lab Attached with CMC Vellore Under EQAS Scheme

NAME: MR.DEVESH SHAHAPURI

AGE/SEX: 31 YRS / MALE

REF BY: DR.ASHUTOSH MISHRA(MD)

DATE: 10/12/2022

X-RAY CHEST PA

BOTH LUNG FIELDS AND PLEURAE:

Both lungs show normal bronchovascular pattern.

Right & left hila are normal

No focal mass or calcification is seen

There is no evidence of any fluid in the both the pleural cavities.

Both domes of diaphragms are normal in position.

MEDIASTINUM:

Trachea is central in position.

Cardiac silhouette is of normal size and configuration.

No evidence of pericardial effusion.

No significant lymphadenopathy is seen.

Visualized skeleton is normal.

NO SIGNIFICANT RADIOGRAPHIC ABNORMALITY

DR. ALPANA PATHAK
MD, RADIOLOGY
REG. NO. 46465

REPORTED BY

DR. ALPANA PATHAK
MBBS (HONS, GOLD MEDALIST) PMCH, PATNA
MD RADIODIAGNOSIS (GOLD MEDALIST) IMS BHU
EX-SR, IMS BHU, VARANASI

Address : Kabir Nagar (Near Sanjay Shiksha Niketan), Durgakund, Varanasi

Mobile : 9554572190 / 9453837595 / Recpn. 9389994334

E-mail : dramishra@gmail.com, drpallaviojha@gmail.com, Website: www.piire.org