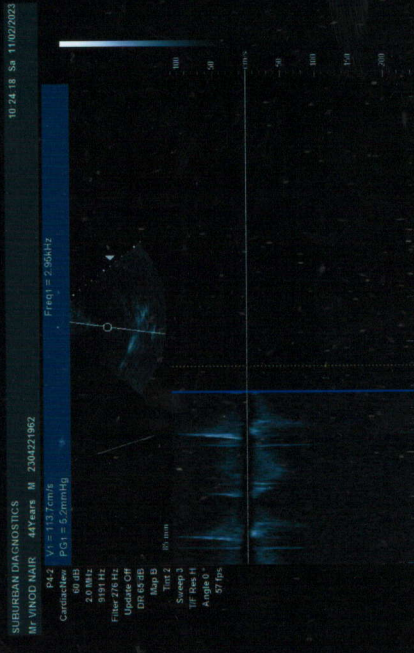
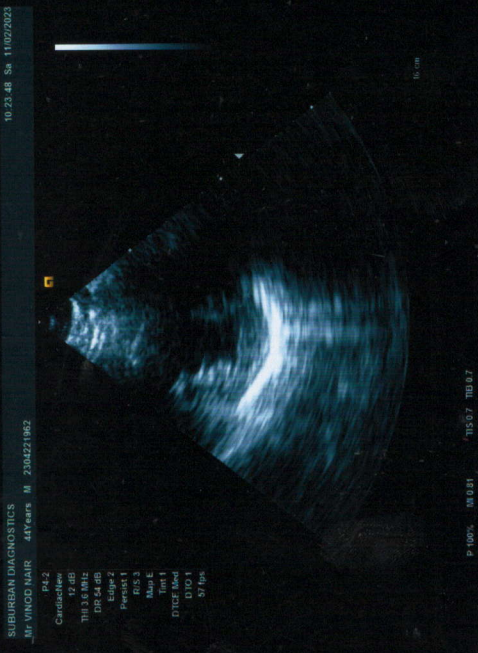
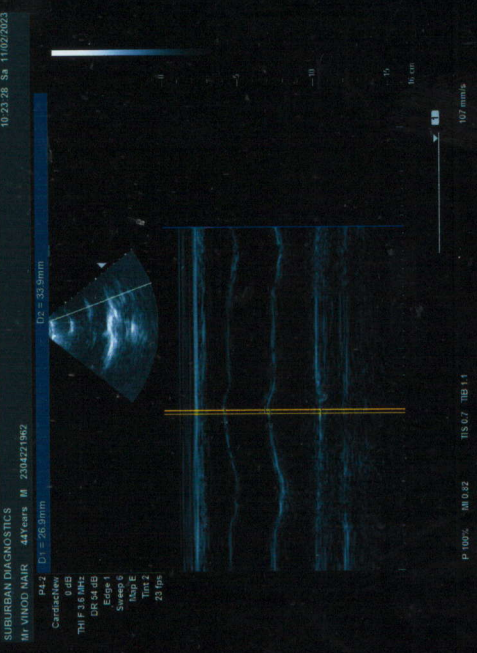
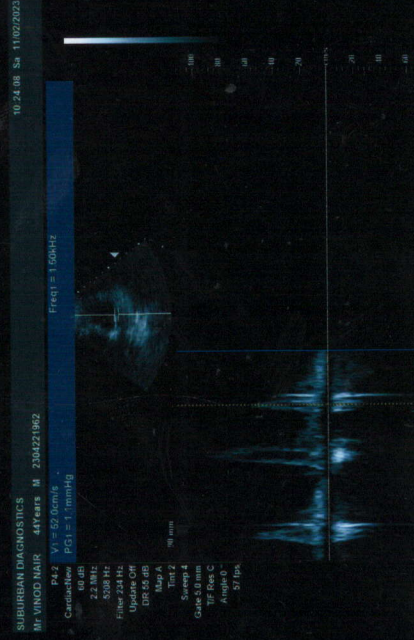
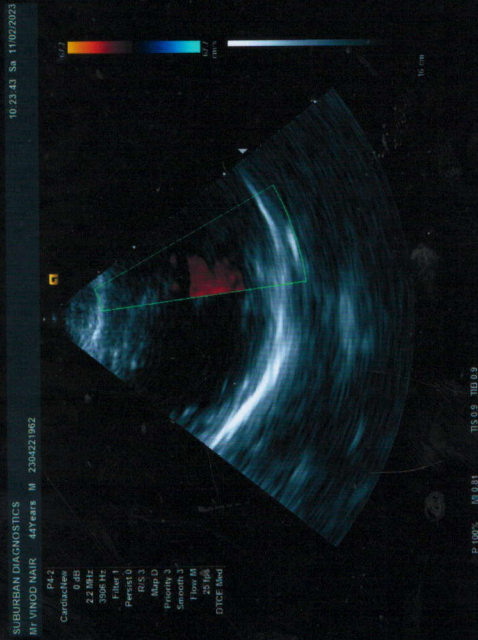
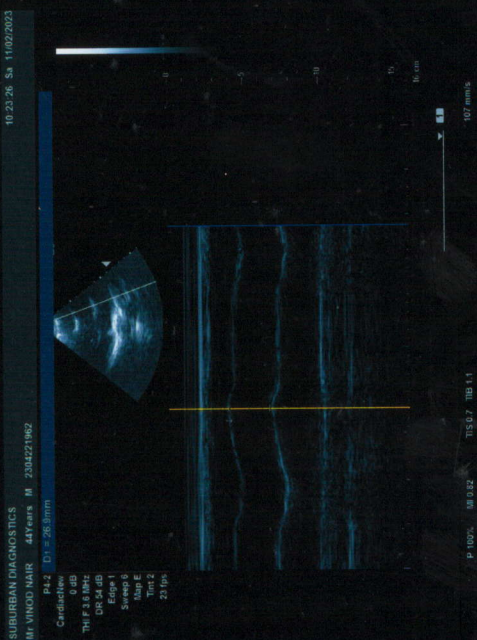
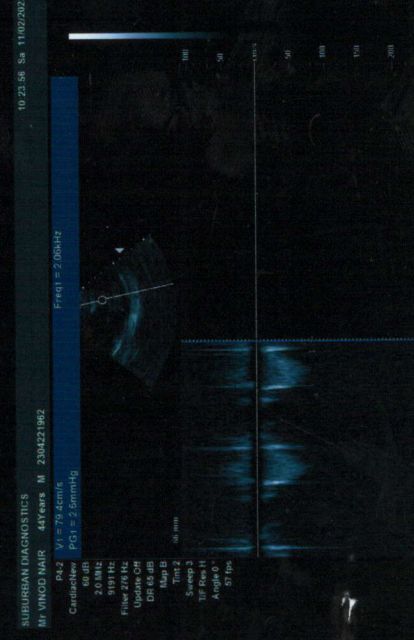
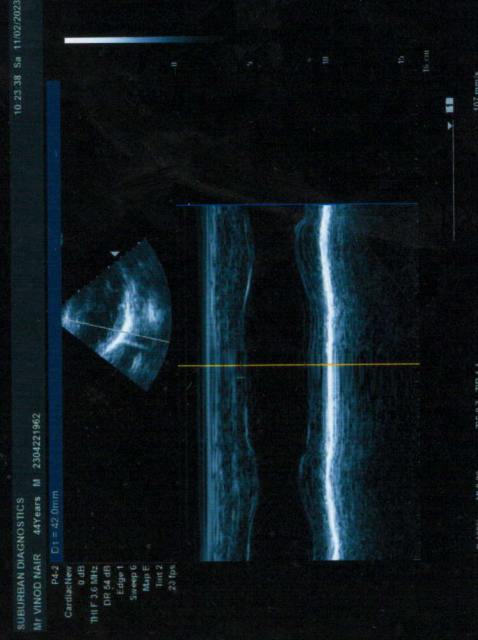
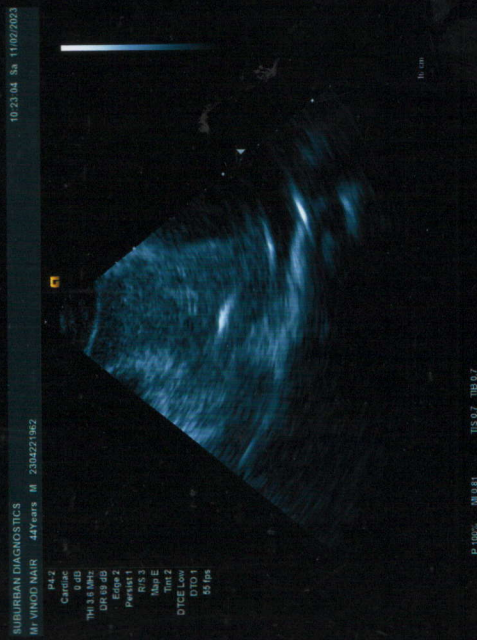




# SUBURBAN DIAGNOSTIC CENTRE

Name : Mr VINOD NAIR 044Y / M

11 Feb 2023 Study : Cardiac



Vinod Nair  
44/M

11-2-23

PHY2.

**History and Complaints:**

NIL

**EXAMINATION FINDINGS:**

Height (cms):	177	Weight (kg):	74	BMI
Temp (0c):	Afebrile	Skin:	Normal	} mmo
Blood Pressure (mm/hg):	110/80	Nails:	Healthy	
Pulse:	76	Lymph Node:	Not Palpable	

**Systems**

Cardiovascular: S1,S2 Normal No Murmurs

Respiratory: Air Entry Bilaterally Equal

Genitourinary: Normal

GI System: Soft non tender No Organomegaly

CNS: Normal

} mmo

**IMPRESSION:**


FIT  
Reports mmo

**ADVICE:**

- NIL


**CHIEF COMPLAINTS:**

1)	Hypertension:	} mmo
2)	IHD:	
3)	Arrhythmia:	
4)	Diabetes Mellitus :	
5)	Tuberculosis :	
6)	Asthama:	
7)	Pulmonary Disease :	
8)	Thyroid/ Endocrine disorders :	

9)	Nervous disorders :	
10)	GI system :	
11)	Genital urinary disorder :	
12)	Rheumatic joint diseases or symptoms :	
13)	Blood disease or disorder :	
14)	Cancer/lump growth/cyst :	
15)	Congenital disease :	
16)	Surgeries :	


**PERSONAL HISTORY:**

1)	Alcohol	180ml / weekly x 20 years.
2)	Smoking	No.
3)	Diet	Normal
4)	Medication	None



Dr. KRUTIKA INGLE

MBBS, D.D.M, PG in Diabetology (USA)  
 MMC Regd - 2012 103018



**DENTAL CHECK - UP**

Name:- *Vinod Nair*

CID :

Sex / Age: *44/M*

Occupation:-

Date: *18/2/23*

Chief complaints:-

Medical / dental history:-

*3 nrl*

**GENERAL EXAMINATION:**

**1) Extra Oral Examination:**

- a) TMJ:
- b) Facial Symmetry:

**2) Intra Oral Examination:**

- a) Soft Tissue Examination:
- b) Hard Tissue Examination:
- c) Calculus:

Stains:

*Gen*

18	17	16	15	14	13	12	11	21	22	23	24	25	26	27	28
48	47	46	45	44	43	42	41	31	32	33	34	35	36	37	38

	Missing	#	Fractured
<input type="radio"/>	Filled/Restored	RCT	Root Canal Treatment
<input type="radio"/>	Cavity/Caries	RP	Root Piece

Advised:

*mn*

Provisional Diagnosis:-

*Krutika Ingle*

Dr. KRUTIKA INGLE

MBBS, D.DM, PG in Diabetology (USA)  
MMC Regd - 2012 103018

Preventive Health Check-up | Pathology | Digital X-Ray | Sonography | Colour Doppler | Mammography | BMD (DXA Scan) | OPG | ECG  
Stress Test/TMT | 2D Echo | Spirometry | Eye Examination | Dental Examination | Diet Consultation | Audiometry | OT Sterility | Water Sterility | Clinical Research

Date:- 18-2-23  
Name:- Vinod Naik

CID:  
Sex / Age: 44 / M


**EYE CHECK UP**

Chief complaints: gm  
Systemic Diseases: gm  
Past history: gm  
Unaided Vision: gm  
Aided Vision: gm  
Refraction: gm

	(Right Eye)				(Left Eye)			
	Sph	Cyl	Axis	Vn	Sph	Cyl	Axis	Vn
Distance	---	---	---	6/6	---	---	---	6/6
Near	---	---	---	12/6	---	---	---	12/6

Colour Vision: Normal / Abnormal

Remark: nil

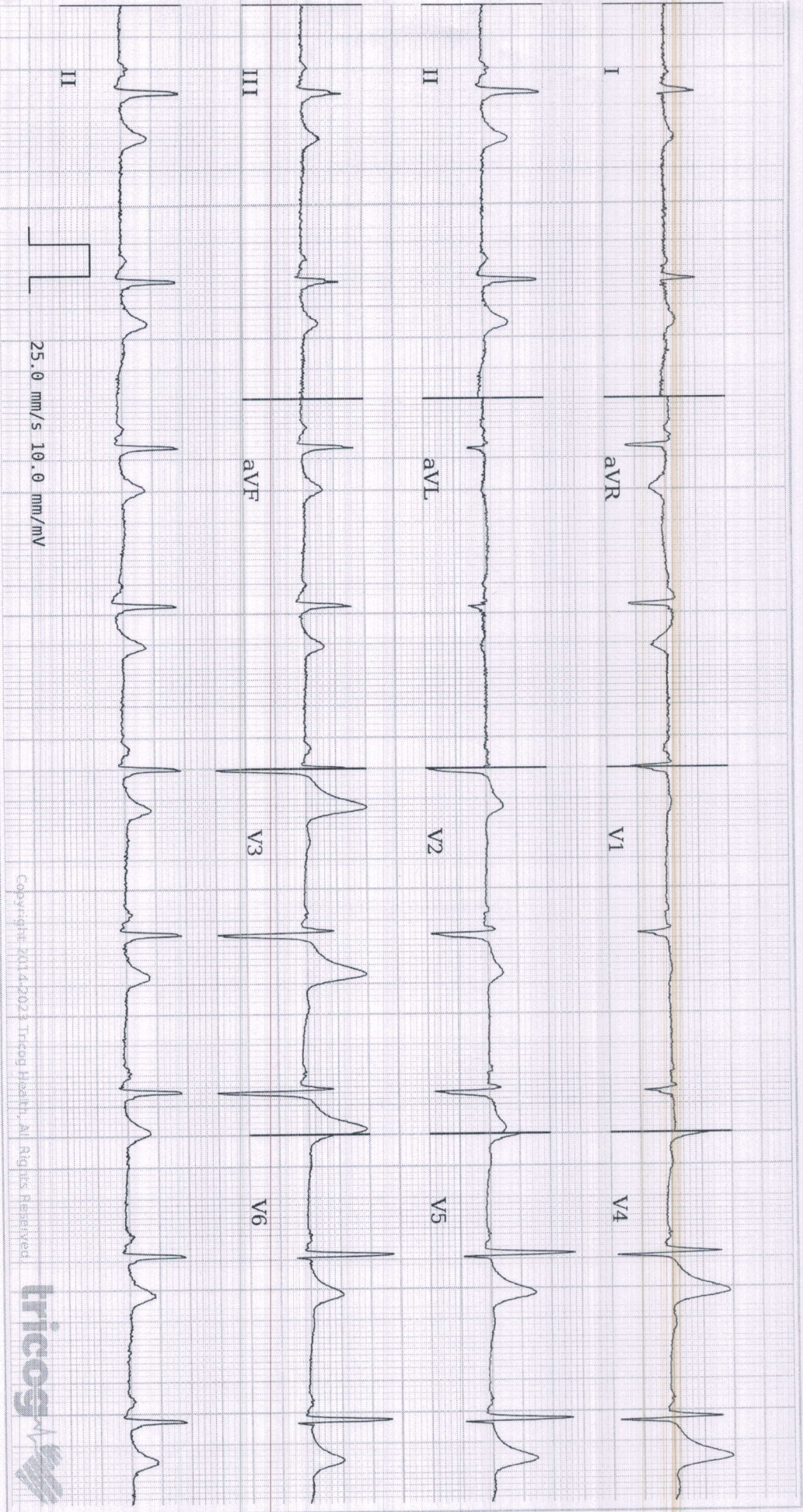


**Dr. KRUTIKA INGLE**

MBBS, D.DM, PG in Diabetology (USA)  
MMC Regd - 2012 103018

Patient Name: VINOD NAIR  
Patient ID: 2304221962

Date and Time: 11th Feb 23 9:23 AM



Copyright 2014-2023 Tricog Health, All Rights Reserved



Age **44** 3 years months d

Gender **Male**

Heart Rate **56bpm**

Patient Vitals

BP: 110/80 mmHg  
Weight: 74 kg  
Height: 177 cm  
Pulse: 76 bpm  
SpO2: NA  
Resp: NA  
Others:

Measurements

QRSD: 88ms  
QT: 402ms  
QTc: 387ms  
PR: 128ms  
P-R-T: 70° 68° 67°

REPORTED BY

Dr. Kratika Ingle  
MBBS, DDM, PG in Diabetology (USA)  
2012103018

ECG Within Normal Limits: Sinus bradycardia. Please correlate clinically.

Disclaimer: 1) Analysis in this report is based on ECG alone and should be used as an adjunct to clinical history, symptoms, and results of other invasive and non-invasive tests and must be interpreted by a qualified physician. 2) Patient vitals are as entered by the clinician and not derived from the ECG.

**2D ECHO / COLOUR DOPPLER**

NAME : MR VINOD NAIR  
REF BY: CORP  
CID NO: 2304221962

Age: 44/Y MALE  
DATE : 11.02.2023  
REG LOC: PIMPLE SAUDAGAR PUNE

**M - Mode values**

**Doppler Values**

AORTIC ROOT (mm)	26	PULMONARY VEL (m/sec)	0.8
LEFT ATRIUM (mm)	32	PG (mmHg)	2
RV (mm)	28	AORTIC VALVE M/SEC	1.1
IVS - D (mm)	11	PG (mmHg)	5
LVID - D (mm)	42	MITRAL E VEL (m/sec)	0.8
LVID - S (mm)	22	A VEL (m/ sec)	0.5
LVPW - D (mm)	11	TRICUSPID VEL. (m/sec)	1.5
EJECTION FRACTION (%)	60	PG (mmHg)	10


**OBSERVATION:**

All four cardiac valves are structurally normal.  
All four cardiac chambers normal in dimensions.  
Normal left ventricle size with Good ventricle systolic function .(LVEF-65%)  
No Regional wall motion abnormality.  
Left atrium, Right atrium & Right ventricle are normal in size.  
No pulmonary artery hypertension. RVSP = 20 mmHg.  
Interatrial septum & Interventricular septum are intact.  
No clot/vegetation /pericardial effusion.  
Doppler study revealed mild mitral regurgitation , mild tricuspid regurgitation.  
IVC 1.5 cm, more than 50% pulsatile.  
Left sided aortic arch, No coarctation of aorta.  
No diastolic dysfunction.

**CONCLUSION:**

**Normal left ventricle size with Good ventricle systolic function .(LVEF-65%)  
No pulmonary artery hypertension. RVSP = 20 mmHg.  
Mild mitral valve prolapse.**

Dr. Sonam Shah  
MBBS MD DM Cardiology  
Interventional Cardiologist  
MMC 2010 / 06 / 2218

  
DR SONAM SHAH  
MD DM CARDIOLOGY  
INTERVENTIONAL CARDIOLOGIST



Authenticity Check



Use a QR Code Scanner  
Application To Scan the Code

CID : 2304221962  
Name : Mr VINOD NAIR  
Age / Sex : 44 Years/Male  
Ref. Dr :  
Reg. Location : Pimple Saudagar, Pune Main Centre  
Reg. Date : 11-Feb-2023  
Reported : 11-Feb-2023 / 10:36

**ULTRASOUND ABDOMEN AND PELVIS**

**Liver-** Normal in size (14.3 cm), shape and echo pattern. No focal lesion. Intrahepatic biliary and portal radicals appear normal. Visualized portion of CBD appears normal in calibre. Portal vein appears normal.

**Gall bladder-** Multiple echoreflexive calculi seen in GB, which are mobile & measures 4-5mm in size. No pericholecystic fluid collection/ inflammatory changes seen in present scan.

**Pancreas-** Head and body are visualized and appear normal in size, shape and echo pattern. No focal lesion seen. No peripancreatic collection noted.

**Spleen** – Appears normal in size (9.9cm), shape & echo pattern. No focal lesion seen.

**Kidneys-** Right kidney-10.1 x 4.1cm, Left kidney-9.4 x 4.9cm, both kidneys appear normal in size, shape, position & echo pattern with maintained corticomedullary differentiation. No hydronephrosis, hydroureter or calculus noted.

**Urinary bladder-** Is partially distended & shows normal wall thickness. No calculus or mass lesion is noted.

**Prostate** - appears normal (Vol- 17.3cc) in size, shape and echo-pattern for age. No focal lesion .

No free fluid in abdomen and pelvis. Visualized bowel loops are well distended appear grossly normal and show normal peristalsis. No evidence of enlarged lymph nodes.

**IMPRESSION:**

**Cholelithiasis without changes of cholecystitis.**

*Advice - Clinical correlation and further evaluation if clinically indicated.*

-----End of Report-----

This report is prepared and physically checked by Dr. Divya Chaudhary before dispatch.

**Dr. Divya Chaudhary**  
**MBBS, M.D. RADIODIAGNOSIS,**  
**DNB, RADIOLOGIST**  
**MMC Reg - 2016/01/0064**

Authenticity Check



Use a QR Code Scanner  
Application To Scan the Code

CID : 2304221962  
Name : Mr VINOD NAIR  
Age / Sex : 44 Years/Male  
Ref. Dr :  
Reg. Location : Pimple Saudagar, Pune Main Centre  
Reg. Date : 11-Feb-2023  
Reported : 11-Feb-2023 / 18:47

**X-RAY CHEST PA VIEW**

Trachea is central.  
Slightly prominent bronchovascular markings are noted bilaterally.  
Visualized bilateral lung fields otherwise appear grossly normal.  
Both hila appear normal.  
Cardiac silhouette has grossly normal appearance for age.  
Bilateral costophrenic and cardiophrenic angles appear grossly normal.  
Visualized bony thorax and soft-tissues are grossly normal for age.

**IMPRESSION :**

No other significant abnormality detected

*Advice – Clinical correlation and further evaluation if clinically indicated.*

**Dr. SATYAJEET S. GHODAKE**  
MBBS, MD, DNB, MNAMS.  
Regd. No. 2013/05/1417  
Consultant Radiologist

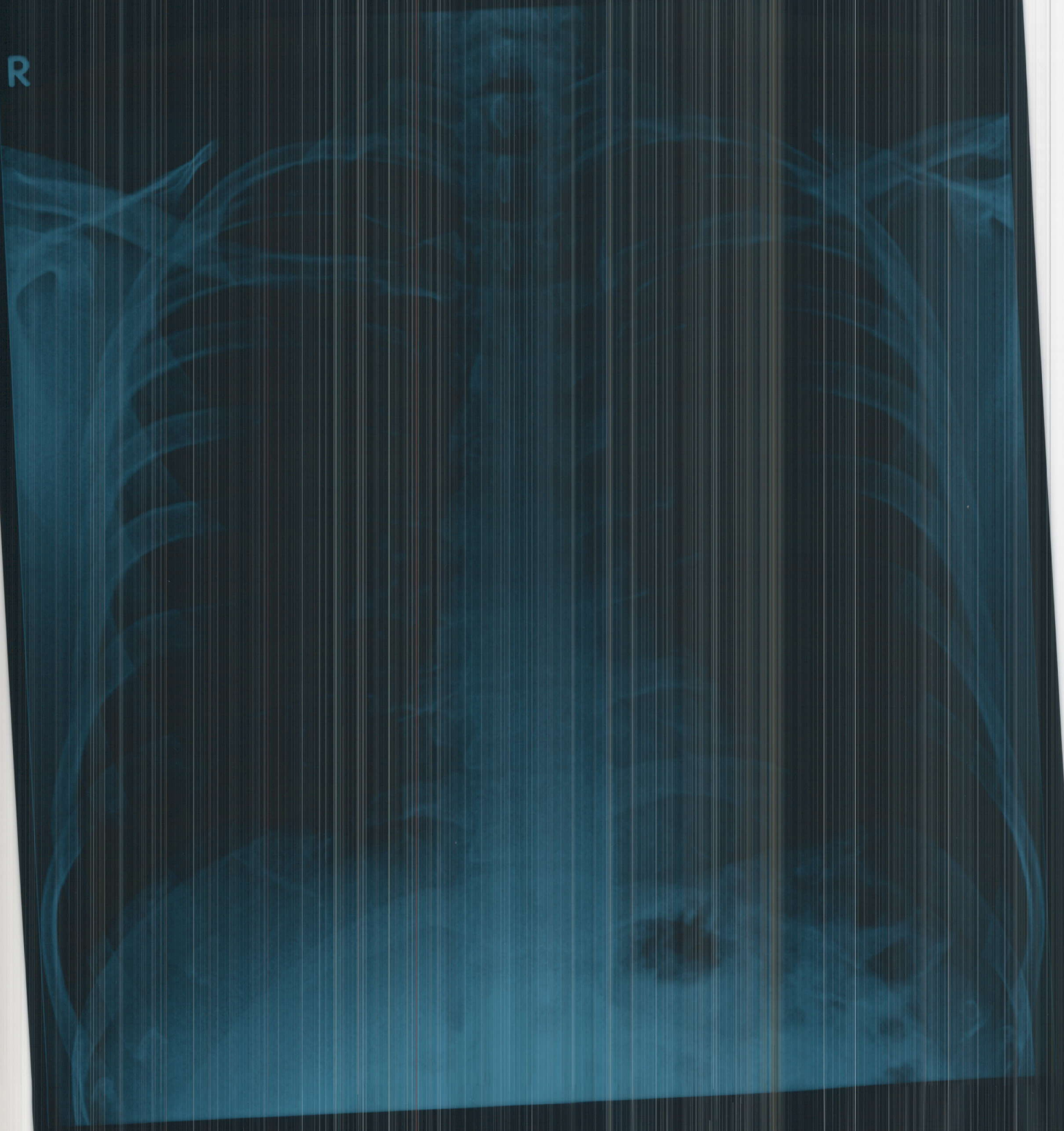-----End of Report-----

This report is prepared and physically checked by DR SATYAJEET before dispatch.  
*Investigations have their own limitations. Solitary radiological investigation never leads to a final diagnosis. They should be always correlated with clinical and pathological examinations.*

Click here to view images [http://3.111.232.119/iRISViewer/NeoradViewer?](http://3.111.232.119/iRISViewer/NeoradViewer?Access)  
Access

sionNo=2023021108550856

R



Mr VINOD NAIR M 044Y 2304221962 CHEST PA 2/11/2023  
SUBURBAN DIAGNOSTICS PIMPLE SAUDAGAR