



Aakriti Labs

3 Mahatma Gandhi Marg, Gandhi Nagar Mod
Tonk Road, Jaipur (Raj.) Ph.: 0141-2710661
www.aakritilabs.com
CIN NO.: U85195RJ2004PTC019563



Name : **Mr. PRATEEK KUMAR MEENA**
Age/Gender: 33 Y/Male
Patient ID : 012205070031
BarcodeNo : 10045923
Referred By : Self

Registration No: 30930
Registered : 07/May/2022 09:36AM
Analysed : 07/May/2022 01:17PM
Reported : 07/May/2022 01:18PM
Panel : Medi Wheel (ArcoFemi
Healthcare Ltd)


USG: WHOLE ABDOMEN (Male)

- LIVER** : Is normal in size, shape and echogenecity.
The IHBR and hepatic radicals are not dilated.
No evidence of focal echopoor/echorich lesion seen.
Portal vein diameter and common bile duct appear normal.
- GALL** : Is normal in size, shape and echotexture. Walls are smooth and
BLADDER regular with normal thickness. There is no evidence of cholelithiasis.
- PANCREAS**: Is normal in size, shape and echotexture. Pancreatic duct is not dilated.
- SPLEEN** : Is normal in size, shape and echogenecity. Splenic hilum is not dilated.
- KIDNEYS** : Right Kidney:-Size: 105x34 mm, Left Kidney:-Size: 103x37 mm.
Bilateral Kidneys are normal in size, shape and echotexture,
corticomedullary differentiation is fair and ratio appears normal.
Pelvi calyceal system is normal. No evidence of hydronephrosis/ nephrolithiasis.
- URINARY** : Bladder walls are smooth, regular and normal thickness.
BLADDER : No evidence of mass or stone in bladder lumen.
- PROSTATE** : Is normal in size, shape and echotexture,
measures: 36x33x27 mm, wt: 17 gms.
Its capsule is intact and no evidence of focal lesion.
- SPECIFIC** : No evidence of retroperitoneal mass or free fluid seen in peritoneal cavity.
No evidence of lymphadenopathy or mass lesion in retroperitoneum.
Visualized bowel loop appear normal. Great vessels appear normal.

IMPRESSION :- **NORMAL STUDY.**

*** End Of Report ***




Dr. Neera Mehta
M.B.B.S., D.M.R.D.
RMCNO.005807/14853



Aakriti Labs

3 Mahatma Gandhi Marg, Gandhi Nagar Mod
Tonk Road, Jaipur (Raj.) Ph.: 0141-2710661
www.aakritilabs.com
CIN NO.: U85195RJ2004PTC019563

Name - Prateek Kumar meena

Age 33/M

mob - 9982315461

VA $\left\{ \begin{array}{l} 6/9 \\ 6/9 \end{array} \right.$

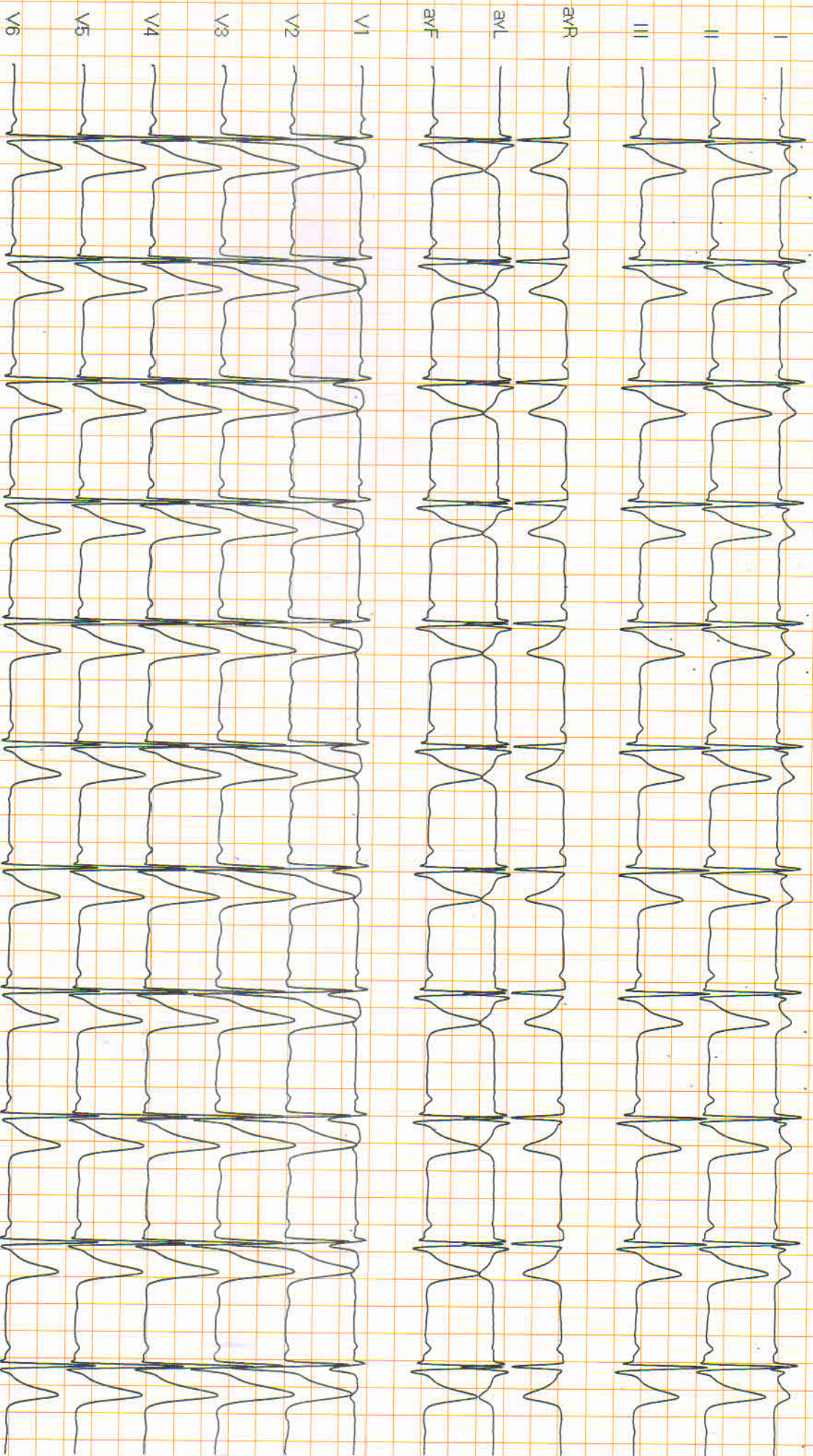
PH $\left\{ \begin{array}{l} 6/6 \\ 6/6 \end{array} \right.$

Ref $\left\{ \begin{array}{l} -0.25 sph \\ -0.25 sph \end{array} \right.$

Colour vision - Normal

R.

Dr. RAKESH SHARMA
M.S.OPTH. B.OPTH
FICLLP



Handwritten signature

DR. ADARSH KUMAR SHAN
 MBBS PGDCC
 RMC NUMBER 0000000000



WEEK KUMAR MEENA / 33 Yrs / M / 0 Cms / 0 Kg Date: 07-May-2022 Refd By : PUS

	Time	Duration	Belt Speed (mph)	Elevation	METS	Rate	% THR Achieved	BP	RPP	PVC	Comments
Upright	00:05	0:01	00.0	00.0	01.0	68	36%	128/85	087	00	
Standing	00:16	0:01	00.0	00.0	01.0	86	46%	128/85	110	00	
HV	00:19	0:03	01.7	10.0	01.1	083	44%	128/85	106	00	
Warm Up	00:21	0:05	01.7	10.0	01.1	086	46%	128/85	110	00	
ExStart	00:23	0:07	01.7	10.0	01.1	096	51%	128/85	122	00	
BRUCE Stage 1	03:23	3:00	01.7	10.0	04.7	104	56%	140/87	145	00	
BRUCE Stage 2	06:23	3:00	02.5	12.0	07.1	118	63%	140/87	165	00	
BRUCE Stage 3	09:23	3:00	03.4	14.0	10.2	146	78%	160/95	233	00	
PeakEx	10:16	0:53	04.2	16.0	11.2	164	88%	160/95	262	00	
Recovery	11:15	1:00	00.0	00.0	04.2	122	65%	170/95	207	00	
Recovery	12:15	2:00	00.0	00.0	01.0	108	58%	173/99	186	00	
Recovery	13:15	3:00	00.0	00.0	01.0	098	52%	160/85	156	00	
Recovery	13:57				00.0	000	0%	---/---	000	00	

Findings :

Exercise Time : 09:54
 Max HR Attained : 164 bpm 88% of Target 187
 Max BP Attained : (Sys) 173/99
 Max Workload Attained : 11.2
 Test End Reasons : Test Complete, Heart Rate Achieved

Report :

FINAL IMPRESSION - TEST IS NEGATIVE FOR INDUCIBLE ISCHAEMIA

DR. ARIF HUSSAIN KHAN
 MBBS, PNDIC
 RMC NUMBER 0000000000

Doctor : **DR. ARIF HUSSAIN KHAN**