

Name	MR.JANARTHANAM R	Patient ID	74748
Accession No	77557	Age/Gender	52Y / Male
Referred By	Dr.MEDIWHEEL	Date	26-Dec-2021

USG REPORT - ABDOMEN AND PELVIS

LIVER:

Liver is normal in size (measures ~ 14.8 cm) and shows increased echotexture.

No focal liver lesion. No intra hepatic biliary radical dilatation seen.

GALL BLADDER:

Is adequately distended. No calculus or cholecystitis seen.

PANCREAS:

Appears normal in size and shows uniform echo texture. The pancreatic duct is normal. No calcifications are seen.

SPLEEN:

Appears normal in size and it shows uniform echo texture. It measures ~ 8.5 cm in long axis.

RIGHT KIDNEY:

Right kidney measures ~ 10.3 x 4.6 cm.

The shape, size and contour of the right kidney appear normal.

Cortico medullary differentiation is within normal. No evidence of pelvicalyceal dilatation.

No calculi seen.

LEFT KIDNEY:

Left kidney measures ~ 10 x 5.3 cm.

The shape, size and contour of the left kidney appear normal.

Cortico medullary differentiation is within normal. No evidence of pelvicalyceal dilatation.

No calculi seen.

Name	MR.JANARTHANAM R	Patient ID	74748
Accession No	77557	Age/Gender	52Y / Male
Referred By	Dr.MEDIWHEEL	Date	26-Dec-2021

USG REPORT - ABDOMEN AND PELVIS

URINARY BLADDER:

Is normal contour. No intra luminal echoes are seen.

Prevoid volume ~ 230 cc.

Postvoid residual urine volume - insignificant (Vol - 45cc).

PROSTATE:

Prostate appears enlarged, Measures ~ 4.6 x 3.6 x 4 cms (Vol - 35 cc).


RIGHT ILIAC FOSSA:

No focal fluid collections seen.

No evidence of hernia seen in anterior abdominal wall.

IMPRESSION:

- ❖ Grade I fatty liver.
- ❖ Grade I prostatomegaly with insignificant PVR.
- Suggested clinical correlation.



**Dr. Lokesh Babu., MDRD.,
Radiologist**

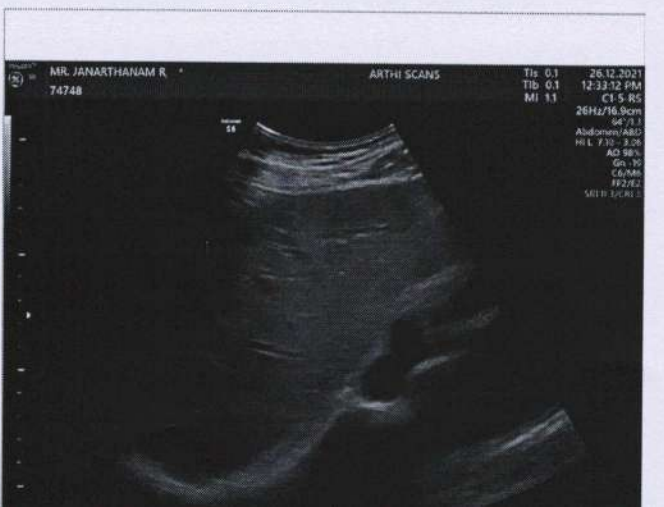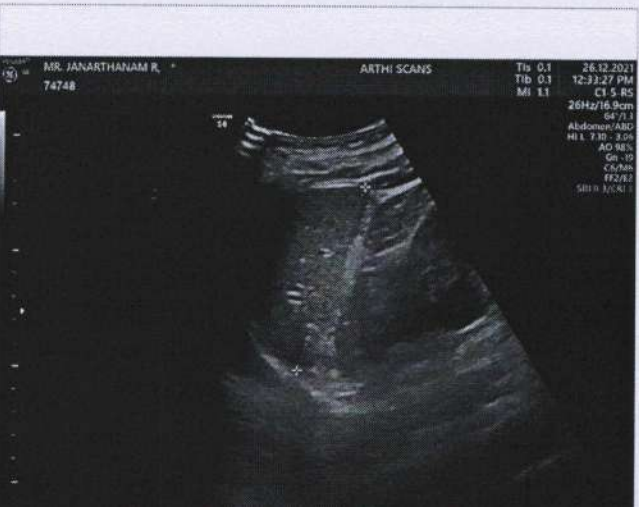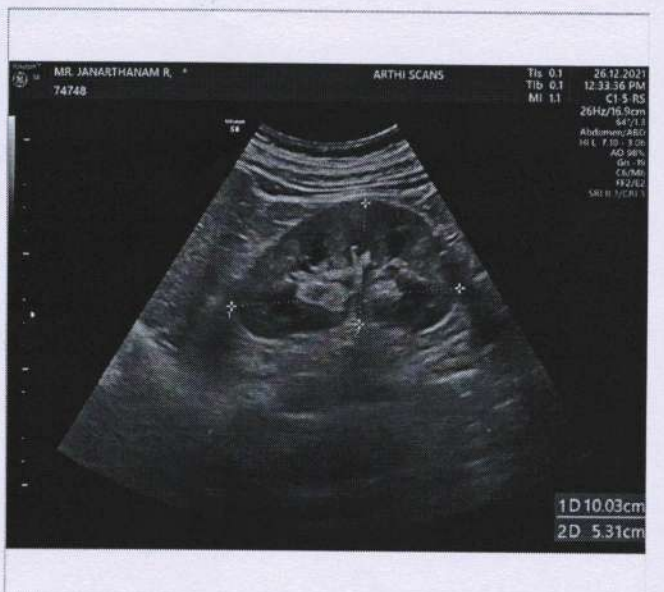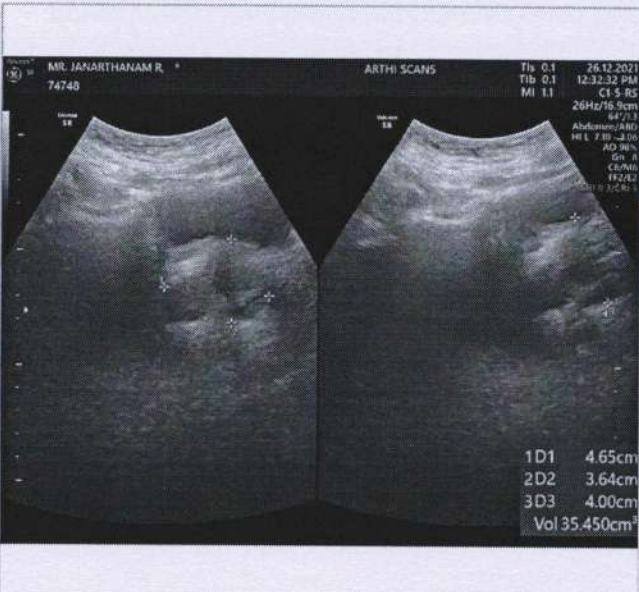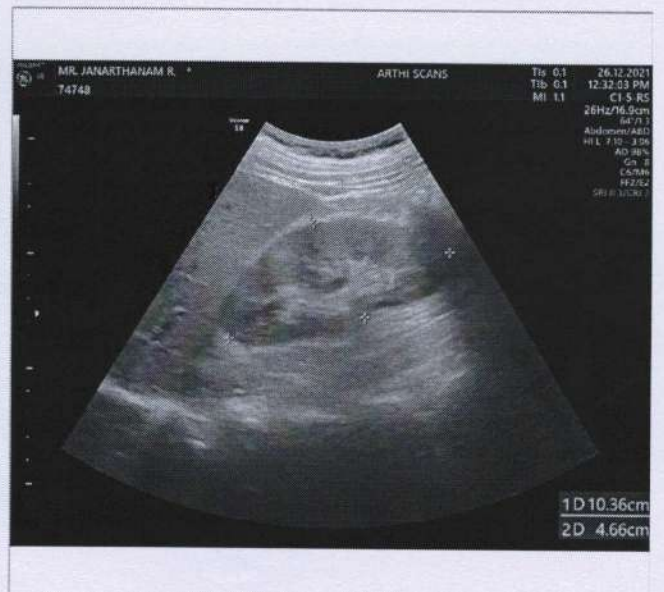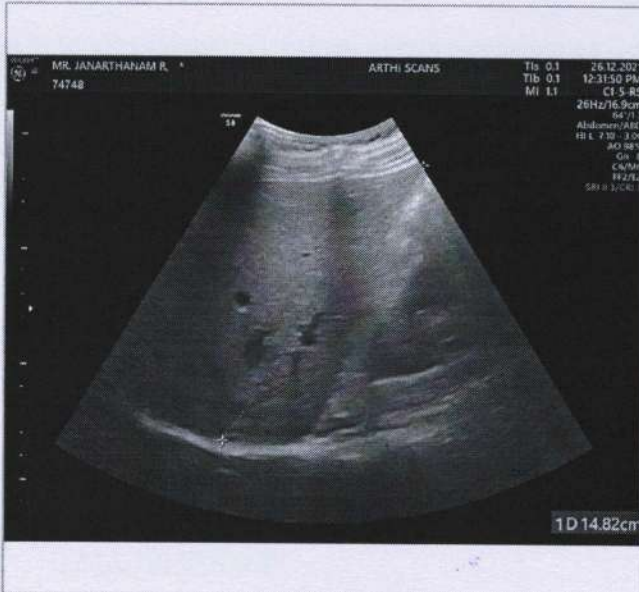Thank you for the courtesy of this referral

Foot Note: Patient's identity is not verified. Report is not valid for medico legal purpose.

Dr. Lokesh Babu, MD.,RD.,
Reg. No: 113030

ARTHI CT AND MRI SCANS

MR. JANARTHANAM R /M 74748 26-Dec-2021 09:40:27 AM



Name	MR.JANARTHANAM R	Patient ID	77557
Accession No	74748	Age/Gender	52 Y / Male
Referred By	Dr.MEDIWHEEL	Date	26-Dec-2021

X-RAY - CHEST PA VIEW

OBSERVATION:

The trachea is central.

The mediastinal and cardiac silhouette are normal.

Cardiothoracic ratio is normal.

Cardiophrenic and costophrenic angles are normal.

Both hila are normal.


Lung zones are clear.

Bones of the thoracic cage are normal.

Soft tissues of the chest wall are normal.

IMPRESSION:

➤ No significant abnormality seen.

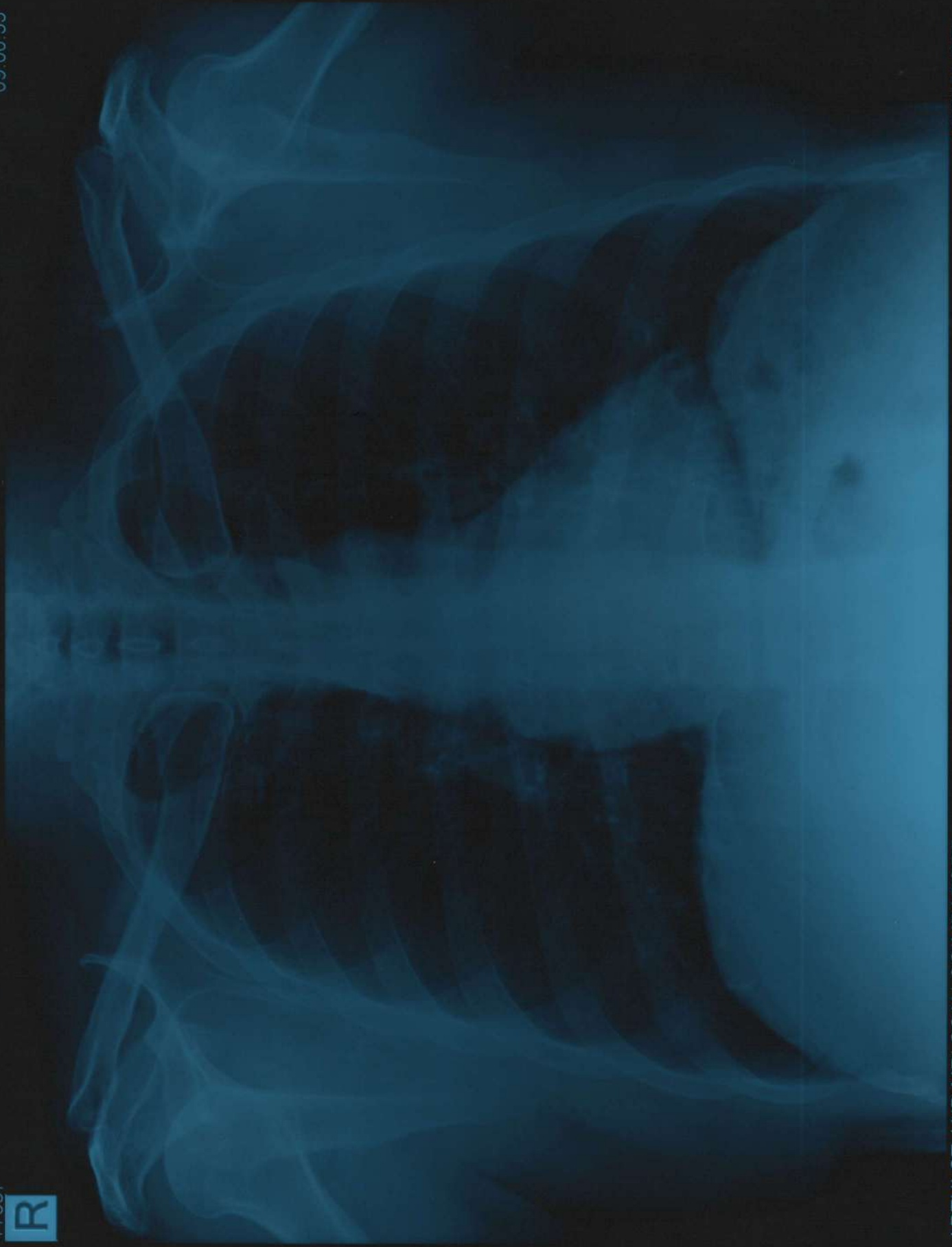


Dr. Abinaya R MDRD.,
Consultant Radiologist

MR JANARTHANAM R 52 Y.,
77557

R

26/12/2021
09:00:33



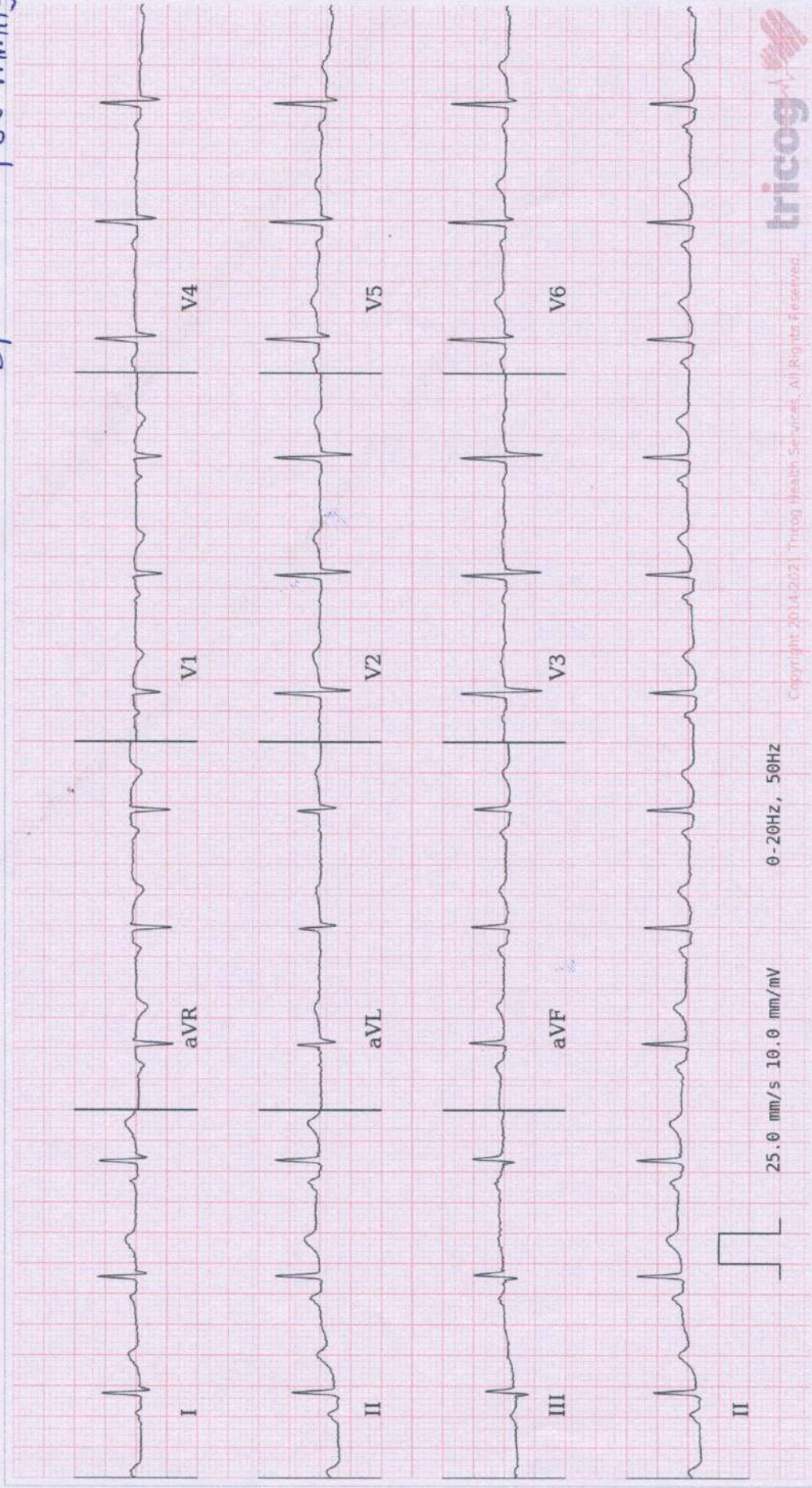


Aarthi CT and MRI Scans, R S Puram West

Age / Gender: 52/Male
Patient ID: 0000074748
Patient Name: MR. JANARTHANAM R

Date and Time: 26th Dec 21 12:04 PM

BP - 130 / 80 mmHg.



AR: 79 bpm VR: 79 bpm QRS: 78 ms QT: 360 ms QTc: 412 ms PRI: 158 ms P-R-T: 66° 54° 45°

Within Normal Limits: Sinus Rhythm, Normal Axis. Please correlate clinically.



Analysis in this report is based on ECG alone and should only be used as an adjunct to clinical history, symptoms and results of other invasive and non-invasive tests and must be interpreted by a qualified physician.



ARTHI SCANS

NAME	MR. JANARTHANAM R	PATIENT ID	74748
ACCESSION NO	77557	AGE/GENDER	52 Y / MALE
REFERRED BY	MEDIWHEEL	DATE	26-DEC-2021

VISION TEST

VISUAL ACUITY (VA)

If The Acuity Can Be Measures, Complete This Box Using Snellen acuities or snellen equivalents or NLP,LP,HM, or distance at which the patient sees the 20/100 letter.

WITH BEST CORRECTION

DISTANCE VISION	
Right	08/11
Left	07/11
Both	07/11

NEAR VISION	
Right	N6
Left	N6
Both	N6

COLOUR VISION	
BOTH	Normal