



PANACEA HOSPITAL

Call Now - 1800-123-3070



A shelter for many hearts A Home for many lives

(An ISO 9001:2008 Certified Organisation)
Lab Attached with CMC Under EQAS Scheme

Dept. of Radiodiagnosis - 32 Slice CT Scan, 3D/4D USG, 2D ECHO, Colour Doppler, Intervention Procedures, Digital X-Ray

Name	MR.NAVIN KUMAR	Sex /Age	46/M	Date	30/10/2023
Ref. by	DR.ASHUTOSH MISHRA(MD)	BSA - m ²		Echo window	fair

Echo - Cardiography

MITRAL VALVE Doppler	AML - normal morphology MV Flow - E - 0.6 A-0.4 E/A=1.25	PML - normal morphology MVA - 0.71 cm ² Mitral Regurgitation - Trivial MR
TRICUSPID VALVE Doppler	Normal TV Flow - No	Tricuspid Regurgitation - No
PULMONARY VALVE Doppler	Normal PV Flow - No	Pulmonary Regurgitation - No
AORTIC VALVE Doppler	Trileaflet-No AV Flow - no	Aortic Regurgitation - No
MEASUREMENT	Aorta - 36.0 (20-38) mm IVS ed - 12.6 (6-12) mm LVID ed - 53.7 (35-55) mm LVPW ed - 9.1 (6-12) mm OA - 7 (> 5) mm	LA - 41.7 (24-32) mm IVS es - 16.0 (6-12) mm LVID es - 31.4 (24-40) mm LVPW es - 17.6 (6-12) mm EPSS - 4 (< 9) mm

CONCLUSION **Concentric LVH present, (IVS & LVPW both are thickened)**
LA enlarge, rest all other cardiac chamber dimensions are WNL
Trivial MR is present, rest other valve are WNL
 Good LV systolic function present Modified Simpson's method (4C, 2C) (LVEF-72%)
 No diastolic dysfunction present (E/A = 1.25)
 RWMA present
 No pericardial effusion
 Intact IAS / IV
 No PAH
 No intra cardiac mass /thrombus /vegetation

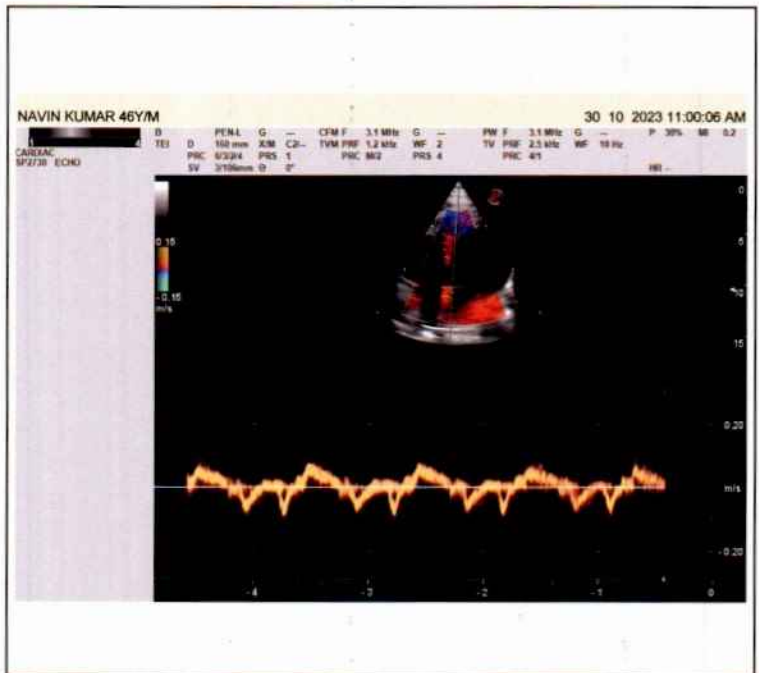
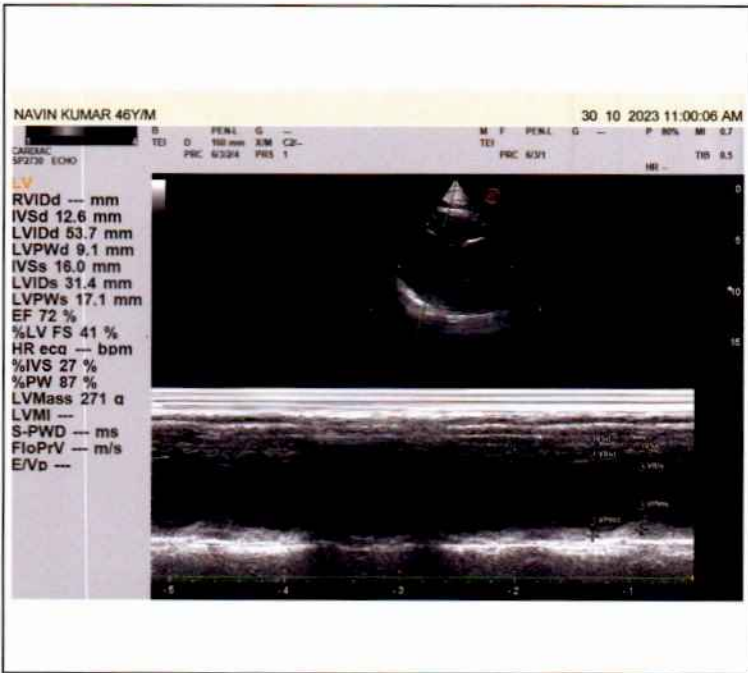
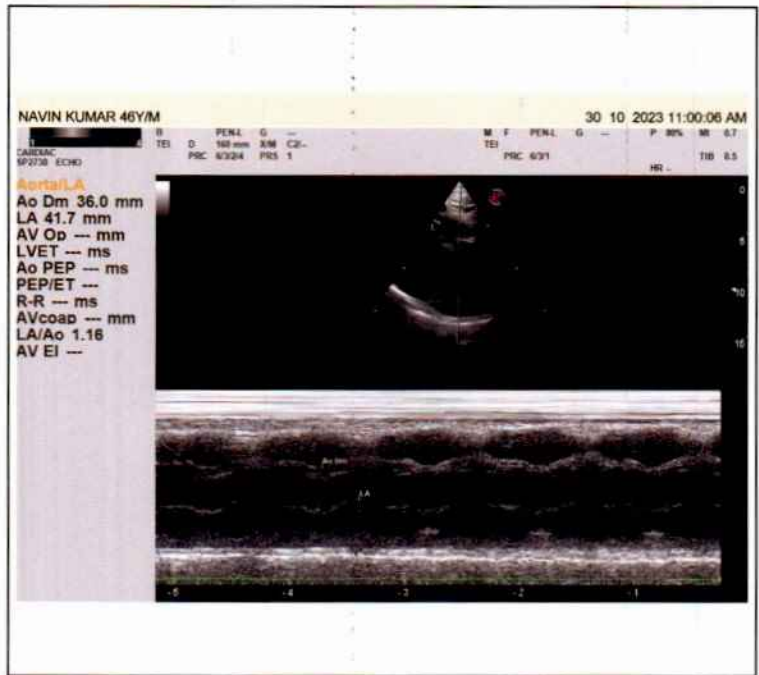
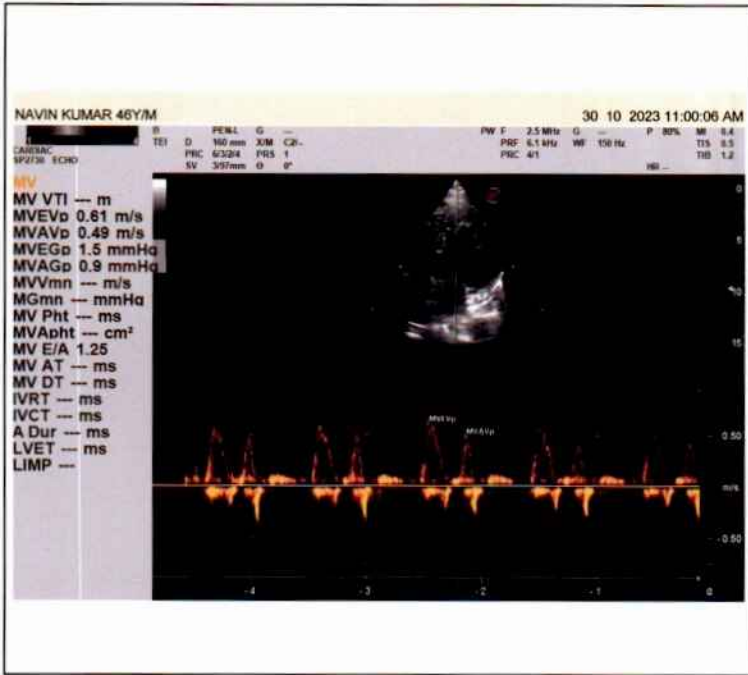
IMPRESSION **Hypertensive Heart Disease**
Concentric LVH present, (IVS & LVPW both are thickened)
LA enlarge, rest all other cardiac chamber dimensions are WNL
Trivial MR is present, rest other valve are WNL
 Good LV systolic function present Modified Simpson's method (4C, 2C) (LVEF-72%)
 No diastolic dysfunction present (E/A = 1.25)
 Rest all other finding are WNL

Niral Mishra
 Physician Assistant
 (PHIRE)

Dr. Pallavi Mishra
 MBBS, MD (GENERAL MEDICINE)
 MCI Reg. No. 52033

Disclaimer: This report is not valid for Madicolegal or Judicial Purpose. Radiological diagnosis is solely interpretation of images produced by tissue & may not be always conclusive.

Address : B36/44 B4 Kabir Nagar (Near Sanjay Shiksha Niketan), Durgakund, Varanasi
 Mobile : 9554572190 / 9453837595 / Recpn, 9389994334
 Email : dramishra@gmail.com, drpallaviojha@gmail.com, Website : www.piire.org





भारतीय विशिष्ट पहचान प्राधिकरण

Unique Identification Authority of India




पता:

द्वारा: उमेश प्रसाद गुप्ता, चितईपुर बी एच यू रोड,
इन्दरलोक अस्पताल के पास, चितईपुर, वाराणसी,
वाराणसी,
उत्तर प्रदेश - 221005

Address:

C/O: Umesh Prasad Gupta, chitaipur bhu
road, near indralok hospital, chitaipur,
Varanasi, Varanasi,
Uttar Pradesh - 221005



6380 7153 9886

VID : 9174 3057 9911 7110



1947



help@uidai.gov.in



www.uidai.gov.in



GPS Map Camera

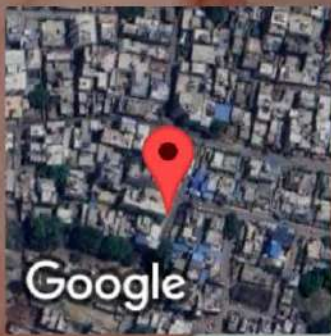Varanasi, Uttar Pradesh, India

B36/44B-3, Padampuri Colony, Durgakund, Nagwa, Varanasi, Uttar Pradesh
221005, India

Lat 25.289174°

Long 82.993387°

30/10/23 04:05 PM GMT +05:30



Google



भारत सरकार
Government of India



Download Date: 18/08/2021



नवीन कुमार
Naveen Kumar
जन्म तिथि/DOB: 01/01/1975
पुरुष/ MALE

Issue Date: 28/06/2021

6380 7153 9886

VID : 9174 3057 9911 7110

मेरा **आधार**, मेरी पहचान

Facilities:

All clinical Biomedical & Hematology Investigations including Bone Marrow Examination VPT, Podiascan & Complete Foot Care (First Time in Purvanchal) All Hormonal Investigation by Chemiluminescent Method Visceral Fat by (AB-140) Ambulatory BP Monitoring CGMS & Insulin Pump Available PFT, 2D-ECHO (Color Doppler), Holter, TMT, Cardiac-3 available VIA, VILI, Colposcopy available Special Endocrinological Investigation Protocols.

ISO 9001:2008 Certified
Mobile: 9389994334, 9554572190, 9453837595



Panacea Pathology

Clinical Reference Lab

Persistence, Preparedness and Precision
EQAS (CMC Vellore Attached) & IQAS System
पूर्वांचल की सर्वोत्तम गुणवत्ता वाली पैथोलॉजी

UHID No	:- UD-23240003721	Booking No/Date	:- 71 / 30-Oct-2023 02:29 PM
Patient Name	:- Mr NAVIN KUMAR	Age/Sex	:- 48 Y/M
Father	:-	Reg No	:- 23240003721
Address	:- CHITAIPUR, varanasi	Mobile No	:- 7380800880
Consultant	:- Dr ASHUTOSH MISHRA (MD(MEDICINE),IMS,BHU)		

Investigations	Observations	Biological Ref. Interval	Unit
----------------	--------------	--------------------------	------

HAEMATOLOGY

CBC

HAEMOGLOBIN <small>DefaultMethod / test Machine</small>	18.1 (1)	13.00 - 16.00	gm/dl
TLC <small>Methology / Carm</small>	7,800	4000.00 - 11000.00	Cells/cumm.
DLC DIFFERENTIAL LEUCOCYTE COUNT			
NEUTROPHILS	57	40.00 - 75.00	%
LYMPHOCYTES	39	20.00 - 45.00	%
EOSINOPHILS	02	1.00 - 6.00	%
MONOCYTES	02	2.00 - 10.00	%
BASOPHILS	00	<1-2	%
PLATELET COUNT	1.85	1.50 - 4.10	lacs /cumm
PCV	56.4	33.00 - 42.00	%
RBC <small>Methology / Carm</small>	6.45	4.50 - 5.50	million/cumm
MCV(MEAN CELL VOLUME)	87.5	83.00 - 101.00	fl
MCH(MEAN CELL HAEMOGLOBIN)	28.1	27.00 - 32.00	pg
MCHC	32.1	31.50 - 35.00	gm%

BIOCHEMISTRY

BLOOD SUGAR FASTING


GLUCOSE	101.0	60.00 - 100.00	mg/dl
---------	--------------	----------------	-------

Lab Technician

Timing : 24/7 hrs

This Report is not valid for medico legal purpose

Note: These tests have technical limitations. Clinico-pathological interpretation is necessary. In case of any disparity test may be repeated immediately.


DR. UMESH KUMAR
MBBS, MD (PATHOLOGIST)
MCI Reg. No. 41413
M.D., Pathology

Facilities:

All clinical Biomedical & Hematology Investigations including Bone Marrow Examination
 VPT, Podiascan & Complete Foot Care (First Time in Purvanchal)
 All Hormonal Investigation by Chemiluminescent Method
 Visceral Fat by (AB-140) Ambulatory BP Monitoring
 CGMS & Insulin Pump Available
 PFT, 2D-ECHO (Color Doppler), Holter, TMT, Cardiac-3 available
 VIA, VILI, Colposcopy available
 Special Endocrinological Investigation Protocols.

ISO 9001:2008 Certified
 Mobile: 9389994334, 9554572190, 9453837595



Panacea Pathology

Clinical Reference Lab

Persistence, Preparedness and Precision
 EQAS (CMC Vellore Attached) & IQAS System
 पूर्वांचल की सर्वोत्तम गुणवत्ता वाली पैथोलॉजी

UHID No :- UD-23240003721 **Booking No/Date** :- 71 / 30-Oct-2023 02:29 PM
Patient Name :- Mr NAVIN KUMAR **Age/Sex** :- 48 Y/M
Father :- **Reg No** :- 23240003721
Address :- CHITAI PUR, varanasi **Mobile No** :- 7380800880
Consultant :- Dr ASHUTOSH MISHRA (MD(MEDICINE),IMS,BHU)

Investigations	Observations	Biological Ref. Interval	Unit
PRE-DIABETICS(IMPAIRED FASTING TOLER)	-	100.00 - 125.00	mg/dl
DIABETICS	-	upto 126	mg/dl
TARGET IN DM	-	80.00 - 130.00	mg/dl

HAEMATOLOGY

ESR 10.0 0.00 - 15.00 mm at 1 hr
HBA1C -(BY GOLD STANDARD METHOD :HPLC) 6.4
 Normal: 4.0 - 5.4
 Prediabetic : 5.5 -6.3
 Diabetes mellitus := 6.4

IMMUNOLOGY

THYROID PROFILE (T3,T4,TSH)

T3 0.89 0.60 - 1.81 ng/ml
T4 7.2 4.50 - 10.90 ug/dl
TSH 1.10 0.39 - 6.10 uIU/mL

THYROID PROFILE

Consulting Pathologist
DR. UMESH KUMAR
 M.B.B.S (MD (PATHOLOGIST))
 MCI Reg. No. 81113
 M.D., Pathology

Lab Technician

Timing : 24/7 hrs

This Report is not valid for medico legal purpose

Note: These tests have technical limitations. Clinico-pathological interpretation is necessary. In case of any disparity test may be repeated immediately.

Facilities:

All clinical Biomedical & Hematology Investigations including Bone Marrow Examination VPT, Pediascan & Complete Foot Care (First Time in Purvanchal) All Hormonal Investigation by Chemiluminescent Method Visceral Fat by (AB-140) Ambulatory BP Monitoring CGMS & Insulin Pump Available PFT, 2D-ECHO (Color Doppler), Holter, TMT, Cardiac-3 available VIA, VILI, Colposcopy available Special Endocrinological Investigation Protocols.

ISO 9001:2008 Certified

Mobile: 9389994334, 9554572190, 9453837595



Panacea Pathology

Clinical Reference Lab

Persistence, Preparedness and Precision
EQAS (CMC Vellore Attached) & IQAS System
पूर्वांचल की सर्वोत्तम गुणवत्ता वाली पैथोलॉजी

UHID No :- UD-23240003721 **Booking No/Date** :- 71 / 30-Oct-2023 02:29 PM
Patient Name :- Mr NAVIN KUMAR **Age/Sex** :- 48 Y/M
Father :- **Reg No** :- 23240003721
Address :- CHITAIPUR , varanasi **Mobile No** :- 7380800880
Consultant :- Dr ASHUTOSH MISHRA (MD(MEDICINE),IMS,BHU)

Investigations	Observations	Biological Ref. Interval	Unit
----------------	--------------	--------------------------	------

Remarks:

- Total serum T3 and T4 concentration is dependent upon a multiplicity of factors: thyroid gland function and its regulation, thyroxin binding globulin (TBG) concentration, and the binding of T3 & T4 to TBG. Thus, total T3 & T4 concentration alone is not sufficient to assess the clinical status.
- A decrease in total tri - iodothyronine values is found with protein - wasting diseases, certain liver diseases & administration of testosterone, diphenylhydantoin or salicylates
- Serum TSH values may be elevated by pharmacological intervention, Domperidone, amiodazon, iodide, Phenobarbital, phenytoin have been reported to increase TSH levels

BIOCHEMISTRY

YGGT	24.0	10.00 - 50.00	U/L
LFT (LIVER FUNCTION TESTS)			
TOTAL BILIRUBIN	0.65	0.00 - 1.20	mg/dl
DIRECT BILIRUBIN	0.21	0.00 - 0.30	
INDIRECT BILIRUBIN	0.42	0.20 - 0.70	mg/dl
SGOT	27.0	2.00 - 31.00	U/L
SGPT	32.0	10.00 - 45.00	U/L
ALKALINE PHOSPHATASE	59.0	25.00 - 140.00	U/L
TOTAL PROTIENS	6.5	6.60 - 8.70	g/dl
ALBUMIN	3.7	3.50 - 5.20	gm%

Umesh Kumar
Consulting Pathologist
DR. UMESH KUMAR
MBBS, MD (PATHOLOGIST)
M.C.D. Pathology

Lab Technician

Timing : 24/7 hrs

This Report is not valid for medico legal purpose

Note: These tests have technical limitations. Clinico-pathological interpretation is necessary. In case of any disparity test may be repeated immediately.

Facilities:

All clinical Biomedical & Hematology Investigations including Bone Marrow Examination VPT, Pediascan & Complete Foot Care (First Time in Purvanchal) All Hormonal Investigation by Chemiluminescent Method Visceral Fat by (AB-140) Ambulatory BP Monitoring CGMS & Insulin Pump Available PFT, 2D-ECHO (Color Doppler), Holter, TMT, Cardiac-3 available VIA, VILI, Colposcopy available Special Endocrinological Investigation Protocols.

ISO 9001:2008 Certified
Mobile: 9389994334, 9554572190, 9453837595



Panacea Pathology

Clinical Reference Lab

Persistence, Preparedness and Precision
EQAS (CMC Vellore Attached) & IQAS System
पूर्वांचल की सर्वोत्तम गुणवत्ता वाली पैथोलॉजी

UHID No :- UD-23240003721 **Booking No/Date** :- 71 / 30-Oct-2023 02:29 PM
Patient Name :- Mr NAVIN KUMAR **Age/Sex** :- 48 Y/M
Father :- **Reg No** :- 23240003721
Address :- CHITAIPUR , varanasi **Mobile No** :- 7380800880
Consultant :- Dr ASHUTOSH MISHRA (MD(MEDICINE),IMS,BHU)

Investigations	Observations	Biological Ref. Interval	Unit
GLOBULIN	2.8	1.50 - 3.60	gms/dl
LIPID PROFILE			
TOTAL CHOLESTROL	118.0	Desirable : - < 200 mg/dL Borderline: - 200 - 239 mg/dL High : - > 240mg/dL	mg/dl
TRIGLYCERIDES	131.0	35.00 - 160.00	mg/dl
HDL CHOLESTROL	32.0	35.30 - 79.50	mg/dl
LDL CHOLESTROL	59.8	<130	mg/dl
VLDL	26.20	<40	mg/dl
CHOLESTROL/ HDL RATIO	3.69	<3.0 LOW RISK, 3.0-5.0 AVG RISK, >5.0 HIGH RISK	ratio
LDL/HDL RATIO	1.87	<3	ratio
RFT (RENAL FUNCTION TESTS)			
BLOOD UREA	24.0	10.00 - 50.00	mg/dl
SERUM CREATININE	1.03	0.60 - 1.60	mg/dl
URIC ACID	4.62	3.60 - 7.70	mg/dl

* END OF REPORT *

Signature

Consulting Pathologist
DR. UMESH KUMAR
MBBS (D. Pathology)
MCI Reg. No. 41115
M.D., Pathology

Lab Technician

Timing : 24/7 hrs

This Report is not valid for medico legal purpose

Note: These tests have technical limitations. Clinico-pathological interpretation is necessary. In case of any disparity test may be repeated immediately.

Facilities:

All clinical Biomedical & Hematology Investigations including Bone Marrow Examination
 VPT, Padiascan & Complete Foot Care (First Time in Purvanchal)
 All Hormonal Investigation by Chemiluminescent Method
 Visceral Fat by (AB-140) Ambulatory BP Monitoring
 CGMS & Insulin Pump Available
 PFT, 2D-ECHO (Color Doppler), Holter, TMT, Cardiac-3 available
 VIA, VILI, Colposcopy available
 Special Endocrinological Investigation Protocols.

ISO 9001:2008 Certified
 Mobile: 9389994334, 9554572190, 9453837595



Panacea Pathology

Clinical Reference Lab

Persistence, Preparedness and Precision
 EQAS (CMC Vellore Attached) & IQAS System
 पूर्वांचल की सर्वोत्तम गुणवत्ता वाली पैथोलॉजी

UHID No	:- UD-23240003721	Booking No/Date	:- 71 / 30-Oct-2023 02:29 PM
Patient Name	:- Mr NAVIN KUMAR	Age/Sex	:- 48 Y/M
Father	:-	Reg No	:- 23240003721
Address	:- CHITAI PUR, varanasi	Mobile No	:- 7380800880
Consultant	:- Dr ASHUTOSH MISHRA (MD(MEDICINE),IMS,BHU)		

Investigations	Observations	Biological Ref. Interval	Unit
----------------	--------------	--------------------------	------

URINE EXAMINATION

URINE ROUTINE EXAMINATION

PHYSICAL EXAMINATION

QUANTITY 25 ml

COLOR STRAW CLEAR YELLOW
Methodology

APPEARANCE CLEAR CLEAR
DefaultMethod

CHEMICAL EXAMINATION

SPECIFIC GRAVITY 1.015 1.01 - 1.03

PH 5.5 4.60 - 8.00

GLUCOSE NIL 60.00 - 100.00 mg/dl

PROTEIN- 1(+)

MICROSCOPIC EXAMINATION

PUS CELLS 02-03 2.00 - 3.00 /HPF

RBCS (RED BLOOD CELLS) NIL 4.50 - 5.50 /HPF

EPITHELIAL CELLS 03-05 /HPF

CASTS ABSENT ABSENT

CRYSTALS ABSENT ABSENT

* END OF REPORT *

Signature

Consulting Pathologist
 DR. GANESH KUMAR
 MBBS, MD (PATHOLOGY)
 MCI Reg. No. 41413
 M.D., Pathology

Lab Technician

Timing : 24/7 hrs

This Report is not valid for medico legal purpose

Note: These tests have technical limitations. Clinico-pathological interpretation is necessary. In case of any disparity test may be repeated immediately.

Facilities:

All clinical Biomedical & Hematology Investigations including Bone Marrow Examination
 VPT, Podiascan & Complete Foot Care (First Time in Purvanchal)
 All Hormonal Investigation by Chemiluminescent Method
 Visceral Fat by (AB-140) Ambulatory BP Monitoring
 CGMS & Insulin Pump Available
 PFT, 2D-ECHO (Color Doppler), Holter, TMT, Cardiac-3 available
 VIA, VILI, Colposcopy available
 Special Endocrinological Investigation Protocols.

ISO 9001:2008 Certified
 Mobile: 9389994334, 9554572190, 9453837595



Panacea Pathology

Clinical Reference Lab

Persistence, Preparedness and Precision
 EQAS (CMC Vellore Attached) & IQAS System
 पूर्वांचल की सर्वोत्तम गुणवत्ता वाली पैथोलॉजी

UHID No	: - UD-23240003721	Booking No/Date	: - 71 / 30-Oct-2023 03:10 PM
Patient Name	: - Mr NAVIN KUMAR	Age/Sex	: - 48 Y/M
Father	: -	Reg No	: - 23240003721
Address	: - CHITAIPUR , varanasi	Mobile No	: - 7380800880
Consultant	: - Dr ASHUTOSH MISHRA (MD(MEDICINE),IMS,BHU)		

Investigations	Observations	Biological Ref. Interval	Unit
----------------	--------------	--------------------------	------

BIOCHEMISTRY

PPBS(POST PRANDIAL BLOOD SUGAR)

POST PRANDIAL BLOOD GLUCOSE(2 HR AFTER MEAL)	136.0	110.00 - 150.00	mg/dl
IGT(2 HR 75GM GLUCOSE)	-	140.00 - 199.00	mg/dl
DIABETES	-	upto200	mg/dl
TARGET IN DM	-	80.00 - 130.00	mg/dl

* END OF REPORT *

Dr. Ashutosh Mishra
 MBBS, MD (PATHOLOGIST),
 MCI Reg. No. 44419
 M.D., Pathology

Lab Technician

Timing : 24/7 hrs

This Report is not valid for medico legal purpose

Note: These tests have technical limitations. Clinico-pathological interpretation is necessary. In case of any disparity test may be repeated immediately.



PANACEA HOSPITAL

B 36/44 F.K KABIR NAGAR, DURGAKUND
TOLLFREE NO-18001233070. Whatsapp No - 8795832852
www.piire.org
panaceaquery@gmail.com|panaceahospitalit@gmail.com



OP Slip

Print Date : 30-Oct-2023 01:46PM



UHID No :- UD-23240003721	OP No :- OP-23240011933	OP Date :- 30 Oct 2023 1:45PM
Patient Name :- Mr NAVIN KUMAR	Age/Sex :- 48 Y/Male	Mobile No :- 7380800880
Father :-	Department :- DENTAL	
Pay Type :- Cash	Consultant :- Dr SHRUTI MISHRA (AA)	
Token No :- NOR. - 1	Paid/Bal :- 0.00 /30.00	
Patient Type :- Normal		
Address :- CHITAI PUR, varanasi		

BP 140/100 :- /
 height :- 170
 Weight (kg) :- 85
 BMI :-
 NC - 45
 CH - 111
 WCL - 108
 PEFr - 250
 SPO₂ - 98
 PR - 75

Rx

- Pt came for routine dental check up.

O/E - stain/calculus - (++)

P/D - Chronic gen gingivitis

Ry

- chlorhexidine mouth wash (10ml / 1g / 1g of water)



Printed By : Ms. RENUKA

Created By : Ms. RENUKA



PANACEA HOSPITAL

B 36/44 F.K KABIR NAGAR, DURGAKUND
TOLLFREE NO-18001233070. Whatsapp No - 8795832852
www.piire.org
panaceaquery@gmail.com|panceahospitalit@gmail.com



OP Slip

Print Date : 30-Oct-2023 02:37PM



UHID No	:- UD-23240003721	OP No	:- OP-23240011934	OP Date	:- 30 Oct 2023 1:46PM
Patient Name	:- Mr NAVIN KUMAR	Age/Sex	:- 48 Y/Male	Mobile No	:- 7380800880
Father	:-	Department	:- GENERAL MEDICINE		
Pay Type	:- Cash	Consultant	:- Dr ASHUTOSH MISHRA (MBBS MD IMS BHU,MD)		
Token No	:- NOR. - 7	Paid/Bal	:- 0.00 /600.00		
Patient Type	:- Normal				
Address	:- CHITAI PUR, varanasi				

140/100
BP :- /
height :- 170
Weight (kg) :- 85
BMI :-
NK - 45
CH - 111
WC - 108
PEFR - 250
SPO₂ - 98
PR - 75

Rx

Pre-Diabetes
COPD

Direct 1000mg/d. (2.0)

Rx.

Es. Rybuteo (3mg) SONDY

Rev. Airle FF (20)

00 ——— 00.

Glycolf

Es. Doxolon. (400) ON

Es. Montelid → 13

Es. Dicheo (10) ON

Es. Ranney (20) ON

AEN

YRET Chart

30%

Printed By : Mr NITIN YADAV

Created By : Ms. RENUKA

Dr. Ashutosh Mishra
MBBS, MD (GENERAL MEDICINE)
MCI, Reg. No. 45695



PANACEA HOSPITAL

B 36/44 F.K KABIR NAGAR, DURGAKUND
TOLLFREE NO-18001233070. Whatsapp No - 8795832852
www.piire.org
panaceaquery@gmail.com|panaceahospital@gmail.com



OP Slip

Print Date : 30-Oct-2023 01:46PM



UHID No :- UD-23240003721	OP No :- OP-23240011935	OP Date :- 30 Oct 2023 1:46PM
Patient Name :- Mr NAVIN KUMAR	Age/Sex :- 48 Y/Male	Mobile No :- 7380800880
Father :-	Department :- OPHTHALMOLOGY	
Pay Type :- Cash	Consultant :- Dr Santosh Verma (MBBS,MS)	
Token No :- NOR. - 2	Paid/Bal :- 0.00 /350.00	
Patient Type :- Normal		
Address :- CHITAIPUR, varanasi		

BP :- 140/100
 height :- 170
 Weight (kg) :- 85
 BMI :-
 NC - 45
 CH - 111
 WC - 108
 PEFr - 250
 SPO₂ - 98
 PR - 75

Rx

with glass.

VA < 6/6 P
6/6

Bath Eye with glass 6/6.

NV < 6/6 ⓧ
6/6 ⓧ

or Lubstone ultra
0000

Printed By : Ms. RENUKA
Created By : Ms. RENUKA





 GPS Map Camera

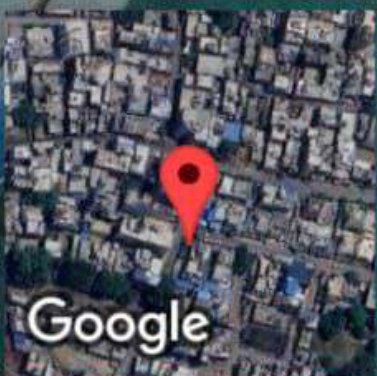Varanasi, Uttar Pradesh, India

B36/44B-3, Padampuri Colony, Durgakund, Nagwa, Varanasi,
Uttar Pradesh 221005, India

Lat 25.289186°

Long 82.993497°

30/10/23 04:43 PM GMT +05:30





PANACEA HOSPITAL

Call Now - 1800-123-3070



A shelter for many hearts A Home for many lives

(An ISO 9001:2008 Certified Organisation)

Lab Attached with CMC Under EQAS Scheme

Dept. of Radiodiagnosis - 32 Slice CT Scan, 3D/4D USG, 2D ECHO, Colour Doppler, Intervention Procedures, Digital X-Ray

PATIENT'S NAME : NAVIN KUMAR AGE/SEX: 46 Y/M
REF. BY : Dr. ASHUTOSH MISHRA (MD) Monday, October 30, 2023

U/S. WHOLE ABDOMEN

- LIVER** : Liver is enlarge in size 167mm, diffuse increased echogenicity of liver parenchyma - Grade I fatty liver. Intra hepatic biliary radicals are normal. Portal venous channels are normal.
- G. B.** : Gall bladder is normal in size, lumen is clear. Wall thickness normal..
- C.B.D.** : C.B.D. is normal in caliber.
- PANCREAS** : Pancreas is normal in size, shape and echotexture. No evidence of any inflammatory disease or mass.
- SPLEEN** : Spleen is normal in size (11.0cm), shape and echotexture.
- Rt. KIDNEY** : Normal in size, shape and echotexture. Renal sinus is normal Cortico medullary differentiation is normal. P. C. system is normal.
- Lt. KIDNEY** : Normal in size, shape and echotexture. Renal sinus is normal Cortico medullary differentiation is normal. P. C. system is normal.
- URI. BLADDER** : Urinary bladder is normal in size, position. Wall thickness normal. No evidence of calculus or mass.
- URI. BLADDER** : Urinary bladder is normal in size, position. Wall thickness normal. No evidence of calculus or mass.
- PROSTATE** : Prostate is normal in size 23X35X29mm Vol 12.6ml. No ascites & retro peritoneal lymphadenopathy seen.

IMPRESSION :

- GRADE I FATTY LIVER WITH HEPATOMEGALY

Dr. Ashutosh Mishra

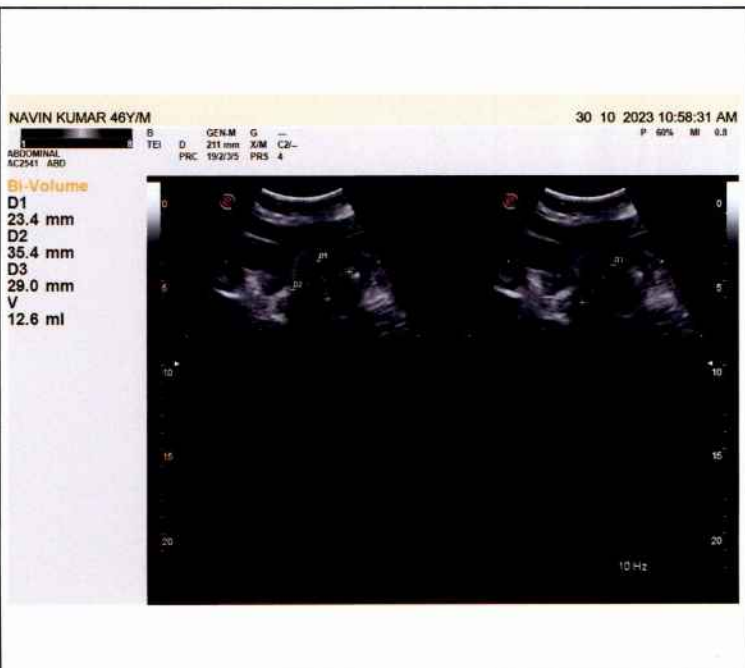
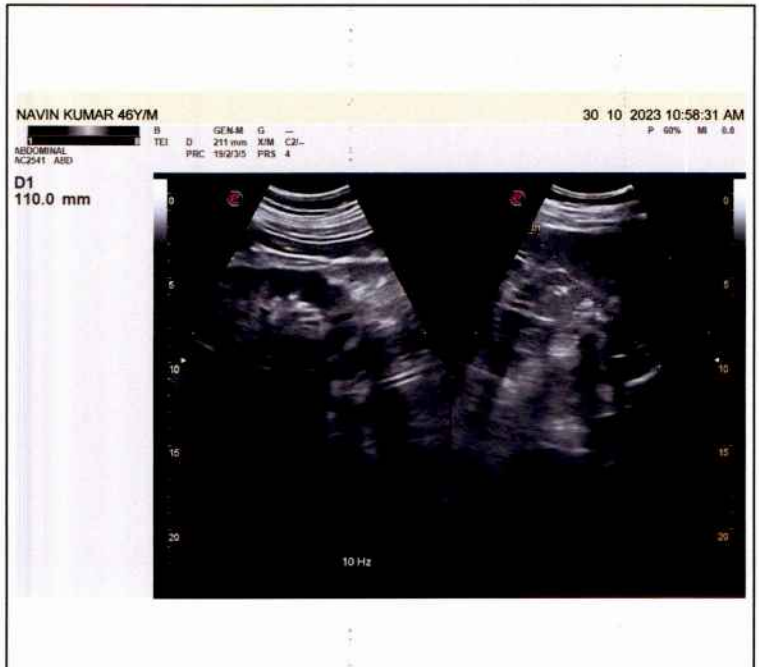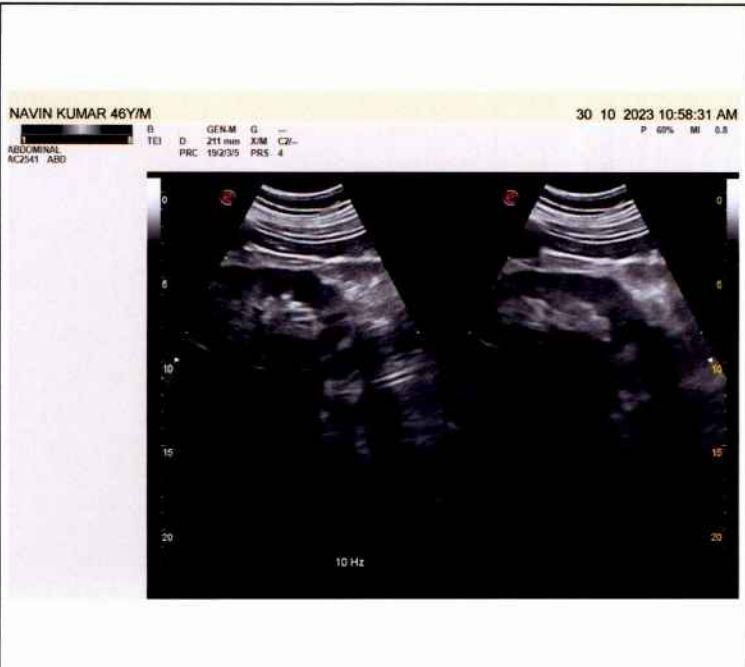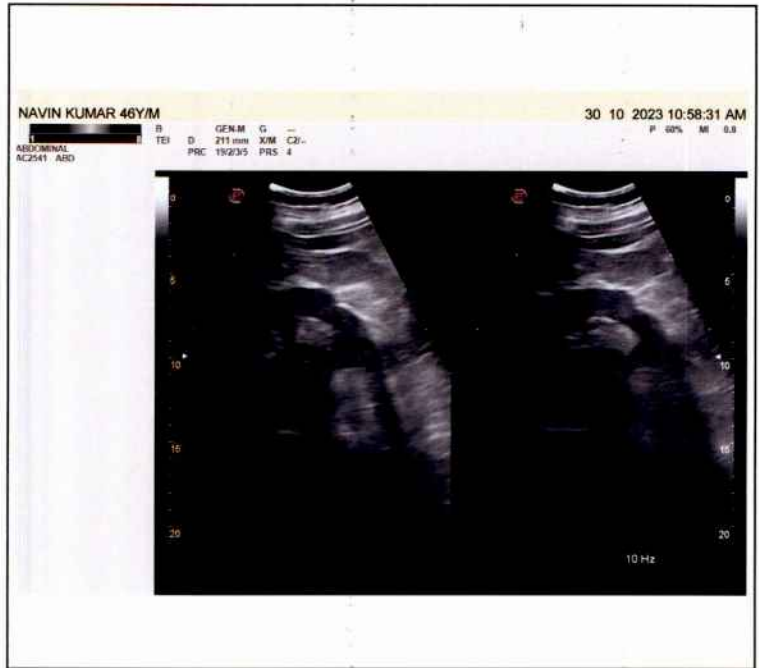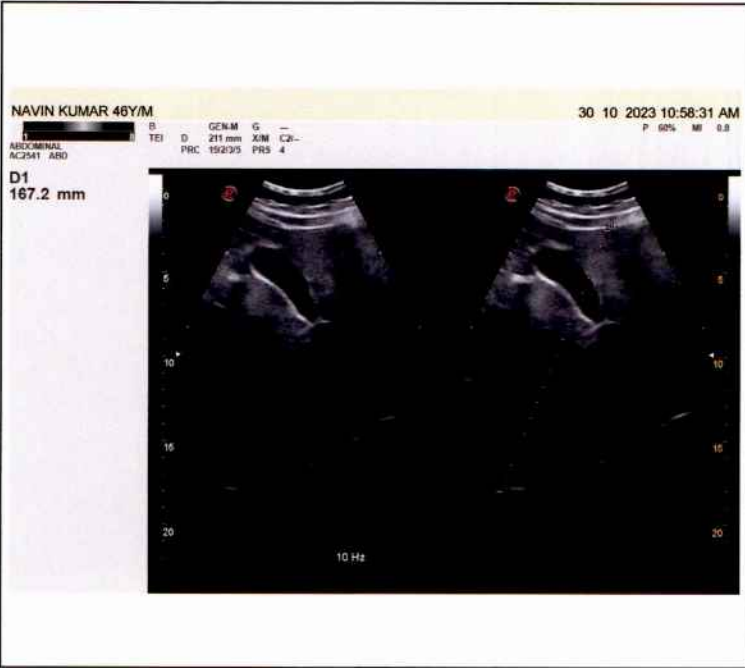
Thanks for reference.

Sonologist

Dr. Rahul Kumar Tiwari
MBBS, MD (Radio Diagonosis)
Reg. No. 57557

Disclaimer: This report is not valid for Madicolegal or Judicial Purpose. Radiological diagnosis is solely interpretation of images produced by tissue & may not be always conclusive.

Address : B36/44 B4 Kabir Nagar (Near Sanjay Shiksha Niketan), Durgakund, Varanasi
Mobile : 9554572190 / 9453837595 / Recpn, 9389994334
Email : dramishra@gmail.com, drpallaviojha@gmail.com, Website : www.piire.org





PANACEA HOSPITAL

Call Now - 1800-123-3070



A shelter for many hearts A Home for many lives

(An ISO 9001:2008 Certified Organisation)
Lab Attached with CMC Under EQAS Scheme

Dept. of Radiodiagnosis - 32 Slice CT Scan, 3D/4D USG, 2D ECHO, Colour Doppler, Intervention Procedures, Digital X-Ray

PATIENT'S NAME : NAVIN KUMAR

AGE/SEX: 48 Y/M

REF. BY : Dr. ASHUTOSH MISHRA

DATE: 30/10/2023

X-RAY CHEST PA

BOTH LUNG FIELDS AND PLEURAE:

Lung fields show hazy opacities in both parahilar basal zone with mild prominent bronchopulmonary marking finding suggestive of MILD BRONCHITIS.

Right & left hila are normal

There is no evidence of any fluid in the both the pleural cavities.

Both domes of diaphragms are normal in position.

MEDIASTINUM:

Trachea is central in position.

No evidence of pericardial effusion.

No significant lymphadenopathy is seen.

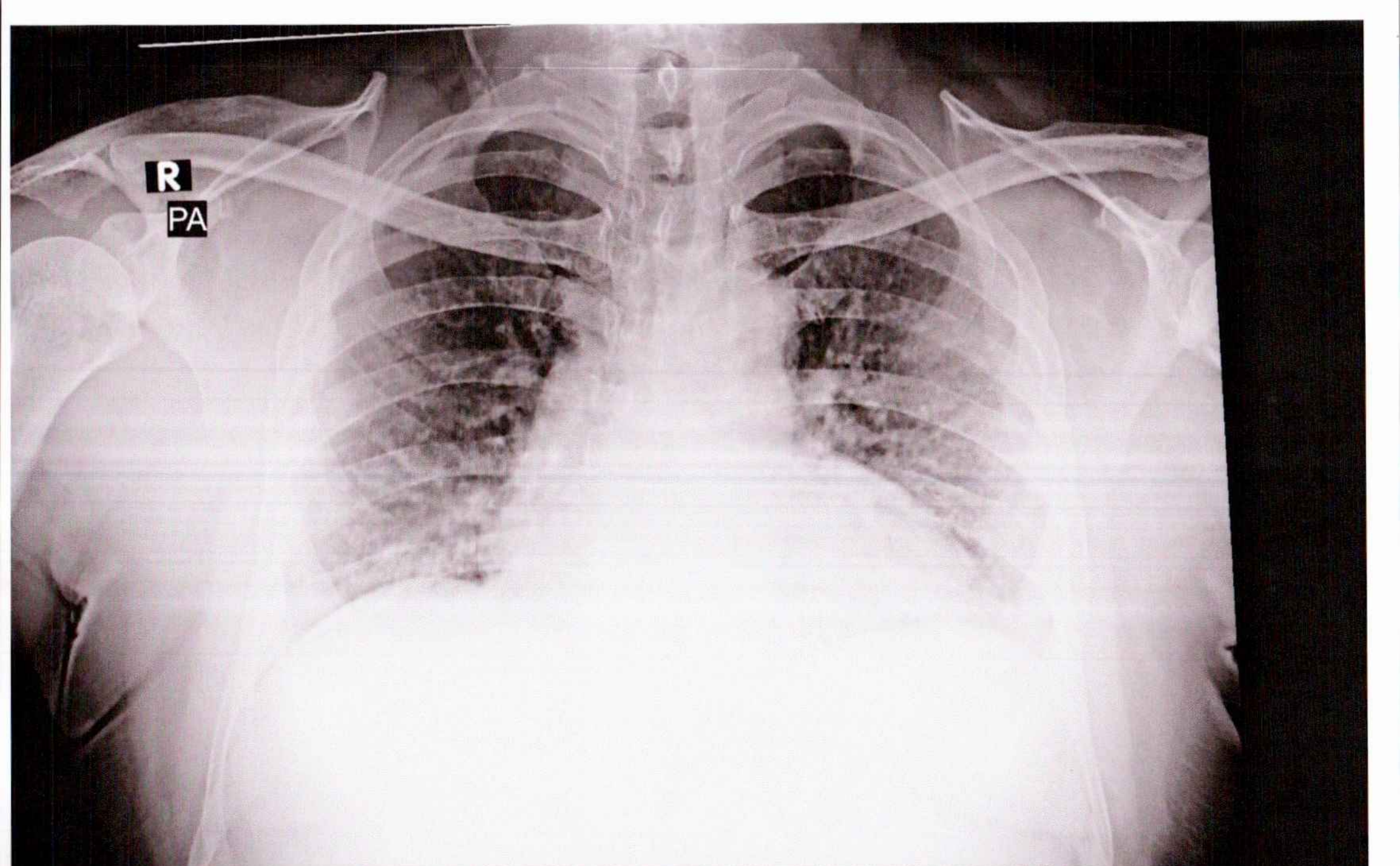
Visualized skeleton is normal.


Radiologist


Dr. Rahul Kumar Tiwari
MBBS, MD (Radio Diagnostics)
Reg. No. 57557

Disclaimer: This report is not valid for Medicolegal or Judicial Purpose. Radiological diagnosis is solely interpretation of images produced by tissue & may not be always conclusive.

Address : B36/44 B4 Kabir Nagar (Near Sanjay Shiksha Niketan), Durgakund, Varanasi
Mobile : 9554572190 / 9453837595 / Recpn, 9389994334
Email : dramishra@gmail.com, drpallaviojha@gmail.com, Website : www.piire.org



R
PA

NAVIN KUMAR 48Y/M 3721 M CHEST P.A. 30-Oct-23 10:52 AM

PANACEA HOSPITAL, KABIR NAGAR, DURGAKUND, VARANASI