

ECHO Report

Date: 25/02/2023

Patient Details

Patient ID –

Name MR NINAD HOMBALKAR

Age- 33 YEARS

Gender- MALE

Referral BY - MEDIWHEEL

Doctor Incharge DR. MAHESH PADSALGE

Clinical Status of Patient -

Finding description -

- 1. Normal cardiac chambers dimensions .**
- 2. Normal LV systolic function.**
- 3. No RWMA.**
- 4. All cardiac valves are structurally normal.**
- 5. Trivial MR, Trivial PR, NO AR.**
- 6. No PAH.**
- 7. Normal RV systolic function.**
- 8. No clot/vegetation/pericardial effusion.**
- 9. No coarctation of aorta.**

Chamber Dimensions-M mode Findings

LVID (Diastole) 35-56(mm)	- 42.00	LVID (Systole) 24-42(mm)	- 28.00
IVS (Diastole) 8-12(mm)	- 11.00	IVS (Systole) 14-42(mm)	- 15.00
LVPWT (Diastole) 6-11(mm)	- 11.00	EPSS	- 3.00
LVEF (%)	- 63%	LVFS (%)	- 33.00

LV Volume (Diastolic)(mm³)
Meridional Wall Stress in System

LV Volume (Systolic)(mm³)
Cubed LV Volume in Diastole (mm³)

Cubed LV+ myocardial volume (mm³)

Velocity of circumferential
Shortening (mm)

Aortic root 22-37(mm)	- 28.00
Left Atrium Length (mm)	- 32.00
Left Atrium Volume (mm ³)	
RV size	Normal
Normal	
RV volume (mm ³)	
Normal	
Pericardium	Normal
Effusion	None
Resp Variation	Present
Predicted RV Systolic Pressure	

Left Atrium Width (mm)
Left Atrium Area (mm²)
RV Function

RA Size

IVC Size (mm) – 14mm Collapsible

Doppler Findings- I



Dr. Mahesh Padsalge

Dr. Mahesh V. Padsalge
MD. (Medicine)
Consultant Physician
Reg. No. 91424 (MMC)

25.02.2023 12:17:21
DIABECARE-DIABETES & ENDOCRINE
OPP. GRAND CENTRAL MALL
SEAWOOD

Ninad hombalkar
ID: age 33f

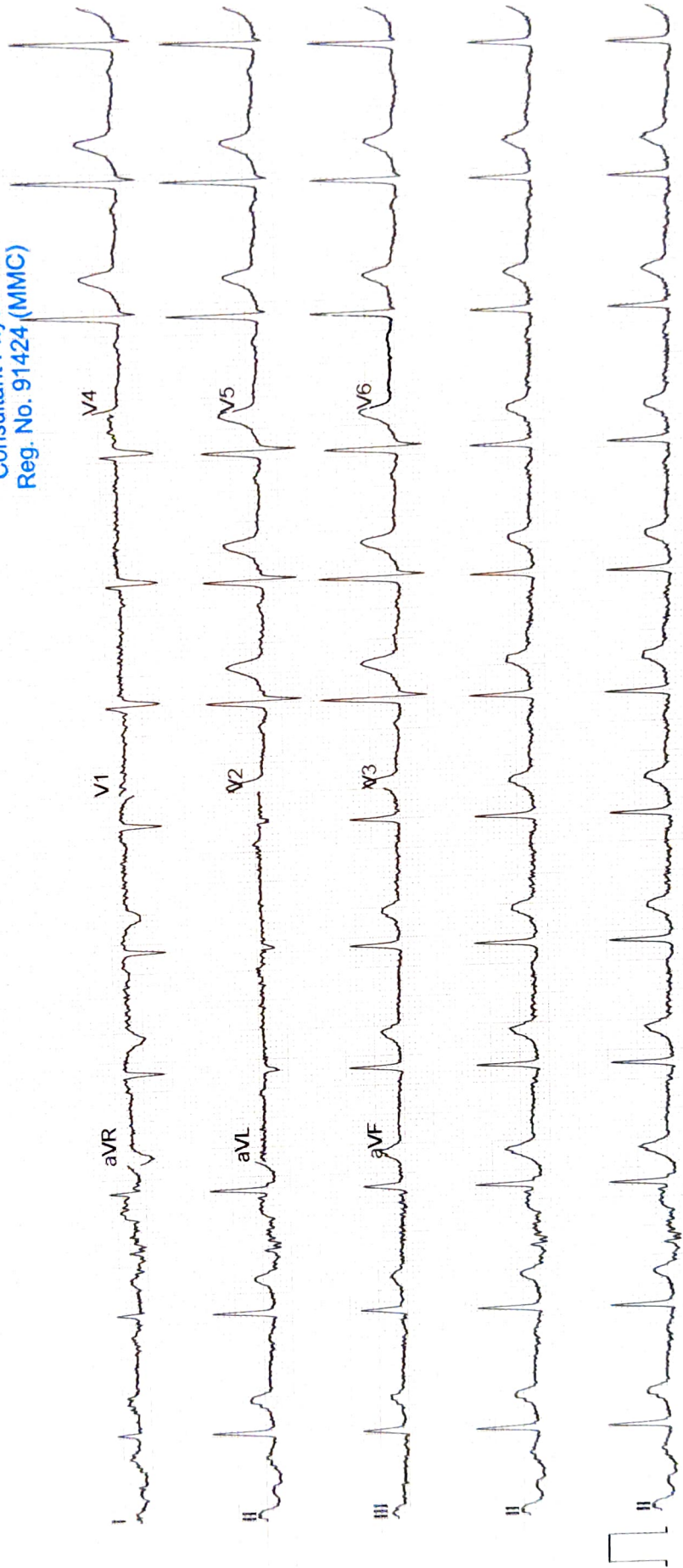
Male

QRS : 74 ms
QT / QTcBaz : 362 / 396 ms
PR : 162 ms
P : 88 ms
RR / PP : 832 / 833 ms
P / QRS / T : 21 / 74 / 63 degrees

Normal sinus rhythm
Normal ECG

copy within normal limit

Dr
Dr. Mahesh V. Padsalge
MD. (Medicine)
Consultant Physician
Reg. No. 91424 (MMC)



Mr. Minad Hombalkar
34/M.

28/2/23

Opnith

	(R)	(L)
VA	6/6	6/6
	N ₆	N ₆
	Color	
	✓	
A/S	✓	✓
(F)	✓	✓
	(BS)	wntz
		lyr

आयकर विभाग
INCOME TAX DEPARTMENT

भारत सरकार
GOVT. OF INDIA

NINAD NANDKUMAR HOMBALKAR
NANDKUMAR NARAYAN HOMBALKAR

15/10/1988
Permanent Account Number
ACVPH0523J


Signature



08022008


Dr. Mahesh V. Padsalge
MD. (Medicine)
Consultant Physician
Reg. No. 91424 (M.M.C.)

NAME- NINAD HOMBALKAR

DATE-25/2/2023

AGE- 34/M

X-RAY CHEST PA

The Soft Tissues And Bony Thorax Are Normal.

Both The Costophrenic And Cardiophrenic Angles Are Clear.

Cardiac Shape And Size Appears Normal.

The Lung Field Appears Normal.

Both The Hila Are Normal In Density And Position.

Both The Domes Of Diaphragm And Mediastinum Are Normal.

Impression: - Normal Chest X-Ray.

For, 

DR.MRUDULA BABAR
CONSULTANT RADIOLOGIST

Dr. MRUDULA BABAR
DURE.CPS Mumbai 2009
(RADIOLOGIST)
Reg. No. 2005/03/2139