

Name	KUCHIMANCHI SWATHI	ID	MED110764719
Age & Gender	31Y/F	Visit Date	Nov 27 2021 12:00AM
Ref Doctor	MediWheel		

RADIOGRAPH CHEST P.A. VIEW

The Cardiac size and configuration are normal.

The Aorta and Pulmonary Vasculature are normal.

Both the lungs are clear.

Both Costophrenic angles are normal.

The soft tissues and bones of thorax are normal.

IMPRESSION :

- Essentially normal study.

- For clinical correlation.



Dr. Jahnavi Barla MD (RD), DGO.
Consultant Radiologist



☎: 0891-2706431
Cell: 9246674691



SHARADA EYE HOSPITAL

H.No. APGV KHN B00 146, Sharada Eye Hospital Complex
Krishnanagar, VISAKHAPATNAM-530 002

Dr. K. Venkateswarlu
MD (AIIMS) FRF

Date 27-11-21

EYE SURGEON
Reg. No. 12677

Ms. K. Swathi 32 F

Vision (R) 6/6 N5 (L) 6/6 N5

Ant seg normal normal

Fundus normal normal

Color vision normal normal

Eyes normal

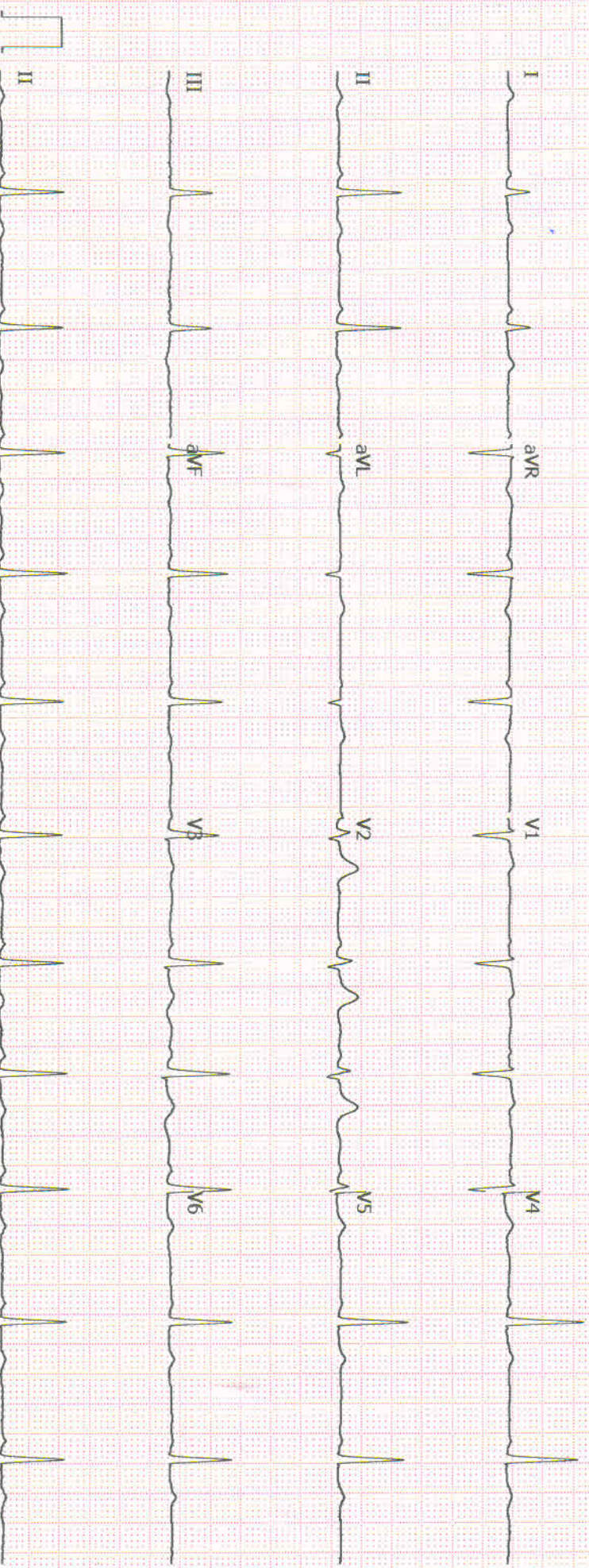


Dr. K. VENKATESWARLU
MB., M.D. (Oph. A.I.I.M.S.), F.R.F.
Sharada Eye Hospital
VISAKHAPATNAM-2
Reg. No. 12677

Technician:
Ordering Ph.:
Referring Ph.:
Attending Ph.:

QRS : 76 ms
QT / QTcBaz : 364 / 395 ms
PR : 130 ms
P : 98 ms
RR / PP : 848 / 845 ms
P / QRS / T : 36 / 73 / 4 degrees

Sinus rhythm with premature atrial complexes
Otherwise normal ECG



Name	KUCHIMANCHI SWATHI	ID	MED110764719
Age & Gender	31Y/F	Visit Date	Nov 27 2021 12:00AM
Ref Doctor	MediWheel		

ULTRASOUND WHOLE ABDOMEN

Liver : Normal in size (13.3 cm) with regular outlines and normal echopattern.
 There is no evidence of IHBR / EHBR dilatation seen.
 No focal space occupying lesions seen.
 CBD is normal. PV normal.

Gall Bladder : Normal in volume and wall thickness.
 No e/o intraluminal calculi seen. No pericholecystic edema noted.

Pancreas : Head, body and tail are identified with normal echopattern and smooth outlines.

Spleen : Measured 9.6 cm, in size with normal echotexture.

Right kidney : Measured 9.6 x 4.3 cm in size.

Left kidney : Measured 9.1 x 4.1 cm in size.

Both kidneys are normal in size, position, with well preserved cortico medullary differentiation and normal pelvicalyceal anatomy.

No e/o calculi / space occupying lesion seen.

No e/o suprarenal / retroperitoneal masses noted.

Urinary : Normal in volume and wall thickness.

bladder : No e/o intraluminal calculi / masses seen.

Uterus : Measured 8.0 x 4.1 x 5.3 cm in size with regular outlines.

Myometrial echotexture is normal.



Name	KUCHIMANCHI SWATHI	ID	MED110764719
Age & Gender	31Y/F	Visit Date	Nov 27 2021 12:00AM
Ref Doctor	MediWheel		

The Endometrial cavity is empty and shows no abnormality.

Endometrial echo measured 5 mm.

Right ovary : Measured 3.2 x 2.0 cm in size.

Left ovary : Measured 2.6 x 1.8 cm in size.

Both ovaries are normal in size and appearance.

No e/o ascites / pleural effusion seen.

No e/o detectable bowel pathology seen..

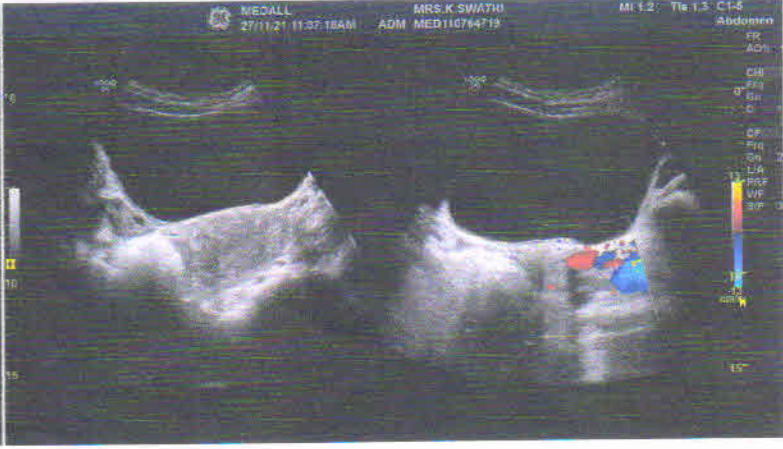
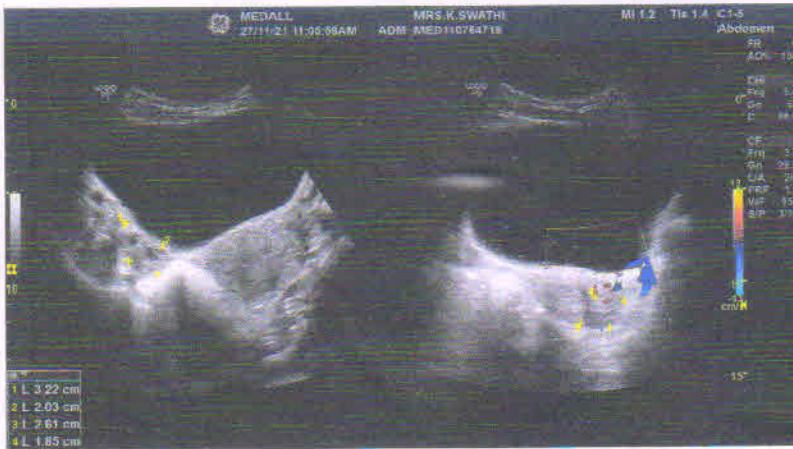
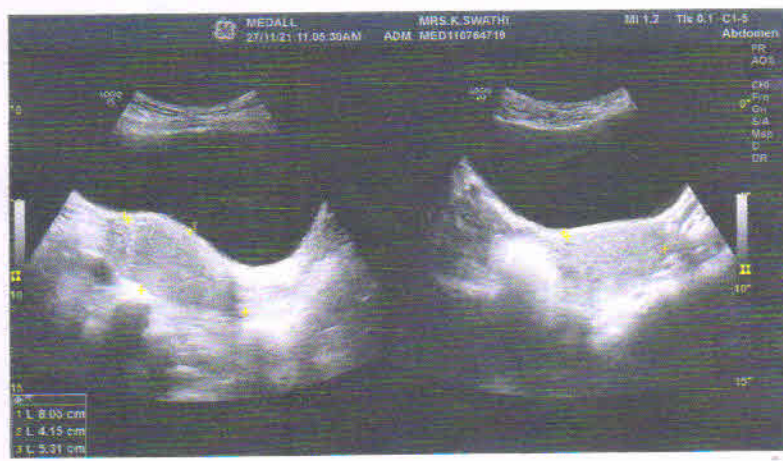
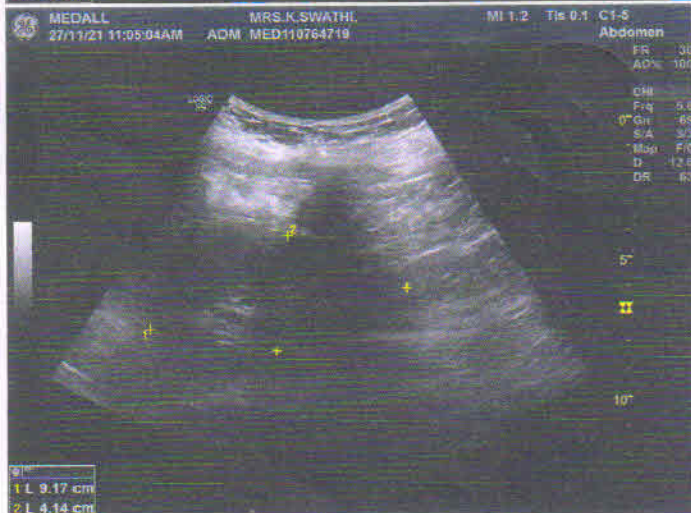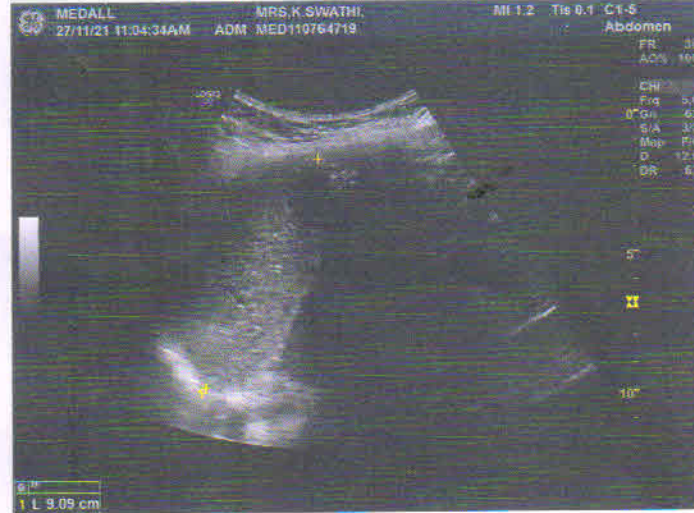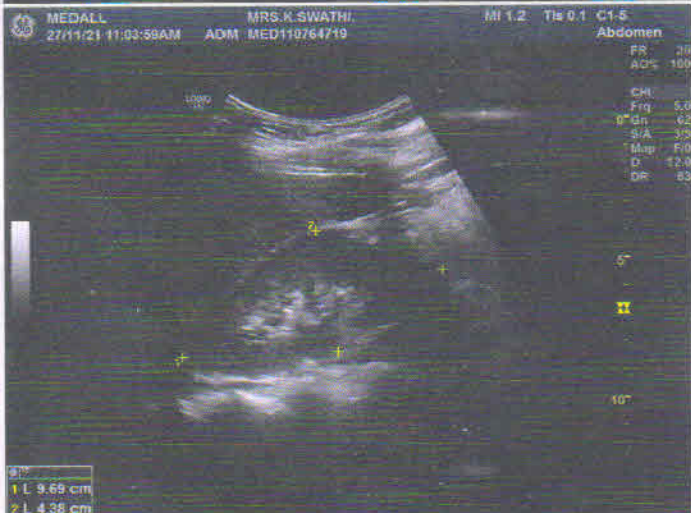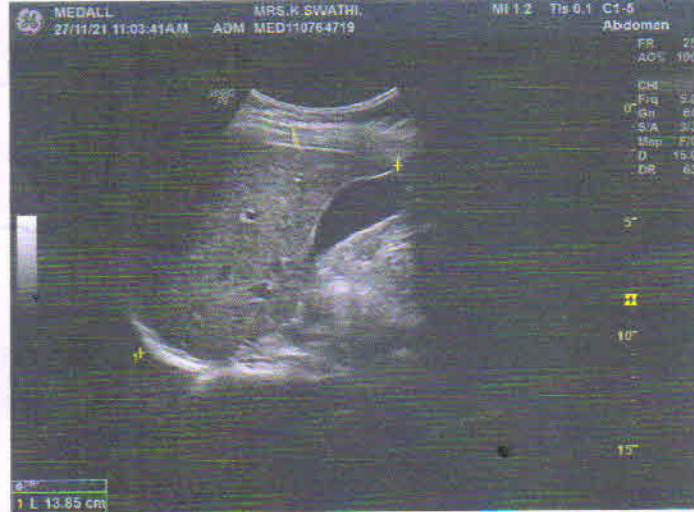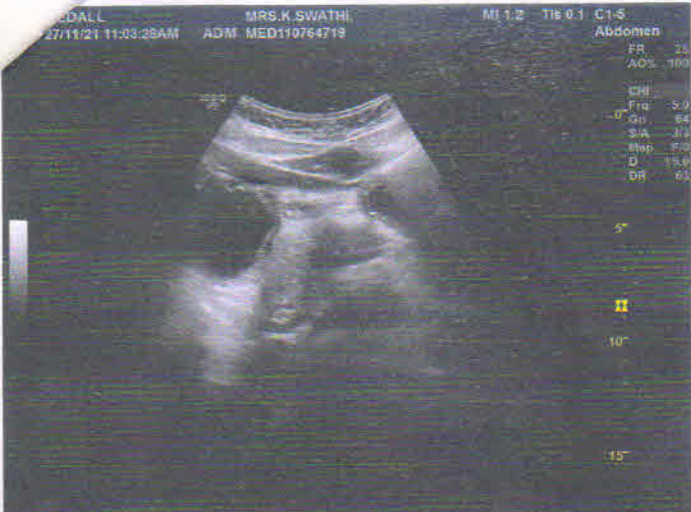IMPRESSION :

- Essentially normal study.
- *For clinical correlation.*



Dr. Jahnavi Barla MD (RD), DGO.
Consultant Radiologist





KUCHIMANCHI SWATHI,

Tabular Summary

MEDALL HEALTHCARE PVT

Patient ID MED110764719

11/27/2021

Female

9:48:51am

31yrs Mongolian

Meds:

Test Reason:

Medical History:

Ref MD: Ordering MD:

Technician: Test Type:

Comment:

BRUCE: Total Exercise Time 08:17
 Max HR: 190 bpm 100% of max predicted 189 bpm HR at rest: 80
 Max BP: 140/90 mmHg Max RPP: 24700 mmHg*bpm
 Maximum Workload: 10.10 METS
 Max. ST: -1.20 mm, 0.00 mV/s in V5; EXERCISE STAGE 2 05:00
 Arrhythmia: A:20, VBIG:1, PVC:6, PSVC:3, PCAP:1
 ST/HR index: 0.90 μ V/bpm

Reasons for Termination: Fatigue
Summary: Resting ECG: normal. Functional Capacity: normal. HR Response to Exercise: appropriate. BP Response to Exercise: normal resting BP - appropriate response. Chest Pain: none. Arrhythmias: none. ST Changes: none. Overall impression: Normal stress test.

Phase Name	Stage Name	Time in Stage	Speed (mph)	Grade (%)	Workload (METS)	HR (bpm)	BP (mmHg)	RPP (mmHg*bpm)	VE (/min)	STLevel (V5 mm)	Comment
EXERCISE	STAGE 1	03:00	1.70	10.00	4.6	120	120/80	14400	0.0	-0.10	
	STAGE 2	03:00	2.50	12.00	7.0	148	130/90	19240	0	-1.10	
	STAGE 3	02:18	3.40	14.00	10.1	190	130/90	24700	0	-0.75	
RECOVERY		02:58	0.00	0.00	1.0	95	140/90	13300	0	-0.10	

Stress Test - Negative for Inducible

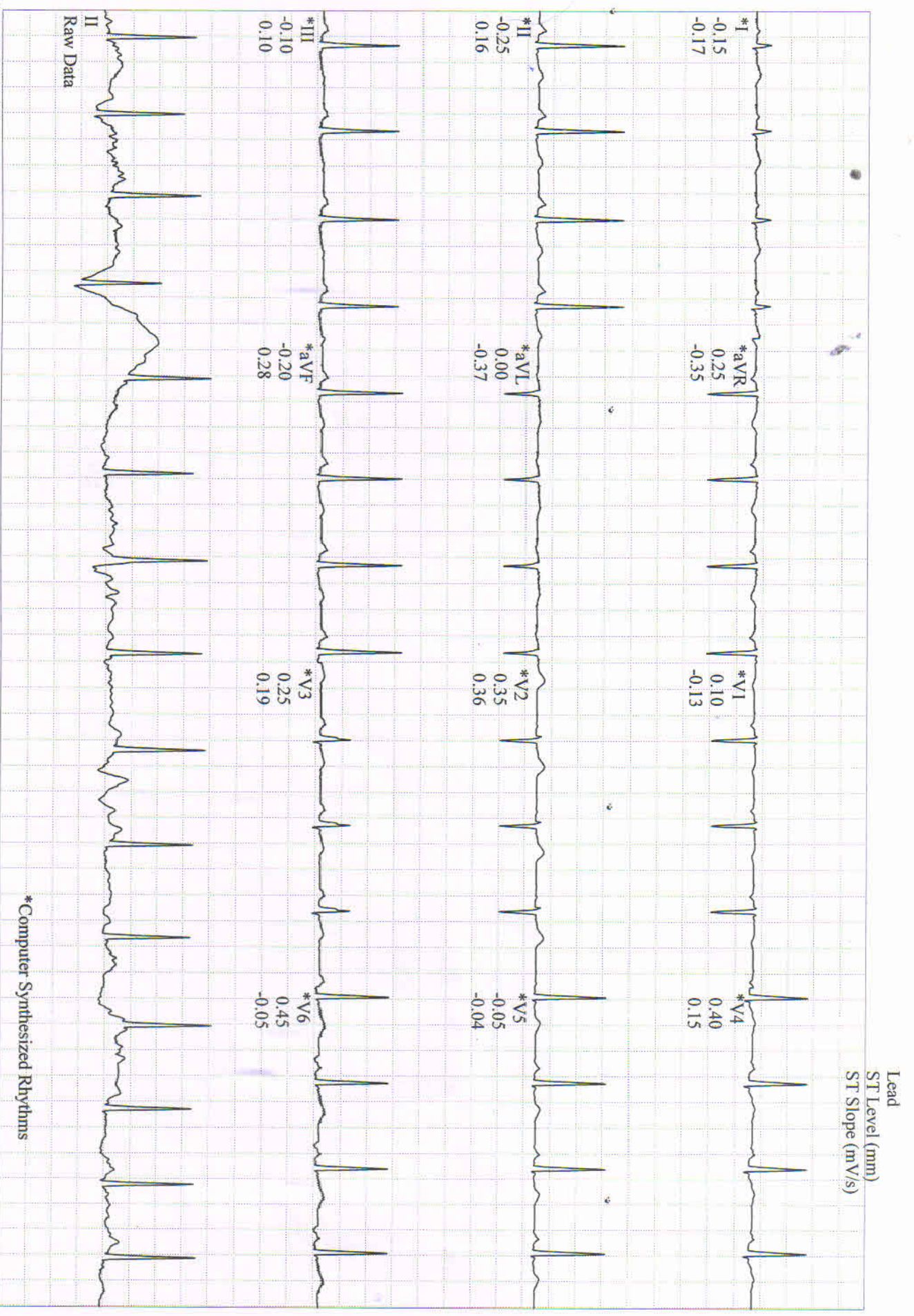Bellocaria

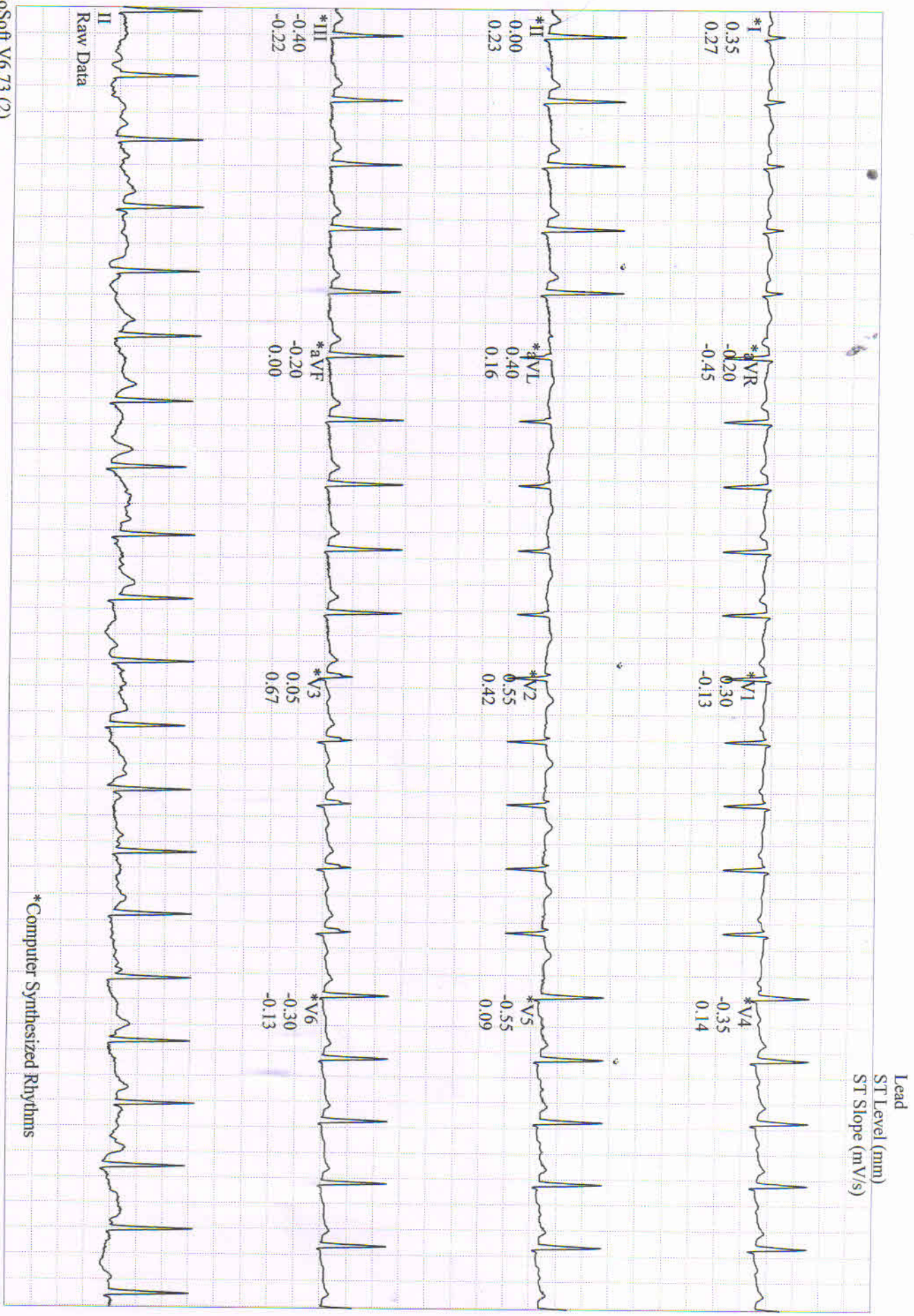
Smeeth

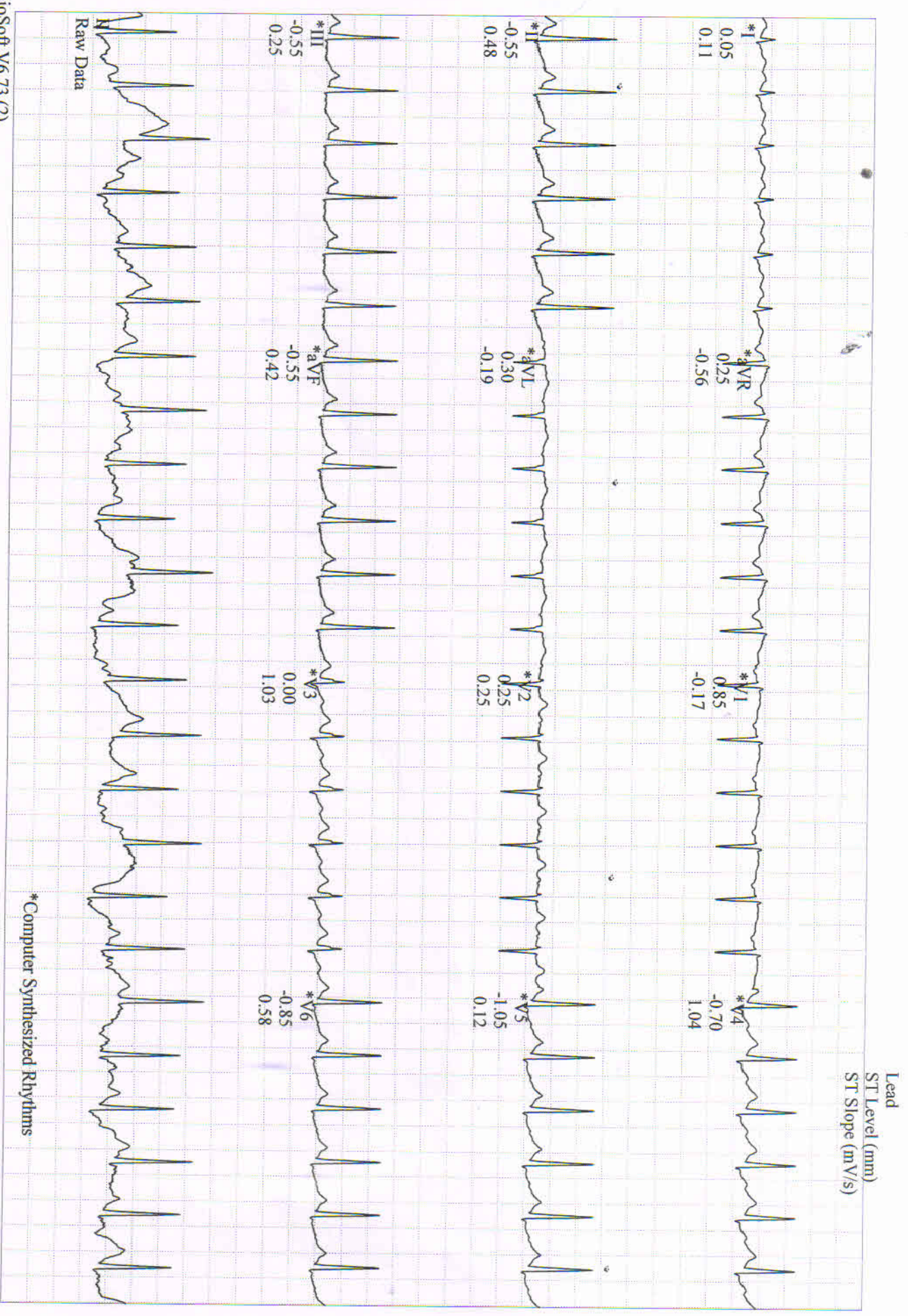
89 bpm

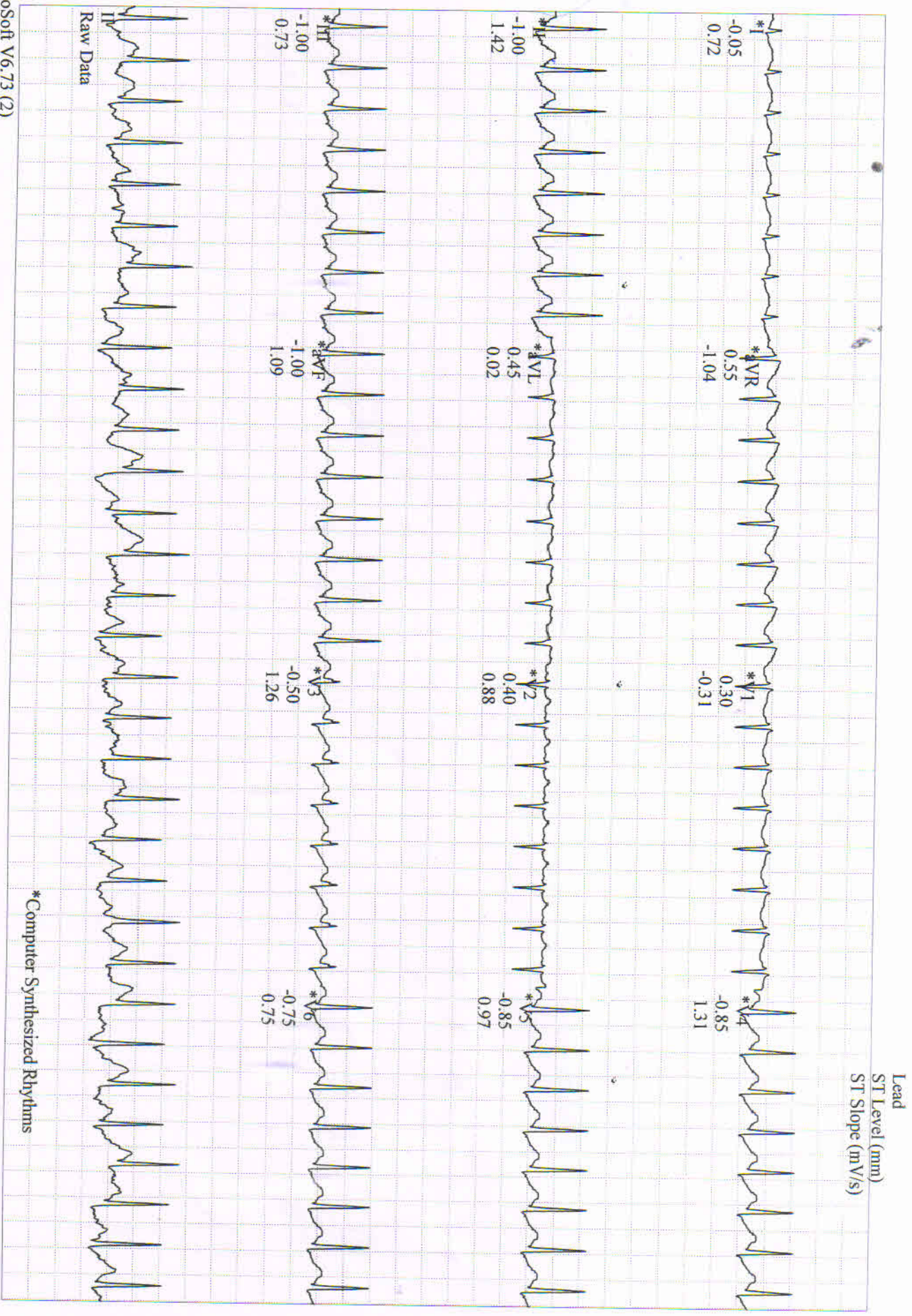
Linked Medians

MEDALL HEALTHCARE PVT





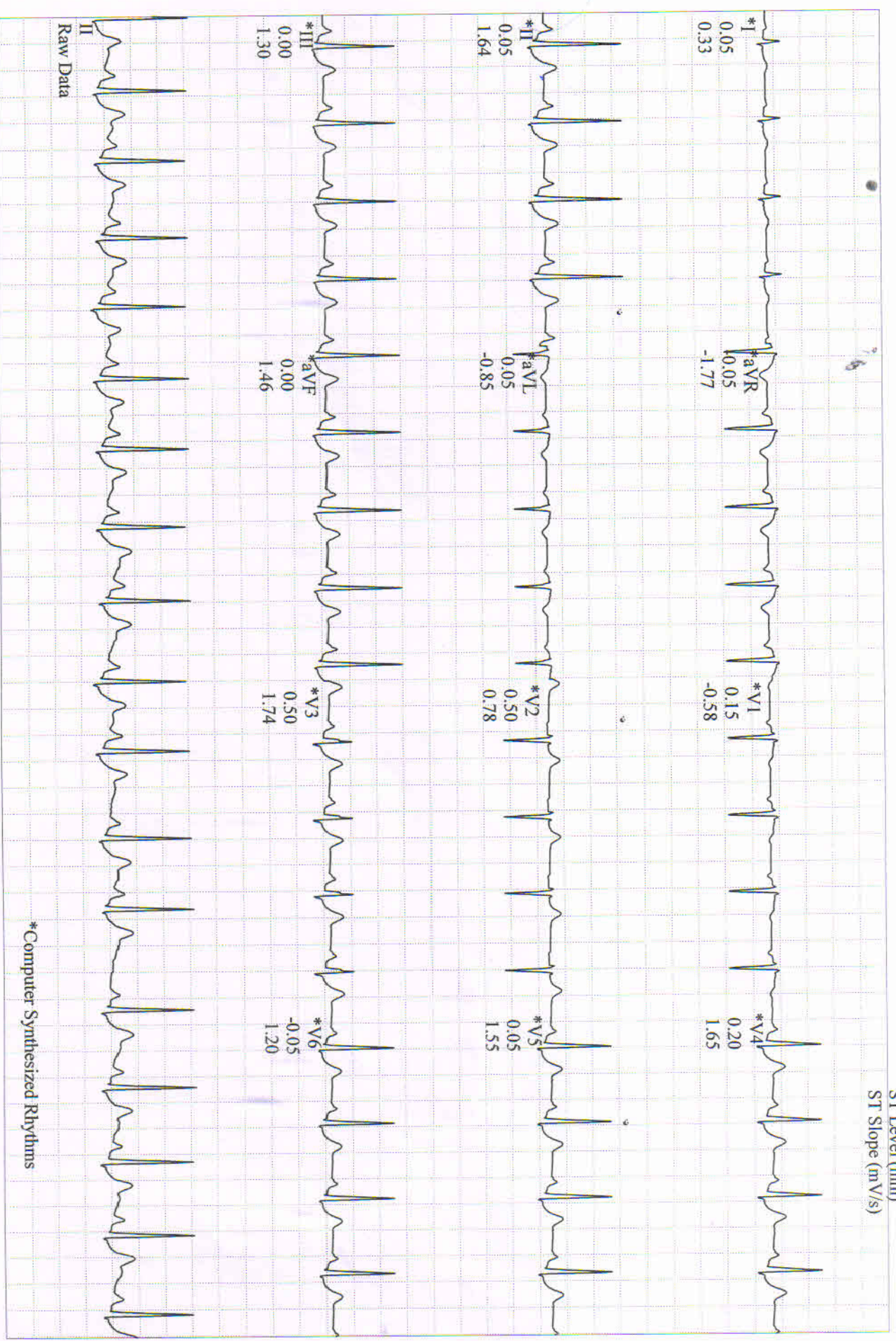




105 bpm

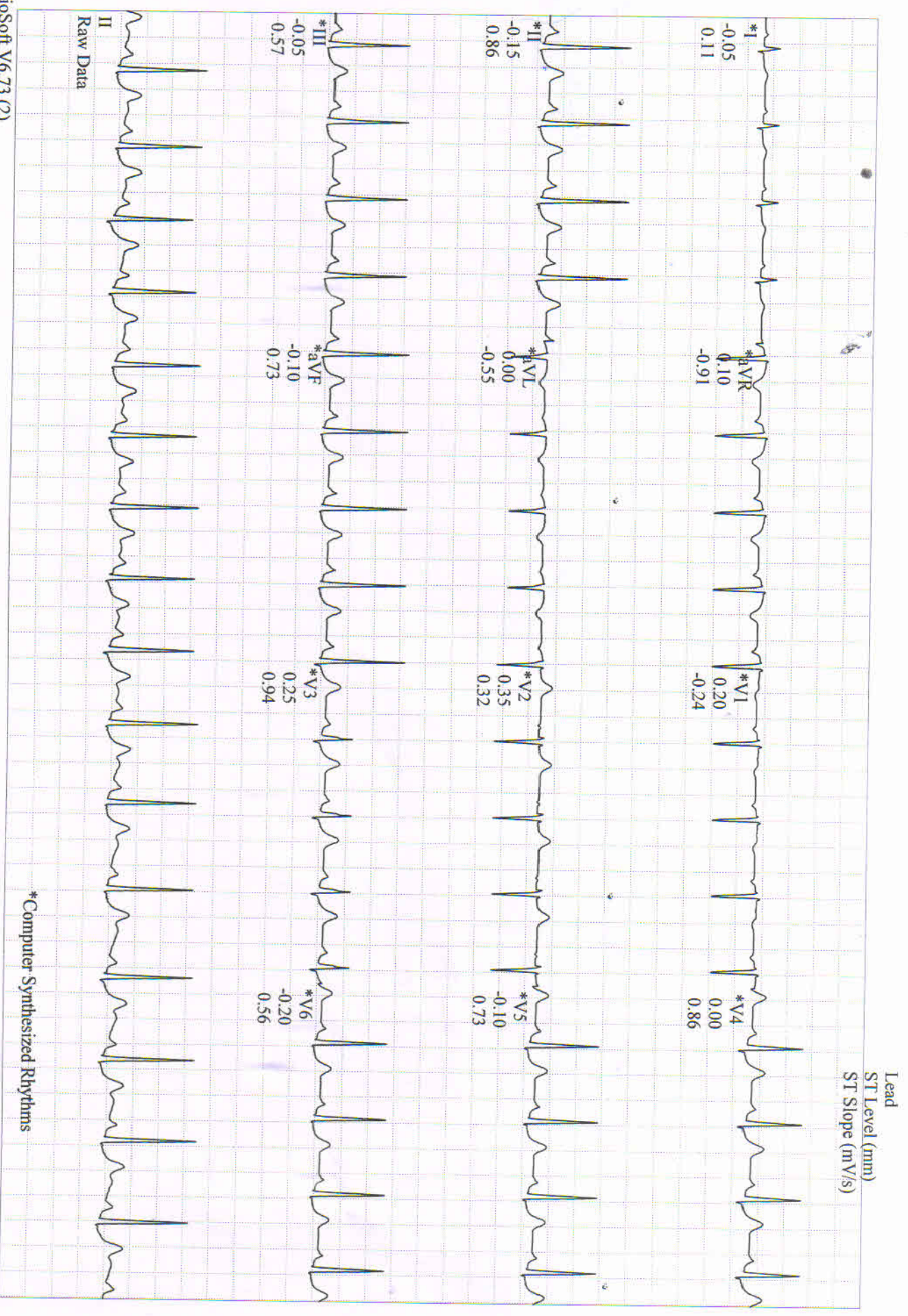
BRUCE
0.0 mph
0.0 %

Lead
ST Level (mm)
ST Slope (mV/s)



Raw Data

*Computer Synthesized Rhythms



FITNESS CERTIFICATE

NAME: K. Swathi	AGE: 32	
Ht: 158 CMS	Wt: 63 KGS	SEX: F

PARAMETERS	MEASUREMENTS
PULSE / BP (supine)	120 / mt 70 6 / mmHg 62
INSPIRATION	35
EXPIRATION	38
CHEST CIRCUMFERENCE	36
PREVIOUS ILLNESS	
VISION	
FAMILY HISTORY	FATHER: V. Satyanarayana Rao. MOTHER: V. Padmavathi

REPORTS:

DATE: 27-11-2021

PLACE: Visakhapatnam

CONSULTANT PHYSICIAN





Dr. Lanka Prasad

PHYSICIAN & SURGEON, M.B.B.S.

Regd. No. 18363

Resi. : Flat No : 104
Dharma Sadan Apartments
Rednam Gardens, Visakhapatnam - 20
Resi. 2535158, Mobile : 98482 66326

MIGH-41
APHB Colony
Visakhapatnam
Pin-530 022
Clinic : 2508502


Date : 29.11.21

Name : Age Sex

Rx

Medical certificate

This is to certify that Smt. K. Swathi 31 years
is physically and mentally sound. Her X-ray
findings are normal, ECG. is normal. She is
free from infectious diseases.


Dr. Lanka Prasad, M.B.B.S.
Reg. No. 18363
CIVIL ASSISTANT SURGEON
MEDICAL OFFICER
Primary Health Centre
KASIN KOTA-531 031
VISAKHA Dist.

Retd. Dr.

పై మందులు దొరుకు చోటు

SEVEN HILLS MEDICAL & GENERAL STORES

MIG-1, H.B. Colony, Last Bus Stop, VISAKHAPATNAM-22, Cell : 98854 71883

FITNESS CERTIFICATE

NAME: K. Swathi	AGE: 32	
Ht: 158 CMS	Wt: 63 KGS	SEX: F

PARAMETERS	MEASUREMENTS
PULSE / BP (supine)	120 / mt 70 / mmHg 62
INSPIRATION	35
EXPIRATION	38
CHEST CIRCUMFERENCE	36
PREVIOUS ILLNESS	
VISION	
FAMILY HISTORY	FATHER: V. Satyanarayana Rao MOTHER: V. Padmavathi

REPORTS:

DATE: 27-11-2021

PLACE: Visakhapatnam

CONSULTANT PHYSICIAN