

1947

www.uidai.gov.in

help@uidai.gov.in

4838 6232 9357

VID: 9197 4244 2001 2042

QR Code with Photograph

Address:
S/D Bhoja Lal, 53, 1st Floor Pocket 6 B
Block, Sector 17 Rohini, Rohini, North
West Delhi,
Delhi - 110085

पता:
श्री. बी. लाल, 53, प्रथम तल्ला, थोक 6 बी, रोहिणी, रोहिणी,
पश्चिम दिल्ली, दिल्ली - 110085

Unique Identification Authority of India



ONEPLUS ULTRASOUND LAB
47, Harsh Vihar, Pitam Pura,
Delhi-110034
Ph. 011-42480101, 9599913051
E-mail: oneplusul@gmail.com


भारत सरकार
Government of India

Dr. NITIN AGARWAL
MBBS,
Regn. No. DMC-R-1436


रंजीत कुमार बरनवाल
Ranjeet Kumar Baranwal
जन्म तिथि/DOB: 20/01/1988
पुरुष/ MALE

4838 6232 9357
VID: 9197 4244 2001 2042

मेरा आधार, मेरी पहचान



Ranjeet Kumar Baranwal



Dr. NITIN AGARWAL
MBBS, MD
Regn. No. DMC-R-1436

ONEPLUS ULTRASOUND LAB
47, Harsh Vihar, Pitampura,
Gurgaon-110054
Ph. 011-42080101, 9599913051
E-mail: oneplusrl@gmail.com

ONEPLUS ULTRASOUND LAB

47, HARSH VIHAR, PITAMPURA, DELHI- 110034

Mr. RANJEET KUMAR BARANWAL
 Age : 34/M
 Ref. by : MEDIWHEEL
 Indication1 :
 Indication2 :
 Indication3 :
 COMMENTS : Normal ECG.

ID : 1884
 H/Wt : 169/61
 Recorded : 26-2-2022 10:18
 Medication1 :
 Medication2 :
 Medication3 :

[Handwritten Signature]

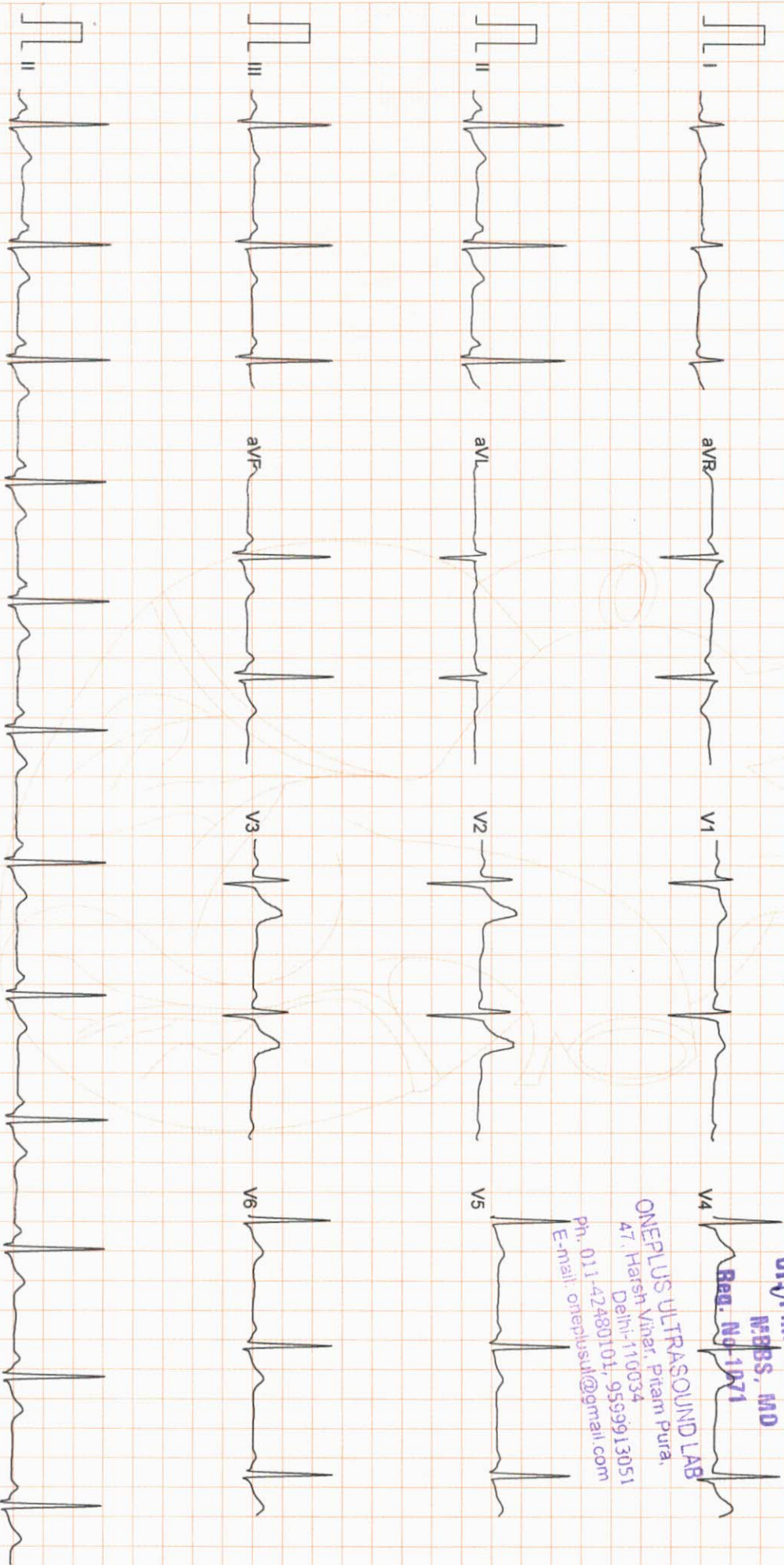
Unconfirmed Report Reviewed By:
 Cardiologist

BPM : 71
 BP : 132/84
 P Axis : 72 deg
 QRS Axis : 77 deg
 T Axis : 60 deg

P duration : 86 msec
 PR duration : 130 msec
 QRS duration : 103 msec
 QT interval : 310 msec
 QTc interval : 329 msec
 Raw E.C.G.(Seq)

[Handwritten Signature]
Dr. P.K. GUPTA
M.B.B.S., MD
Reg. No-1971

ONEPLUS ULTRASOUND LAB
 47, Harsh Vihar, Pitam Pura,
 Delhi-110034
 Ph. 011-42480101, 9599913051
 E-mail: oneplusul@gmail.com



Filtered

25mm/sec 10mm/mV

AI

CardiCom, INDIA

ONEPLUS ULTRASOUND LAB

47, HARSH VIHAR PITAMPURA DELHI 110034

Mr: RANJEET KUMAR BARANWAL

Age/Sex : 34/M

Ref. by : MEDIWHEEL

Indication1 :

Indication2 :

Indication3 :

ID : 987

HiWi : 169/61

Recorded : 26-2-2022 10:21

TREADMILL TEST SUMMARY REPORT

Protocol: BRUCE

History:

Medication1 :

Medication2 :

Medication3 :

PHASE	PHASE TIME	STAGE TIME	SPEED (Km./Hr.)	GRADE (%)	H.R. (BPM)	B.P. (mmHg)	RPP X100	II	ST LEVEL (mm) V2	V5	METS
SUPINE					68	132/84	89	0.4	2.6	0.1	
STANDING					74	132/84	97	0.4	2.6	0.2	
STAGE 1	2:59	2:59	2.70	10.00	109	146/88	159	0.1	2.9	0.0	4.80
STAGE 2	5:59	2:59	4.00	12.00	118	158/90	186	-0.4	2.1	-0.5	7.10
STAGE 3	8:59	2:59	5.40	14.00	137	168/92	230	-1.1	2.0	-0.8	10.00
STAGE 4	10:59	1:59	6.70	16.00	160	178/94	284	-1.9	2.9	-0.8	12.66
PEAK EXER	11:05	2:05			163	178/94	290	-1.4	3.1	-0.9	12.79
RECOVERY	2:59	2:59	0.00	0.00	103	134/84	138	-0.9	1.3	-0.6	

RESULTS

Exercise Duration

Max Heart Rate

Max Blood Pressure

Max Work Load

Reason of Termination

11:05 Minutes

163 bpm 87 % of target heart rate 186 bpm

178/94 mmHg

12.79 METS

IMPRESSIONS

Negative for ischaemic arte

Cardiologist

Dr. P.K. GUPTA

MBBS, MD

Reg. No-1071

ONEPLUS ULTRASOUND LAB
47, Harsh Vihar, Pitampura,
Delhi-110034
Ph: 011-42480101, 9599913091
Email: oneplusul@gmail.com

ONEPLUS ULTRASOUND LAB

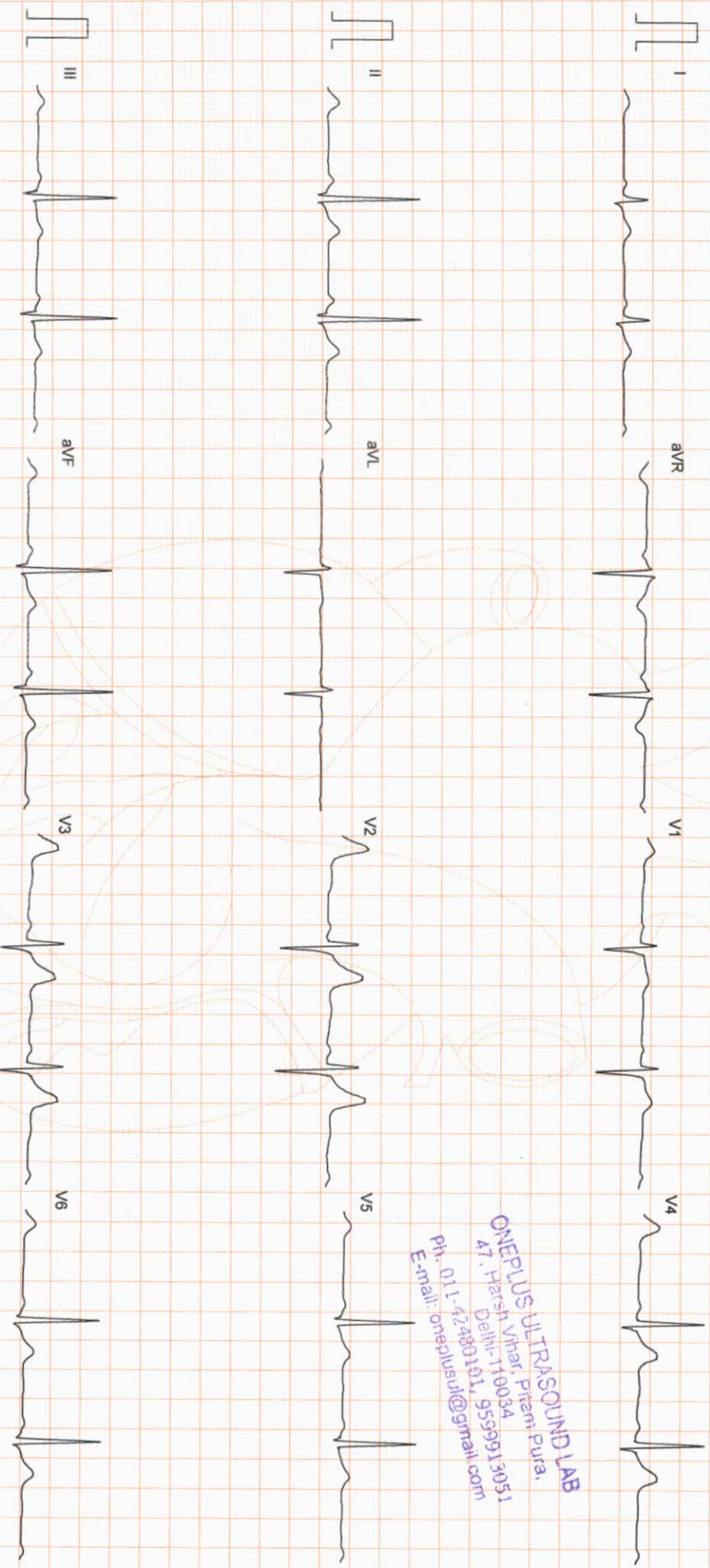
SUPINE
PRETEST

ST @ 10mm/mV
80ms PostJ

Mr. RANJEET KUMAR BARANWAL
I.D. : 987
AGE/SEX : 34/M
RECORDED : 26-2-2022 10:21

RATE : 68 BPM
B.P. : 132/84 mmHg

RAW E.C.G.



ONEPLUS ULTRASOUND LAB
47, Harsh Vihar, Pitam, Pura,
Delhi-110034
Ph: 011-42480101, 9539913051
E-mail: oneplusul@gmail.com

Filtered

25mm/sec 10mm/mV

AVR aVL aVF V1 V2 V3 V4 V5 V6

CardiCom, INDIA Ph.:091-731-2620740, Telefax:091-731-2431214

ONEPLUS ULTRASOUND LAB

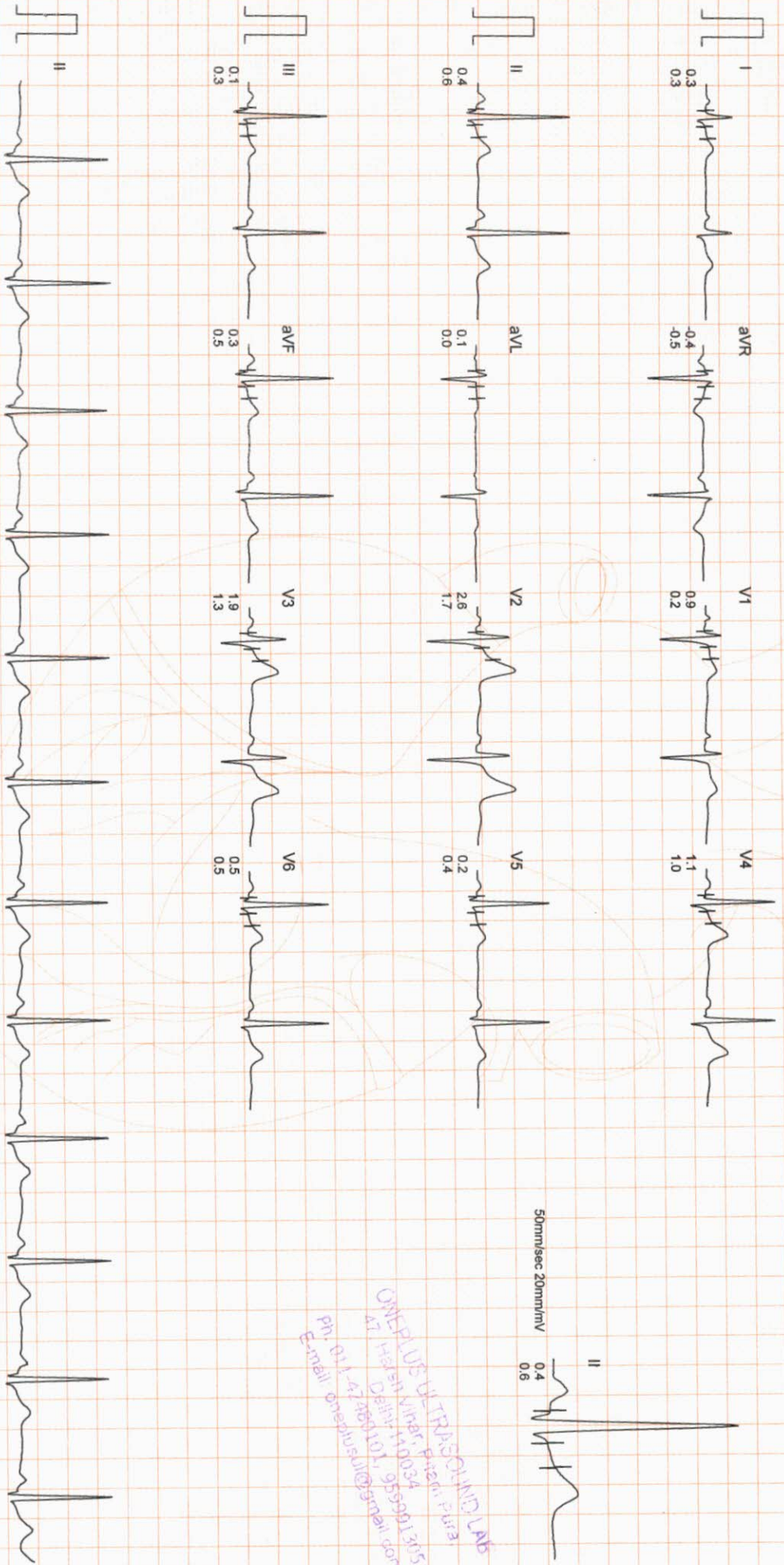
STANDING
PRETEST

ST @ 10mm/mV
80ms PostJ

Mr. RANJEET KUMAR BARANWAL
I.D. : 987
AGE/SEX : 34/M
RECORDED : 26-2-2022 10:21

RATE : 74 BPM
B.P. : 132/84 mmHg

LINKED MEDIAN



ONEPLUS ULTRASOUND LAB
47 Hazrat Nizami, Buzam, Puzra
Delhi-110034
Ph: 011-47269101
E-mail: onepplusul@gmail.com

ONEPLUS ULTRASOUND LAB

Mr. RANJEET KUMAR BARANWAL
 I.D. : 987
 AGE/SEX : 34/M
 RECORDED : 26-2-2022 10:21

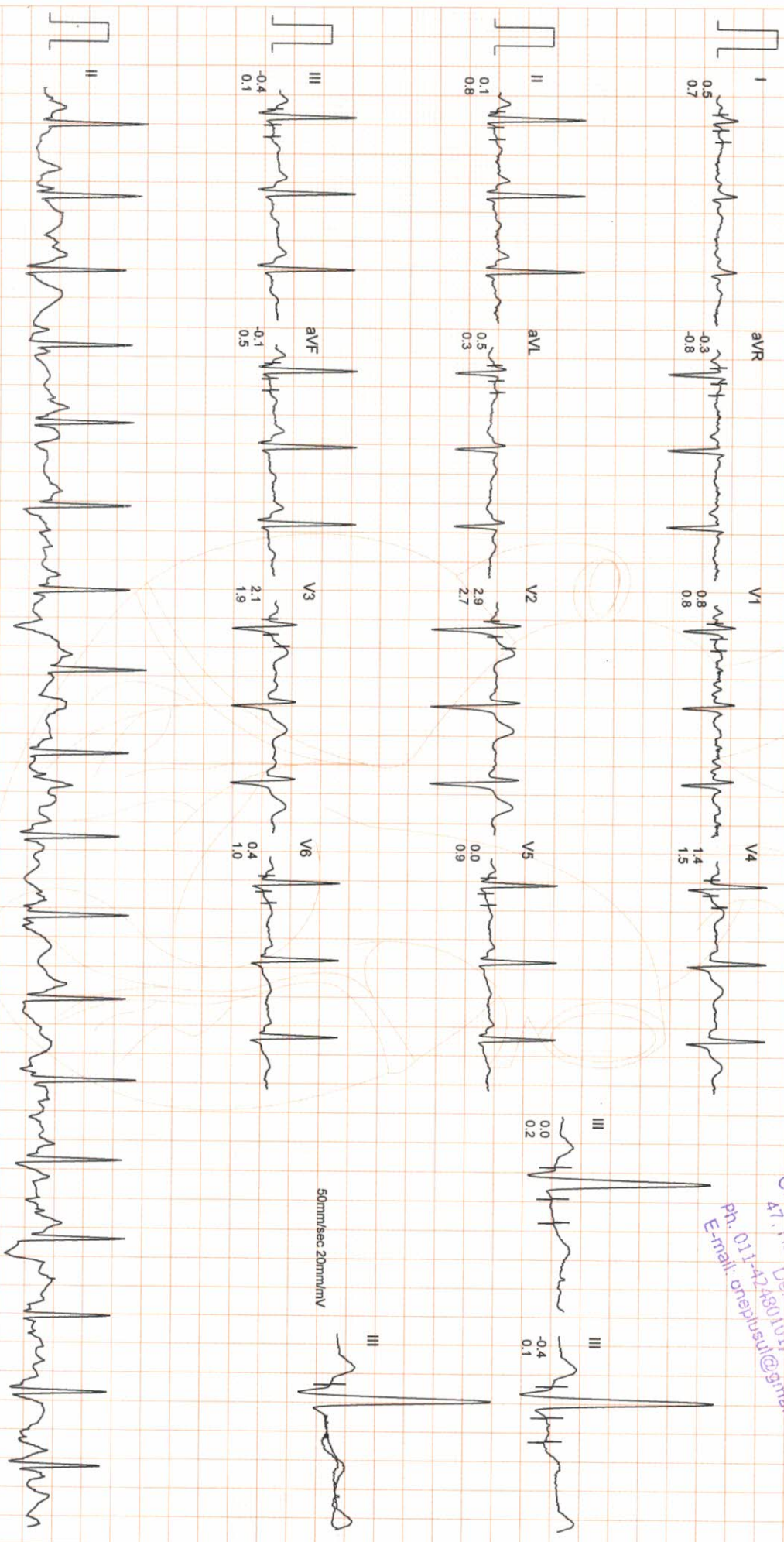
RATE : 109 BPM
 B.P. : 146/88 mmHg

BRUCE
 EXERCISE 1
 PHASE TIME : 2:59
 STAGE TIME : 2:59

ST @ 10mm/mV
 80ms PostJ
 SPEED : 2.7 Km./Hr.
 GRADE : 10.0 %

LINKED MEDIAN AB

ONEPLUS ULTRASOUND LAB
 47, Harish Vihar, Preeti, Pura,
 Delhi-110034
 Ph. 011-42480101-9599913051
 E-mail: onepplusul@gmail.com



ONEPLUS ULTRASOUND LAB

Mr. RANJEET KUMAR BARANWAL

I.D. : 987

AGE/SEX : 34/M

RECORDED : 26-2-2022 10:21

RATE : 118 BPM
B.P. : 158/90 mmHg

BRUCE

EXERCISE 2

PHASE TIME : 5:59

STAGE TIME : 2:59

ST @ 10mm/mv

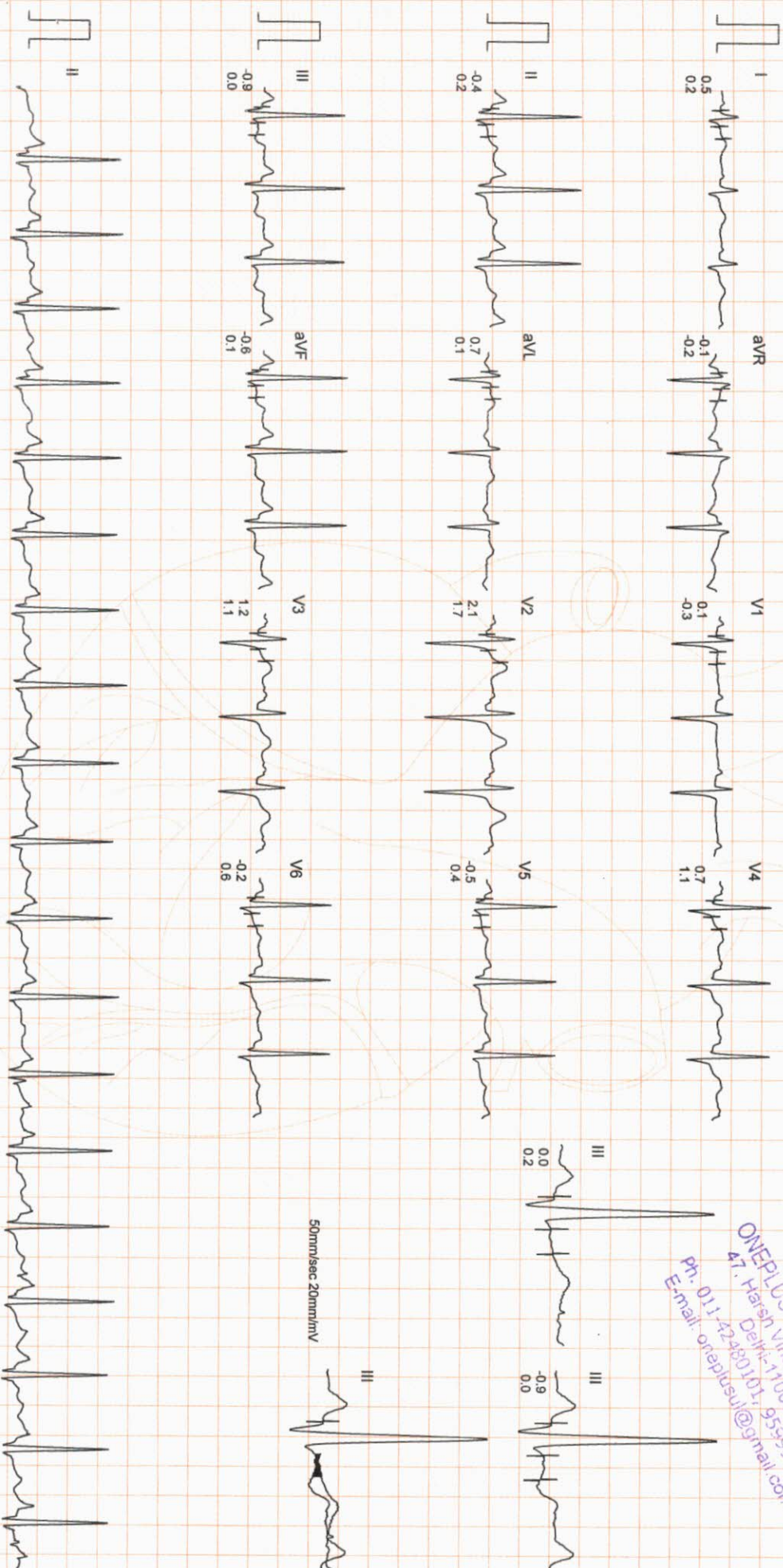
80ms PostJ

SPEED : 4.0 Km./Hr.

GRADE : 12.0 %

LINKED MEDIAN

ONEPLUS ULTRASOUND LAB
47, Hans Vihar, Pitam Pura,
Delhi-110034
Ph: 011-42480101, 9559913051
E-mail: oneplusul@gmail.com



50mm/sec 20mm/mV

Filtered

Computer Corrected Baseline

25mm/sec 10mm/mV

AVR-V6

CardiCom, INDIA Ph.:091-731-2620740, Telefax:091-731-2431214

ONEPLUS ULTRASOUND LAB

Mr. RANJEET KUMAR BARANWAL
I.D. : 987
AGE/SEX : 34/M
RECORDED : 26-2-2022 10:21

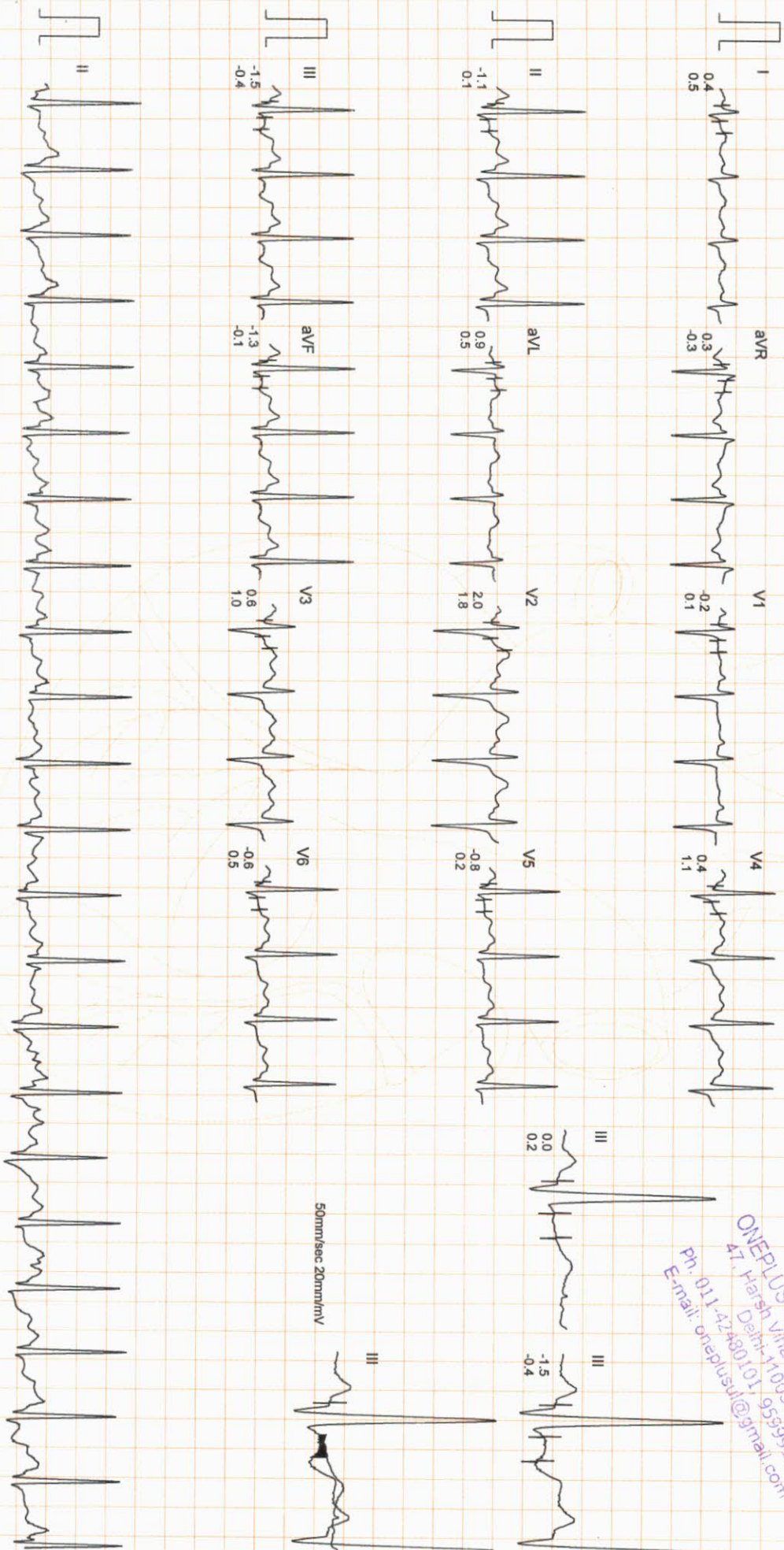
RATE : 137 BPM
B.P. : 168/92 mmHg

BRUCE
EXERCISE 3
PHASE TIME : 8:59
STAGE TIME : 2:59

ST @ 10mm/mv
80ms PostJ
SPEED : 5.4 Km./Hr.
GRADE : 14.0 %

LINKED MEDIAN

ONEPLUS ULTRASOUND LAB
47, Harsh Vihar, Pitam Pura,
Delhi-110034
Ph. 011-42480101, 9599913051
E-mail: oneplusul@gmail.com



50mm/sec 20mm/mv

ONEPLUS ULTRASOUND LAB

M. RANJEET KUMAR BARANWAL

I.D. : 987

AGE/SEX : 34/M

RECORDED : 26-2-2022 10:21

RATE : 157 BPM
B.P. : 168/92 mmHg

BRUCE

EXERCISE 4

PHASE TIME : 10:14

STAGE TIME : 1:14

ST @ 10mm/mV

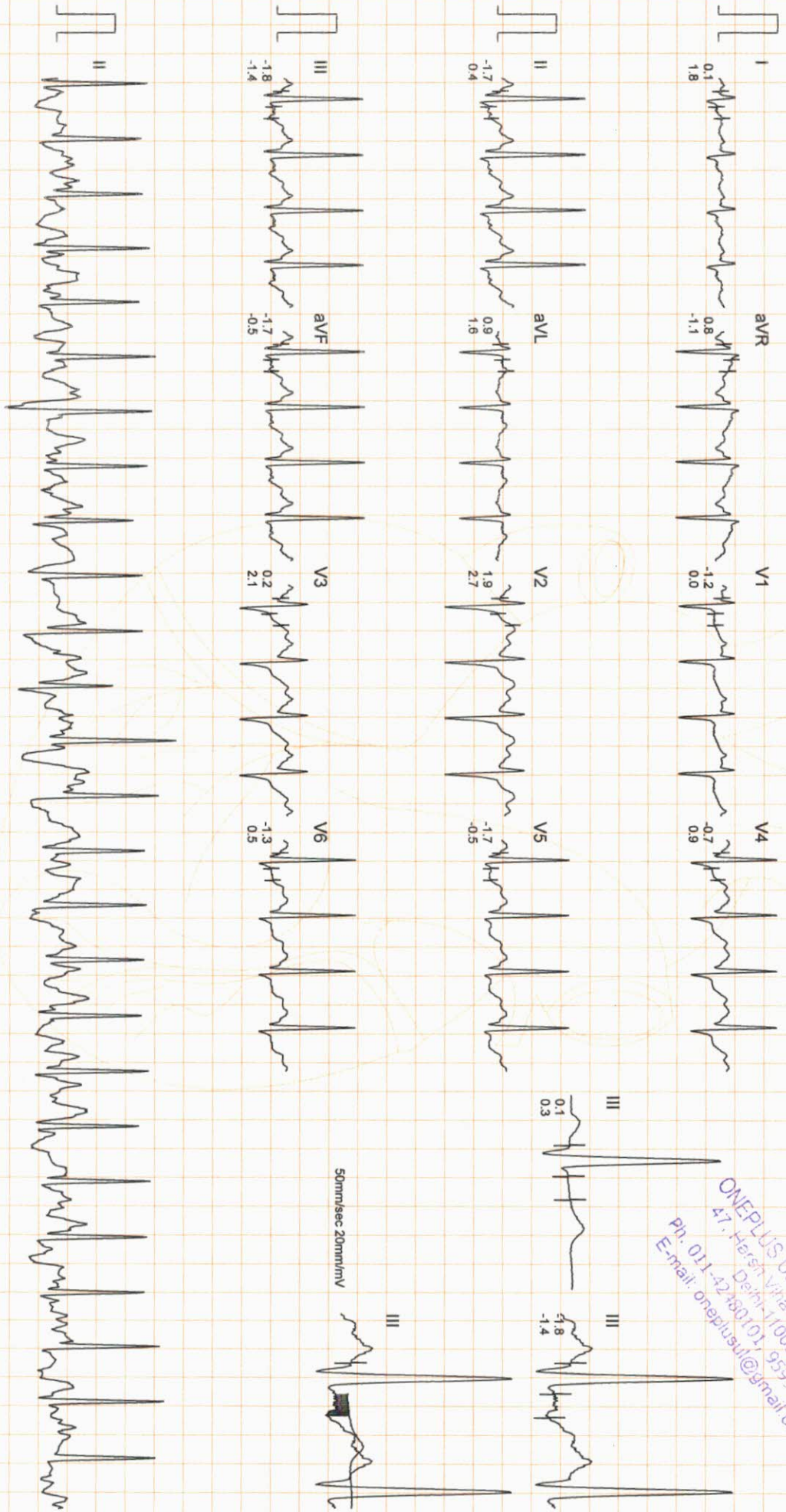
80ms PostJ

SPEED : 6.7 Km./Hr.

GRADE : 16.0%

LINKED MEDIAN

ONEPLUS ULTRASOUND LAB
47, Harsah Vihar, Prithvi Pura,
Delhi-110034
Ph: 011-42480101, 9539913051
E-mail: oneplusul@gmail.com



ONEPLUS ULTRASOUND LAB

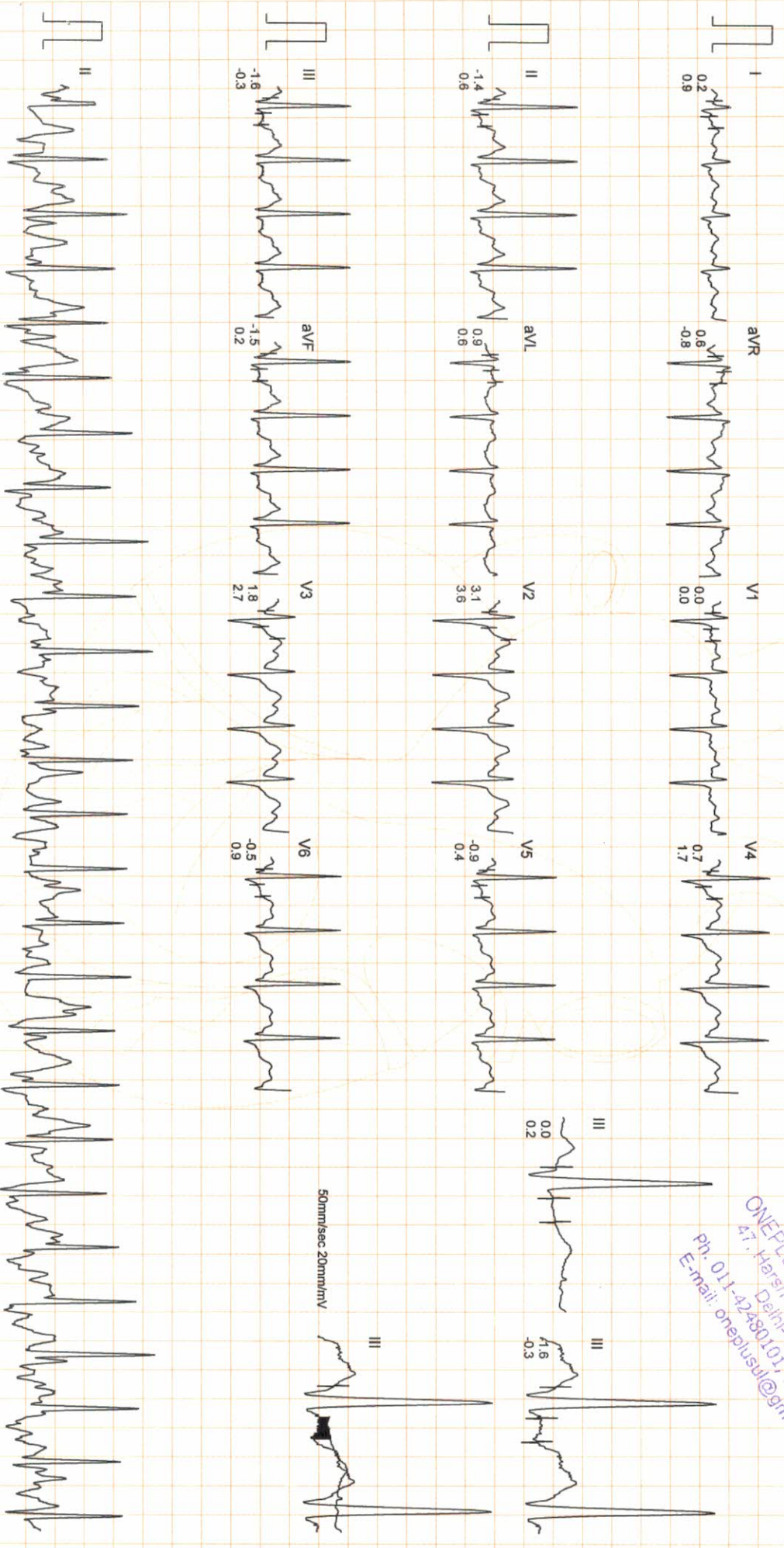
Mr. RANJEET KUMAR BARANWAL
 I.D. : 987
 AGE/SEX : 34/M
 RECORDED : 26-2-2022 10:21

RATE : 163 BPM
 B.P. : 178/94 mmHg

ST @ 10mm/mV
 80ms PostU
 SPEED : 6.7 Km./Hr.
 GRADE : 16.0 %

LINKED MEDIAN LAB

ONEPLUS ULTRASOUND LAB
 47, Harsh Vihar, Pitam p.u.a.
 Delhi-110034
 Ph. 011-42480101, 9599915051
 E-mail: oneplusul@gmail.com



50mm/sec 20mm/mV

ONEPLUS ULTRASOUND LAB

Mr. RANJEET KUMAR BARANWAL

I.D. : 987

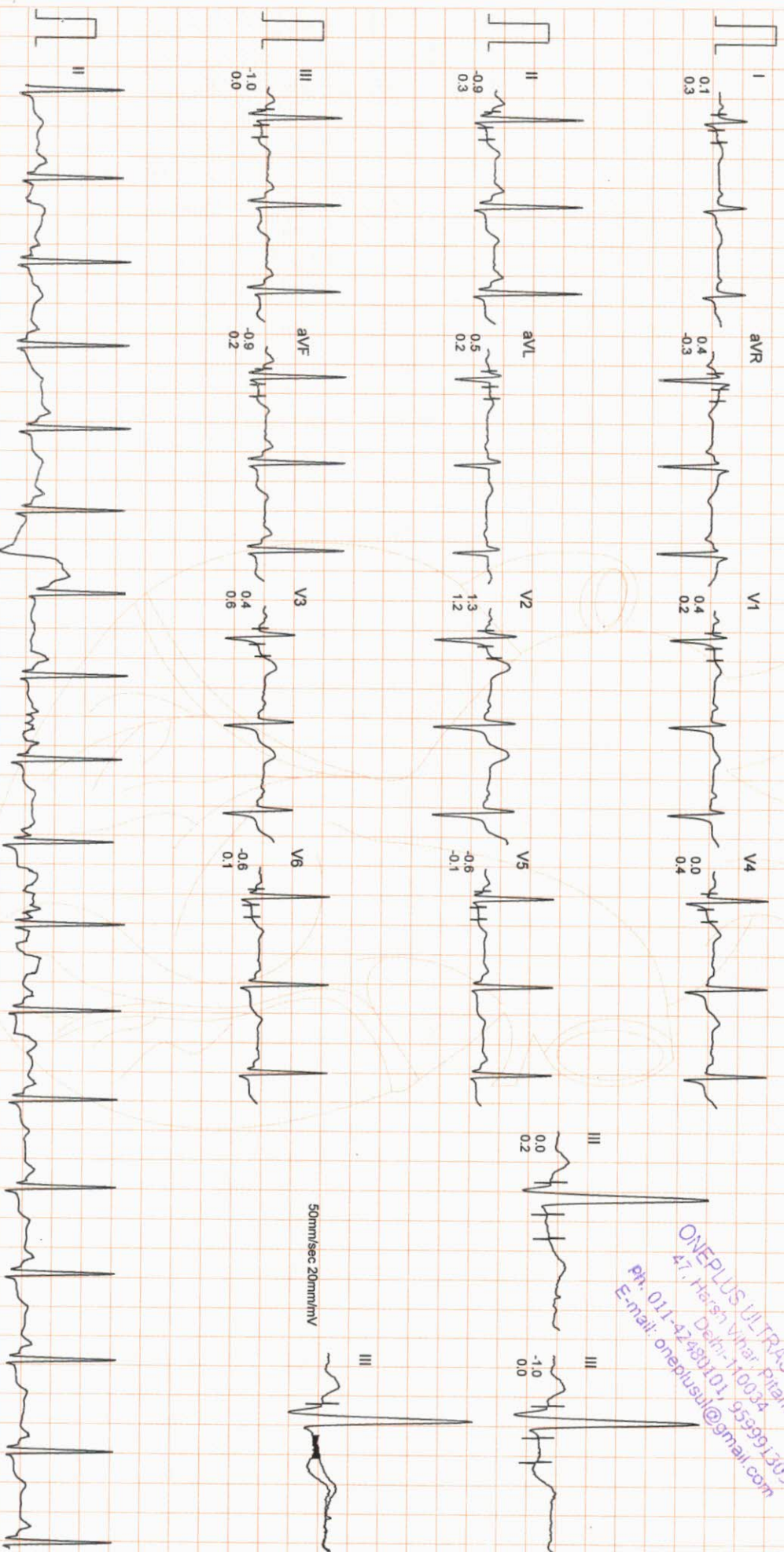
AGE/SEX : 34M

RECORDED : 26-2-2022 10:21

RATE : 103 BPM
B.P. : 134/84 mmHg

BRUCE
RECOVERY
PHASE TIME : 2:59

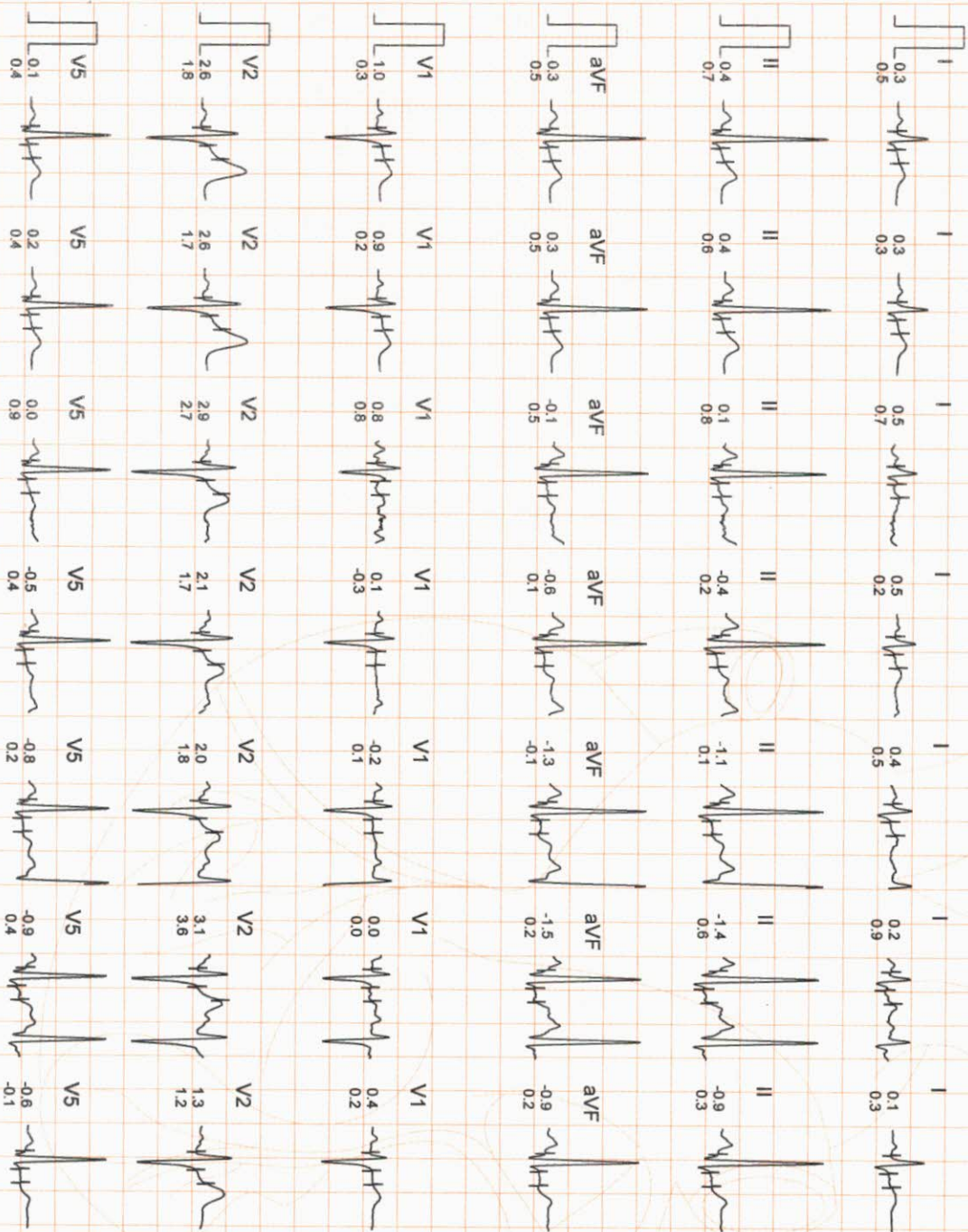
ST @ 10mm/mV
80ms PostJ
SPEED : 0.0 Km./Hr.
GRADE : 0.0 %
LINKED MEDIAN



ONEPLUS ULTRASOUND LAB
47, Harsh Vihar, Pitam Pura,
Delhi-110034
Ph: 011-42480101, 9599913051
E-mail: oneplusul@gmail.com

50mm/sec 20mm/mV

STAGE	STAGE 1	STAGE 2	STAGE 3	PEAK EXERCISE	RECOVERY
SUPINE	STANDING	STAGE 1	STAGE 2	STAGE 3	RECOVERY
0.0kmph 0.0% 68 bpm B.P. 132/84 80ms PostU	0.0kmph 0.0% 74 bpm B.P. 132/84 80ms PostU	2:59 2.7kmph 10.0% 109 bpm B.P. 146/98 80ms PostU	5:59 4.0kmph 12.0% 118 bpm B.P. 158/90 80ms PostU	8:59 5.4kmph 14.0% 137 bpm B.P. 168/92 80ms PostU	11:05 6.7kmph 16.0% 163 bpm B.P. 178/94 80ms PostU




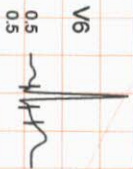

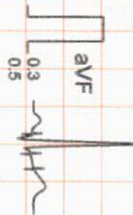
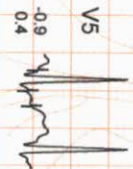
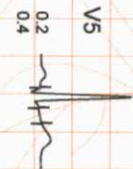

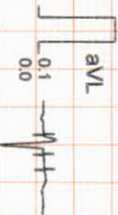




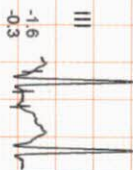
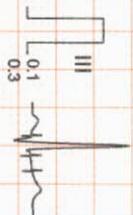
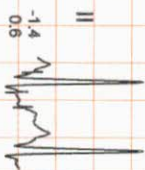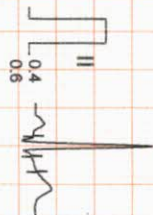




ONEPLUS ULTRASOUND LAB
 47, Harsh Vihar, Pitam Pura,
 Delhi-110034
 Ph: 011-42480101, 9559913051
 E-mail: oneplusul@gmail.com

STANDING
 0.0kmph
 0.0%
 74 bpm
 B.P. 132/84
 80ms PostJ

PEAK EXERCISE
 11:05
 2:05
 6.7kmph
 16.0%
 163 bpm
 B.P. 178/94
 80ms PostJ

STANDING
 0.0kmph
 0.0%
 74 bpm
 B.P. 132/84
 80ms PostJ

PEAK EXERCISE
 11:05
 2:05
 6.7kmph
 16.0%
 163 bpm
 B.P. 178/94
 80ms PostJ



ONEPLUS ULTRASOUND LAB
 47, Harsh Vihar, Pitam Pura,
 Delhi-110034
 Ph: 011-42480101, 9599913051
 E-mail: oneplusul@gmail.com



OnePLUS
Ultrasound Lab
— QUALITY FIRST... ALWAYS! —

Dr. Nitin Agarwal
Pathologist & Director
Ex. Sr. Res. MAMC
& Lok Nayak Hospital
Ex. Chief of Lab Dr. Lal Path Labs.

Dr. Pooja (Garg) Agarwal
Radiologist & Director
MAMC & Lok Nayak Hospital

Name	: Mr. RANJEET KUMAR BARANWAL	Age/Sex	: 34 YRS/Male
Ref. By	: Dr. MEDIWHEEL	Lab No	: 012202260006
Date	: 26-Feb-2022	Patient ID	: LSHHI91724

ULTRASOUND EXAMINATION----WHOLE ABDOMEN

Liver is normal in size (13.9 cm) and normal in outline with normal echopattern. Intrahepatic biliary radicles are not dilated. No abscess or mass lesion seen. Hepatic veins, portal vein, IVC and aorta are normal. CBD is normal in caliber.

Gall bladder is well distended with anechoic lumen. Wall thickness is normal.

Both kidneys are normal in size, shape, position, outline and echopattern. Corticomedullary differentiation is maintained. No pelvicalyceal dilation or mass lesion is seen.

Spleen is normal in size and echotexture. No mass lesion seen.

Pancreas is normal in size, outline and echotexture.

Urinary bladder is normal in shape and position. No evidence of intravesical stone or mass seen.


Prostate is normal in size, shape and echopattern.

Prostate measures 3.5 x 3.4 x 3.9 cm. **Weight of prostate is 24.7 grams.**

No abnormal bowel wall thickening seen in right iliac fossa.
No free fluid seen anywhere in abdomen.

IMPRESSION:

- Normal study.


DR. POOJA GARG
RADIOLOGIST
REG NO. DMC/R/03398
M.B.B.S., D.M.R.D
Reg No. DMC/R/03398
Radiologist

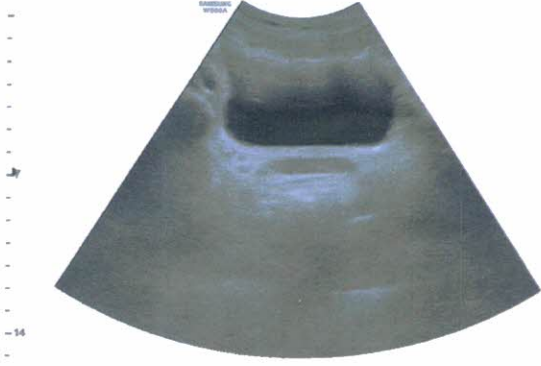
Type By : pooja

47, Harsh Vihar, Pitampura, New Delhi-110034 | Ph.: 011-42480101, 9599913051
E-mail: oneplusul@gmail.com | Web.: www.oneplusul.in

W550A MR RANJEET 34/M OnePlus Ultrasound Lab MI 1.4 26-02-2022
CA1-7A / Abdomen / FR 24Hz Tls 0.1 11:03:45 AM

20 G63 DR135-FAB-P90 Frq Gen. 15.0cm

13.0

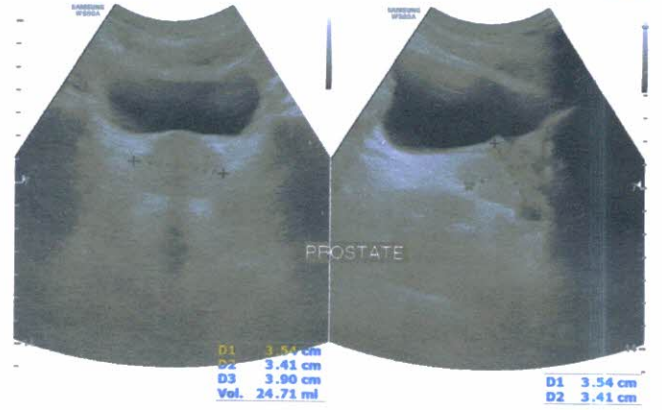


W550A MR RANJEET 34/M OnePlus Ultrasound Lab MI 1.4 26-02-2022
CA1-7A / Abdomen / FR 24Hz Tls 0.1 11:04:01 AM

20 G63 DR135-FAB-P90 Frq Gen. 15.0cm

20 G63 DR135-FAB-P90 Frq Gen. 15.0cm

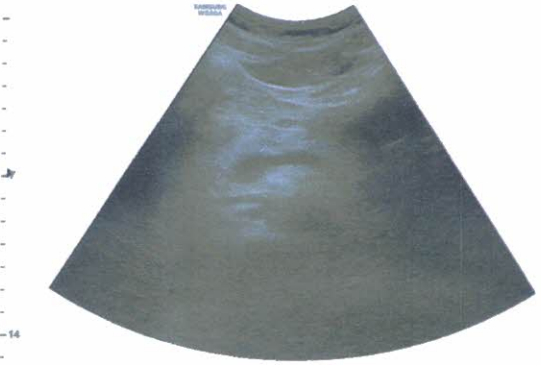13.0



W550A MR RANJEET 34/M OnePlus Ultrasound Lab MI 1.4 26-02-2022
CA1-7A / Abdomen / FR 24Hz Tls 0.1 11:04:08 AM

20 G66 DR135-FAB-P90 Frq Gen. 15.0cm

13.0

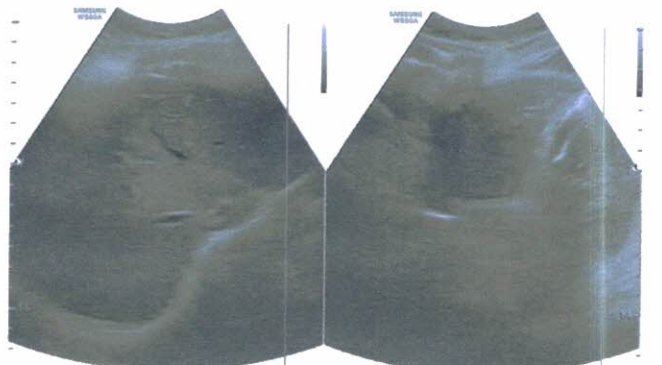


W550A MR RANJEET 34/M OnePlus Ultrasound Lab MI 1.4 26-02-2022
CA1-7A / Abdomen / FR 24Hz Tls 0.1 11:04:19 AM

20 G80 DR135-FAB-P90 Frq Gen. 17.0cm

20 G80 DR135-FAB-P90 Frq Gen. 17.0cm

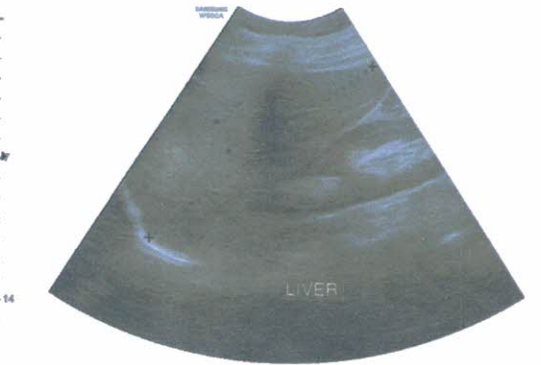
13.0



W550A MR RANJEET 34/M OnePlus Ultrasound Lab MI 1.4 26-02-2022
CA1-7A / Abdomen / FR 24Hz Tls 0.1 11:04:29 AM

20 G89 DR135-FAB-P90 Frq Gen. 17.0cm

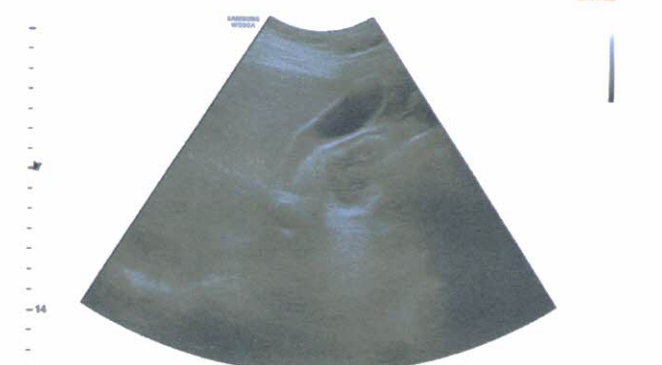13.0



W550A MR RANJEET 34/M OnePlus Ultrasound Lab MI 1.4 26-02-2022
CA1-7A / Abdomen / FR 24Hz Tls 0.1 11:04:38 AM

20 G80 DR135-FAB-P90 Frq Gen. 17.0cm

13.0

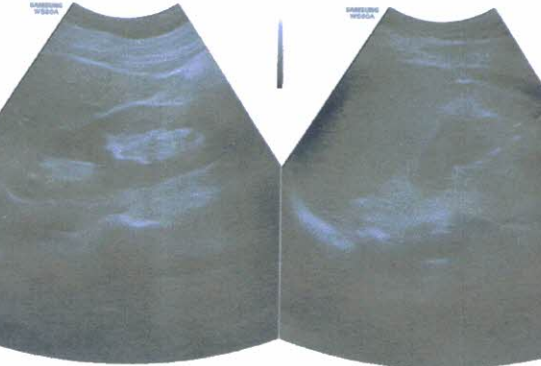


W550A MR RANJEET 34/M OnePlus Ultrasound Lab MI 1.4 26-02-2022
CA1-7A / Abdomen / FR 24Hz Tls 0.1 11:05:00 AM

20 G83 DR135-FAB-P90 Frq Gen. 17.0cm

20 G76 DR135-FAB-P90 Frq Gen. 17.0cm

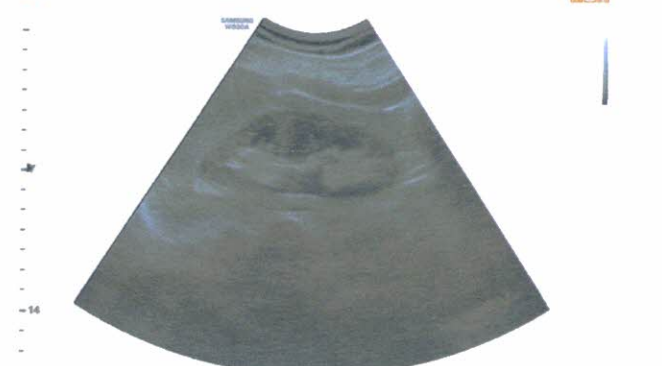13.0



W550A MR RANJEET 34/M OnePlus Ultrasound Lab MI 1.4 26-02-2022
CA1-7A / Abdomen / FR 24Hz Tls 0.1 11:05:07 AM

20 G64 DR135-FAB-P90 Frq Gen. 17.0cm

13.0





OnePLUS
Ultrasound Lab
— QUALITY FIRST... ALWAYS! —

Dr. Nitin Agarwal
Pathologist & Director
Ex. Sr. Res. MAMC
& Lok Nayak Hospital
Ex. Chief of Lab Dr. Lal Path Labs.

Dr. Pooja (Garg) Agarwal
Radiologist & Director
MAMC & Lok Nayak Hospital

Name	: Mr. RANJEET KUMAR BARANWAL	Age/Sex	: 34 YRS/Male
Ref. By	: Dr. MEDIWHEEL	Lab No	: 012202260006
Date	: 26-Feb-2022	Patient ID	: LSHHI91724

X-ray-Chest PA view

Bony cage and soft tissues are normal.

Cardiothoracic ratio is normal.

Mediastinum is normal.

Both hila are normal.

Both costophrenic angles are clear.

Both domes of diaphragm are normal.

Lung fields are clear. No parenchymal lesion seen.

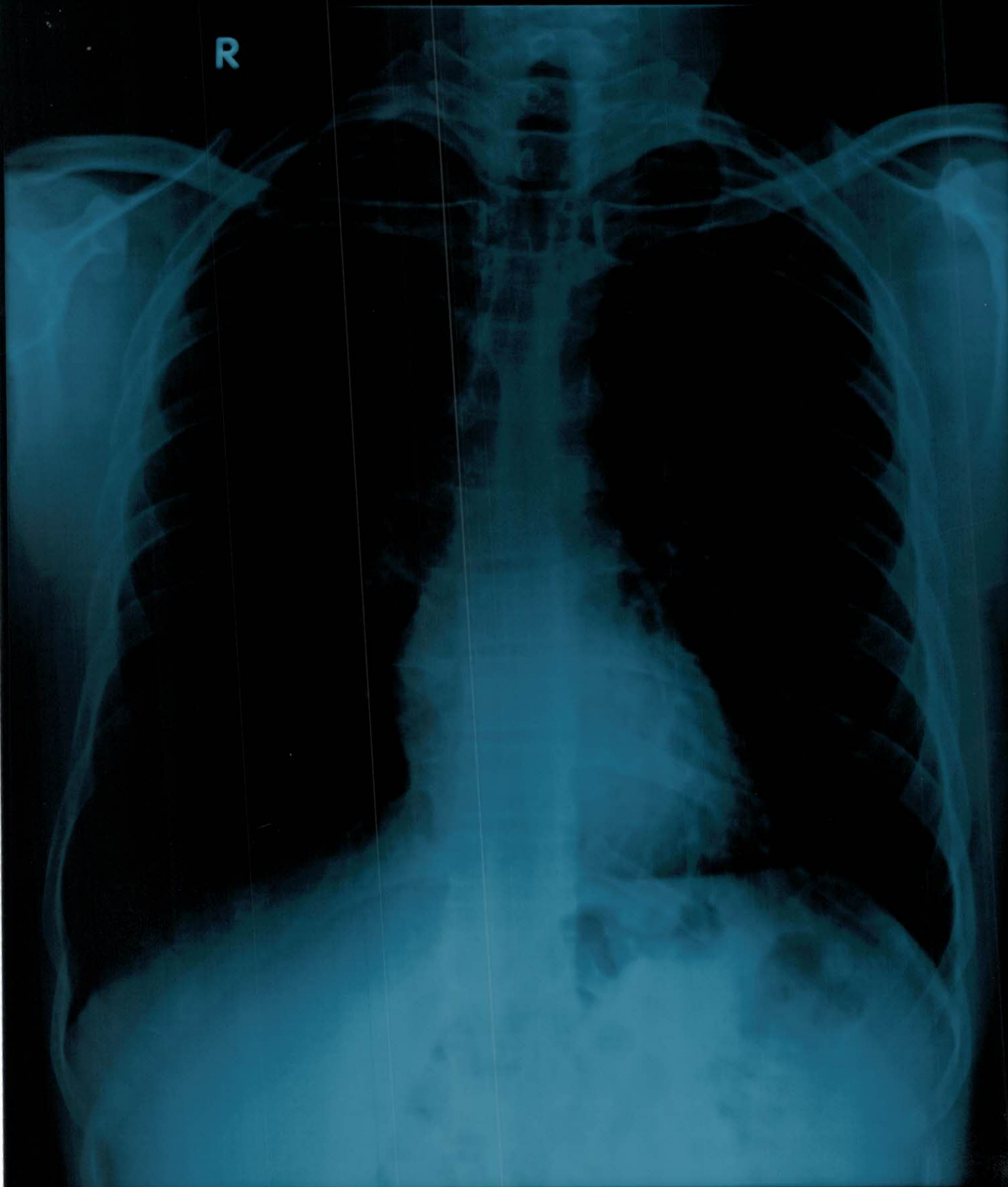IMPRESSION: Normal Study.


DR. POOJA GARG
RADIOLOGIST
REG NO- DMC/R/03398
Dr. POOJA GARG
M.B.B.S., D.M.R.L
Reg No. DMC/R/03398
Radiologist

Type By : pooja

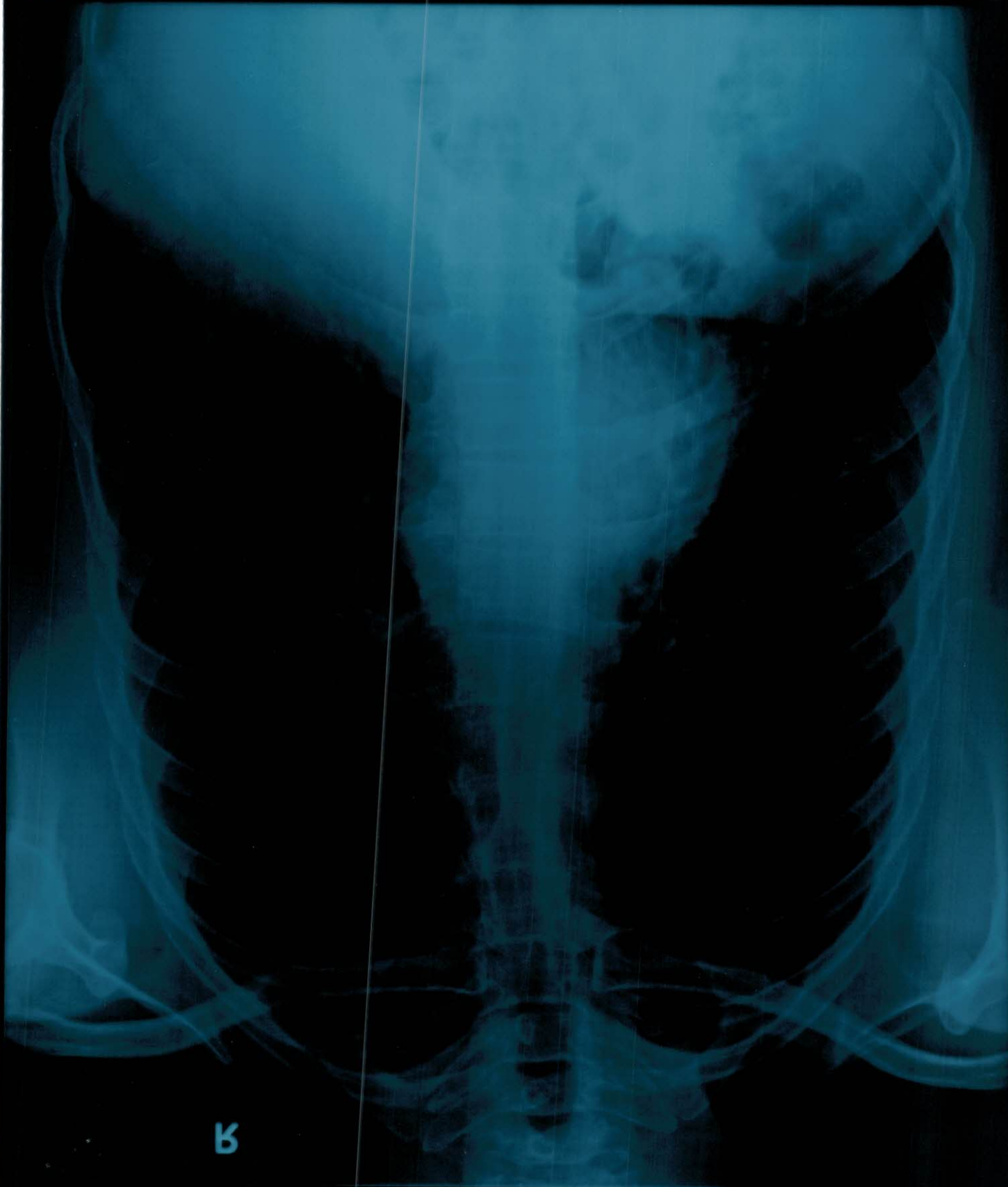47, Harsh Vihar, Pitampura, New Delhi-110034 | Ph.: 011-42480101, 9599913051
E-mail: oneplusul@gmail.com | Web.: www.oneplusul.in

R



MR RANJEET KUMAR BARANWAL AGE 34 YRS 26-2-2022 M
ONEPLUS ULTRASOUND LAB,47-HARSH VIHAR,PITAMPURA

ОИЕБГУС ПГТРАСОИИД ГАВ, 47-НАР2Н УИНАР, РИТАМБУРА
МР ВАНДЕТ КУМАР ВАРАИМАГ АСЕ 34 УР2 38-5-5055 M



B