

DATE: 12-04-2023

HEIGHT - 147 cm.

WEIGHT: 62.2 kg.

S/B DR. JAYDEEP BHAMBARE

PATIENT NAME: Chandrakala K. Kordile

AGE/SEX 43 Yr

PR - 62 bpm

RR - 24 bpm

SpO₂ - 97 %

B.P. - 106/65 mmHg

CBC - 10.9 | 8700 | 296

HbA1C - 6.1

F/PP - 98.3 | 105

creat - 0.86

Uric acid - 3

Lipids - 235 | 295 | 130

SGPT - 15.3

Bili - 0.6

Total proteins - 7.2

TSH - 2.673

Urine - Pus cells - 10-12

Epithelial cells 18-20

Calcium oxalate ⊕

① Anemia

② had fungal infection
 confirmed

③ neuralgia prosthesis;

④ renal small stones
 No symptoms

⑤ dyslipidemia

⑥ Allergic Rhinitis

ECHOCARDIOGRAPHY AND COLOUR DOPPLER IMAGING

PATIENT NAME:- CHANDRAKALA KARDILE

AGE/SEX- 43 YRS/F

DATE :-10/04/2023

REF:- MEDIWHEEL INSURANCE

Normal LV Size & Function

No regional wall motion abnormality.

Normal LV & RV systolic function. LVEF-60%.

No S/o Diastolic Dysfunction.

Trivial Mitral Regurgitation.

Left atrium is normal.

Normal RA and RV size and shape.

Normal RV systolic function.

PASP - 20 mmHg


No Pulmonary Hypertension.

IVC Collapsing with respiration. No Clot/Vegetation.

IVS and IAS are intact.

Normal pericardium. No effusion.

IMPRESSION:- Trivial MR with Good LV Function with LVEF- 60%



DR. RAHUL SHEVALE

M.D. (Medicine)

D.M. (Cardiology)

Consultant Cardiologist

NAME: MRS. CHANDRAKALA KARDILE	DATE: 08/04/2023
AGE/ SEX: 43 YEARS / MALE	REFERRED BY: HEALTH CHECKUP

XRAY CHEST PA (VIEW)

Both the lungs are clear and do not show any obvious focal lesion.

Bilateral costo-phrenic and cardio-phrenic angles appear clear.

There is no evidence of pleural effusion or pneumothorax on either side.

Both the hilum appear normal.

Domes of diaphragm have normal contours and positions.

Visualised bones and soft tissues reveal no abnormality.

CONCLUSION:

No significant abnormality is seen.

Advise clinical correlation.


DR TRIPTI PAREEK
(DNB RADIOLOGIST)

NAME: MRS. CHANDRAKALA KARDILE	DATE: 08/04/2023
AGE/ SEX: 43 YEARS/ FEMALE	REFERRED BY: HEALTH CHECKUP

ULTRASOUND ABDOMEN & PELVIS

Clinical profile- Health checkup

Liver: Normal in size (11.8 cm), shape and shows normal echotexture. No evidence of any space occupying lesion seen. Intrahepatic biliary radicals are not dilated. Portal vein is normal in caliber.

Gallbladder: GB is collapsed. No wall thickening/pericholecystic fluid collection seen. CBD is normal in caliber.

Pancreas: Visualized in its entire extent and appears normal in bulk & echotexture.

Spleen: Appears normal in size (8.3 cm), shape and echotexture. No calcification or mass is seen.

Kidneys: Right kidney – 10.2 x 3.3 cm. Left kidney – 10.4 x 3.6 cm.

Both kidneys are normal in size, shape, positions and echotexture. Bilateral corticomedullary differentiation appears normal. No hydronephrosis seen. No evidence of any calculus or mass lesion seen.

Urinary Bladder: is well distended. No evidence of calculus/ wall thickening noted.

Uterus is retroverted measures 6.8 x 4.9 x 3.3 cm appears normal in size, shape and echotexture. Endometrium appears normal measuring 7 mm. No evidence of adnexal abnormality.

Right ovary measures :- 1.6 x 0.9 cm.

Left ovary measures :- 1.6 x 1.1 cm.

Bilateral ovaries appear normal in size, shape and echotexture.

Free fluid: No evidence of any free fluid in peritoneal cavity.

IMPRESSION:

No significant abnormality seen.

Clinical correlation is suggested.


DR TRIPTI PAREEK
(DNB RADIOLOGIST)

NAME: MRS. CHANDRAKALA KARDILE	DATE: 08/04/2023
AGE/ SEX: 43 YEARS/ FEMALE	REFERRED BY: HEALTH CHECKUP

ULTRASOUND SCAN OF BOTH BREAST

Ultrasound examination of both breast done with high frequency linear transducer.

Both breasts appear normal in echotexture. No e/o any focal lesion.

Both areolar regions are normal.

Ductal systems appear normal on both sides.

Underlying pectoral muscles appear normal.

No e/o axillary lymphadenopathy.

IMPRESSION:

- No obvious sonographic abnormality detected.

Advise clinical correlation.



DR TRIPTI PAREEK
(DNB RADIOLOGIST)

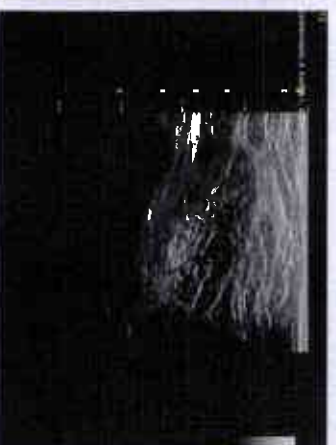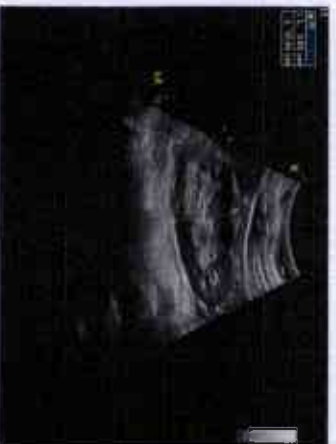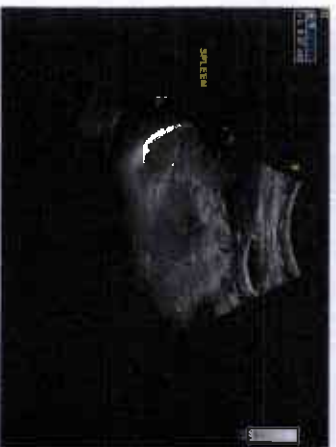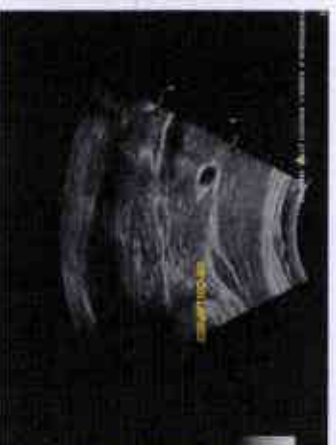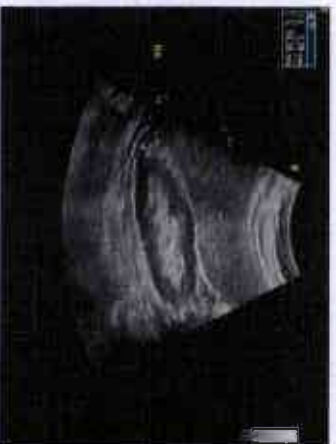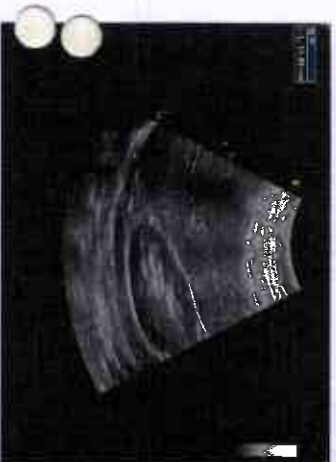
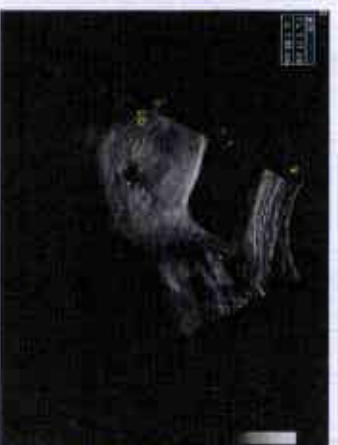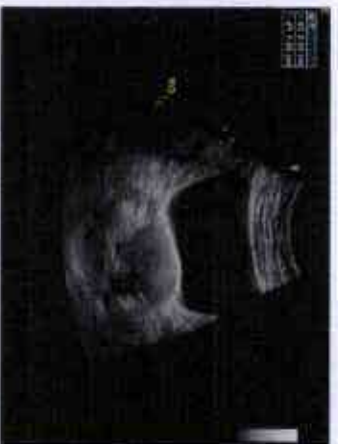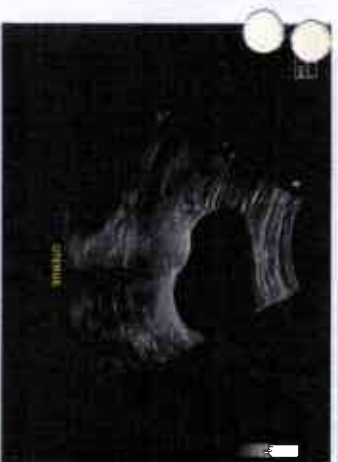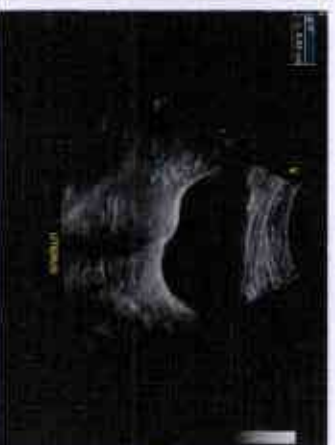
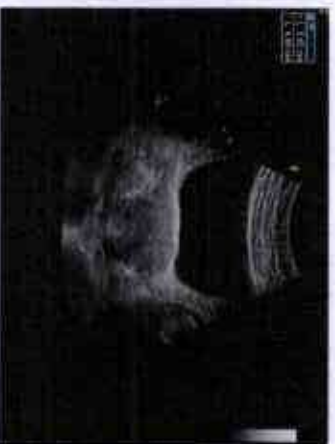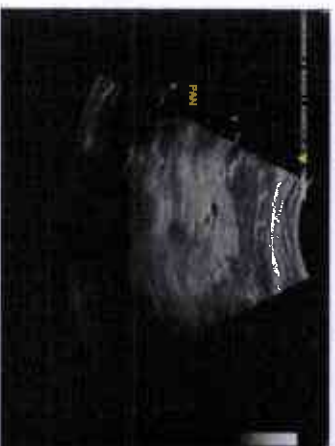**MAGNUM MULTISPECIALITY HOSPITAL
NASIK ROAD, NASHIK**

Name KARDILE, CHANDRAKALA

Sex Female

Age 43

Date 08/04/2023



**MAGNUM MULTISPECIALITY HOSPITAL
NASIK ROAD, NASHIK**

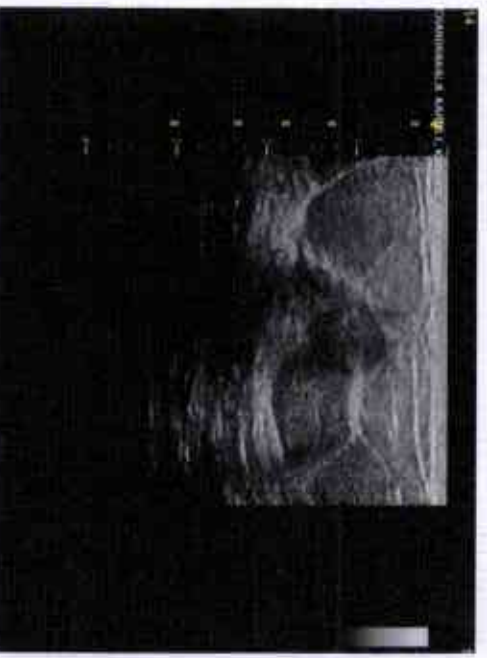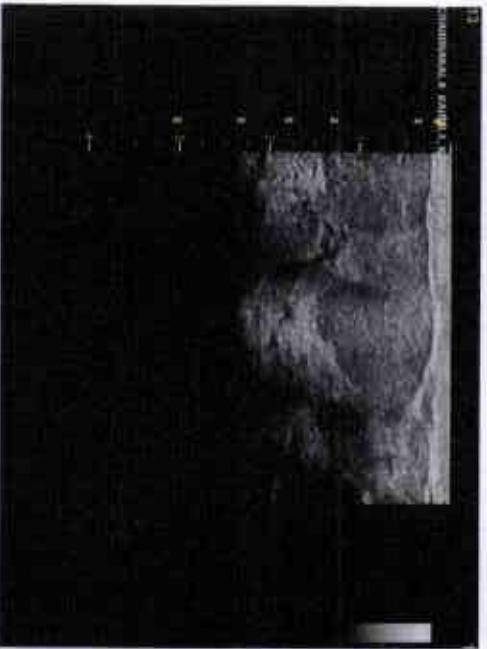
Name KARDILE, CHANDRAKALA

Sex Female

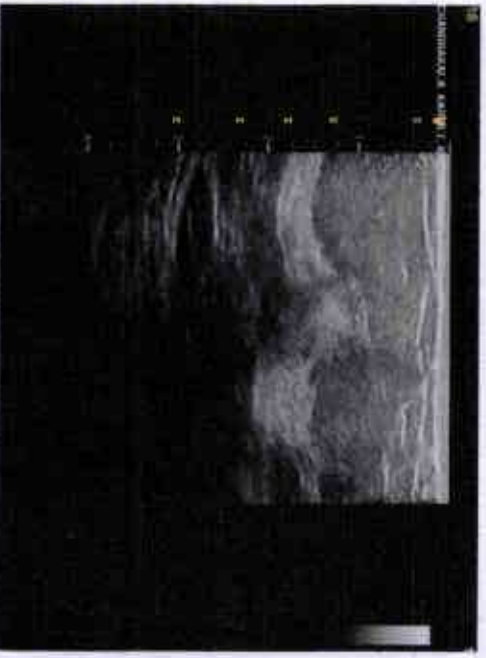
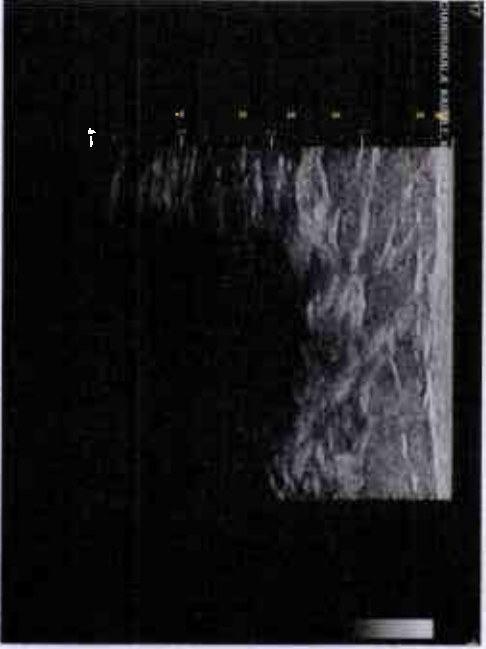
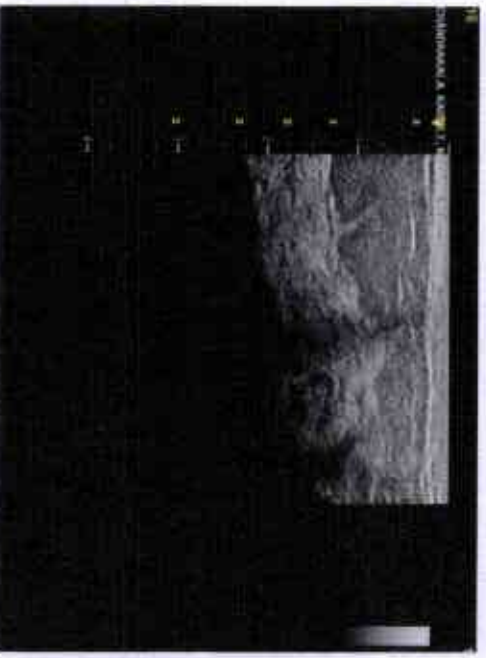
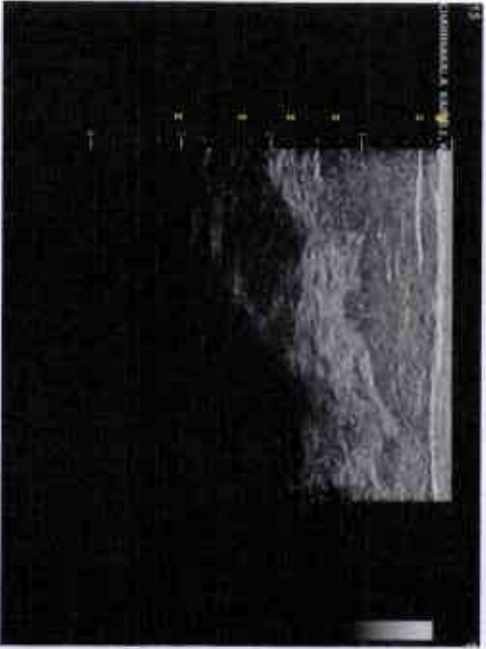
Age 43

Date 08/04/2023

3



3



ID: 0

CHANDRAKALA KARDIL

Female 43years

Department: ER

08-04-2023 09:06:31 AM

HR : 60 bpm

P : 108 ms

PR : 154 ms

QRS : 88 ms

QT/QTc : 446/446 ms

P/QRS/T : 46/11/22 °

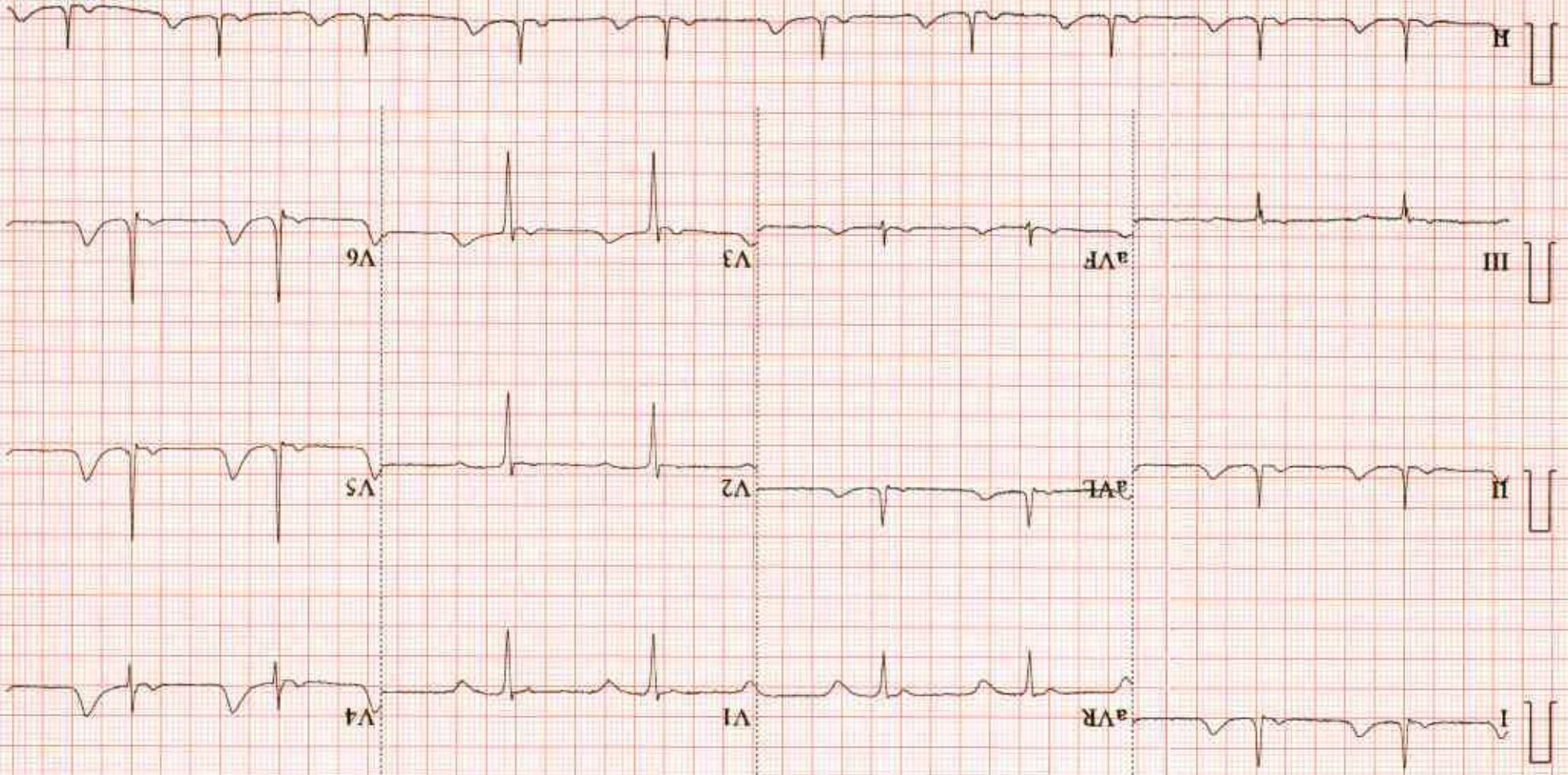
RV5/SV1 : 1.524/1.003 mV

Diagnosis Information:

Sinus rhythm

Normal ECG

Report Confirmed by:



0.05-35Hz AC50 25mm/s 10mm/mV 4*2.5s+1r 60 SE-1200Express V2.1 Glasgow V28.60 MAGNUM MULTISPECIALIT