

Name : Mr. PRADHAN CHANDRASHEKAR

Age: 52 Y

UHID:CKOR.0000248190

Sex: M

Address : KML

Plan : ARCOFEMI MEDIWHEEL MALE AHC CREDIT PAN
 INDIA OP AGREEMENT

OP Number:CKOROPV389362

Bill No :CKOR-OCR-79167

Date : 27.11.2023 08:26

Sno	Service Type/ServiceName	Department
1	ARCOFEMI - MEDIWHEEL - FULL BODY ANNUAL PLUS ABOVE 50Y MALE - 2D ECHO - PAN INDIA - FY2324	
✓1	URINE GLUCOSE(FASTING)	
✓2	GAMMA GLUTAMYL TRANSFERASE (GGT)	
✓3	PROSTATIC SPECIFIC ANTIGEN (PSA TOTAL)	
✓4	HbA1c, GLYCATED HEMOGLOBIN	
✓5	2 D ECHO R10	
✓6	LIVER FUNCTION TEST (LFT)	
✓7	X-RAY CHEST PA R-11	
✓8	GLUCOSE, FASTING	
✓9	HEMOGRAM + PERIPHERAL SMEAR	
✓10	ENT CONSULTATION R-23 Dr. Nijane.	
11	FITNESS BY GENERAL PHYSICIAN	
12	DIET CONSULTATION	
✓13	COMPLETE URINE EXAMINATION	
14	URINE GLUCOSE(POST PRANDIAL)	
✓15	PERIPHERAL SMEAR	
✓16	EKG R-14	
✓17	BLOOD GROUP ABO AND RH FACTOR	
✓18	LIPID PROFILE	
19	BODY MASS INDEX (BMI)	
✓20	OPHTHAL BY GENERAL PHYSICIAN R-20 ✓	
✓21	RENAL PROFILE/RENAL FUNCTION TEST (RFT/KFT)	
✓22	ULTRASOUND - WHOLE ABDOMEN	
✓23	THYROID PROFILE (TOTAL T3, TOTAL T4, TSH)	
24	DENTAL CONSULTATION R-15	
✓25	GLUCOSE, POST PRANDIAL (PP), 2 HOURS (POST MEAL)	

② Physio

Ht - 165 cm
 wt - 62.1 kg



DR VIJAYA LAKSHMI M
M.B.B.S, D.L.O, D.N.B(ENT)
 Phone No.9972044580,080-25633823/24/23



Apollo Medical
Centre
Expertise. Closer to you

27/11/23

HEALTH CHECK- ENT

NAME: Prathin Chandrabekal

AGE: 52

EAR:

RE:

LE:

EXTERNAL EAR

MIDDLE EAR

INNER EAR (FN)

Normal

HEARING ASSESSMENT:

RE:

LE:

RHINNE

WEBER

ABC

Normal

NOSE

THROAT

AIRWAY

ORAL CAVITY

SEPTUM

OROPHARYNX

TURBINATES

PHARYNX

OTHERS

LARYNX

Normal

NECK

NECK NODES

OTHER

Normal

AUDIOMETRY

IMPRESSION

Normal

[Signature]
SIGNATURE:

Apollo Health and Lifestyle Limited

(CIN - U85110TG2000PLC046089) Regd. Office: #7-1-617/A, 615 & 616, Imperial Towers, 7th Floor, Ameerpet, Hyderabad, Telangana - 500 038 | Email ID: enquiry@apollohi.com

APOLLO CLINICS NETWORK KARNATAKA

Bangalore (Basavanagudi | Bellandur | Electronics City | HSR Layout | Indira Nagar | JP Nagar | Kundalahalli | Koramangala | Sarjapur Road) **Mysore** (Kalladasa Road)

Online appointments: www.apolloclinic.com

TO BOOK AN APPOINTMENT

1860 500 7788



DR. MAHABALESHWAR.M
MBBS.(MYS), MD(AIIMS DELHI)FICS
D.O (JIPMER)
REG.NO:KMC:9748

DATE: 27/11/20
OP NO:

THE APOLLO MEDICAL CENTER KORAMANGALA

NAME: Pradhane Keshav
AGE : 52
GENDER: M

OPHTHALMIC REPORT A/o diabetes

RIGHT EYE

LEFT EYE

GENERAL APPEARANCE

VISION - DISTANCE

WITHOUT GLASS

6/6

6/6

WITH GLASS

GLASS POWER

-9 ball

NEAR

WITHOUT GLASS

N6

N6

WITH. GLASS

GLASS POWER

COLOUR

- normal

ANTERIOR SEGMENT:-

FUNDUS - WMC

} WMC

Ad Regular
followup

I.O.P: DIGITAL

20

DOCTOR SIGNATURE

NAME: MR.PRADHAN CHANDRASHEKAR AR
AGE: 52Y

SEX: MALE

DATE: 27/11/2023

ECHOCARDIOGRAPHY REPORT

MEASUREMENT

AO -24(20 – 35)mm	LIVD d – 42(36-52)mm	IVS - 10 (06 - 11)mm
LA -37(19- 40)mm	LVID s - 29 (23- 39)mm	PWD – 09(06- 11)mm
EF - 60% (>50%)	RVID-22	

VALVES

Mitral Valve : Normal
Aortic Valve : Normal
Tricuspid Valve : Normal
Pulmonary Valve : Normal

CHAMBERS

Left Atrium : Normal
Right Atrium : Normal
Left Ventricle : Normal
Right Ventricle : Normal

SEPTAE

IVS : Intact
IAS : Intact

GREAT ARTERIES

Aorta : Normal
Pulmonary Artery : Normal

DOPPLER DATA

Mitral : E > A , MILD MR
Aortic : Normal
Tricuspid : Normal
Pulmonary : Normal

WALL MOTION ABNORMALITIES : No RWMA

Pericardium : Normal

FINAL DIAGNOSIS
NORMAL CHAMBERS AND VALVES, MILD MR
NORMAL BIVENTRICULAR FUNCTION
NO RWMA AT REST, LV EF -60%

XX TO CORRELATE CLINICALLY XX


DR. MOHAN MURALI
CONSULTANT
CARDIOLOGIST

Patient Name : Mr Pradhan Chandrashekar
Age : 52 Year(s)
Referring Doctor : H/C

Patient ID : 248190
Sex : Male
Date : 27.11.2023

ULTRASOUND ABDOMEN AND PELVIS

FINDINGS:

Liver is normal in size and shows normal echotexture. No biliary dilatation. No focal lesion
CBD is not dilated. **Portal vein** is normal in size, course and calibre.

Gall bladder is normal without evidence of calculi, wall thickening or pericholecystic fluid.

Pancreas to the extent visualized, appears normal in size, contour and echogenicity

Spleen is normal in size, shape, contour and echopattern. No evidence of mass or focal lesions.

Right Kidney is normal in size, position, shape and echopattern. Corticomedullary differentiation is maintained. No evidence of calculi or hydronephrosis.

Left Kidney is normal in size, position, shape and echopattern. Corticomedullary differentiation is maintained. No evidence of calculi or hydronephrosis.

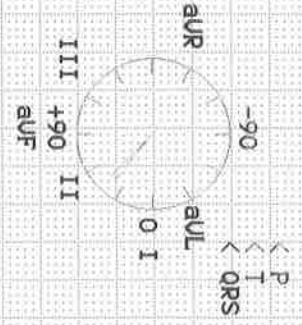
Urinary Bladder is well distended. Wall thickness is normal. No evidence of calculi, mass or mural lesion.

Prostate: normal in size and echotexture. There is no ascites.

IMPRESSION: NO SIGNIFICANT ABNORMALITY DETECTED

**DR VINOD JOSEPH DNB,DMRD
RADIOLOGIST**

AGE: 52
 Measurement Results:
 QRS : 95 ms
 QT/QTcB : 358 / 415 ms
 PR : 136 ms
 P : 96 ms
 RR/PP : 740 / 750 ms
 P/ORS/T : 45 / 45 / 40 degrees
 QTd/QTcBd : 66 / 77 ms
 Sokolow NK : 1.8 mV
 NK : 12

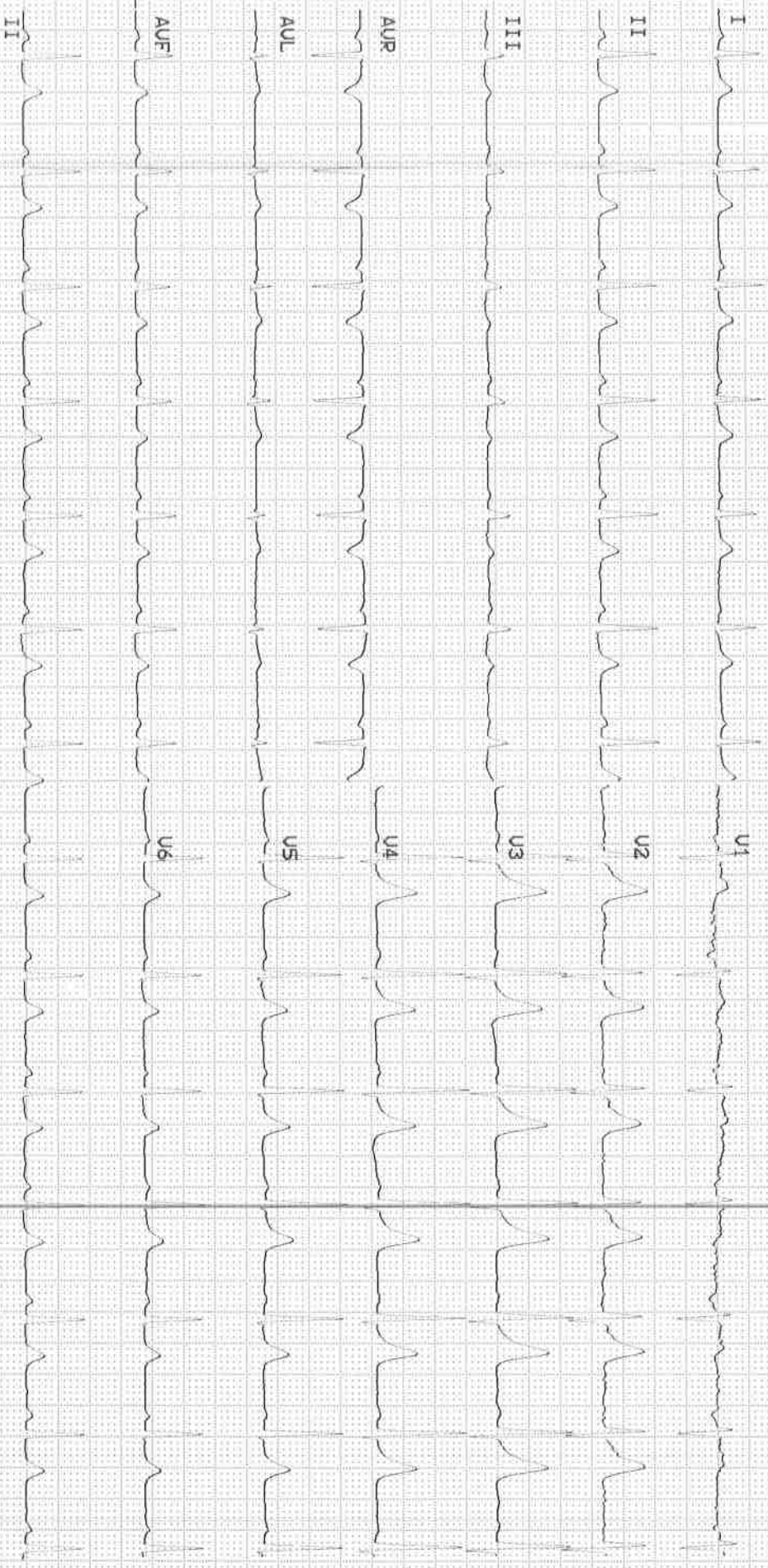


Interpretation:

Normal sinus rhythm

[Handwritten signature]

Unconfirmed report.



25 Nov 2023 11:25:30 25 Nov 2023 10:44:40 400 5000 0.05 0.05 0.05 0.05 0.05 0.05 0.05 0.05 0.05 0.05 0.05 0.05

Patient Name	: Mr. PRADHAN CHANDRASHEKAR	Age	: 52 Y/M
UHID	: CKOR.0000248190	OP Visit No	: CKOROPV389362
Reported By:	: Dr. TOBY ABRAHAM THOMAS	Conducted Date	: 28-11-2023 08:33
Referred By	: SELF		

ECG REPORT

Observation :-

1. Normal Sinus Rhythm.
2. Heart rate is 81 beats per minutes.
3. No pathological Q wave or S-T,T changes seen.
4. Normal P,Q,R,S,T waves and axis.
5. No evidence of chamber, hypertrophy or enlargement seen.

Impression:

NORMAL RESTING ECG.

Dr.TOBY ABRAHAM THOMAS
CONSULTANT

NOTE:KINDLY TAKE A PHOTOCOPY OF THE GRAPH
FOR FUTURE REFERENCE IF NEEDED.

-----END OF THE REPORT--

Patient Name	: Mr. PRADHAN CHANDRASHEKAR	Age	: 52 Y M
UHID	: CKOR.0000248190	OP Visit No	: CKOROPV389362
Reported on	: 27-11-2023 12:50	Printed on	: 27-11-2023 17:31
Adm/Consult Doctor	:	Ref Doctor	: SELF

DEPARTMENT OF RADIOLOGY

X-RAY CHEST PA

Right apical ill defined opacity seen.

Rest of the lungs fields appear normal.

Both hila are normal.

Both costophrenic and cardiophrenic angles are normal.

The cardiac and mediastinal shadows appear normal.

Bones and soft tissues appear normal. Right

IMPRESSION :

RIGHT APICAL ILL DEFINED OPACITY POSSIBLE FIBROSIS


DR VINOD JOSEPH DNB,DMRD
RADIOLOGIST

Printed on: 27-11-2023 12:50

---End of the Report---