

Health Check up Booking Request(bobE43544), Beneficiary Code-56378

1 message

Mediwheel <wellness@mediwheel.in>
 To: vidhidiagnostics@gmail.com
 Cc: customercare@mediwheel.in

5 August 2023 at 17:23



Mediwheel
 ...Your wellness partner

011-41195959

Email:wellness@mediwheel.in

Dear **VIDHI DIAGNOSTICS,**

City : Ahmedabad . **Address** : L-86 Swatantra - Senani Nagar , Opp- Akhbarnagar Bus Terminals,
 New Wadaj , Ahmedabad -13,

We have received the confirmation for the following booking .

Name : MR. VAGHELA CHANDRAKANT RAMESHBHAI
Age : 34
Gender : Male
Package Name : Medi-Wheel Metro Full Body Health Checkup Male Below 40
Contact Details : 7096237521
Booking Date : 05-08-2023
Appointment Date : 23-09-2023

| Member Information | | | |
|------------------------------------|-----|--------|-----------------|
| Booked Member Name | Age | Gender | Cost(In INR) |
| MR. VAGHELA CHANDRAKANT RAMESHBHAI | 34 | Male | Cashless |
| Total amount to be paid | | | Cashless |

We will get back to you with confirmation update shortly. Please find the package details as attached for your reference.

Package Name : Medi-Wheel Metro Full Body Health Checkup Male Below 40 - Includes (37)Tests

Tests included in this Package : Ecg, TSH, X-ray Chest, Stress Test (tmt)/ 2d Echo, Blood Sugar Postprandial, A:g Ratio, Blood Group, Total Cholesterol, Triglycerides, Fasting Blood Sugar, Ultrasound Whole Abdomen , Glycosylated Haemoglobin (hba1c), Hdl, Vldl, Urine Analysis, LDL, Total Protine, General Consultation, HDL/ LDL ratio, GGT(Gamma-glutamyl Transferase), Eye Check-up consultation, ALP (ALKALINE PHOSPHATASE), Uric Acid, AST/ALT Ratio, Serum Protein, CBC with ESR, Stool Analysis, Urine Sugar Fasting, Urine Sugar PP, T3, T4, Cholesterol Total / HDL Ratio, BUN, BUN/Creatinine Ratio, Bilirubin Total & Direct and Indirect, Albumin, Globulin

Dr. Dinesh S. Modh

M.D., D.M.R.E. (Radiodiagnosis)

Consultant Radiologist & Sonologist

Ex. Junior Lecturer, B.J. Medical College, Civil Hospital, A'bad.



19/09/2023

Vaghela Chandrakant

36 yr. / male

Height : 169 cm.

Weight : 77 kg

Bp : 128/88 mmHg

Pulse : 84 per min.

T : normal

RS : normal
CVS : normal

SPO₂ : 98

Asymptomatic

NO H/O DM, HTN, Thyroid or TB.

Adv: He is medically fit.

Eye check up

- O/G - within normal limit
- N/G - within normal limit
- NO night and colour blindness.

Dr. Vidhi D. Modh

MBBS

Reg. No. 74540

ISO 9001:2015 Certified Diagnostics Center

Vidhi Imaging Center

L-86, Swatantra Senani Nagar, Opp. Indian Oil Petrol Pump, Akhbaragar Circle, Nava Vadaj, Ahmedabad - 380 013.

Phone : (Radiology) 079-2762 1406 | M. 98799 29406, 98250 09406 | Time (Radiology) : Mon. to Sat. 9 am to 2 pm, 5 to 9 pm, Sunday 9 am to 12 Noon

E-mail : vidhidiagnostics@gmail.com, Website : www.vidhidiagnostics.com

Vidhi Diagnostics

L-86, Swatantra-Senani Nagar,
Opp. Akhbaragar Bus Terminals,
Nr. Akhbaragar Circle,
New Wadaj, Ahmedabad-13.

Multislice CT Scan | CBCT-Dental Scan | Live 3D-4D Sonography | Colour Doppler | Echo Cardiography | Interventional Radiology | Maxillofacial Radiology | Fetal Medicine
Digital X-Ray | Digital Mammography | Digital OPG/TMJ | ECG/TMT/PFT/EEG/EMG | Audiometry | Pathology Laboratory | Health Check Up Plans | Pre Employment Check Up

CT SCAN & CBCT FACILITY NOW AVAILABLE

Dr. Dinesh S. Modh

M.D., D.M.R.E. (Radiodiagnosis)

Consultant Radiologist & Sonologist

Ex. Junior Lecturer, B.J. Medical College, Civil Hospital, A'bad.



Patient's name: CHANDRAKANT VAGHELA
Reg. ID : R-7151-23
Referred by : Dr. MEDIWHEEL

Age/Sex : 36 Years/Male
Accession : 13455
Date : 19/09/2023

USG ABDOMEN

LIVER:- Liver appears normal in size & echo texture. No evidence of focal lesion is seen. IHBR appear normal. Portal vein and CBD appear normal. No e/o calculus is seen in bile duct.

GALL BLADDER:- Gall bladder is distended & appears normal. No evidence of calculus or cholecystitis is seen.

SPLEEN:- Spleen appears normal in size & shows normal echo texture. No evidence of diffuse or focal lesion is seen.

PANCREAS:- Pancreas appears normal size and echo pattern. No e/o diffuse or focal lesion is seen. Main pancreatic duct appears normal.

KIDNEY:- Both Kidneys appear normal in size & echo texture.

- No e/o calculus or hydronephrosis/ hydroureter is seen on both sides.

Cortico-medullary differentiation is maintained on both sides.

Both suprarenal regions appear normal.

No evidence of pre & para aortic lymphadenopathy is seen.

Both suprarenal regions appear normal.

No evidence of pre & para aortic lymphadenopathy is seen.

RIF & BOWEL LOOPS (By high frequency probe):-Normal.

No evidence of dilated or thickened bowel loops is seen.

No evidence of free fluid is seen in abdomen.

Urinary bladder:- appears normal. No e/o calculus or mass lesion is seen in bladder.

Prostate appears normal size and echopattern.

Thanks for reference.

Dr. Dinesh S. Modh

DR. DINESH S. MODH (Radiodiagnosis)

M.D. DMRE (RADIODIAGNOSIS)

ISO 9001:2015 Certified Diagnostics Center

Vidhi Imaging Center

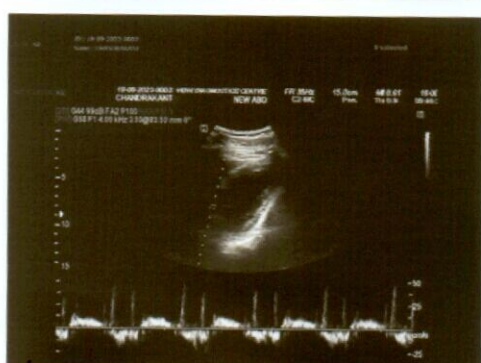
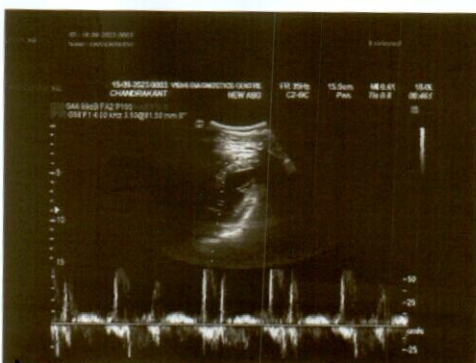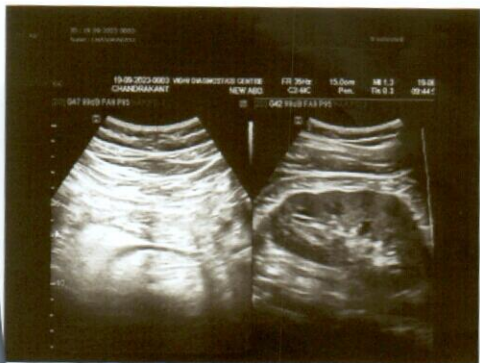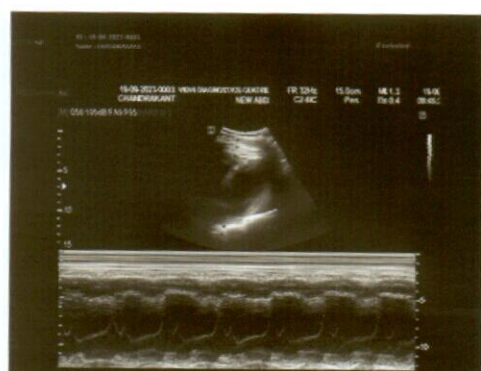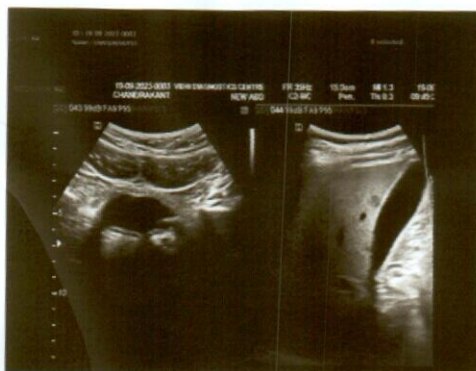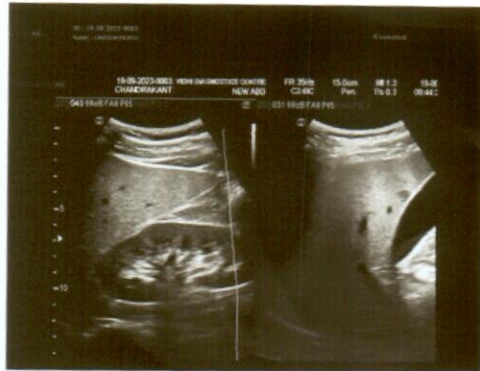L-86, Swatantra Senani Nagar, Opp. Indian Oil Petrol Pump, Akhbarnagar Circle, Nava Vadaj, Ahmedabad - 380 013.

Phone : (Radiology) 079-2762 1406 | M. 98799 29406, 98250 09406 | Time (Radiology) : Mon. to Sat. 9 am to 2 pm, 5 to 9 pm, Sunday 9 am to 12 Noon

E-mail : vidhidiagnostics@gmail.com, Website : www.vidhidiagnostics.com

Multislice CT Scan | CBCT-Dental Scan | Live 3D-4D Sonography | Colour Doppler | Echo Cardiography | Interventional Radiology | Maxillofacial Radiology | Fetal Medicine
Digital X-Ray | Digital Mammography | Digital OPG/TMJ | ECG/TMT/PFT/EEG/EMG | Audiometry | Pathology Laboratory | Health Check Up Plans | Pre Employment Check Up

CT SCAN & CBCT FACILITY NOW AVAILABLE



Chandrekant

Medi wce/

Dr. Dinesh S. Modh

M.D., D.M.R.E. (Radiodiagnosis)

Consultant Radiologist & Sonologist

Ex. Junior Lecturer, B.J. Medical College, Civil Hospital, A'bad.



Patient's name : CHANDRAKANT VAGHELA
Reg. ID : R-7151-23
Referred by : Dr. MEDIWHEEL

Age/Sex : 36 Years/Male
Accession : 13455
Date : 19/09/2023

X-RAY CHEST (PA VIEW)

Both lung fields appear normal.
No e/o consolidation or cavitations is seen.
Both costo-phrenic angles appear clear.
Cardiac size is within normal limits.
Both domes of diaphragm appear normal.
Bony thoracic cage appears normal.

Thanks for reference.

Dr. Dinesh S. Modh

MD DMRE (Radiodiagnosis)

DR DINESH S MODH

M.D. DMRE(RADIODIAGNOSIS)

ISO 9001:2015 Certified Diagnostics Center

Vidhi Imaging Center

L-86, Swatantra Senani Nagar, Opp. Indian Oil Petrol Pump, Akhbarnagar Circle, Nava Vadaj, Ahmedabad - 380 013.

Phone : (Radiology) 079-2762 1406 | M. 98799 29406, 98250 09406 | Time (Radiology) : Mon. to Sat. 9 am to 2 pm, 5 to 9 pm, Sunday 9 am to 12 Noon

E-mail : vidhidiagnostics@gmail.com, Website : www.vidhidiagnostics.com

Multislice CT Scan | CBCT-Dental Scan | Live 3D-4D Sonography | Colour Doppler | Echo Cardiography | Interventional Radiology | Maxillofacial Radiology | Fetal Medicine
Digital X-Ray | Digital Mammography | Digital OPG/TMJ | ECG/TMT/PFT/EEG/EMG | Audiometry | Pathology Laboratory | Health Check Up Plans | Pre Employment Check Up

CT SCAN & CBCT FACILITY NOW AVAILABLE

Dr. Dinesh S. Modh

M.D., D.M.R.E. (Radiodiagnosis)

Consultant Radiologist & Sonologist

Ex. Junior Lecturer, B.J. Medical College, Civil Hospital, A'bad.



Patient's name : CHANDRAKANT VAGHELA
Reg. ID : R-7151-23
Referred by : Dr. MEDIWHEEL

Age/Sex : 36 Years/Male
Accession : 13455
Date : 19/09/2023

2D- ECHO REPORT

FINAL CONCLUSION:

LV IS NORMAL SIZE. GOOD LV SYSTOLIC FUNCTION NO RWMA.
LVEF - 60%. NO CONCENTRIC LVH.
NORMAL LV COMPLIANCE.
LA IS NORMAL SIZE. NO LA CLOT.
RV IS NORMAL SIZE. GOOD RV SYSTOLIC FUNCTION.
RA IS NORMAL SIZE.
MITRAL VALVE IS NORMAL. NO MS. MILD MR (15%). NO MVP.
AORTIC VALVE IS NORMAL. NO AS. NO AR.
TRICUSPID VALVE IS NORMAL. NO TR. RVSP-26 mmHg. NO PAH.

NO CLOT, NO VEGETATION, NO PERICARDIAL EFFUSION.

DIMENSIONS:

| | |
|-------------|----------|
| AORTA | 2.6 C.M |
| LEFT ATRIUM | 2.7 C.M |
| LVDD | 4.1 C.M. |
| IVSD | 1.0 C.M |
| PWD | 1.0 C.M |
| LVDS | 2.6 C.M. |

COLOUR DOPPLER FINDING:

| STRUCTURE | VELOCITY m/sec |
|-----------------|-------------------|
| | Max |
| PULMONARY VALVE | 0.7 |
| MITRAL VALVE | E : 0.7 A: 0.4 |
| AORTIC VALVE | 1.0 |

Avinash
DR AVINASH BHASKAR

ISO 9001:2015 Certified Diagnostics Center

Vidhi Imaging Center

L-86, Swatantra Senani Nagar, Opp. Indian Oil Petrol Pump, Akhbarnagar Circle, Nava Vadaj, Ahmedabad - 380 013.

Phone : (Radiology) 079-2762 1406 | M. 98799 29406, 98250 09406 | Time (Radiology) : Mon. to Sat. 9 am to 2 pm, 5 to 9 pm, Sunday 9 am to 12 Noon

E-mail : vidhidiagnostics@gmail.com, Website : www.vidhidiagnostics.com

Multislice CT Scan | CBCT-Dental Scan | Live 3D-4D Sonography | Colour Doppler | Echo Cardiography | Interventional Radiology | Maxillofacial Radiology | Fetal Medicine
Digital X-Ray | Digital Mammography | Digital OPG / TMJ | ECG / TMT / PFT / EEG / EMG | Audiometry | Pathology Laboratory | Health Check Up Plans | Pre Employment Check Up

CT SCAN & CBCT FACILITY NOW AVAILABLE

HR : 85 bpm
 PR : 140 ms
 QRS : 84 ms
 QT/QTc : 338/402 ms
 P/QRS/T : 57/18/20 deg.
 RV5/SV1 : 1.154/-0.701 mv
 RV5+SV1 : 1.855 mv

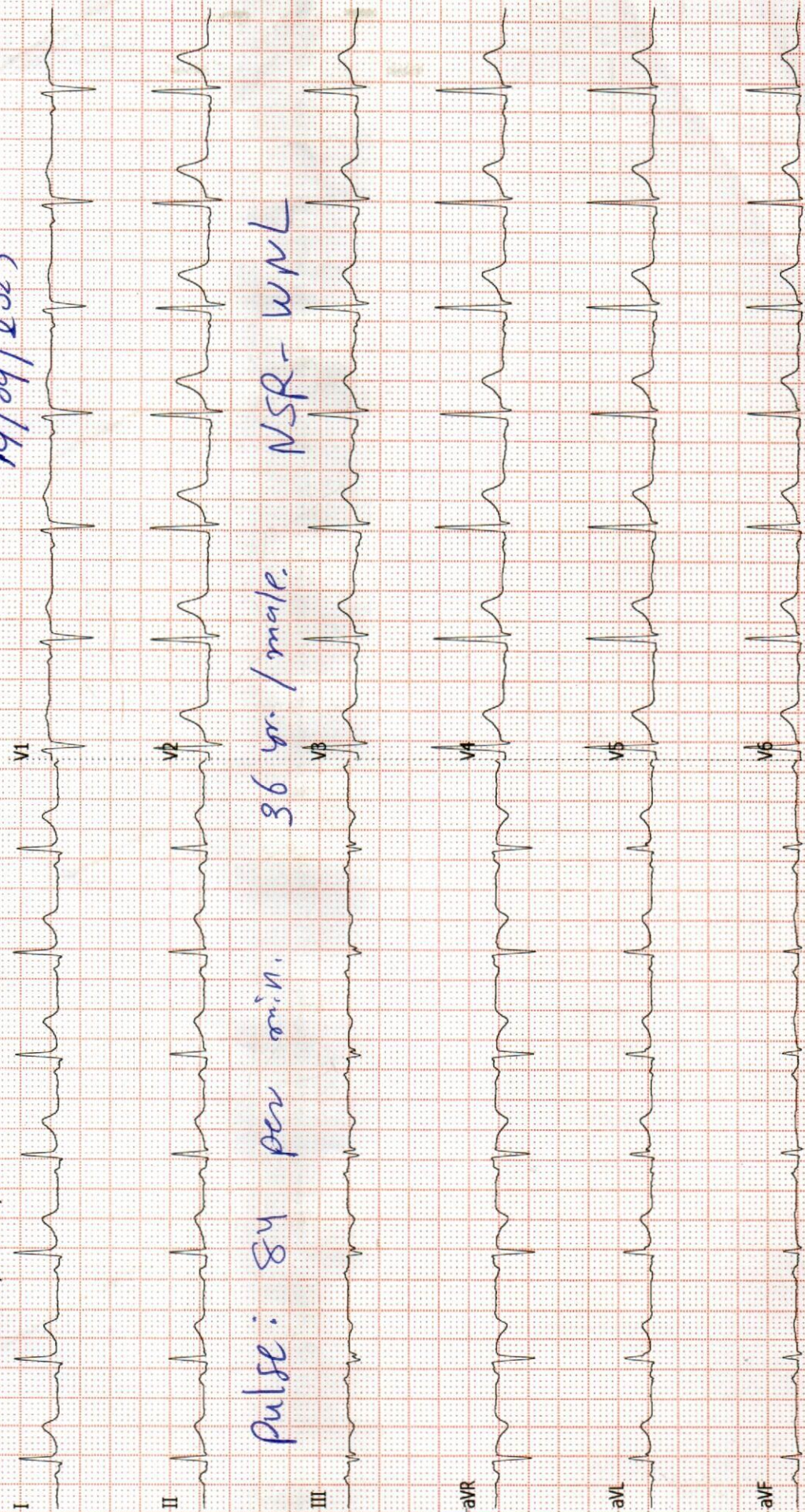
ID: 10766
 Name: Chandrakant Vaghela

Age: 36 yrs
 Sex: Male
 Hospital: **Dr. Avinash Bhaerbar**
MAESTROS CARDIO

Department: **G-45946**

Need to be confirmed by doctor. Doctor Name:

0.67Hz - 35Hz AC 50Hz 25 mm/s 10 mm/mv

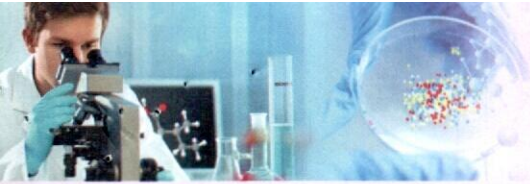

Vidhi Diagnostics

1-88, Swatantra-Senani Nagar,
 Opp. Akharnagar Bus Terminals,
 Nr. Akharnagar Circle,
 New Wadaj, Ahmedabad-13.

19/09/2023

Pulse: 84 per min. 36 yr / male. NSR - WPL



Patient's name : VAGHELA CHANDRAKANT
 Age/Sex : 36 Years/Male
 Referred by : Dr. MEDIWHEEL
 Collection Time : 09:17

Reg. ID : P-3326-23
 Accession : 13449
 Order Dt/time : 19/09/2023 09:17

Complete Blood Count

Sample Type: EDTA

| Test Name | Result | Units | Biological Reference Interval |
|----------------------------------|-------------|-----------|-------------------------------|
| <u>Blood Counts</u> | | | |
| Haemoglobin : | 16.0 | Gms% | 13.5 - 18.0 |
| Total R.B.C. : | 5.44 | mill/c.mm | 4.7 - 6.0 |
| Total W. B. C. : | 6710 | /cu mm | 4000 - 10500 |
| Platelet Count : | 253000 | /cu.mm | 1,50,000 - 4,50,000 |
| <u>Differential Count</u> | | | |
| Neutrophils : | 57 | % | 40 - 70 |
| Lymphocytes : | 38 | % | 20 - 40 |
| Eosinophils : | 03 | % | 1 - 4 |
| Monocytes : | 02 | % | 2 - 6 |
| Basophils : | 00 | % | 0 - 01 |
| <u>Blood Indices</u> | | | |
| P. C. V : | 46.2 | % | 42 - 52 |
| M. C. V. : | 84.9 | fl | 78 - 100 |
| M.C.H : | 29.3 | pg | 27 - 31 |
| M. C. H. C : | 34.5 | % | 32 - 36 |
| R.D.W : | 15.1 | % | 11.5 - 14.0 |

E.S.R.(Westergren Method)

After one hour : 04 mm/hr 1 - 7

TESTS DONE ON FULLY AUTOMATED HEMATOLOGY ANALYZER.

Dr. Gayatri M. Mehta
 M. D. (Patho)

Reg. No. G-32215

DR GAYATRI MEHTA
 MD(PATHOLOGY)

DR. ANAND D. PARIKH
 MD(PATHOLOGY)

LAB USE ONLY (Entered by :GM Enter Date/Time:19/09/2023 1:21:00 PM) (Verify by :GM Verify Date/Time:19/09/2023 1:21:00 PM)



Vidhi Imaging Center | Pathology Department

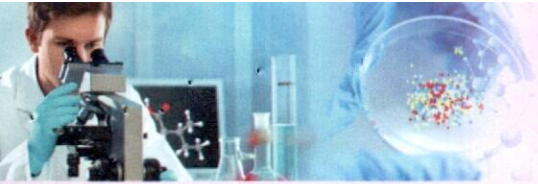L-86, Swatantra Senani Nagar, Opp. Akhbarnagar Petrol Pump, Nr. Akhbarnagar Circle, Nava-Vadaj, Ahmedabad - 380 013.

Ph. (Pathology) : 8849893954 M. 98799 29406, 98250 09406, E-mail : vidhidiagnostics@gmail.com, Web. : www.vidhidiagnostics.com

Time (Pathology) : Mon. to Sat. 8.30 am to 8.00 pm, Sunday 9 am to 12 Noon

Pathology means science behind medicine

CT SCAN & CBCT FACILITY NOW AVAILABLE



Patient's name : VAGHELA CHANDRAKANT
Age/Sex : 36 Years/Male
Referred by : Dr. MEDIWHEEL
Collection Time : 09:17

Reg. ID : P-3326-23
Accession : 13449
Order Dt/time : 19/09/2023 09:17

Blood Group

Sample Type: EDTA sample.

| Test Name | Result |
|-----------|----------------------------------|
| BG : | " A " |
| RH : | POSITIVE |
| Remarks | Done by forward grouping method. |

Blood Glucose

Sample Type: Serum

| Test Name | Result | Units | Biological Reference Interval |
|---|--------------|-------|-------------------------------|
| Fasting Blood Glucose : <i>GOD-POD Method.</i> | 124.8 | mg/dl | 70 - 110 |

Blood Glucose

Sample Type: Serum

| Test Name | Result | Units | Biological Reference Interval |
|---|--------|-------|-------------------------------|
| Post Prandial Blood Glucose After 2hr. : <i>GOD-POD Method.</i> | 132.3 | mg/dl | 80 - 140 |

Dr. Gayatri M. Mehta
M. D. (Patho)

DR GAYATRI MEHTA-32215
MD(PATHOLOGY)

DR.ANAND D.PARIKH
MD(PATHOLOGY)

LAB USE ONLY (Entered by :GM Enter Date/Time:19/09/2023 2:07:00 PM) (Verify by :GM Verify Date/Time:19/09/2023 2:07:00 PM)



Vidhi Imaging Center | Pathology Department

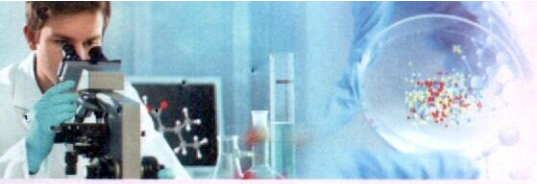L-86, Swatantra Senani Nagar, Opp. Akhbarnagar Petrol Pump, Nr. Akhbarnagar Circle, Nava-Vadaj, Ahmedabad - 380 013.

Ph. (Pathology) : 8849893954 M. 98799 29406, 98250 09406, E-mail : vidhidiagnostics@gmail.com, Web. : www.vidhidiagnostics.com

Time (Pathology) : Mon. to Sat. 8.30 am to 8.00 pm, Sunday 9 am to 12 Noon

Pathology means science behind medicine

CT SCAN & CBCT FACILITY NOW AVAILABLE



Patient's name : VAGHELA CHANDRAKANT
Age/Sex : 36 Years/Male
Referred by : Dr. MEDIWHEEL
Collection Time : 09:17

Reg. ID : P-3326-23
Accession : 13449
Order Dt/time : 19/09/2023 09:17

Lipid Profile

Sample Type: Serum

| Test Name | Result | Units | Biological Reference Interval |
|---|--------|-------|-------------------------------|
| S. Cholesterol : Oxidase-esterase method. | 178 | mg/dl | 0 - 200 |
| S. Triglyceride : Enzymatic Colorimetry method | 73.9 | mg/dL | 0 - 200 |
| S. HDL - Cholesterol : Serum by Enzymatic method. | 50.1 | mg/dL | 35 - 65 |
| S. LDL - Cholesterol : Serum by Enzymatic method | 113.12 | mg/dL | 0 - 130 |
| S. VLDL - Cholesterol : | 14.78 | mg/dL | 0 - 30 |
| S. Chole/HDL.Ratio : | 3.55 | | 1 - 6 |
| S. LDL / HDL Cholesterol Ratio : | 2.26 | | 0 - 3.5 |

Dr. Gayatri M. Mehta

M. D. (Pathology)

Reg. No. G-32215

DR GAYATRI MEHTA
MD(PATHOLOGY)

DR. ANAND D. PARIKH
MD(PATHOLOGY)

LAB USE ONLY (Entered by :GM Enter Date/Time:19/09/2023 12:35:00 PM) (Verify by :GM Verify Date/Time:19/09/2023 12:35:00 PM)



Vidhi Imaging Center | Pathology Department

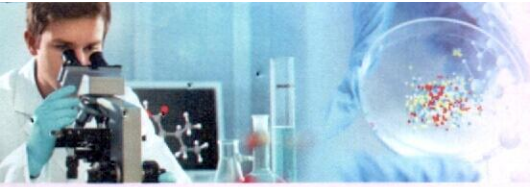L-86, Swatantra Senani Nagar, Opp. Akharnagar Petrol Pump, Nr. Akharnagar Circle, Nava-Vadaj, Ahmedabad - 380 013.

Ph. (Pathology) : 8849893954 M. 98799 29406, 98250 09406, E-mail : vidhidiagnostics@gmail.com, Web. : www.vidhidiagnostics.com

Time (Pathology) : Mon. to Sat. 8.30 am to 8.00 pm, Sunday 9 am to 12 Noon

Pathology means science behind medicine

CT SCAN & CBCT FACILITY NOW AVAILABLE



Pathology Department



Patient's name : VAGHELA CHANDRAKANT
Age/Sex : 36 Years/Male
Referred by : Dr. MEDIWHEEL
Collection Time : 09:17

Reg. ID : P-3326-23
Accession : 13449
Order Dt/time : 19/09/2023 09:17

HbA1C

Sample Type: Serum

| Test Name | Result | Units | Biological Reference Interval |
|---------------------------------------|--------|-------|--|
| HbA1C : | 5.6 | % | Non-diabetic: 4.2-6.2 Pre-diabetic : 6.3-7.2 Diabetic : 7.3-8.2 |
| Mean Blood Glucose of Last 03 months. | 114 | mg/dl | |

Comment

*As per the new 2009 update of American Diabetes Association regarding HbA1C & Mean Blood Glucose relationship.

NOTE:

This test is used to monitor diabetic patients compliance with the therapeutic regimen and logo It's level is proportional to both the average blood glucose concentration and the life span of the red blood cells (RBC) in circulation. HbA1c values are free of day to day glucose fluctuations and are unaffected by exercise or recent food intake.

Dr. Gayatri M. Mehta

M. D. (Patho)

Reg. No. G-32215

DR GAYATRI MEHTA
MD(PATHOLOGY)

DR. ANAND D. PARIKH
MD(PATHOLOGY)

LAB USE ONLY (Entered by :GM Enter Date/Time:19/09/2023 12:36:00 PM) (Verify by :GM Verify Date/Time:19/09/2023 12:36:00 PM)



Vidhi Imaging Center | Pathology Department

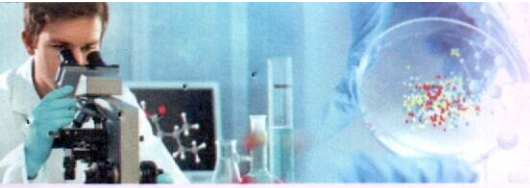L-86, Swatantra Senani Nagar, Opp. Akhbarnagar Petrol Pump, Nr. Akhbarnagar Circle, Nava-Vadaj, Ahmedabad - 380 013.

Ph. (Pathology) : 8849893954 M. 98799 29406, 98250 09406, E-mail : vidhidiagnostics@gmail.com, Web. : www.vidhidiagnostics.com

Time (Pathology) : Mon. to Sat. 8.30 am to 8.00 pm, Sunday 9 am to 12 Noon

Pathology means science behind medicine

CT SCAN & CBCT FACILITY NOW AVAILABLE



Patient's name : VAGHELA CHANDRAKANT
Age/Sex : 36 Years/Male
Referred by : Dr. MEDIWHEEL
Collection Time : 09:17

Reg. ID : P-3326-23
Accession : 13449
Order Dt/time : 19/09/2023 09:17

BIOCHEMISTRY

Sample type :Serum

| Test Name | Result | Units | Biological Reference Interval |
|---|-------------|--------|-------------------------------|
| Urea, (Serum by GLDH method) : | 31.6 | mg/dl | 10 - 50 |
| S.Uric acid, (Serum by Uricase method) : | 8.0 | mg/dl | 3.4 - 7.0 |
| Bun : | 14.8 | mg/dl | 6-20 |
| Creatinine, (Serum by Enzymatic reaction) : | 0.89 | mg/dl | 0.5-1.2 |
| S.G.P.T (ALT) : (Serum by IFCC method) | 51.5 | U/L | 0 - 40 |
| S.G.O.T (AST) : (Serum by IFCC method) | 26.3 | U/L | 0 - 37 |
| ALK.PHOSPHATASE : (Serum by PNP method) | 95 | U/L | 40-129 |
| G.G.T : | 23.7 | U/L | 8 - 78 |
| <u>BILIRUBIN</u> | | | |
| Total : | 0.61 | mg/dl | Up to 1.2 |
| Direct : | 0.26 | mg/dl | 0-0.7 |
| Indirect : | 0.35 | mg/dl | 0 - 0.5 |
| <u>SERUM PROTEINS</u> | | | |
| Total Protein (Serum by Biuret method) : | 7.16 | gms/dl | 6.4 - 8.5 |
| Albumin (Serum by BCG method) : | 4.39 | gms/dl | 3.97-4.94 |
| Globulins : | 2.77 | gms/dl | 2.3 - 3.5 |
| A/G Ratio : | 1.585 | | 0.9 - 2.9 |

Dr. Gayatri M. Mehta

M. D. (Patho)

Reg. No. G-32215

DR GAYATRI MEHTA
MD(PATHOLOGY)DR.ANAND D.PARIKH
MD(PATHOLOGY)

LAB USE ONLY (Entered by :AP Enter Date/Time:19/09/2023 12:54:00 PM) (Verify by :GM Verify Date/Time:19/09/2023 12:55:00 PM)



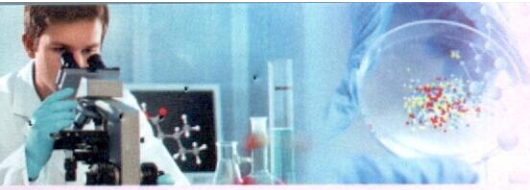Vidhi Imaging Center | Pathology Department

L-86, Swatantra Senani Nagar, Opp. Akhbarnagar Petrol Pump, Nr. Akhbarnagar Circle, Nava-Vadaj, Ahmedabad - 380 013.

Ph. (Pathology) : 8849893954 M. 98799 29406, 98250 09406, E-mail : vidhidiagnostics@gmail.com, Web. : www.vidhidiagnostics.com

Time (Pathology) : Mon. to Sat. 8.30 am to 8.00 pm, Sunday 9 am to 12 Noon

*Pathology means science behind medicine***CT SCAN & CBCT FACILITY NOW AVAILABLE**



Pathology Department

Patient's name : VAGHELA CHANDRAKANT
Age/Sex : 36 Years/Male
Referred by : Dr. MEDIWHEEL
Collection Time : 09:17

Reg. ID : P-3326-23
Accession : 13449
Order Dt/time : 19/09/2023 09:17

Thyroid Function Test

Sample Type: Serum

| Test Name | Result | Units | Biological Reference Interval |
|------------------------|--------|-------|-------------------------------|
| TOTAL T3 : | 1.69 | ng/ml | 0.84 - 2.0 |
| TOTAL T4 : | 10.10 | ug/dl | 5.1 - 14.0 |
| TSH(Ultra sensitive) : | 2.85 | mIU/L | 0.27 - 4.2 |

Dr. Gayatri M. Mehta
M. D. (Patho)

Reg. No. G-32215

DR GAYATRI MEHTA
MD(PATHOLOGY)

DR. ANAND D. PARIKH
MD(PATHOLOGY)

LAB USE ONLY (Entered by :GM Enter Date/Time:19/09/2023 2:08:00 PM) (Verify by :GM Verify Date/Time:19/09/2023 2:08:00 PM)



Vidhi Imaging Center | Pathology Department

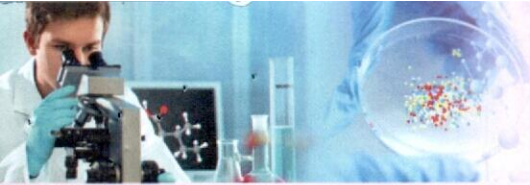L-86, Swatantra Senani Nagar, Opp. Akhbar Nagar Petrol Pump, Nr. Akhbar Nagar Circle, Nava-Vadaj, Ahmedabad - 380 013.

Ph. (Pathology) : 8849893954 M. 98799 29406, 98250 09406, E-mail : vidhidiagnostics@gmail.com, Web. : www.vidhidiagnostics.com

Time (Pathology) : Mon. to Sat. 8.30 am to 8.00 pm, Sunday 9 am to 12 Noon

Pathology means science behind medicine

CT SCAN & CBCT FACILITY NOW AVAILABLE



Patient's name : VAGHELA CHANDRAKANT
 Age/Sex : 36 Years/Male
 Referred by : Dr. MEDIWHEEL
 Collection Time : 09:17

Reg. ID : P-3326-23
 Accession : 13449
 Order Dt/time : 19/09/2023 09:17

Urine Analysis

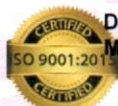Sample Type: Urine

| Test Name | Result | Units | Biological Reference Interval |
|---------------------------------------|-----------------------|--------|-------------------------------|
| <u>Physical Examination</u> | | | |
| Quantity : | 20 | ml | 0 - 500 ml |
| Colour : | Pale Yellow | | Pale Yellow |
| Transparency : | Slight Turbid. | | Clear |
| Reaction : | Acidic | | 4.6 - 8.0 |
| Specific Gravity : | 1.020 | | 1.016 - 1.022 |
| Sediment : | Present | | |
| <u>Chemical Examination</u> | | | |
| Albumin : | Present (Faint Trace) | | Absent |
| Sugar : | NIL | | Absent |
| Acetone : | Absent | | Absent |
| Bile Salts : | Absent | | Absent |
| Bile Pigments : | Absent | | Absent |
| Urobilogen : | Absent | | Absent |
| Nitrites : | Absent | | Absent |
| <u>Microscopic Examination</u> | | | |
| Red blood Cells : | 1-2 | /h.p.f | Absent |
| Pus Cells : | 2-3 | /h.p.f | Absent |
| Epithelial Cells : | 1-2 | /h.p.f | < 10.0 |
| Amorphous : | Absent | /h.p.f | Absent |
| Bacteria : | Absent | /h.p.f | Absent |
| Crystals : | Absent | /h.p.f | Absent |
| Casts : | Absent | /h.p.f | Absent |
| Fungus : | Not seen | /h.p.f | Absent |

Dr. Gayatri M. Mehta

M. D. (Patho)

Reg. No. G-32215

DR. ANAND D. PARIKH
MD(PATHOLOGY)

Entered by: GM Enter Date/Time: 19/09/2023 12:36:00 PM (Verify by: GM Verify Date/Time: 19/09/2023 12:36:00 PM)

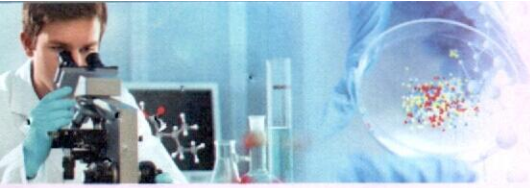Vidhi Imaging Center | Pathology Department

L-86, Swatantra Senani Nagar, Opp. Akharnagar Petrol Pump, Nr. Akharnagar Circle, Nava-Vadaj, Ahmedabad - 380 013.

Ph. (Pathology) : 8849893954 M. 98799 29406, 98250 09406, E-mail : vidhidiagnostics@gmail.com, Web. : www.vidhidiagnostics.com

Time (Pathology) : Mon. to Sat. 8.30 am to 8.00 pm, Sunday 9 am to 12 Noon

*Pathology means science behind medicine***CT SCAN & CBCT FACILITY NOW AVAILABLE**



Pathology Department



Patient's name : VAGHELA CHANDRAKANT
Age/Sex : 36 Years/Male
Referred by : Dr. MEDIWHEEL
Collection Time : 09:17

Reg. ID : P-3326-23
Accession : 13449
Order Dt/time : 19/09/2023 09:17

Stool Examination

Sample Type: Stool

| Test Name | Result | Units | Biological Reference Interval |
|--|------------|-------|-------------------------------|
| <u>PHYSICAL EXAMINATION</u> | | | |
| Quantity | 30 gms | | |
| Colour | Yellow | | |
| Consistency | Semi-Solid | | |
| Mucus | Nil | | |
| Occult Blood | Negative | | |
| Peroxidase Reaction with o-Dianisidine | | | |
| Reaction | Acidic | | |
| pH Strip Method | | | |

MICROSCOPIC EXAMINATION

| | |
|-----------------|-----------|
| Pus Cells | 1 - 2/hpf |
| RBCs | Nil |
| Vegetable Cells | Absent |
| Trophozoites | Nil |
| Cysts | Nil |
| Ova | Nil |
| Fat Globules | Nil |

----- End Of Report -----

Dr. Gayatri M. Mehta
M. D. (Patho)

DR. GAYATRI MEHTA
MD(PATHOLOGY)
Reg. No. G-32215

DR. ANAND D. PARIKH
MD(PATHOLOGY)

LAB USE ONLY (Entered by :GM Enter Date/Time:19/09/2023 2:09:00 PM) (Verify by :GM Verify Date/Time:19/09/2023 2:09:00 PM)



Vidhi Imaging Center | Pathology Department

L-86, Swatantra Senani Nagar, Opp. Akhbarnagar Petrol Pump, Nr. Akhbarnagar Circle, Nava-Vadaj, Ahmedabad - 380 013.

Ph. (Pathology) : 8849893954 M. 98799 29406, 98250 09406, E-mail : vidhidiagnostics@gmail.com, Web. : www.vidhidiagnostics.com

Time (Pathology) : Mon. to Sat. 8.30 am to 8.00 pm, Sunday 9 am to 12 Noon

Pathology means science behind medicine

CT SCAN & CBCT FACILITY NOW AVAILABLE




भारत सरकार
Government of India

वाग्हेला चंद्रकान्त
Vaghela Chandrakant
જાગ૨ીખ / DOB : 03/02/1987
પુરુષ / Male

Issue Date: 16/02/2013

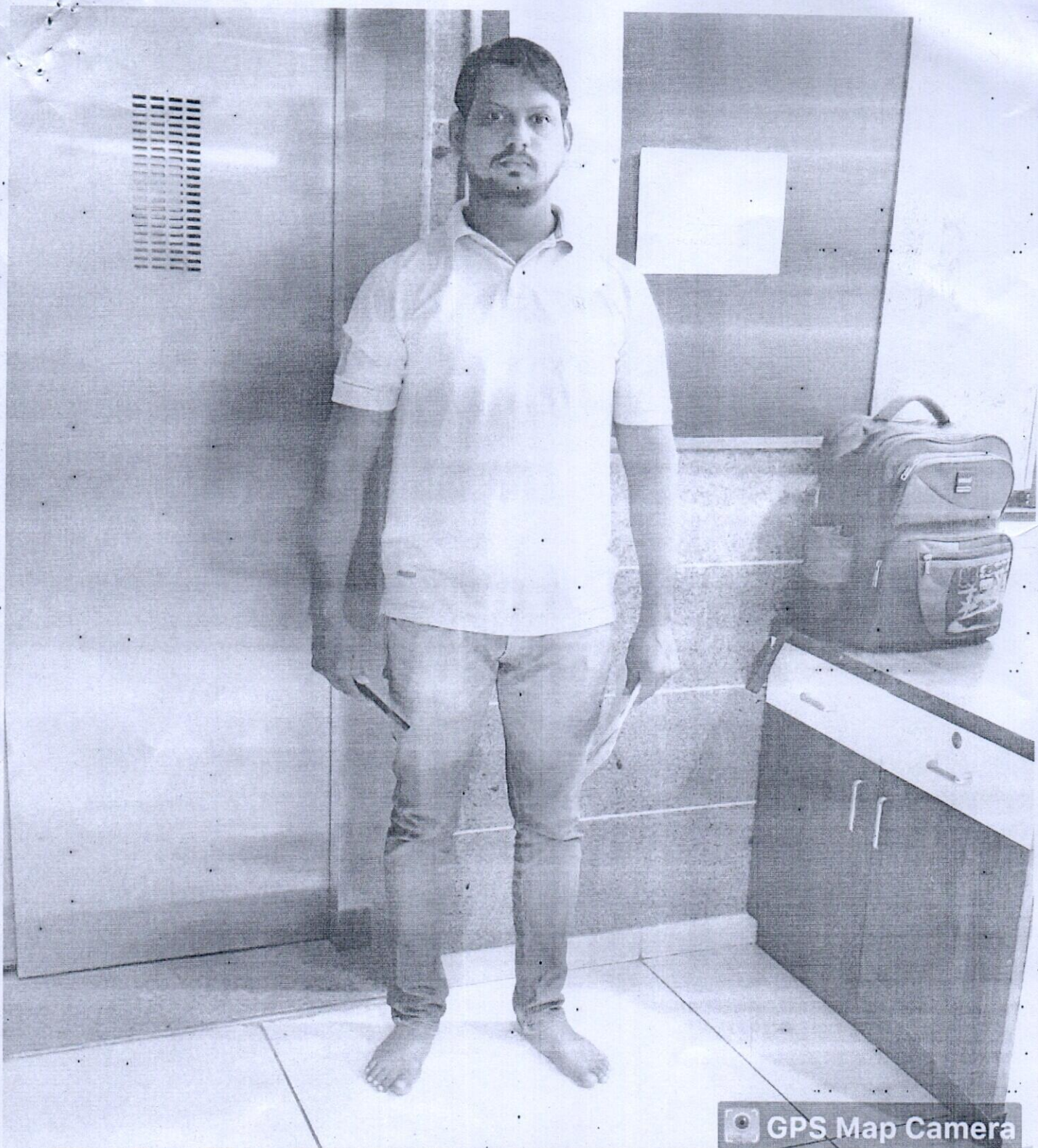6654 2903 8529

मेरा आधार, मेरी पहचान



C. Vaghela

Vidhi Diagnostics
L-86, Swatantra-Senani Itagar,
Opp. Akhbarnagar Bus Terminals,
Nr. Akhbarnagar Circle,
New Wadaj, Ahmedabad-13.



 GPS Map Camera



Ahmedabad, Gujarat, India

3H96+6PR, Chandlodiya Rd, Swatantra Senani Nagar, Nava
Wadaj, Ahmedabad, Gujarat 380013, India

Lat 23.06811°

Long 72.561762°

19/09/23 09:13 AM GMT +05:30

Vidhi Diagnostics
L-86, Swatantra-Senani Nagar,
Opp. Akhbarnagar Bus Terminals,
Nr. Akhbarnagar Circle,
New Wadaj, Ahmedabad-13.