



# MURUGAN HOSPITALS

HEALING HANDS



## LAB REPORT

Patient Name : Mrs. VIMALA.K  
 Age / Gender : 31-Years / Female  
 UHID ID : MH20220041696  
 Doctor Name : Dr. ARUN PRAKASH

OP Report No. : INVA2107822  
 Bill No. : INV2205483  
 Sample Date : 21/11/2022 - 09:11 AM  
 Report Date : 21/11/2022 - 04:00 PM

Test Name	Result	Units	Reference Interval
<b>HAEMATOLOGY</b>			
<b>Complete Blood Cell Count(CBC)</b>			
HAEMOGLOBIN	12.5	gms/dl	male :13.0 - 17.0 female :12.0 - 15.0
PACKED CELL VOLUME	39.9	%	male : 40 - 50 female : 36 - 46
RBC COUNT	<u>4.38</u>	millions cells/cu.mm	female: 3.8 - 4.8 male : 4.5 - 5.5
TOTAL WBC	8,800	Cells/Cumm	4,000 - 11,000
<b>Differential Count</b>			
NEUTROPHILS	53	%	40 - 65
LYMPHOCYTES	42	%	30-50
EOSINOPHILS	05	%	01-06
MONOCYTES	<u>00</u>	%	1-10
BASOPHILS	00	%	0-2
ESR 60 MTS	05	mm	5 - 20
PLATELET COUNT	3.58	Lakhs/cumm	1.5 - 4.5
MCV	91.1	fL	76 - 96
MCH	28.5	pg	27 - 32
MCHC	31.3	gms/dl	30 - 36

INTERPRETATION: Test done on automated three part cell counter, all abnormal results are reviewed and confirmed microscopically

BLOOD GROUPING & RH TYPING " A ", POSITIVE

Healing Hearts and Lives

264/125, Kilpauk Garden Road, Kilpauk, Chennai - 600 010.  
 Phone : +91 44 4644 8989 / 75500 53335 | Email : muruganhosp@gmail.com  
 Website : www.muruganhospitals.in





# MURUGAN HOSPITALS

HEALING HANDS



## LAB REPORT

Patient Name : Mrs. VIMALA.K  
Age / Gender : 31-Years / Female  
UHID ID : MH20220041696  
Doctor Name : Dr. ARUN PRAKASH

OP Report No. : INVA2107822  
Bill No. : INV2205483  
Sample Date : 21/11/2022 - 09:11 AM  
Report Date : 21/11/2022 - 04:00 PM

Test Name	Result	Units	Reference Interval
<b>BIO CHEMISTRY</b>			
BLOOD SUGAR FASTING	84	mgs/dl	70-110
BLOOD SUGAR POST PRANDIAL	91	mgs/dl	80- 160
SERUM URIC ACID	2.9	mg/dl	male 3.1-7.0 , female 2.5-5.6
SERUM CREATININE	0.7	mg/dl	0.6-1.4
<b>LIPID PROFILE</b>			
TOTALCHOLESTEROL	149	mg/dl	< 200
TRIGLYCERIDE	69	mg/dl	< 150
HDL	40	mg/dl	35 - 80
VLDL	14	mg/dl	2 to 30
LDL	95	mg/dl	<130
CHOLESTEROL/ HDL RATIO	3.7	mg/dl	





# MURUGAN HOSPITALS

HEALING HANDS



## LAB REPORT

Patient Name : Mrs. VIMALA.K  
 Age / Gender : 31-Years / Female  
 UHID ID : MH20220041696  
 Doctor Name : Dr. ARUN PRAKASH

OP Report No. : INVA2107822  
 Bill No. : INV2205483  
 Sample Date : 21/11/2022 - 09:11 AM  
 Report Date : 21/11/2022 - 04:00 PM

Test Name	Result	Units	Reference Interval
<b>LIVER FUNCTION TEST</b>			
BILLIRUBIN(TOTAL)	0.4	mg/dl	0.0 -1.0
BILLIRUBIN(DIRECT)	0.2	mg/dl	0.1- 0.30
BILLIRUBIN(INDIRECT)	0.2	mg/dl	0.2-0.8
SGOT	17	IU/L	0-38
SGPT	13	IU/L	0.0-40
ALKALINE PHOSPHATASE	57	IU/L	40-140 4-6Years 93-309 13-15Years 74-390
TOTAL PROTEIN	7.7	gm/dl	6.6-8.7
ALBUMIN	4.6	gm/dl	3.5 - 5.5
GLOBULIN	3.1	gm/dl	2.0-3.5
AG RATIO	1.4		
GAMMA G T	15	U/L	male<49 female<32
BLOOD UREA NITROGEN	8.8	mg/dl	7-21
HBA1C	5.4	%	normal: <6.0 good control: 6.1-7.0 fair control: 7.1- 8.0 poor control:8.1 -10.0 unsatisfactory: >10.0

**Healing Hearts and Lives**

264/125, Kilpauk Garden Road, Kilpauk, Chennai - 600 010.  
 Phone : +91 44 4644 8989 / 75500 53335 | Email : muruganhosp@gmail.com  
 Website : www.muruganhospitals.in





# MURUGAN HOSPITALS

HEALING HANDS



## LAB REPORT

Patient Name : Mrs. VIMALA.K  
 Age / Gender : 31-Years / Female  
 UHID ID : MH20220041696  
 Doctor Name : Dr. ARUN PRAKASH

OP Report No. : INVA2107822  
 Bill No. : INV2205483  
 Sample Date : 21/11/2022 - 09:11 AM  
 Report Date : 21/11/2022 - 04:00 PM

Test Name	Result	Units	Reference Interval
<b><u>CLINICAL PATHOLOGY</u></b>			
URINE SUGAR (F)	NIL		
URINE SUGAR (PP)	NIL		
<b>URINE ROUTINE</b>			
COLOUR	STRAW YELLOW		
APPEARANCE	CLEAR		
REACTION	ACIDIC		
SUGAR	NIL		
ALBUMIN	NIL		
<b>DEPOSITES</b>			
PUS CELLS	2 - 3	/ HPF	
EPI CELLS	4 - 5	/ HPF	
RBC COUNT	NIL	/ HPF	
CAST	NIL		
CRYSTALS	NIL		
OTHERS	NIL		

SHENBAGAVALLI  
 Verified by

\*\*\* End of Report \*\*\*



**Healing Hearts and Lives**

264/125, Kilpauk Garden Road, Kilpauk, Chennai - 600 010.  
 Phone : +91 44 4644 8989 / 75500 53335 | Email : muruganhosp@gmail.com  
 Website : www.muruganhospitals.in





# MURUGAN HOSPITALS

HEALING HANDS



## LAB REPORT

Patient Name : Mrs. VIMALA.K  
 Age / Gender : 31-Years / Female  
 UHID ID : MH20220041696  
 Doctor Name : Dr. ARUN PRAKASH

OP Report No. : INVA2107822  
 Bill No. : INV2205483  
 Sample Date : 21/11/2022 - 09:11 AM  
 Report Date : 22/11/2022 - 02:11 PM

Test Name	Result	Units	Reference Interval
-----------	--------	-------	--------------------

### ENDOCRINOLOGY

T3	1.607	ng/ml	0.52-1.85
T4	6.006	ug/dl	5.0 -13.0 ug/dl
TSH	0.571	uIU/ml	0.39 - 6.16 uiu/ml

MALATHI  
 Verified by

\*\*\* End of Report \*\*\*



*[Signature]*  
**PAVITHRA**  
 Pathologist  
 Reg. No: 78256

Healing Hearts and Lives

264/125, Kilpauk Garden Road, Kilpauk, Chennai - 600 010.  
 Phone : +91 44 4644 8989 / 75500 53335 | Email : muruganhosp@gmail.com  
 Website : www.muruganhospitals.in





**MURUGAN HOSPITALS**  
HEALING HANDS

NAME : MRS.VIMALA  
AGE /GENDER:31YRS/ FEMALE  
CONSULTANT: DR.ARUNPRAKASH

UHID : MH20220041696  
IP/OP : OP  
DATE : 21.11.2022

**X-RAY CHEST (PA VIEW)**

- The cardio thoracic ratio is normal
- The heart size and configuration are within normal limits
- The aortic arch is normal
- The lung fields show normal broncho- Vascular markings
- Both the pulmonary hila are normal in size
- The costophrenic and cardiophrenic recesses and the domes of diaphragm are normal
- The bones and soft tissues of the chest wall show no abnormality

**IMPRESSION:**

Normal Study





ID: 2211210008  
 Name: MRS. VIMALA  
 Sex: Female  
 Divisions:

Date/Time: 2022-11-21 10:32  
 Age: 31  
 BP: 100/60 mmHg  
 Bed No.:

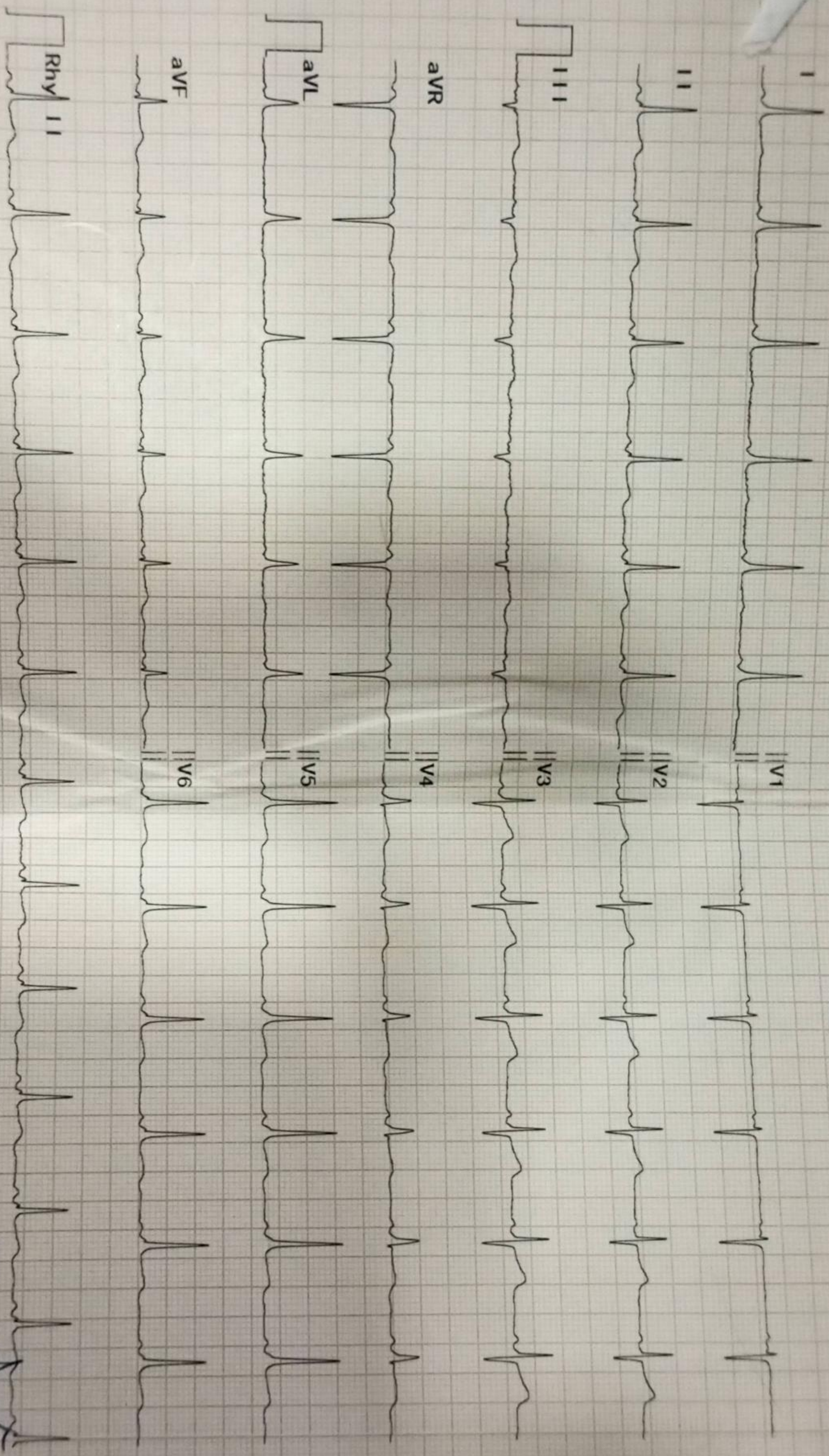
Patient ID: 41696  
 Height: 145 cm  
 Weight: 55 kg  
 Hospital No.:

Hospital: MURUGAN HOSPITAL  
 Diagnosis Info:  
 800: Sinus Rhythm  
 611: Flat T (1)

HR: 78 bpm  
 P Dur/PR Int: 80/118ms  
 QRS Dur: 98 ms  
 QT/QTc: 380/430 ms  
 P/QRS/T axis: 48/20/70°

RV5/SV1 amp: 1.415/0.810mV  
 RV5+SV1 amp: 2.225mV  
 RV6/SV2 amp: 1.243/0.464mV

Minnesota Code:  
 5-4-0 (1)  
 5-5-0 (11)  
 9-4-1 (V3)



Diagnosis for reference, ask your doctor to confirm  
 AUTO PRINT 6X2+1R 78bpm 10 mm/mV 0.50Hz-35Hz AC 50Hz 25 mm/sec

Confirmed By:

**SIDHARTHAN MD, DM**  
 Consultant Cardiologist  
 Reg No. 62072





### SCAN REPORT

NAME	:MRS.VIMALA.K	PATIENT ID	:MH20220041696
AGE/SEX	:31 Years /FEMALE	IP / OP NO	:OP21035142
CONSULTANT	:DR.ARUN PRAKASH	DATE	:21/11/2022

### ULTRA SOUND SCAN OF ABDOMEN

**LIVER:** Normal in size and measures- 13.1 cm and normal in echotexture. No focal lesions are seen. No dilatation of intra-hepatic biliary radicals present. Hepatic veins and IVC appear normal. Portal vein is normal in caliber. Common bile duct is normal in caliber.

**GALL BLADDER:** Normal in size and wall thickness. No evidence of any calculus or mass present. No evidence of pericholecystic collections.

**PANCREAS:** Normal in size and echotexture. No focal lesions are seen. No evidence of calculi or calcifications. No evidence of pancreatic duct dilation.

**PARA AORTIC AREAS:** Aorta and IVC appear normal. No evidence of para aortic lymphadenopathy.

**SPLEEN:** Normal in size and measures-9.1 cm. Normal in echotexture. No evidence of focal lesions.

**RIGHT KIDNEY:** Measures 10.7 x 4.2 cm and is normal in size and echotexture. Cortico medullary differentiation is well maintained. There is no hydronephrosis or mass.

**LEFT KIDNEY:** Measures 10.3 x 4.2 cm and is normal in size and echotexture. Cortico medullary differentiation is well maintained. There is no calculus or hydronephrosis or mass.

Healing Hearts and Lives

264/125, Kilpauk Garden Road, Kilpauk, Chennai - 600 010. Phone : +91 44 4644 8989 / 75500 53335  
Email : muruganhosp@gmail.com | Website : www.muruganhospitals.in



**URINARY BLADDER:** Normal in size, contour and wall thickness. There is no evidence of calculus or mass. No vesical diverticulum present.

**UTERUS AND OVARIES :** Normal in size and measures- 5.6 X 4.9 cm echotexture. ET- 6.2 mm.

Right ovary measures- 3.0 x 1.7 cm .

Left ovary measures- 3.6 x 1.9 cm .

No ascites present. No retroperitoneal lymphadenopathy present.

**IMPRESSION:**

***No significant abnormality detected in the visualized abdominal organs.***



**DR. SARTHU, MDRD.,**

**CONSULTANT RADIOLOGIST.,**





# MURUGAN HOSPITALS

HEALING HANDS



## ECHO CARDIOGRAM REPORT

NAME : MRS.VIMALA.K      PATIENT ID : MH20220041696  
AGE/SEX : 31Years / FEMALE      IP / OP NO : OP21035142  
CONSULTANT : DR.ARUN PRAKASH      DATE : 21/11/2022

### 2D PLAX (mm)

RV - 30 mm  
AO - 30 mm  
LA - 32 mm

### M-Mode (mm)

IVS - 08 mm  
PW - 10 mm  
LVD - 28 mm  
LVS - 19 mm  
EF - 61 %  
FS - 30 %

### COLOR DOPPLER

Normal

### DOPPLER (m/sec)

MITRAL E - 0.4 m/s  
MITRAL A - 0.7 m/s  
PULMONARY - 0.7 m/s  
AORTIC - 1.1 m/s  
TRICUSPID - 0.4 m/s

### IMPRESSION:

No RWMA  
Normal biventricular function  
No pulmonary hypertension  
No pericardial effusion  
No clot/ Vegetation.

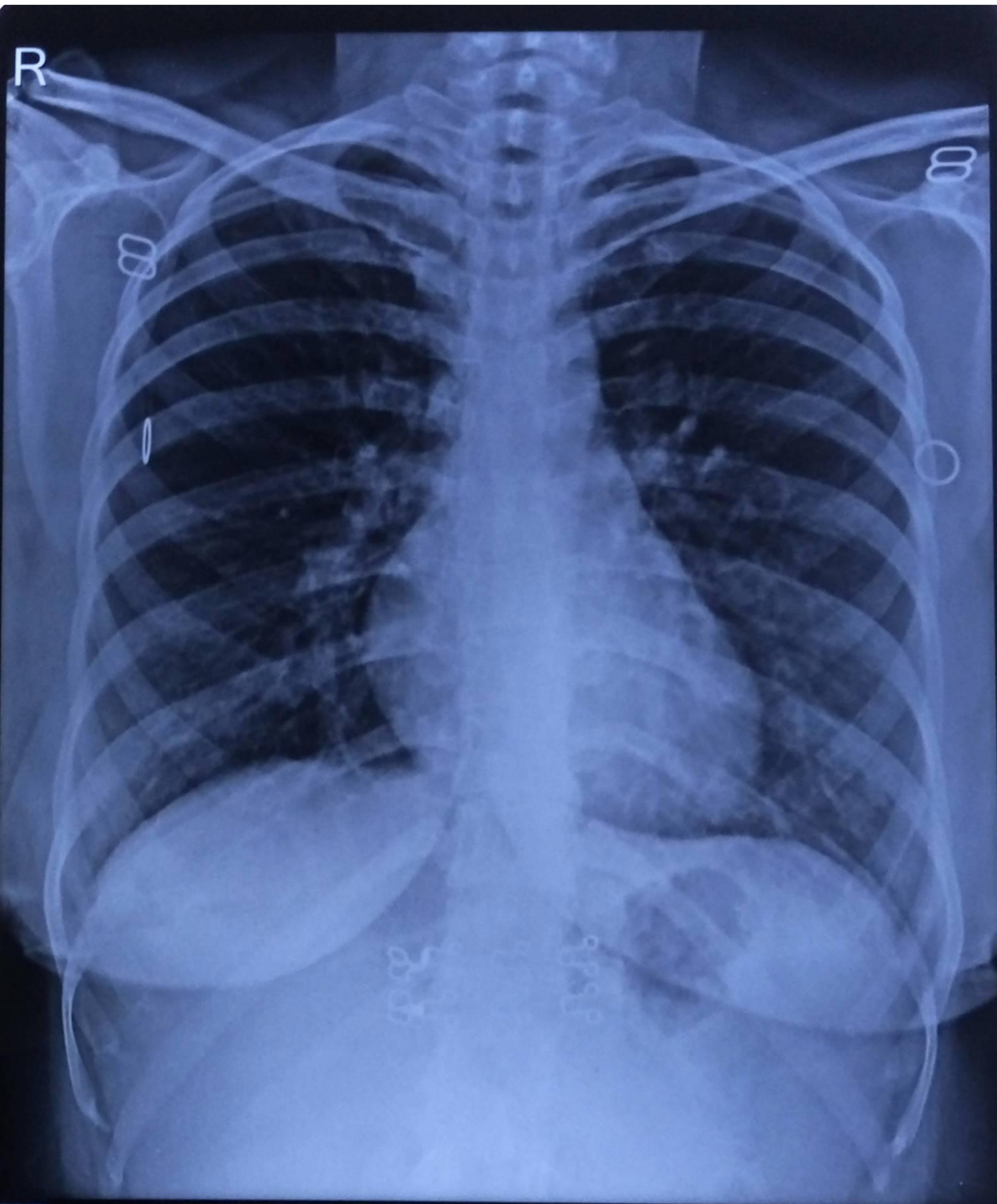


DR.SIDHARTHAN MD.DM.,  
CONSULTANT CARDIOLOGIST

Healing Hearts and Lives

264/125, Kilpauk Garden Road, Kilpauk, Chennai - 600 010.  
Phone : +91 44 4644 8989 / 75500 53335 | Email : muruganhosp@gmail.com  
Website : www.muruganhospitals.in





MRS.VIMALA K 31YRS 41696 CHEST-PA 21-11-2022

MURUGAN HOSPITALS, KILPAUK, CHENNAI 10, PIN NO. 600062