



**MURUGAN HOSPITALS**  
HEALING HANDS

Date : 25/09/2021

NAME OF PATIENT : **Mr.B.KALIAPPAN**

AGE : **49/ Y/MALE**

● Nil visual complaints

O/E

V/A

OD : 6/6 N6

OS : 6/6 N6

Within normal limits in both eyes.

● **IMPRESSION :**

- Nil ophthalmic problem



**Medical Officer**

264/125, Kilpauk Garden Road, Kilpauk, Chennai - 600 010.

☎ : +91 44 4644 8989 / 75500 53335 email : muruganhosp@gmail.com

Website : [www.muruganhospitals.in](http://www.muruganhospitals.in)



# MURUGAN HOSPITALS

HEALING HANDS

25/9/2024

Mr. B. Kaliyappan | 49 | m

o/c

- Take Care - Lower Right Second molar, Third molar  
Upper Left Third molar
- Root Extraction - Lower left Second molar
- Dental Crown - Right upper Second molar
- Discoloration +
- Alignment +





# MURUGAN HOSPITALS

HEALING HANDS

25/9/2024

Mr. B. Kaliappan | 49 | m



etc

No ENT Complaints



264/125, Kilpauk Garden Road, Kilpauk, Chennai - 600 010.

☎ : +91 44 4644 8989 / 75500 53335 email : [muruganhosp@gmail.com](mailto:muruganhosp@gmail.com)

Website : [www.muruganhospitals.in](http://www.muruganhospitals.in)



# MURUGAN HOSPITALS

HEALING HANDS



## SCAN REPORT

**NAME** : MR.KALIYAPPAN  
**AGE / SEX** : 49/MALE  
**CONSULTANT:** DR. ARUN PRAKASH

**UHID NO** : MH20210031216  
**IP / OP NO:** OUTPATIENT  
**DATE** : 25-09-2021

## ULTRA SOUND SCAN OF ABDOMEN

**LIVER:** Normal in size and normal in echotexture. No focal lesions are seen. No dilatation of intra-hepatic biliary radicals present. Hepatic veins and IVC appear normal. Portal vein is normal in caliber. Common bile duct is normal in caliber.

**GALL BLADDER:** Normal in size and wall thickness. No evidence of any calculus or mass present. No evidence of pericholecystic collections.

**PANCREAS:** Normal in size and echotexture. No focal lesions are seen. No evidence of calculi or calcifications. No evidence of pancreatic duct dilation.

**PARA AORTIC AREAS:** Aorta and IVC appear normal. No evidence of para aortic lymphadenopathy.

**SPLEEN:** Normal in size and measures 8.5 cm. Normal in echotexture. No evidence of focal lesions.

**RIGHT KIDNEY:** Measures 10.2 X 4.5 cm and is normal in size and echotexture. Cortico medullary differentiation is well maintained. There is no calculus hydronephrosis or mass.

**LEFT KIDNEY:** Measures 9.8 X 4.5 cm and is normal in size and echotexture. Cortico medullary differentiation is well maintained. There is no calculus or hydronephrosis or mass.

**Healing Hearts and Lives**

264/125, Kilpauk Garden Road, Kilpauk, Chennai - 600 010. Phone : +91 44 2644 8989 / 26440519

Email : [admin@muruganhospitals.in](mailto:admin@muruganhospitals.in) | Website : [www.muruganhospitals.in](http://www.muruganhospitals.in)

**URINARY BLADDER: Diffuse bladder wall thickening measures- 6 mm.** There is no evidence of calculus or mass. No vesical diverticulum present.

**PROSTATE:** Normal in size and echotexture. Measures 3.2 X 5.0 X 2.8 cm and approximate volume being 24 cc. Seminal vesicles appear normal.

No ascites present. No retroperitoneal lymphadenopathy present.

**IMPRESSION:**

- ***Features suggestive of cystitis.***
- ***Suggested for urine analysis correlation***



**Dr. SAKTHI, MDRD.**  
**Consultant Radiologist.**



# MURUGAN HOSPITALS

HEALING HANDS



## SCAN REPORT

NAME : Mr.B.KALIPPAN

UHID NO: MH20210031216

AGE / SEX : 49/Y MALE

DATE : 25- 09- 2021

CONSULTANT: DR. ARUN PRAKSH

OP /IP : OUT PATIENT

### CHEST XRAY PA VIEW

- Trachea is in midline.
- Hila appear Normal.
- Mediastinal shadow appears normal.
- Costophrenic&Cardiophrenic angles appear free.
- Cardiothoracic ratio is within normal limits.
- Lungs fields appear clear
- Bony thorax and soft tissue appear normal

### IMPRESSION:

- No significant abnormality noted.



CONSULTANT RADIOLOGIST

**Healing Hearts and Lives**

264/125, Kilpauk Garden Road, Kilpauk, Chennai - 600 010. Phone : +91 44 2644 8989 / 26440519

Email : [admin@muruganhospitals.in](mailto:admin@muruganhospitals.in) | Website : [www.muruganhospitals.in](http://www.muruganhospitals.in)



# MURUGAN HOSPITALS

HEALING HANDS



## ECHO CARDIOGRAM REPORT

NAME : MR.KALIYAPPAN

UHID NO: MH20210031216

AGE&SEX : 49Y /MALE

IP/OP : OUTPATIENT

CONSULTANT: DR. ARUN PRAKASH

DATE : 25-09-2021

### 2D PLAX (mm)

RV - 25 mm  
AO - 34 mm  
LA - 31 mm

### COLOR DOPPLER

Normal

### M-Mode (mm)

IVS - 09 mm  
PW - 08 mm  
LVD - 44 mm  
LVS - 29 mm  
EF - 63 %  
FS - 34 %

### DOPPLER (m/sec)

MITRAL E - 0.7 m/s  
MITRAL A - 1.0 m/s  
PULMONARY - 1.1 m/s  
AORTIC - 1.3 m/s  
TRICUSPID - 0.4 m/s

### IMPRESSION:

No RWMA  
Normal LV Systolic function  
Grade I left ventricular diastolic dysfunction  
Normal RV function  
No pulmonary hypertension  
No pericardial effusion  
No clot/ Vegetation.

  
DR. SIDHANT MD.,DM.,  
CONSULTANT CARDIOLOGIST

Healing Hearts and Lives

264/125, Kilpauk Garden Road, Kilpauk, Chennai - 600 010.

Phone : +91 44 4644 8989 / 75500 53335 | Email : muruganhosp@gmail.com

Website : www.muruganhospitals.in

ID : 2109250004  
Name: MR KALIAPPAN  
Sex : Male  
Divisions:

HR 60 bpm  
P Dur/PR int 93 /143ms  
QRS Dur 93 ms  
QT/QTc int 389/389 ms  
P/QRS/T axis 43/16/7 °

DateTime: 2021-09-25 11:11  
Age : 48  
BP : 100/80 mmHg  
Bed No. :

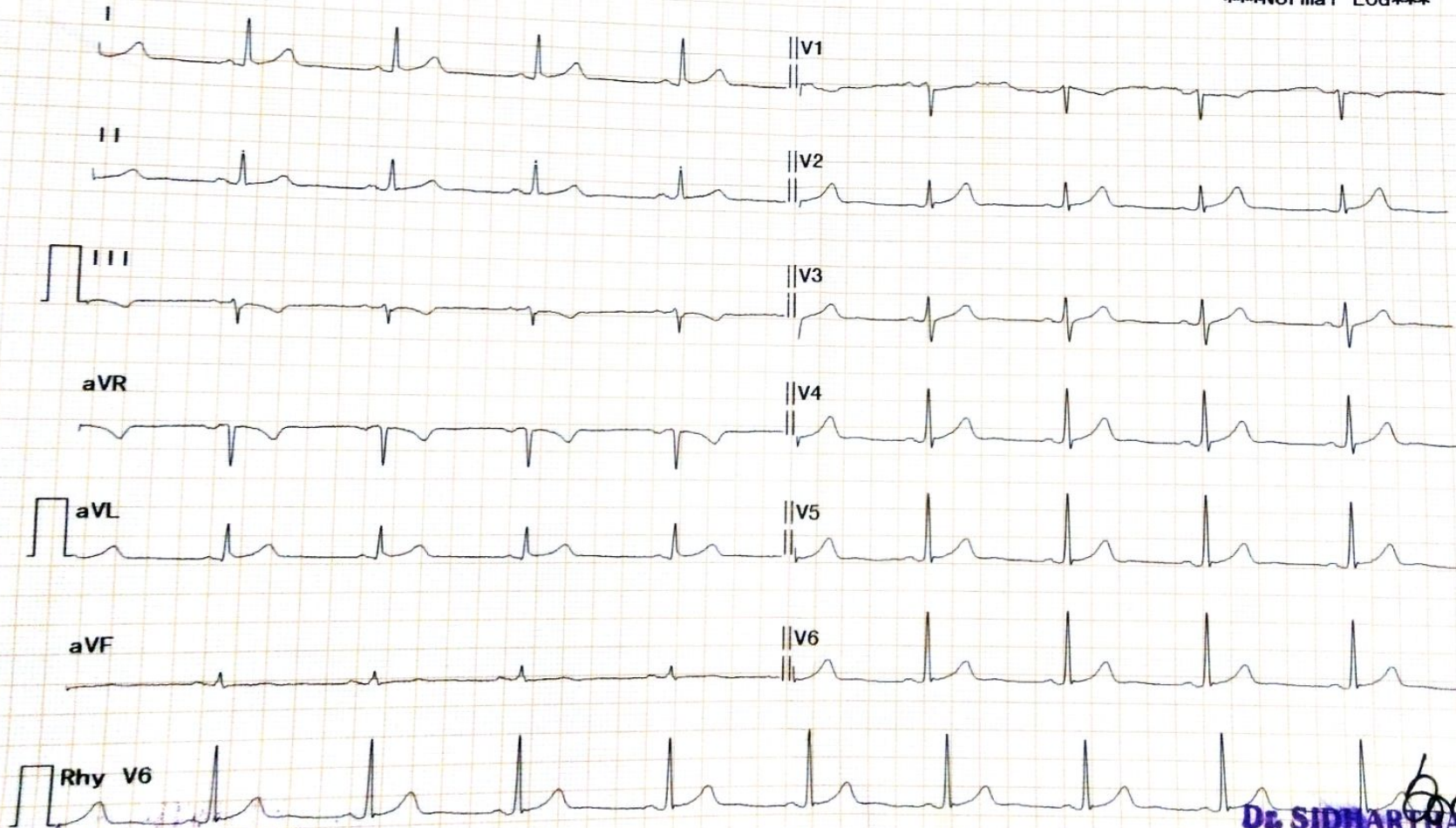
RV5/SV1 amp 1.350/0.495mV  
RV5+SV1 amp 1.845mV  
RV6/SV2 amp 1.388/0.057mV

Hospital: MURUGAN HOSPITALS  
Height : 170 cm  
Weight : 74 kg  
Hospital No.:

Minnesota Code  
9-4-1 (V3)

Diagnosis Info  
800: Sinus Rhythm  
121: Counter Clock Wise Rotation

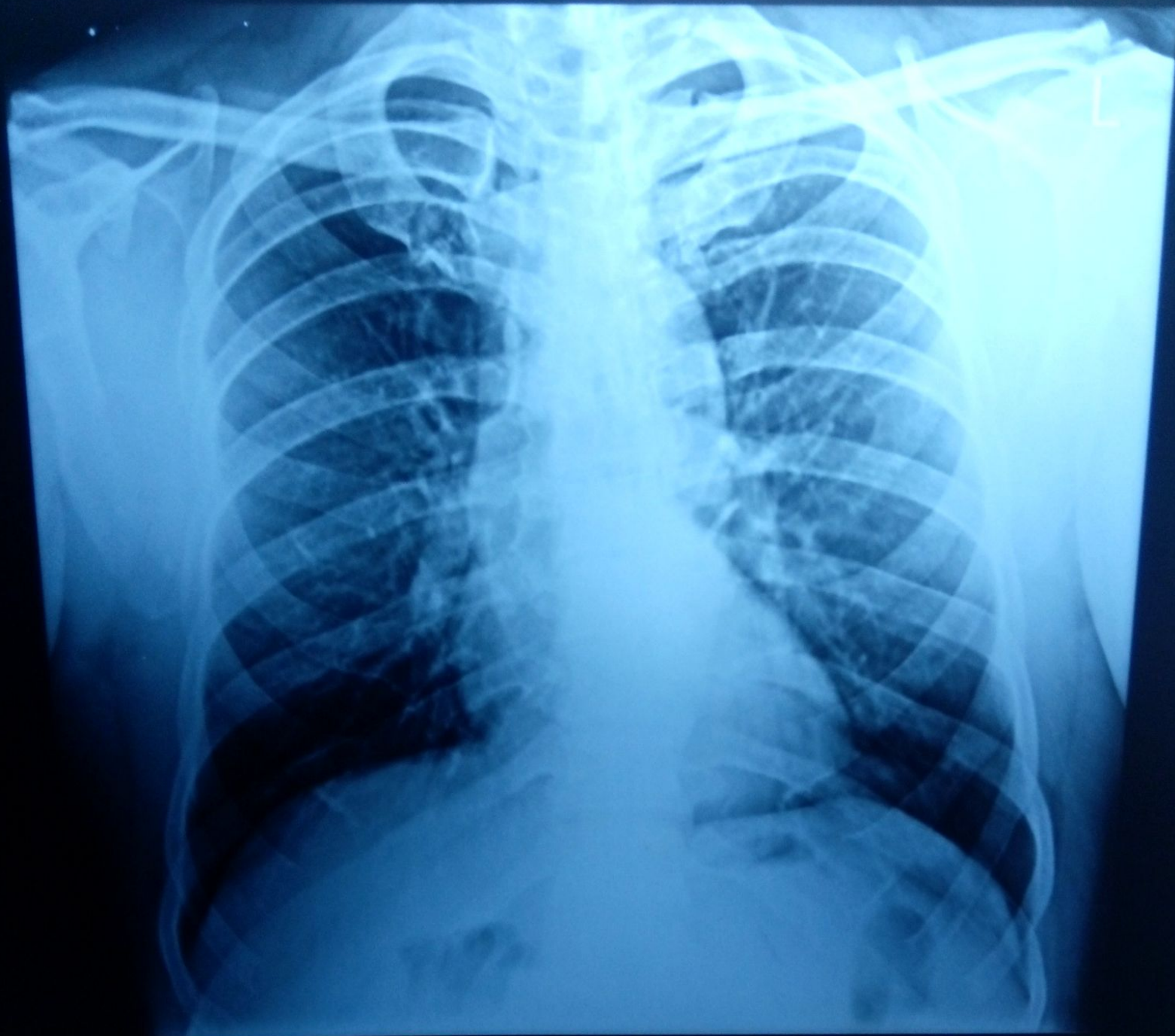\*\*\*Normal ECG\*\*\*



Diagnosis for reference. ask your doctor to confirm  
AUTO PRINT 6X2+1R 60bpm 10 mm/mV 0.50Hz-45Hz AC 50Hz 25 mm/sec Confirmed By:

13  
13.12  
Dr. SIDHARTHAN, MD.,DM.,  
Consultant Cardiologist  
Reg. No.: 62979





MR.KALIAPPAN 49YRS 31216 CHEST-PA 25-09-2021

MURUGAN HOSPITAL S. KIL PAUK CHENNAI 10 PH NO: 7550053335 46448989





# MURUGAN HOSPITALS

HEALING HANDS



## LAB REPORT

Patient Name : Mr. B.KALIAPPAN  
Age / Gender : 49-Years / Male  
UHID ID : MH20210031216  
Doctor Name : Dr. ARUN PRAKASH

OP Report No. : INVA2102494  
Bill No. : INV2104049  
Sample Date : 25/09/2021 - 11:13 AM  
Report Date : 25/09/2021 - 06:57 PM

Test Name	Result	Units	Reference Interval
<b><u>HAEMATOLOGY</u></b>			
<b>Complete Blood Cell Count(CBC)</b>			
HAEMOGLOBIN	14.5	gms/dl	male :13.0 - 17.0 female :12.0 - 15.0
PACKED CELL VOLUME	45.3	%	male : 40 - 50 female : 36 - 46
RBC COUNT	<u>4.91</u>	millions cells/cu.mm	female: 3.8 - 4.8 male : 4.5 - 5.5
TOTAL WBC	4,800	Cells/Cumm	4,000 - 11,000
<b>Differential Count</b>			
NEUTROPHILS	53	%	40 - 65
LYMPHOCYTES	40	%	30-50
EOSINOPHILS	04	%	01-06
MONOCYTES	03	%	1-10
BASOPHILS	00	%	0-2
ESR 60 MTS	05	mm	5 - 20
PLATELET COUNT	2.16	Lakhs/cumm	1.5 - 4.5
MCV	92.3	fL	76 - 96
MCH	29.5	pg	27 - 32
MCHC	32.0	gms/dl	30 - 36

*INTERPRETATION: Test done on automated three part cell counter, all abnormal results are reviewed and confirmed microscopically.*

**BLOOD GROUPING & RH TYPING** " O " POSITIVE

**Healing Hearts and Lives**



# MURUGAN HOSPITALS

HEALING HANDS



## LAB REPORT

Patient Name : Mr. B.KALIAPPAN  
Age / Gender : 49-Years / Male  
UHID ID : MH20210031216  
Doctor Name : Dr. ARUN PRAKASH

OP Report No. : INVA2102494  
Bill No. : INV2104049  
Sample Date : 25/09/2021 - 11:13 AM  
Report Date : 25/09/2021 - 06:57 PM

Test Name	Result	Units	Reference Interval
<b>BIO CHEMISTRY</b>			
BLOOD SUGAR FASTING	91	mg/dl	70-110
BLOOD SUGAR POST PRANDIAL	100	mg/dl	80- 160
SERUM URIC ACID	3.5	mg/dl	male 3.1-7.0 , female 2.5-5.6
<b>LIPID PROFILE</b>			
TOTAL CHOLESTEROL	162	mg/dl	< 200
TRIGLYCERIDE	79	mg/dl	< 150
HDL	49	mg/dl	35 - 80
VLDL	16	mg/dl	2 to 30
LDL	98	mg/dl	<130
CHOLESTEROL/ HDL RATIO	3.3	mg/dl	

**Healing Hearts and Lives**



# MURUGAN HOSPITALS

HEALING HANDS



## LAB REPORT

Patient Name : Mr. B.KALIAPPAN  
Age / Gender : 49-Years / Male  
UHID ID : MH20210031216  
Doctor Name : Dr. ARUN PRAKASH

OP Report No. : INVA2102494  
Bill No. : INV2104049  
Sample Date : 25/09/2021 - 11:13 AM  
Report Date : 25/09/2021 - 06:57 PM

Test Name	Result	Units	Reference Interval
<b>LIVER FUNCTION TEST</b>			
BILLIRUBIN(TOTAL)	1.0	mg/dl	0.0 -1.0
BILLIRUBIN(DIRECT)	0.3	mg/dl	0.1- 0.30
BILLIRUBIN(INDIRECT)	0.7	mg/dl	0.2-0.8
SGOT	21	IU/L	0-38
SGPT	18	IU/L	0.0-40
ALKALINE PHOSPHATASE	48	IU/L	40-140 4-6Years 93-309 13-15Years 74-390
TOTAL PROTEIN	7.6	gm/dl	6.6-8.7
ALBUMIN	4.4	gm/dl	3.5 - 5.5
GLOBULIN	3.2	gm/dl	2.0-3.5
A/G RATIO	1.2		
GAMMA G T	22	U/L	male<49 female<32
BUN	10	mg/dl	7-21
HBA1C	5.0	%	normal: <6.0 good control: 6.1-7.0 fair control: 7.1- 8.0 poor control:8.1 -10.0 unsatisfactory: >10.0

**Healing Hearts and Lives**



# MURUGAN HOSPITALS

HEALING HANDS



## LAB REPORT

Patient Name : Mr. B.KALIAPPAN  
Age / Gender : 49-Years / Male  
UHID ID : MH20210031216  
Doctor Name : Dr. ARUN PRAKASH

OP Report No. : INVA2102494  
Bill No. : INV2104049  
Sample Date : 25/09/2021 - 11:13 AM  
Report Date : 25/09/2021 - 06:57 PM

Test Name	Result	Units	Reference Interval
<b><u>CLINICAL PATHOLOGY</u></b>			
URINE SUGAR (F)	NIL		
<b>URINE ROUTINE</b>			
COLOUR	PALE YELLOW		
APPEARANCE	CLEAR		
REACTION	ACIDIC		
ALBUMIN	NIL		
<b>DEPOSITES</b>			
PUS CELLS	2 - 3	/ HPF	
EPI CELLS	1 - 2	/ HPF	
RBC COUNT	NIL	/ HPF	
CAST	NIL		
CRYSTALS	NIL		
OTHERS	NIL		
<b><u>ENDOCRINOLOGY</u></b>			
T3	0.920	ng/ml	0.52-1.85
T4	6.649	ug/dl	5.0 -13.0 ug/dl
TSH	1.937	uIU/ml	0.39 - 6.16 uiu/ml

MALATHI

Verified by

\*\*\* End of Report \*\*\*



**Healing Hearts and Lives**



# MURUGAN HOSPITALS

HEALING HANDS



## LAB REPORT

Reg.ID : I - 29505  
 Patient Name : MR. B KALIAPPAN  
 Contact No : -  
 Age : 49 (Male)  
 Referral : DR. ARUN PRAKASH S.  
 Source : MURUGAN HOSPITALS  
 Report ID : 41076

Reg. Date : Sep 25, 2021, 02:02 p.m.  
 Sample Date : Sep 25, 2021, 02:07 p.m.  
 Report Date : Sep 25, 2021, 03:22 p.m.  
 Print Date : Sep 25, 2021, 06:08 p.m.  
 Sample ID :



1921090855

Test Description	Value(s)	Reference Range
------------------	----------	-----------------

### TEST REPORT

#### IMMUNOLOGY

PSA - TOTAL (Method/Sample : ECLIA/Serum)	: 1.28 ng/mL	0.0 - 4.0
--	--------------	-----------

#### CLINICAL PATHOLOGY

##### STOOL ANALYSIS

##### MACROSCOPIC EXAMINATION

Colour : Yellowish  
 Consistency : Semisolid  
 Reaction (pH) : Alkaline  
 Mucus : Absent  
 Blood : Absent

##### MICROSCOPIC EXAMINATION

Pus cells : 2-3/hpf  
 Epithelial cells : Nil  
 Rbc : Nil  
 Ova : Nil  
 Cyst : Nil  
 Trophozoites : Nil  
 Others : Bacteria present

Dr. Hema Vaneeswari. C., MD  
 CONSULTANT PATHOLOGIST

Note: All Lab test values are subjective and may have variation in context to age, gender and clinical status. The reference values given are a guidance, all variations in test values are to be interpreted with clinical correlation.

Healing Hearts and Lives

264/125, Kilpauk Garden Road, Kilpauk, Chennai - 600 010.  
 Phone : +91 44 4644 8989 / 75500 53335 | Email : muruganhosp@gmail.com  
 Website : www.muruganhospitals.in



# MURUGAN HOSPITALS

HEALING HANDS



## LAB REPORT

Patient Name : Mr. B.KALIAPPAN  
Age / Gender : 49-Years / Male  
UHID ID : MH20210031216  
Doctor Name : Dr. ARUN PRAKASH

OP Report No. : INVA2102509  
Bill No. : INV2104075  
Sample Date : 26/09/2021 - 11:51 AM  
Report Date : 26/09/2021 - 11:55 AM

Test Name	Result	Units	Reference Interval
-----------	--------	-------	--------------------

### BIO CHEMISTRY

SERUM CREATININE

1.0

mg/dl

0.7-1.4

MALATHI

Verified by

\*\*\* End of Report \*\*\*



  
**Dr. PAVITHRA, MD.**  
Pathologist  
Reg. No.: 78256

Page 1 of 1

**Healing Hearts and Lives**

264/125, Kilpauk Garden Road, Kilpauk, Chennai - 600 010.  
Phone : +91 44 4644 8989 / 75500 53335 | Email : muruganhosp@gmail.com  
Website : www.muruganhospitals.in