

Patient Name:	ASHISH KUMAR SRIVASTAVA	Patient ID:	MILL.0000045650
Age:	35 Years	Sex:	M
Accession Number:	17101.123012691	Modality:	DX
Referring Physician:	Akhil Kumar Tiwari	Study:	CHEST
Study Date:	27-Nov-2023		

X-RAY CHEST (PA VIEW)

Both lung fields are clear. No active pleural or parenchymal lesion is seen.

The hila, mediastinum, bony thoracic cage and the diaphragmatic domes are normal.


The costophrenic and cardiophrenic angles are clear.

The cardiac silhouette is unremarkable.

IMP:- RADIOGRAPHIC IMAGE REVEALS:-

Normal findings are seen.

Thanks for Ref



DR. HARI SANTOSH
CONSULTANT RADIOLOGIST

Date: 27-Nov-2023 15:12:47



Ashish Shrivastava

33/A 9753430779



Admission Salary 



Dep. of ophthalmology.

No. Astish kumar. 35/M.

27/11/23.

Vn $\left\{ \begin{array}{l} 6/9 \\ 6/9 \end{array} \right.$

Sub (R) $-0.75 / -0.5 \times 75^\circ$ 6/6.

(L) -1.00 Dsph $-$ 6/6

Nv $-$ Ng (Be).

AR $\left\{ \begin{array}{l} -1.25 / -0.5 \times 74 \\ -1.25 \end{array} \right.$



DR ANKIT MISHRA

MBBS MS (Otorhinolaryngology Head & Neck Surgery)
EAR NOSE THROAT HEAD & NECK SURGEON
FELLOWSHIP IN ENDOSCOPIC SINUS SURGERY
Registration no- MP-15530



NAME Ashish Kumar AGE 35 M/F DATE 27/11/23

Rouxn CM Cheep

C
W / ~~T~~ med
T

R

- Newspan - 1 gm - 300
X 5 days

- Tab Augment - 500 mg

Am



Ashish Kumar
ID: 5650

Vital Signs™ 226 166 05

27.11.20 12:15:24

35 Years Male

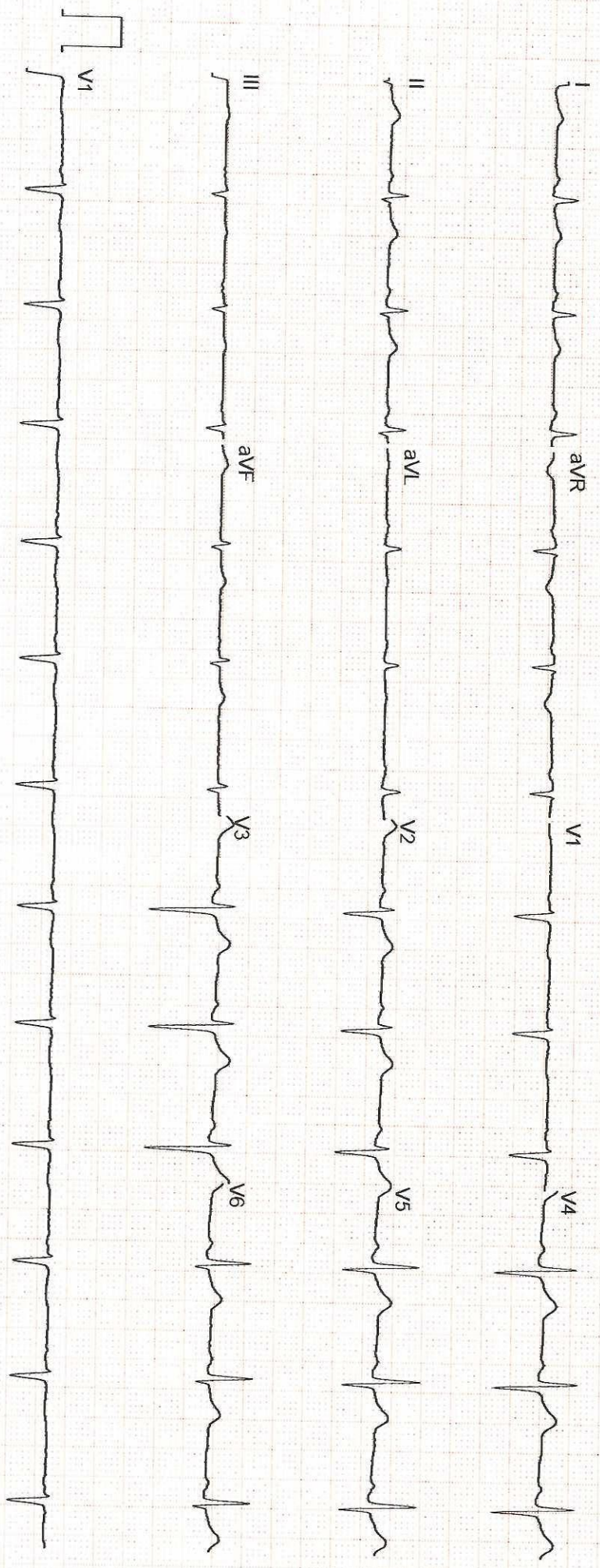
QRS : 74 ms
 QT / QTcBaz : 376 / 417 ms
 PR : 148 ms
 P : 98 ms
 RR / PP : 806 / 810 ms
 P / QRS / T : 11 / 12 / 33 degrees

Normal sinus rhythm
Normal ECG

Location: P m:
 Order No: sr:
 Indication:
 Medication 1:
 Medication 2:
 Medication 3:

Technician:
 Ordering Ph:
 Referring Ph:
 Attending Ph:

74 bpm
 - / - mmHg



GE MAC2000 1.1 12SL™ V241

25 mm/s 10 mm/mV

ADS 0.5-20 Hz 50 Hz 4x2.5x3_25_R1

Unconfirmed

APOLLO SAGE HOSPITALS
BAWADIYA KALAN, BHOPAL

Name **ASHISH KUMAR SRIVASTAVA,**

Gender **Male**

Patient Id **MILL.0000045650**

Age **35 years**

Date **27/11/2023**

2D

M-Mode		Doppler	
IVSd	1.2 cm	MV E Vel	0.52 m/s
LVIDd	3.4 cm ✓	MV DecT	239 ms
LVPWd	1.1 cm	MV Dec Slope	2.2 m/s ²
IVSs	1.3 cm	MV A Vel	0.56 m/s
LVIDs	2.2 cm	MV E/A Ratio	0.93
LVPWs	1.2 cm	AV Vmax	1.05 m/s
EDV(Teich)	48 ml	AV Vmean	0.70 m/s
ESV(Teich)	17 ml	AV maxPG	4.39 mmHg
EF(Teich)	65 % ✓	AV meanPG	2.31 mmHg
%FS	34 %	AV Env.Ti	265 ms
SV(Teich)	31 ml	AV VTI	18.6 cm
RWT	0.62	HR	75 BPM
Ao Diam	2.7 cm	PV Vmax	0.93 m/s
LA Diam	3.1 cm	PV Vmean	0.61 m/s
LA/Ao	1.13	PV maxPG	3.50 mmHg
		PV meanPG	1.79 mmHg

ECHO SUMMARY

- Left Ventricle: Normal Left Ventricular Size, Wall Thickness & Functions
- Left Ventricular Ejection Fraction is Within Normal Limits (LVEF = 60%)
- Left Atrium: Normal Left Atrial Size & Functions
- Right Ventricle: Normal Right Ventricular Size & Functions
- Right Atrium: Normal Right Atrial Size & Function.
- Valvular Structures: Normal Mitral, Tricuspid, Pulmonic & Aortic Valve Structures
- Aortic Root is Normal
- No Evidence of Pericardial Effusion

Dr. Gaurav Khandelwal
DM (Cardiology), FACC, FESC, FSCAI, FIC
Interventional Cardiologist

Dr. Anurag Jain
MD, DNB, DM (Cardiology)
Interventional Cardiologist

Dr. Akhil Kumar Tiwari
MD, FRCP (UK)
Senior Consultant, Internal Medicine
Clinical Cardiology

Dr. Manish Kedia
MBBS, PGDCC
Specialist Non Invasive
& Clinical Cardiology

APOLLO SAGE HOSPITALS

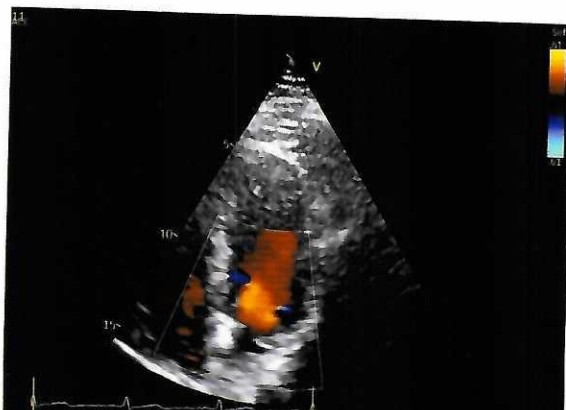
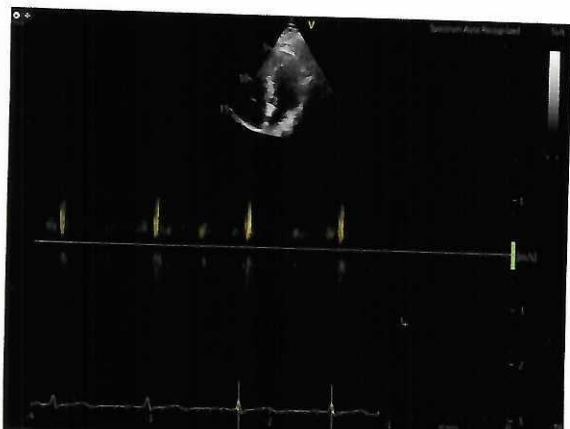
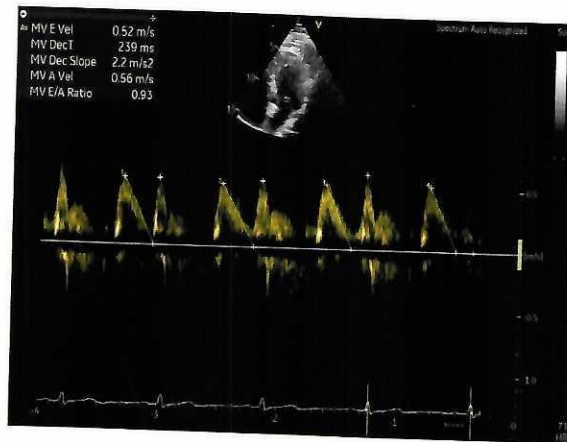
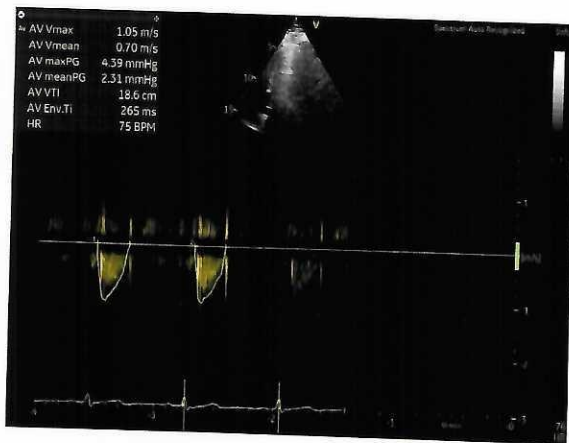
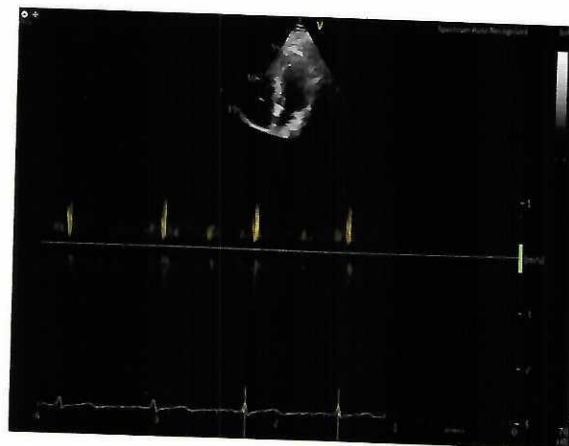
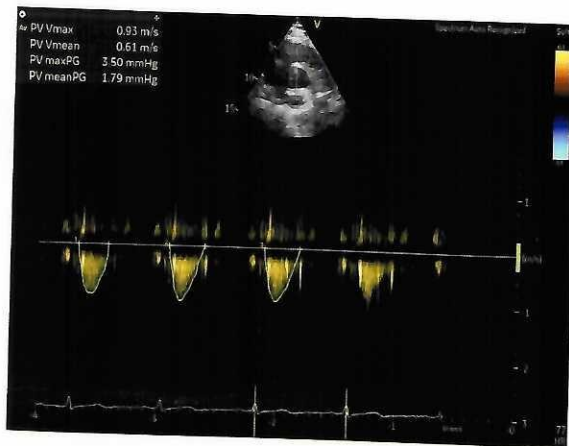
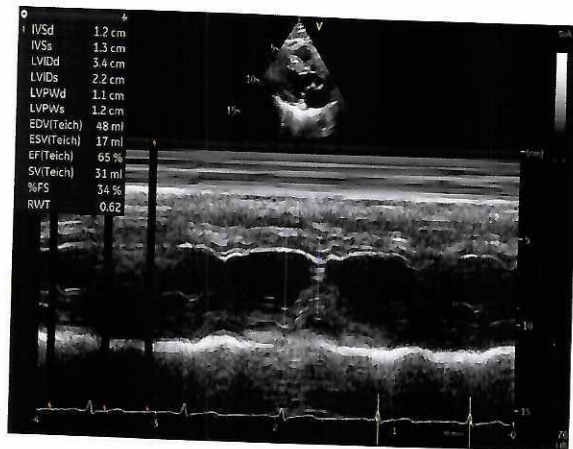
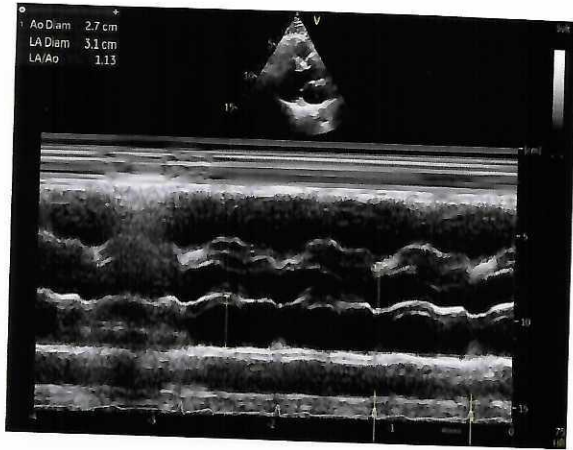
BAWADIYA KALAN , BHOPAL

Name **ASHISH KUMAR SRIVASTAVA,**

Gender **Male**

Patient Id **MILL.0000045650**

Date **27/11/2023**



ULTRA SONOGRAPHY ABDOMEN

Patient Name:	ASHISH KUMAR SRIVASTAVA	Patient ID:	MILL.0000045650
Age:	35 Years	Sex:	M
Accession Number:	17101.223008970	Modality:	US
Referring Physician:	Akhil Kumar Tiwari	Study:	ULTRASOUND - WHOLE ABDOMEN
Study Date:	27-Nov-2023		

Liver:- is mildly enlarged and shows mild increased in parenchymal echotexture. Portal and hepatic venous system appears normal. Intra and extra hepatic biliary radicals are not dilated.

Gall Bladder:- is normal in size and shape. Its lumen is echofree.

Pancreas is normal in size outline and echopattern.

Spleen is normal in size and echopattern.

Both kidneys are normal in size, shape and echogenicity. Central pelvicalyceal sinus and corticomedullary ratio are normal.

Right kidney measures:- 10.4x3.9cm

Left kidney measures:- 11.3x4.7cm

Urinary bladder is normal in shape and contour. Its wall is normal.

Prostate is normal in size and shape and echotexture. Estimated volume is- 21cc.

No evidence of ascites is seen.

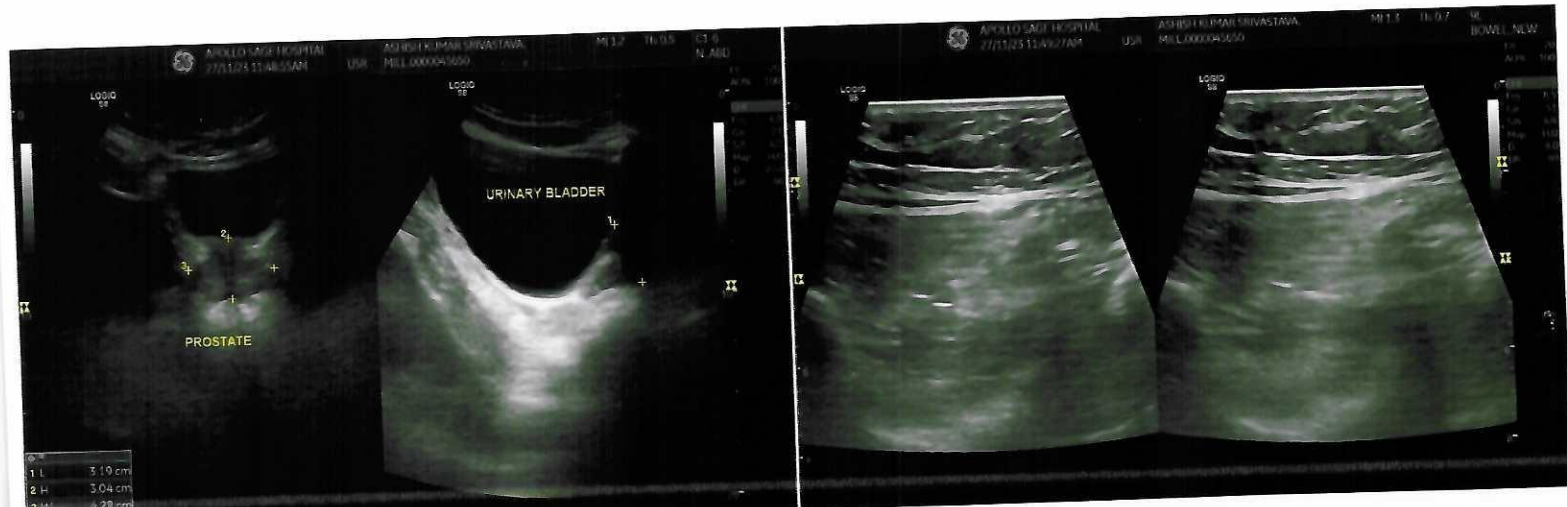
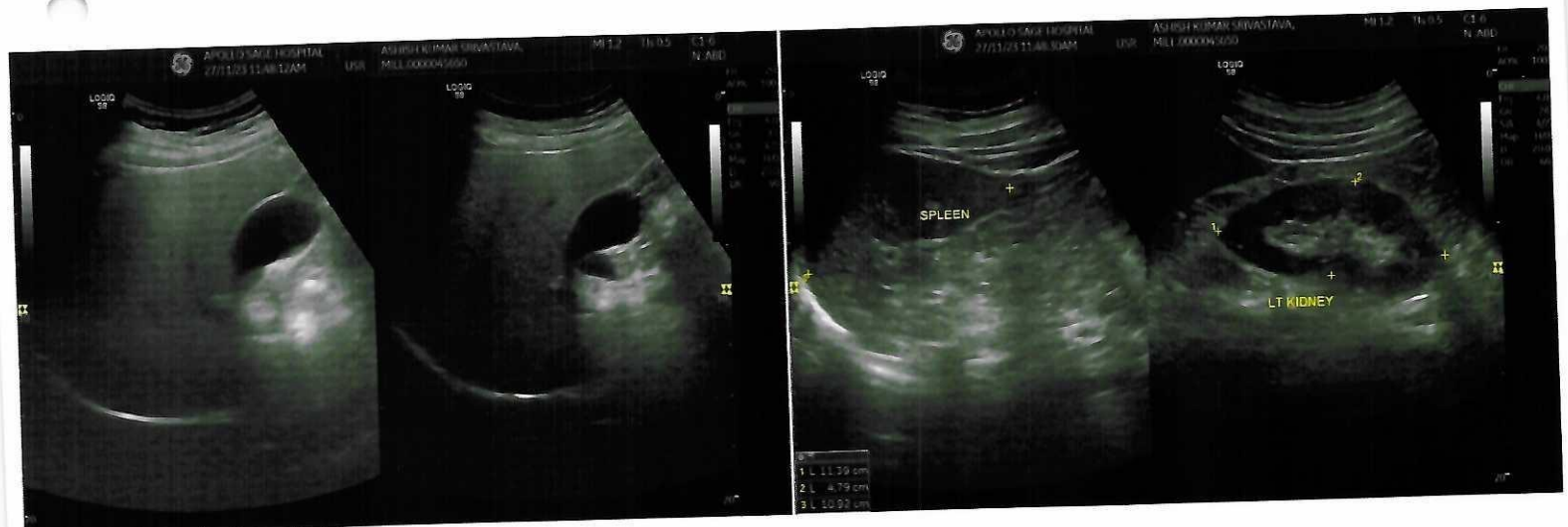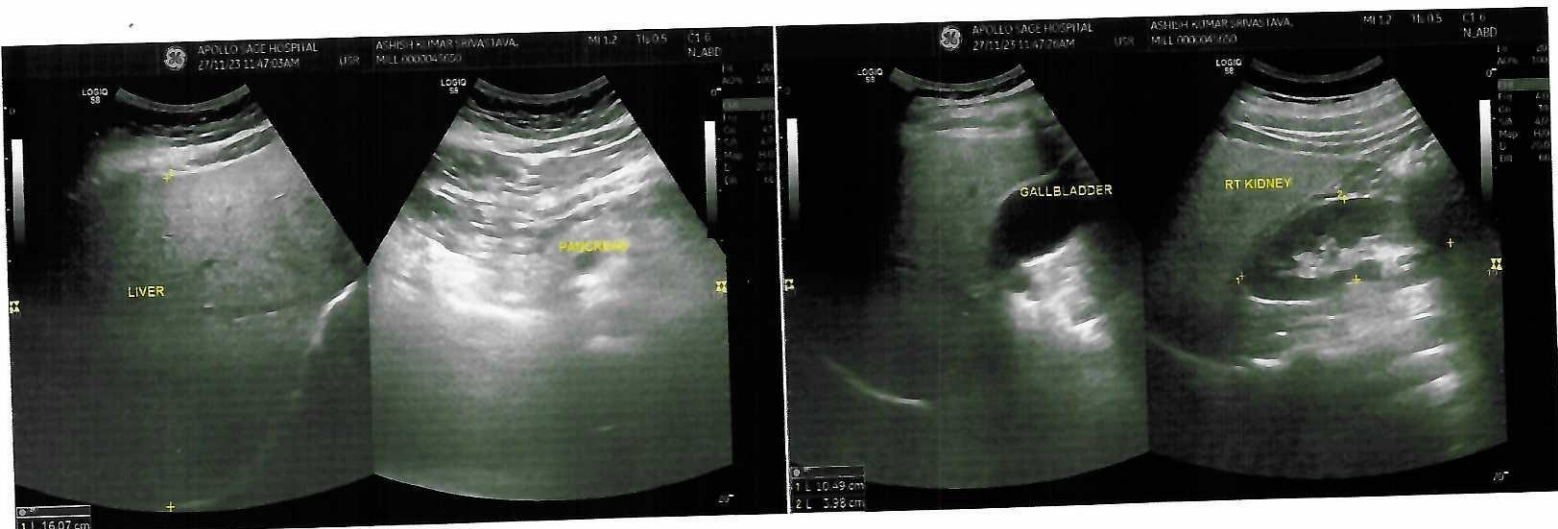
IMPRESSION:- Sonography Study Reveals:-

- Mild hepatomegaly with grade- I fatty liver. ✓

ADV:- Clinical Correlation.


DR. HARI SANTOSH
 CONSULTANT RADIOLOGIST







Out Patient Assessment Form

Apollo Hospital, Bhopal

Place Patient Label Here

MR. ASHISH KUMAR
If label not available, write Pt. Name UHID No. IP
No Age, Sex, Date, Name of Treating Physician

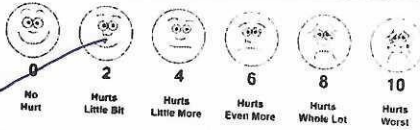Date : 27/11/23

Time : 12:34 PM

Consultant Name : HC

Pain Assessment

Nursing Assessment



Height 167cm

Weight 96.3kg

Pulse : 86/m

BP : 100/84

Allergies (if any)

No

Falls risk :

Yes

No

Oral hygiene :

Poor

Fair

Good

Investigation Ordered

Chief complains past medical / surgical history. Diagnosis, Treatment Plan, Current Medications & Follow - up advice :

SpO2 - 99.1

BMI - 34.5

Patient Education (Patient Is Briefed on Following) Cost May Vary In Course Of Disease

Proposed Care Plan Yes No

Expected Outcome : Yes No

Expected Cost : Yes No

Admission Advice : Yes No

Consultant Signature

Date :

Time

Name : Mr. ASHISH KUMAR SRIVASTAVA**OP Number:** BPLAH4822**Bill No:** BPL-OCR-2337**Package Information**

S.No	Service Type\Service Name	Department
1	MEDIWHEEL FULL BODY ANNUAL CHECKUP	
1	ALBUMIN - SERUM	BioChemistry
2	ALBUMIN/GLOBULIN RATIO	BioChemistry
3	ALKALINE PHOSPHATASE - SERUM/PLASMA	BioChemistry
4	ALT(SGPT) - SERUM / PLASMA	BioChemistry
5	AST (SGOT) - SERUM	BioChemistry
6	BILIRUBIN CONJUGATED (DIRECT) - SERUM	BioChemistry
7	BILIRUBIN UNCONJUGATED (INDIRECT) - SERUM	BioChemistry
8	BILIRUBIN, TOTAL - SERUM	BioChemistry
9	BLOOD GROUPING AND TYPING (ABO and Rh)	Blood Bank - 2 Services
10	BUN (BLOOD UREA NITROGEN)	BioChemistry
11	CBC	Haematology
12	CHOLESTEROL - SERUM / PLASMA	BioChemistry
13	COMPLETE BLOOD COUNT(CBC) WITH ESR	Haematology
14	CONSULTATION - DENTAL	Dental
15	CONSULTATION - DIET	Dietetics
16	CONSULTATION - ENT	Ear Nose and Throat
17	CONSULTATION - INTERNAL MEDICINE	General Medicine
18	CONSULTATION - OPHTHALMOLOGY	Ophthalmology
19	CREATININE - SERUM / PLASMA	BioChemistry
20	ECG	CARDIOLOGY
21	ERYTHROCYTE SEDIMENTATION RATE (ESR)	Haematology
22	GGTP: GAMMA GLUTAMYL TRANSPEPTIDASE - SERUM	BioChemistry
23	GLOBULIN - SERUM	BioChemistry
24	GLUCOSE - SERUM / PLASMA (FASTING)	BioChemistry
25	GLUCOSE - SERUM / PLASMA (POST PRANDIAL)	BioChemistry
26	HDL CHOLESTEROL - SERUM / PLASMA	BioChemistry

Name : Mr. ASHISH KUMAR SRIVASTAVA		OP Number: BPLAH4822	Bill No: BPL-OCR-2337
27	HISTORY TAKING - AHC		Medical
28	LDL CHOLESTEROL - SERUM / PLASMA		BioChemistry
29	LIPID PROFILE TEST (PACKAGE)		BioChemistry
30	LIVER FUNCTION TEST (PACKAGE)		BioChemistry
31	PHYSICAL EXAMINATION		Medical
32	PROTEIN TOTAL - SERUM / PLASMA		BioChemistry
33	THYROID PACKAGE		BioChemistry
34	TMT/2D ECHO		CARDIOLOGY
35	TOTAL CHOLESTEROL AND HDL RATIO		BioChemistry
36	TOTAL T3: TRI IODOTHYRONINE - SERUM		BioChemistry
37	TOTAL T4: THYROXINE - SERUM		BioChemistry
38	TRIGLYCERIDES - SERUM / PLASMA		BioChemistry
39	TSH: THYROID STIMULATING HORMONE - SERUM		BioChemistry
40	ULTRASOUND - WHOLE ABDOMEN		Ultrasound Radiology
41	URIC ACID - SERUM / PLASMA		BioChemistry
42	URINE ROUTINE (CUE)		Haematology
43	VLDL CHOLESTEROL - SERUM		BioChemistry
44	X-RAY CHEST PA		X Ray

Amount saved on availing Health Check Package INR 11970

Note: Cancellation of individual test will not be refunded.

Amount saved on availing Health Check Package INR 11970