



To,

The Coordinator,
Mediwheel (Arcofemi Healthcare Limited)
Helpline number: 011- 41195959

Dear Sir / Madam,

Sub: Annual Health Checkup for the employees of Bank of Baroda

This is to inform you that the following spouse of our employee wishes to avail the facility of Cashless Annual Health Checkup provided by you in terms of our agreement.

PARTICULARS OF HEALTH CHECK UP BENEFICIARY	
NAME	PRITI MISHRA
DATE OF BIRTH	01-05-1988
PROPOSED DATE OF HEALTH CHECKUP FOR EMPLOYEE SPOUSE	11-09-2021
BOOKING REFERENCE NO.	21S123739100003648S
SPOUSE DETAILS	
EMPLOYEE NAME	MR. MISHRA RAKESH KUMAR
EMPLOYEE EC NO.	123739
EMPLOYEE DESIGNATION	SINGLE WINDOW OPERATOR A
EMPLOYEE PLACE OF WORK	DHANBAD
EMPLOYEE BIRTHDATE	26-09-1978

This letter of approval / recommendation is valid if submitted along with copy of the Bank of Baroda employee id card. This approval is valid from **08-09-2021** till **31-03-2022**. The list of medical tests to be conducted is provided in the annexure to this letter. Please note that the said health checkup is a **cashless facility** as per our tie up arrangement. We request you to attend to the health checkup requirement of our employee's spouse and accord your top priority and best resources in this regard. The EC Number and the booking reference number as given in the above table shall be mentioned in the invoice, invariably.

We solicit your co-operation in this regard.

Yours faithfully,

Sd/-

**Chief General Manager
HRM Department
Bank of Baroda**

(Note: This is a computer generated letter. No Signature required. For any clarification, please contact Mediwheel (Arcofemi Healthcare Limited))

OUT PATIENT DEPARTMENT



Type : Mediwheel
 DEPARTMENT OF GENERAL MEDICINE

Regd. No. :	SEP21-22922	Visit :	OPD/110921/452
Patient Name :	MRS. PRITI MISHRA	Mobile :	9425794937
Age/Sex :	33 Yrs / FEMALE	Date :	11-Sep-2021
Address :	MATHURA NAGAR, KOLA KUSMA-, DHANBAD Jharkhand , INDIA		
Doctor :	Dr. PANKAJ KUMAR (M.B.B.S, DNB-GENERAL MEDICINE),		
OPD Timing :			

BP- 125/85mmHg.
 G- 80mg.

for body health checkup

Ivo

- LFT
- Routine urine.
- T₃, T₄, TSH
- BSR
- CBC
- Blood grouping
- Blood urea nitrogen
- USG Abdomen
- X-Ray chest PA
- Echo
- BCG.
- KFT Band.

Adn

- no need medicine.

Dr. PANKAJ
 DNB (Medicine)
 Asarfi Hospital
 Dhanbad, Jharkhand

DEPARTMENT OF PATHOLOGY

Name : MRS. PRITI MISHRA
Age : 33 Yrs Sex : Female
Doctor : SELF WALK-IN
Reg. No. : SEP21-22922
Sub Dept. : Biochemistry

Lab No: : 2,628
Collection Date: 11-Sep-2021
Collection Time: 12:48:14PM
Reporting Date : 14-Sep-2021

Test	Result	Reference Range
LIVER FUNCTION TEST (LFT)		
Bilirubin (Total)	0.9 mg/dl	0.2 - 1.0 mg/dl
Bilirubin (Direct)	0.3 mg/dl	0 - 0.2 mg/dl
Bilirubin (Indirect)	0.6 mg/dl	0.2 - 0.8 mg/dl
Total Proteins	7.1 g/dl	6.5 - 8.5 g/dl
Albumin	3.9 g/dl	3.5 - 5.5 g/dl
Globulin	3.2 g/dl	1.5 - 3.5 g/dl
SGOT	18.9 IU/L	< 40 IU/L
SGPT	22.2 IU/L	< 49 IU/L
Alkaline Phosphatase	160.0 IU/L	70-306 IU/L
Gamma-GT	9.8 U/L	0-38 U/L

DEPARTMENT OF PATHOLOGY

Name : MRS. PRITI MISHRA
Age : 33 Yrs Sex : Female
Doctor : SELF WALK-IN
Reg. No. : SEP21-22922
Sub Dept. : Clinical Pathology

Lab No: : 2,634
Collection Date: 11-Sep-2021
Collection Time: 12:48:40PM
Reporting Date : 14-Sep-2021

Test	Result	Reference Range
<u>Routine Examination of Urine</u>		
Quantity	30 ml (Approx)	
Colour	STRAW	
Appearance	CLEAR	
Specific Gravity	1.010	
Reaction (pH)	ACIDIC	
Albumin.	PRESENT (+)	
Sugar	NIL	
Ketone Bodies	XX	
Bile Salts	XX	
Bile Pigments	XX	
RBC	NIL /hpf	
Pus Cells	0-1 /hpf	/hpf
Epithelial Cells	1-2	
Casts	NOT SEEN /hpf.	/hpf.
Crystals	NOT SEEN /hpf.	/hpf.
Bacteria	NOT SEEN /hpf.	/hpf.

DEPARTMENT OF PATHOLOGY

Name : MRS. PRITI MISHRA
Age : 33 Yrs Sex : Female
Doctor : SELF WALK-IN
Reg. No. : SEP21-22922
Sub Dept. : Immunology

Lab No: : 2,628
Collection Date: 11-Sep-2021
Collection Time: 12:48:14PM
Reporting Date : 14-Sep-2021

Test	Result	Reference Range
Thyroid hormones T3 T4 TSH (Enzyme Immunoassay)		
T3, Total, Serum	0.94 ng/ml	0.74-1.79 ng/ml
T4, Total, Serum	6.95 ng/dl	4.7-12.8 ng/dl
TSH, SERUM (Enzyme Immunoas)	1.75 μ IU/ml	0.25-5.00 μ IU/ml
ESR		
E.S.R (Westergren)	29 mm/hr	0 - 15 mm/hr
CBC		
Haemoglobin	12.7 g/dl	11-16 g/dl
Red Blood Cells Count	4.63 / cumm	4.0 - 6.0 / cumm
TOTAL COUNT OF PLATELET	1.66 lakhs/cumm	1 - 4 lakhs/cumm
Total WBC Count	5,400 /cumm	4000 - 11000 /cumm
Neutrophils	60 %	55 - 75 %
Lymphocytes	33 %	15 - 30 %
Eosinophils	05 %	1 - 6 %
Monocytes	02 %	2 - 10 %
Basophils	00 %	0 - 1 %
PCV	38.7 %	40 - 54 %
MCV	83.6 cu-microns	80 - 99 cu-microns
MCHC	32.8 %	32 - 38 %



DEPARTMENT OF PATHOLOGY

Name : MRS. PRITI MISHRA
Age : 33 Yrs Sex : Female
Doctor : SELF WALK-IN
Reg. No. : SEP21-22922
Sub Dept. : Haematology

Lab No. : 2,629
Collection Date: 11-Sep-2021
Collection Time: 12:48:17PM
Reporting Date : 14-Sep-2021

Test	Result	Reference Range
------	--------	-----------------

ABO Group	<u>Blood Grouping</u> "O"	
Rh (Factor)	POSITIVE	
Blood Urea Nitrogen	<u>Blood Urea Nitrogen</u> 8.5 mg/dl	5 - 20 mg/dl

Dhanbad's 1st NABH & NABL Certified Hospital & Lab

PATHOLOGIST

24 HOUR EMERGENCY

©AHL/D/0066



"KEEP THE REPORTS CAREFULLY AND BRING THEM ALONG DURING YOUR NEXT VISIT TO OUR HOSPITAL"



RADIOLOGY REPORT

Reg. No.	22922	Ref. Dr.	SELF
Name	MRS. PRITI MISHRA	Study	USG W/A
Age & Sex	33Y /F	Reporting Date	11.09.2021

USG WHOLE ABDOMEN

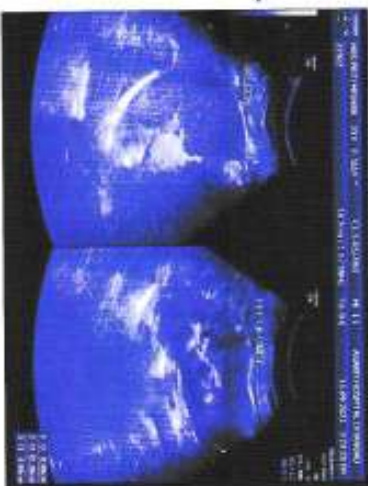
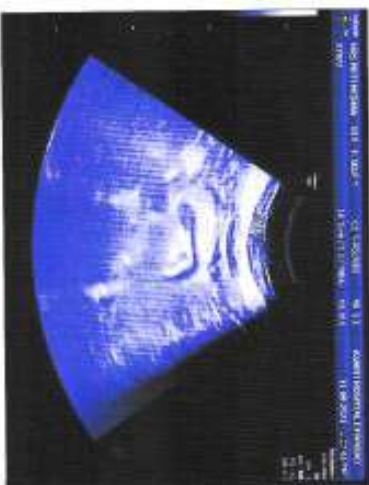
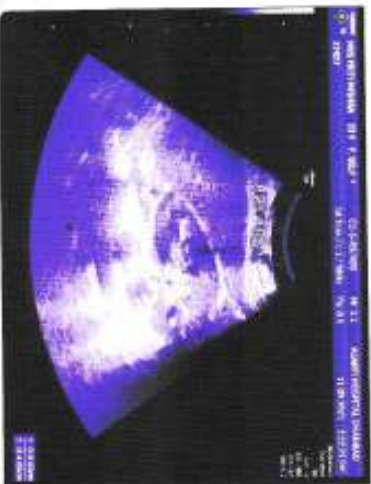
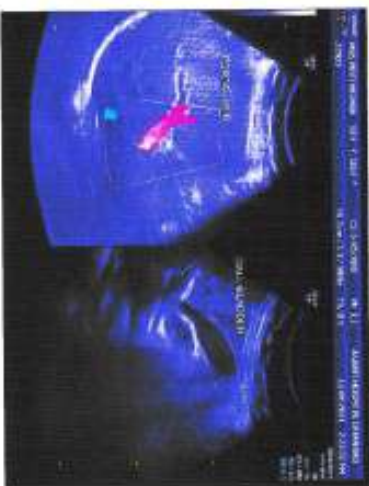
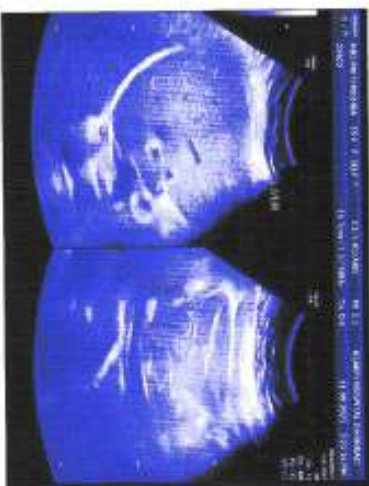
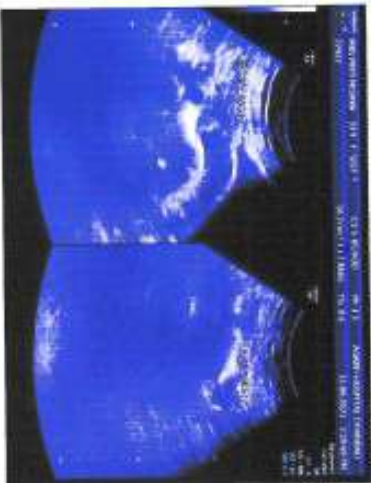
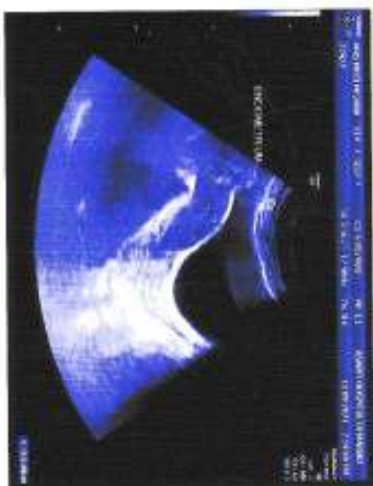
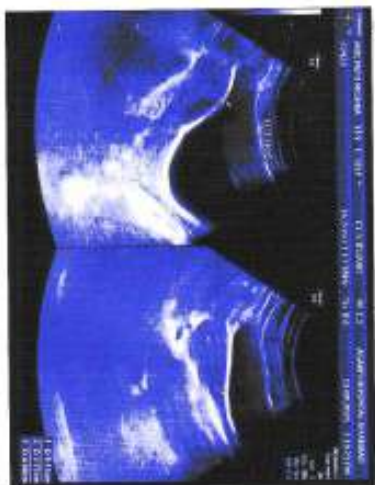
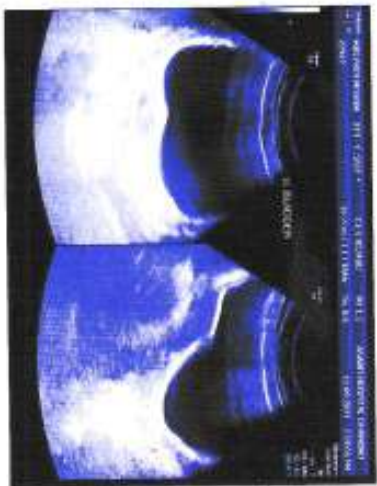
- LIVER** : Liver is normal in size, shape & echotexture. No obvious focal lesion is seen. IHBR are not dilated.
- GALL BLADDER** : GB is well distended. No obvious calculus or mass lesion is seen. The wall thickness is normal.
- CBD** : CBD is normal in course & caliber.
- PV** : PV is normal in course & caliber.
- PANCREAS** : Pancreas is normal in size, shape & echotexture. Peripancreatic soft tissues appear normal. MPD is not dilated.
- SPLEEN** : Spleen is normal in shape, size & echotexture. It measures 10.9 cm in size.
- KIDNEYS** : The right kidney measures 9.5 x 4 cm. The left kidney measures 10.3 x 4.2 cm. Both kidneys are normal in shape, size & position. The pelvicalyceal system is normal. Corticomedullary differentiation is maintained. No focal lesion is seen.
- URINARY BLADDER** : Urinary bladder is well distended. No obvious calculus or mass lesion is seen.
- UTERUS** : Uterus is normal in size, shape & echotexture. It measures 9.1 x 2.7 x 3.6 cm. Endometrium thickness is 4.8mm.
- OVARIES** : Both ovaries are normal in shape, size & position.
- OTHERS** : No ascites or retroperitoneal lymphadenopathy is seen.

IMPRESSION : • **No significant abnormality detected.**
Clinical correlation is suggested.

11/09/2021

Dr. VAISHALI PATEL
MBBS, DNB (Radio-diagnosis)
Consultant Radiologist







असर्फी हॉस्पिटल

सबके लिए स्वास्थ्य

Baramuri, P.O. - Bishunpur Polytechnic, Dhanbad (Jharkhand) - 828130
Regd. Office : Phulantand, Kharkaree, Dhanbad (Jharkhand) - 828125
Mob : 9234302735, 9234651512, 9234681514
CIN : U85110JH2005PLC011673



RADIOLOGY REPORT

Patient Information			
Patient Name:	MRS PRITI MISHRA	Patient ID	22922
Age Gender	33Y/FEMALE	Scan Date	SEP 11 2021
Referring Doctor	DR SELF	Report Date	SEP 11 2021

X-RAY CHEST

VIEWS

PA View of Chest

FINDINGS

Lungs

- Both para hilar shadow in calcification see.

Airways

- Trachea is central. Tracheo-bronchial tree is normal.

Heart

- Cardiac silhouette is normal.

Others

- Bilateral CP angles are clear.
- Both domes of diaphragm are normally placed.
- Bony thoracic cage is normal.

IMPRESSION

- Both para hilar shadow in calcification see.

RECOMMENDATION

Suggested clinical correlation

Dr. Kajal Agarwal

MD Radiology

Consultant Radiologist

Disclaimer

It is an online interpretation of medical imaging based on the available clinical data. Patient's identification in online reporting is not established, so this report cannot be utilized for any medico legal purpose/ certifications. All modern machines/procedures have their own limitations. If there is any clinical discrepancy, this investigation may be repeated or reassessed by other tests.

MRS PRITI MISHRA 33Y/F (DR SELF) 1



24 HOUR EMERGENCY

© AHL/D/0070

"KEEP THE REPORTS CAREFULLY AND BRING THEM ALONG DURING YOUR NEXT VISIT TO OUR HOSPITAL"



OUT PATIENT DEPARTMENT

ECHOCARDIOGRAPHY REPORT

Name: **MRS PRITI MISHRA**

Age: **33**

Sex: **Female**

Date: **11/09/2021**

2D & M-MODE MEASUREMENTS

LA Diam	3.2 cm
Ao Diam	2.7 cm
IVSd	1.2 cm
LVIDd	5.4 cm
LVPWd	1.1 cm
IVSs	1.4 cm
LVIDs	3.5 cm

2D & M-MODE CALCULATIONS

EDV(Teich)	138 ml
ESV(Teich)	51 ml
EF(Teich)	63 %
%FS	35 %
SV(Teich)	88 ml
LVd Mass	291.95 g
RWT	0.42

MITRAL VALVE

MV E Vel	0.97 m/s
MV DecT	169 ms
MV Dec Slope	5.7 m/s ²
MV A Vel	0.78 m/s
MV E/A Ratio	1.24

AORTIC VALVE

AV Vmax	1.39 m/s
AV maxPG	7.73 mmHg

TRICUSPID VALVE

PV Vmax	0.82 m/s
PV maxPG	2.71 mmHg

PULMONARY VALVE

COMMENTS:

- NORMAL SIZE OF CARDIAC CHAMBERS
- NO LVRWMA
- GOOD LV SYSTOLIC FUNCTION(EF-64%)
- NO MR, AR, TR
- IAS, IVS INTACT
- NO CLOT, PE
- IVC NORMAL

IMPRESSION:

- NORMAL SIZE OF CARDIAC CHAMBERS
- NO LVRWMA
- GOOD LV SYSTOLIC FUNCTION(EF-64%)

DR. S.H CHAVAN
(CONSULTANT CARDIOLOGIST)

TECH. SIG

