



**ECHOCARDIOGRAPHY AND COLOUR DOPPLER IMAGING**

**PATIENT NAME:- KAILASH KARDILE**

**AGE/SEX- 52 YRS/M**

**DATE :-10/04/2023**

**REF:- MEDIWHEEL INSURANCE**

Normal LV Size & Function

No regional wall motion abnormality.

**Normal LV & RV systolic function. LVEF-60%.**

No S/o Diastolic Dysfunction.

Left atrium is normal.

Normal RA and RV size and shape.

Normal RV systolic function.

PASP - 15 mmHg


No Pulmonary Hypertension.

IVC Collapsing with respiration. No Clot/Vegetation.

IVS and IAS are intact.

Normal pericardium. No effusion.

**IMPRESSION:- Good LV Function with LVEF- 60%**



**DR. RAKESH SHEWALE**  
M.D. (Medicine)  
D.M. (Cardiology)  
Consultant Cardiologist  
Regd. No. 2910041390

NAME: MR. KAILASH KARDILE	DATE: 08/04/2023
AGE/ SEX: 52 YEARS/ MALE	REFERRED BY: HEALTH CHECKUP

**ULTRASOUND ABDOMEN & PELVIS**

**Clinical profile- Health checkup**

**Liver:** Normal in size (13 cm), shape and shows normal echotexture. **Small hyperechoic lesion measuring 5 mm is seen in right lobe of liver likely benign haemangioma.** Intrahepatic biliary radicals are not dilated. Portal vein is normal in caliber.

**Gallbladder:** GB is partially distended. No evidence of any calculus seen. No wall thickening/pericholecystic fluid collection noted. CBD is normal in caliber.

**Pancreas:** Head & part of the body is visualized, appears normal in bulk & echotexture. Rest of the pancreas is obscured by bowel gases.

**Spleen:** Appears normal in size (9 cm), shape and echotexture. No calcification or mass is seen. Splenic vein is not dilated.

**Kidneys:** Right kidney – 10.4 x 4.1 cm. Left kidney – 10.6 x 5.2 cm.

Both kidneys are normal in size, shape, positions and echotexture. Bilateral corticomedullary differentiation appears normal. No hydronephrosis seen. No evidence of any calculus or mass lesion seen.

**Urinary Bladder:** is well distended. No evidence of calculus/ wall thickening noted.

**Prostate** is normal in size and echotexture.

**Free fluid:** No evidence of any free fluid in peritoneal cavity.

**IMPRESSION:**

- Small hyperechoic lesion in right lobe of liver likely benign haemangioma.

Clinical correlation is suggested.



**DR. TRIPTI PAREEK**  
**(DNB RADIODIAGNOSIS)**

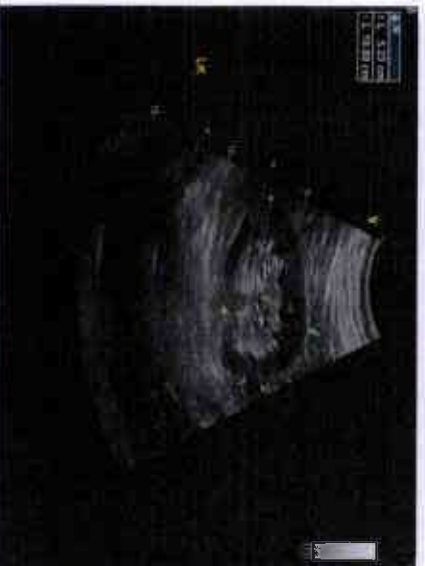
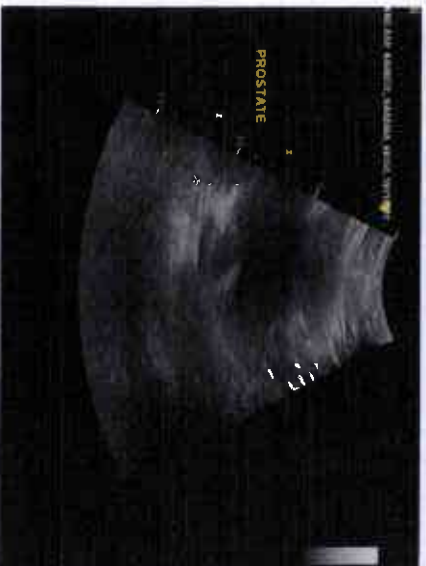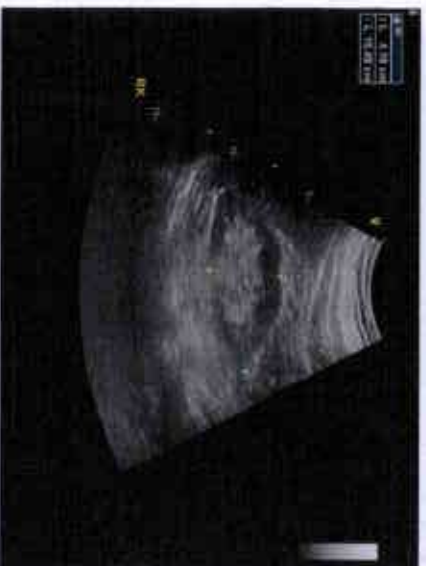
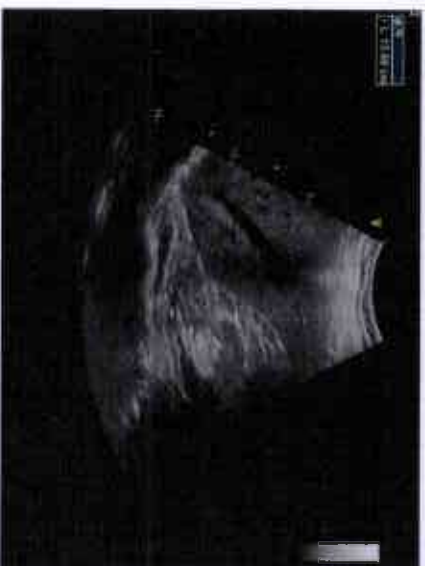
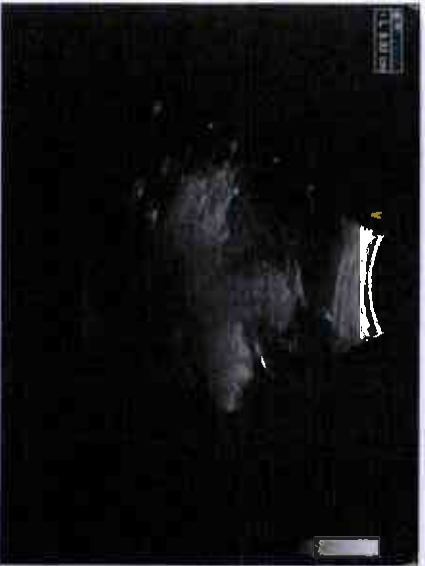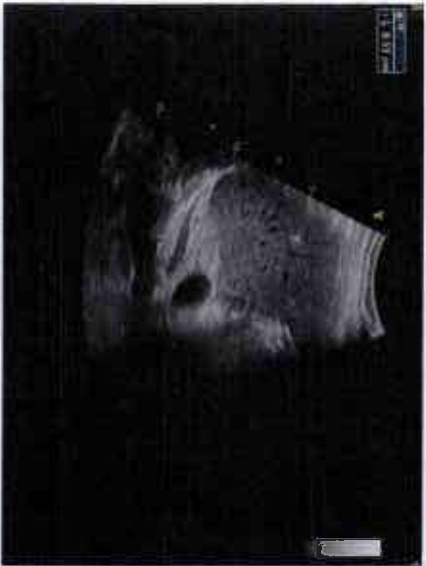
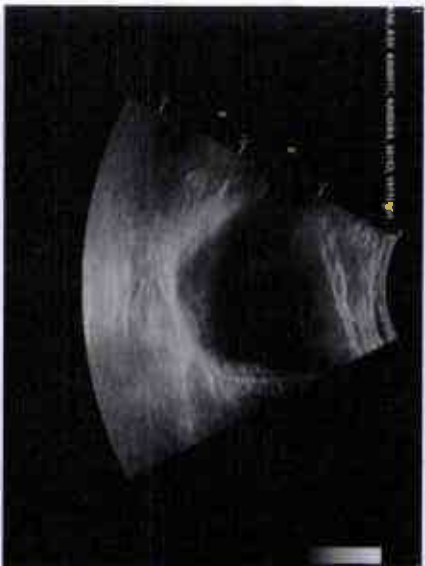
**MAGNUM MULTISPECIALITY HOSPITAL  
NASIK ROAD, NASHIK**

**Name KARDITE, KAILASH**

**Sex Male**

**Age 52**

**Date 08/04/2023**



NAME: MR. KAILASH KARDILE	DATE: 08/04/2023
AGE/ SEX: 52 YEARS / MALE	REFERRED BY: HEALTH CHECKUP

**XRAY CHEST PA (VIEW)**

Both the lungs are clear and do not show any obvious focal lesion.

Bilateral costo-phrenic and cardio-phrenic angles appear clear.

There is no evidence of pleural effusion or pneumothorax on either side.

Both the hilum appear normal.

Domes of diaphragm have normal contours and positions.

Visualised bones and soft tissues reveal no abnormality.

**CONCLUSION:**

No significant abnormality is seen.

Advise clinical correlation.

  
DR TRIPTI PAREEK  
(DNB RADIOLOGIST)

ID: 0

KAILAS KARDIL  
Male 52 Years  
Department: ER

08-04-2023 09:12:46 AM

HR : 68 bpm

P : 108 ms

PR : 132 ms

QRS : 80 ms

QT/QTc : 388/413 ms

P/QRS/T : 60/39/37 °

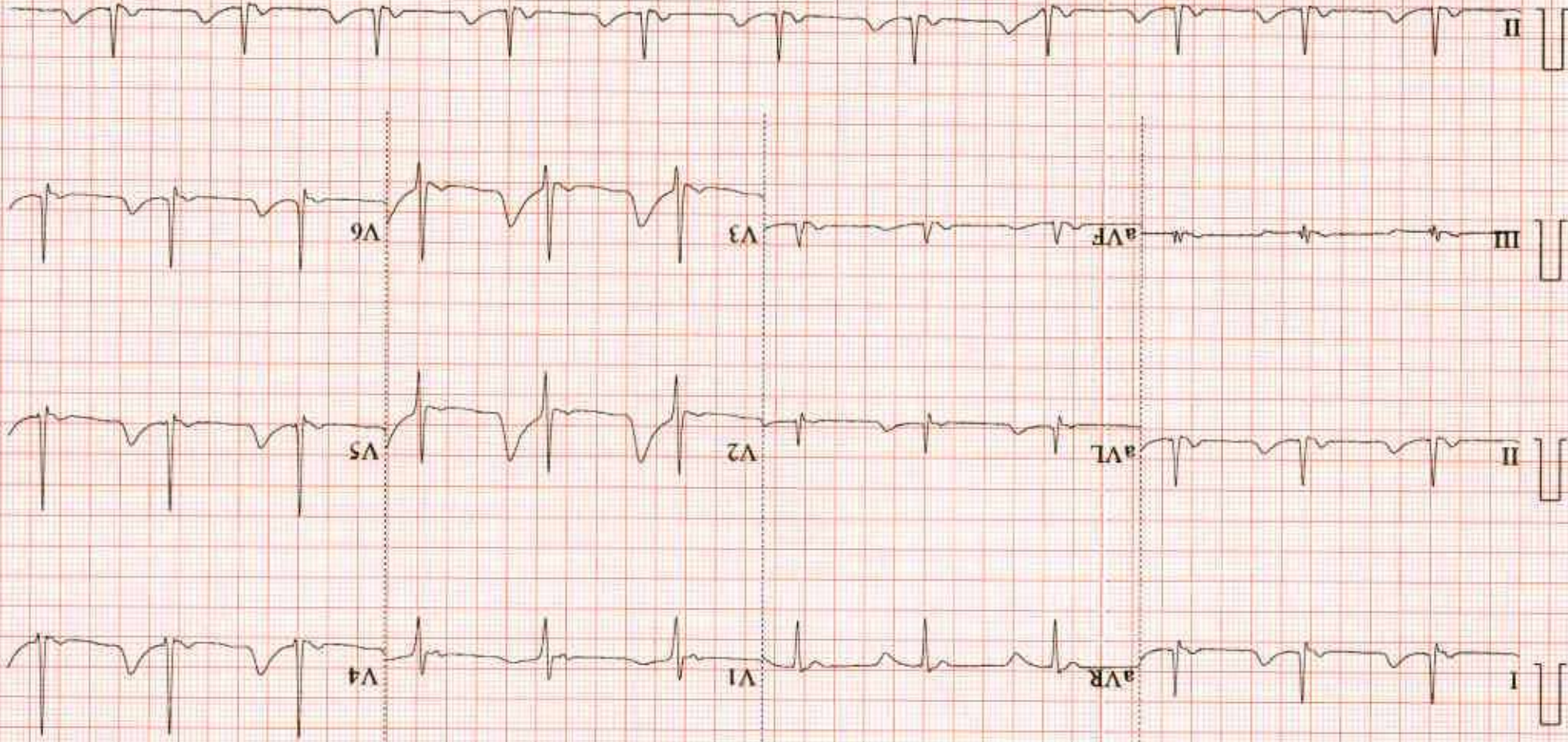
RV5/SV1 : 1.524/0.630 mV

Diagnosis Information:

Sinus rhythm

Normal ECG

Report Confirmed by:



0.05~35Hz AC50 25mm/s 10mm/mV 4\*2.5s+1r 68 SF 1200Express V2.21 Glasgow V28.60 MAGNUM MULTISPECIALIT