



Chopda Medicare & Research Centre Pvt. Ltd.

# MAGNUM HEART INSTITUTE



**Patient Name :** Mr. THAMKE DHANANJAY PRABHAKAR [MRN-230300127]  
**Age / Gender :** 30 Yr / Male  
**Address :** Laxminarayan Nagar Poosad , YAVATMAL, MAHARASHTRA  
**Req. Doctor:** DR. PATEL AMIT  
**Regn. ID:** OPD.22-23-18121

## HAEMATOLOGY

**Request Date :** 07-03-2023 11:55 AM  
**Collection Date :** 07-03-2023 12:10 PM[12239]  
**Acceptance Date :** 07-03-2023 12:11 PM | TAT: 02:55 [HH:MM]

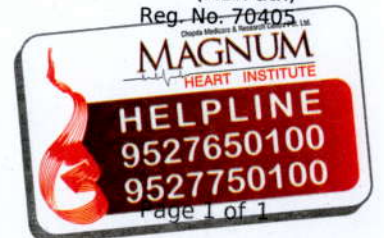**Reporting Date :** 07-03-2023 03:06 PM  
**Reporting Status :** Finalized

Investigations	Result	Biological Reference Range
<b>CBC * [ EDTA ]</b>		
HAEMOGLOBIN (Hb)	14.7 g/dl	M 12.50 - 17.50 g/dl
WBC TOTAL COUNT	6900 /cmm	4000.00 - 11000.00 /cmm
PLATELET COUNT	2.90 Lakh	1.50 - 4.50 Lakh
DIFFERENTIAL COUNT		
NEUTROPHILS	68 %	40.00 - 70.00 %
LYMPHOCYTES	24 %	20.00 - 45.00 %
EOSINOPHILS	03 %	1.00 - 6.00 %
MONOCYTES	05 %	2.00 - 10.00 %
BASOPHILS	00 %	0.00 - 1.00 %
<b>RBC</b>		
RBC COUNT	<b>5.59 mil/cmm *</b>	3.50 - 5.50 mil/cmm
PCV/HCT	46.3 %	37.00 - 54.00 %
MCV	83.0 fL	80.00 - 100.00 fL
MCH	26.2 pg	24.00 - 34.00 pg
MCHC	<b>31.7 g/dl *</b>	32.00 - 36.00 g/dl
RDW-CV	12.7 %	11.00 - 16.00 %

END OF REPORT.

Prepared By  
JAYSHREE RAVI ADATIYA

*Le*  
**Dr. Sudhir Sanklecha**  
Pathologist  
(MD Path)  
Reg. No. 70405



3/5, Patil Lane No.1, Laxmi Nagar, Near K.B.H. Vidyalaya, Canada Corner, Nashik-422005

Phone : 0253-2316200/01/02/03/04, Email : magnumheartinstitute@gmail.com

Mr. THAMKE DHANANJAY PRABHAKAR / MRN-230300127  
Regn No.: OPD.22-23-18121

www.magnumheartinstitute.com

Page 1 of 1



Chopda Medicare & Research Centre Pvt. Ltd.

# MAGNUM

## HEART INSTITUTE



**Patient Name :** Mr. THAMKE DHANANJAY PRABHAKAR [MRN-230300127]  
**Age / Gender :** 30 Yr / Male  
**Address :** Laxminarayan Nagar Poosad , YAVATMAL, MAHARASHTRA  
**Req. Doctor:** DR. PATEL AMIT  
**Regn. ID:** OPD.22-23-18121

### BIOCHEMISTRY

**Request Date :** 07-03-2023 11:55 AM  
**Collection Date :** 07-03-2023 12:10 PM [BI2958]  
**Acceptance Date :** 07-03-2023 12:11 PM | TAT: 02:47 [HH:MM]  
**Reporting Date :** 07-03-2023 02:58 PM  
**Reporting Status :** Finalized

Investigations	Result	Biological Reference Range
Blood Urea Nitrogen (BUN) *[ Serum ]	7.1 mg/dl	7.00 - 20.00 mg/dl
CREATININE *[ Serum ]	0.8 mg/dl	0.60 - 1.40
URIC ACID	7.5 mg/dl *	M 2.50 - 7.20
BLOOD SUGAR F & PP		
BLOOD SUGAR (PP)	97.34 mg/dl	70.00 - 140.00

END OF REPORT.

Prepared By  
JAYSHREE RAVI ADATIYA

**Dr. Sudhir Sanklecha**  
Pathologist  
(MD Path)  
Reg. No. 70405

3/5, Patil Lane No.1, Laxmi Nagar, Near K.B.H. Vidyalyaya, Canada Corner, Nashik-422005  
Phone : 0253-2316200/01/02/03/04, Email : magnumheartinstitute@gmail.com

Mr. THAMKE DHANANJAY PRABHAKAR / MRN-230300127  
Regn No.: OPD.22-23-18121

www.magnumheartinstitute.com



**Patient Name :** Mr. THAMKE DHANANJAY PRABHAKAR [MRN-230300127]  
**Age / Gender :** 30 Yr / Male  
**Address :** Laxminarayan Nagar Poosad , YAVATMAL, MAHARASHTRA  
**Req. Doctor:** DR. PATEL AMIT  
**Regn. ID:** OPD.22-23-18121

**BIOCHEMISTRY**

**Request Date :** 07-03-2023 11:55 AM  
**Collection Date :** 07-03-2023 12:10 PM[B12958]  
**Acceptance Date :** 07-03-2023 12:11 PM | **TAT:** 02:48 [HH:MM]  
**Reporting Date :** 07-03-2023 02:59 PM  
**Reporting Status :** Finalized

Investigations	Result	Biological Reference Range
<b>LIPID PROFILE</b>		
CHOLESTROL	174.19 mg/dl	< 200.00
TRIGLYCERIDES	<b>162.66 mg/dl *</b>	< 160.00
HDL CHOLESTROL	32.01 mg/dl	30.00 - 65.00
LDL CHOLESTROL	109.65 mg/dl	75.00 - 165.00 mg/dl
VLDL	32.53 mg/dl	6.00 - 38.00 mg/dl
CHO/HDL RATIO	5.44	3.00 - 5.50
LDL/HDL RATIO	3.43	2.50 - 4.00

END OF REPORT.

Prepared By  
JAYSHREE RAVI ADATIYA

*Le*  
**Dr. Sudhir Sanklecha**  
Pathologist  
(MD Path)  
Reg. No. 70405



Chopda Medicare & Research Centre Pvt. Ltd.

# MAGNUM

## HEART INSTITUTE



**Patient Name :** Mr. THAMKE DHANANJAY PRABHAKAR [MRN-230300127]  
**Age / Gender :** 30 Yr / Male  
**Address :** Laxminarayan Nagar Poosad , YAVATMAL, MAHARASHTRA  
**Req. Doctor:** DR. PATEL AMIT  
**Regn. ID:** OPD.22-23-18121

### BIOCHEMISTRY

**Request Date :** 07-03-2023 11:55 AM  
**Collection Date :** 07-03-2023 12:10 PM [BI2958]  
**Acceptance Date :** 07-03-2023 12:11 PM | **TAT:** 02:49 [HH:MM]  
**Reporting Date :** 07-03-2023 03:00 PM  
**Reporting Status :** Finalized

Investigations	Result	Biological Reference Range
<b>Liver Function Test *[ Serum ]</b>		
SGOT	23.2 IU/L	UPTO <= 40.00
SGPT	18.9 IU/L	UPTO <= 40.00
ALKP	68.7 U/L	40.00 - 130.00 (Age 18 Y - 100 Y)
Total Protein	7.1 g/dl	6.00 - 7.80
Albumin	4.6 g/dl	3.20 - 4.60
Globulin	2.5 g/dl	2.00 - 3.50 g/dl
A:G Ratio	1.84	
Total Bilirubin	0.7 mg/dl	0.20 - 1.20
Direct Bilirubin	0.3 mg/dl	0.00 - 0.40 mg/dl
Indirect Bilirubin	0.40 mg/dl	0.20 - 0.60 mg/dl

END OF REPORT.

Prepared By  
JAYSHREE RAVI ADATIYA

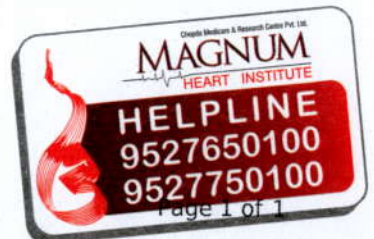**Dr. Sudhir Sanklecha**  
Pathologist  
(MD Path)  
Reg. No. 70405

3/5, Patil Lane No.1, Laxmi Nagar, Near K.B.H. Vidyalaya, Canada Corner, Nashik-422005

Phone : 0253-2316200/01/02/03/04, Email : magnumheartinstitute@gmail.com

Mr. THAMKE DHANANJAY PRABHAKAR / MRN-230300127  
Regn No.: OPD.22-23-18121

www.magnumheartinstitute.com



**Patient Name :** Mr. THAMKE DHANANJAY PRABHAKAR [MRN-230300127]  
**Age / Gender :** 30 Yr / Male  
**Address :** Laxminarayan Nagar Poosad , YAVATMAL, MAHARASHTRA  
**Req. Doctor:** DR. PATEL AMIT  
**Regn. ID:** OPD.22-23-18121

**HAEMATOLOGY**

**Request Date :** 07-03-2023 11:55 AM **Reporting Date :** 07-03-2023 03:01 PM  
**Collection Date :** 07-03-2023 12:10 PM[12239] **Reporting Status :** Finalized  
**Acceptance Date :** 07-03-2023 12:11 PM | **TAT:** 02:50 [HH:MM]

Investigations	Result	Biological Reference Range
<b>ESR</b>	06 mm/h	0.00 - 15.00 mm/h
<b>HBA1C</b>		
HBA1C	5.3 %	
METHOD	HPLC METHOD	
Performed On: Biorad D 10		
<u>Reference Range As Per ADA</u>		
Normal : Below 5.7%	<u>Guidance For Known Diabetes</u>	
Pre-Diabetes : 5.7% - 6.4%	Good Control : Below 6.5%	
Diabetes : >=6.5%	Fair Control : 6.5% - 7%	
	Unsatisfactory Control : 7.0% - 8%	
	Poor Control : >8%	
<b>BLOOD GROUP *[ Whole blood ]</b>	'O' POSITIVE .	

END OF REPORT.

Prepared By  
 JAYSHREE RAVI ADATIYA



**Dr. Sudhir Sanklecha**  
 Pathologist  
 (MD Path)  
 Reg. No. 70405



Chopda Medicare & Research Centre Pvt. Ltd.

# MAGNUM

## HEART INSTITUTE



**Patient Name :** Mr. THAMKE DHANANJAY PRABHAKAR [MRN-230300127]  
**Age / Gender :** 30 Yr / Male  
**Address :** Laxminarayan Nagar Poosad , YAVATMAL, MAHARASHTRA  
**Req. Doctor:** DR. PATEL AMIT  
**Regn. ID:** OPD.22-23-18121

### URINE

**Request Date :** 07-03-2023 11:55 AM  
**Collection Date :** 07-03-2023 12:10 PM[UR944]  
**Acceptance Date :** 07-03-2023 12:11 PM | **TAT:** 02:54 [HH:MM]

**Reporting Date :** 07-03-2023 03:05 PM  
**Reporting Status :** Finalized

Investigations	Result	Biological Reference Range
<b>URINE ROUTINE</b>		
PHYSICAL EXAMINATION		
VOLUME	20ml	
COLOUR	PALE YELLOW	
APPEARANCE	CLEAR	
pH	ACIDIC	
CHEMICAL EXAMINATION		
ALBUMIN	ABSENT	
SUGAR	ABSENT	
KETONES	ABSENT	
BILE SALTS	ABSENT	
BILE PIGMENT	ABSENT	
MICROSCOPIC EXAMINATION		
EPITHELIAL CELLS	1 - 2/hpf	
PUS CELLS	1 - 2/hpf	
RBC	ABSENT	
CASTS	ABSENT	
CRYSTALS	ABSENT	
BACILLI	ABSENT	
OTHERS	ABSENT	

END OF REPORT.

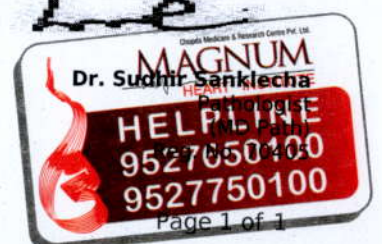Prepared By  
JAYSHREE RAVI ADATIYA

3/5, Patil Lane No.1, Laxmi Nagar, Near K.B.H. Vidyalaya, Canada Corner, Nashik-422005

Phone : 0253-2316200/01/02/03/04, Email : magnumheartinstitute@gmail.com

Mr. THAMKE DHANANJAY PRABHAKAR / MRN-230300127  
Regn No.: OPD.22-23-18121

www.magnumheartinstitute.com





Chopda Medicare & Research Centre Pvt. Ltd.

**MAGNUM**  
HEART INSTITUTE



**Patient Name:** Mrs. KATEKAR RAKSHA JANARDHAN / MRN-230300129

**Age / Gender:** 28 Yr /Female

**Address:** Durga Chouk Malegaon Dist Vashim, AKOLA (VIDARBHA), MAHARASHTRA

**Req. Doctor:** DR. PATEL AMIT

**Regn. Number:** OPD.22-23-18123

Request Date : 07-03-2023 12:05 PM

Reporting Date : 07-03-2023 02:33 PM

Report Status : Finalized

**RADIOGRAPH OF CHEST (PA)**

No obvious pleuro-parenchymal lesion in rest of the visualised lung fields.

Both apices and costophrenic angles are clear.

Tracheal bifurcation appears normal. No obvious carinal splaying.

Both hila are normal. No obvious hilar lymphadenopathy.

Cardiac configuration appears normal. Diaphragmatic silhouette also appears normal.

Bony thorax does not reveal any obvious abnormality.

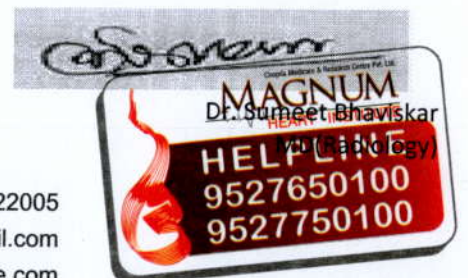- Heart shadow normal.

**IMPRESSION:**

**CHEST RADIOGRAPH DOES NOT REVEAL ANY SIGNIFICANT ABNORMALITY.**

END OF REPORT

Prepared by  
SONALI PRAMOD PINGALE



3/5, Patil Lane No.1, Laxmi Nagar, Near K.B.H. Vidyalaya, Canada Corner, Nashik-422005

Phone : 0253-2316200/01/02/03/04, Email : magnumheartinstitute@gmail.com

www.magnumheartinstitute.com



Chopda Medicare & Research Centre Pvt. Ltd's

# MAGNUM

HEART INSTITUTE

ISO 9001 : 2008 CERTIFIED HOSPITAL

## ECHOCARDIOGRAPHY AND COLOUR DOPPLER IMAGING

Patient Name: Mrs. KATEKAR RAKSHA JANARDHAN / MRN-230300129

Age / Gender: 28 Yr /Female

Address: Durga Chouk Malegaon Dist Vashim, AKOLA (VIDARBHA), MAHARASHTRA

Req. Doctor: DR. PATEL AMIT

Regn. Number: OPD.22-23-18123

### REGIONAL ANALYSIS OF THE HEART

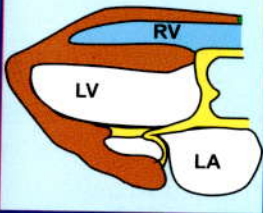
03-2023 12:05 PM

Reporting Date : 07-03-2023 04:00 PM

Report Status : Finalized

### 2D ECHO-CARDIOGRAPHY WITH PRINT

#### PARASTERNAL LONG AXIS



#### OBSERVATION:

**NORMAL SIZED LV WITH GOOD LV FUNCTION EF=60%**

SITUS SOLITUS

LEFT VENTRICLE - NORMAL SIZED

NO REGIONAL WALL MOTION ABNORMALITY

NO S/O LV HYPERTROPHY IVS = 7mm ,PW =7 mm PRESENT-

NO S/O DIASTOLIC DYSFUNCTION.

OVERALL GOOD LV FUNCTION EF= 60 %

LEFT ATRIUM -NORMAL SIZED, NO CLOT .

RIGHT ATRIUM /VENTRICLE -NORMAL SIZED

OVERALL GOOD RV FUNCTION.

ALL VALVES - NORMAL

NO S/O PULMONARY HYPERTENSION PRESENT

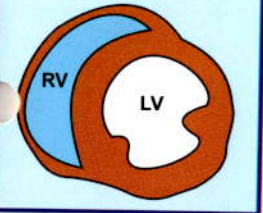
PULMONARY ARTERY SYSTOLIC PRESSURE = 26mm Hg

NO S/O PERICARDIAL EFFUSION NOTED

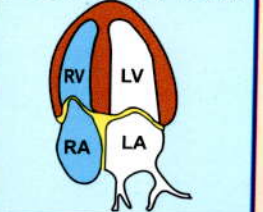
NO S/O TAMPONADE PRESENT .NO S/O CONSTRICTION.

IVC 12mm COLLAPSING WITH RESPIRATION

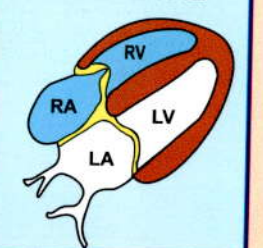
#### PARASTERNAL SHORT AXIS



#### APICAL FOUR CHAMBER



#### SUBCOSTAL



**Dr. MANOJ B. CHOPDA**

M.D. (Medicine) D.M. (Cardiology)

**INTERVENTIONAL CARDIOLOGIST**





Chopda Medicare & Research Centre Pvt. Ltd.

**MAGNUM**  
HEART INSTITUTE



Patient Name: Mrs. KATEKAR RAKSHA JANARDHAN / MRN-230300129

Age / Gender: 28 Yr /Female

Address: Durga Chouk Malegaon Dist Vashim, AKOLA (VIDARBHA), MAHARASHTRA

Req. Doctor: DR. PATEL AMIT

Regn. Number: OPD.22-23-18123

Request Date : 07-03-2023 12:05 PM

Reporting Date : 07-03-2023 02:34 PM

Report Status : Finalized

### USG ROUTINE ABDOMEN & PELVIS

#### OBSERVATION:

LIVER : SHOWS NORMAL IN SIZE, SHAPE, POSITION & ECHOTEXTURE.

NO FOCAL LESION.

NO INTRINSIC MASS LESION SEEN IN LIVER PARENCHYMA.

PV AND CBD : NORMAL IN IVC & AORTA

GALL BLADDER IS WELL DISTENDED & THERE IS NO STONE SEEN.

SPLEEN AND PANCREAS SHOWS NORMAL ECHOTEXTURE.

BOTH KIDNEYS SHOWS NORMAL SIZE, SHAPE, POSITION & ECHOTEXTURE.

RIGHT KIDNEY MEASURES – 9.3 CM X 3.9 CM

LEFT KIDNEY MEASURES – 9.4 CM X 3.6 CM

URINARY BLADDER – NORMAL

NO LYMPHADENOPATHY

NO PLEURAL EFFUSION SEEN

UTERUS – 6.0 CM X 3.5 CM X 3.9 CM.

BOTH OVARIES ARE NORMAL

#### IMPRESSION:

IMPRESSION : NORMAL ABDOMINAL STUDY

Dr. Manoj Choudhari  
Radiologist

3/5, Patil Lane No.1, Laxmi Nagar, Near K.B.H. Vidyalaya, Canada Corner, Nashik-422005

Phone : 0253-2316200/01/02/03/04, Email : magnumheartinstitute@gmail.com

www.magnumheartinstitute.com



# MAGNUM HEART INSTITUTE nashik 12-Lead ECG Report

KATEKAR RAKSHA

Female

28Years

ID:230300129

Request Department:

OutpatientID:

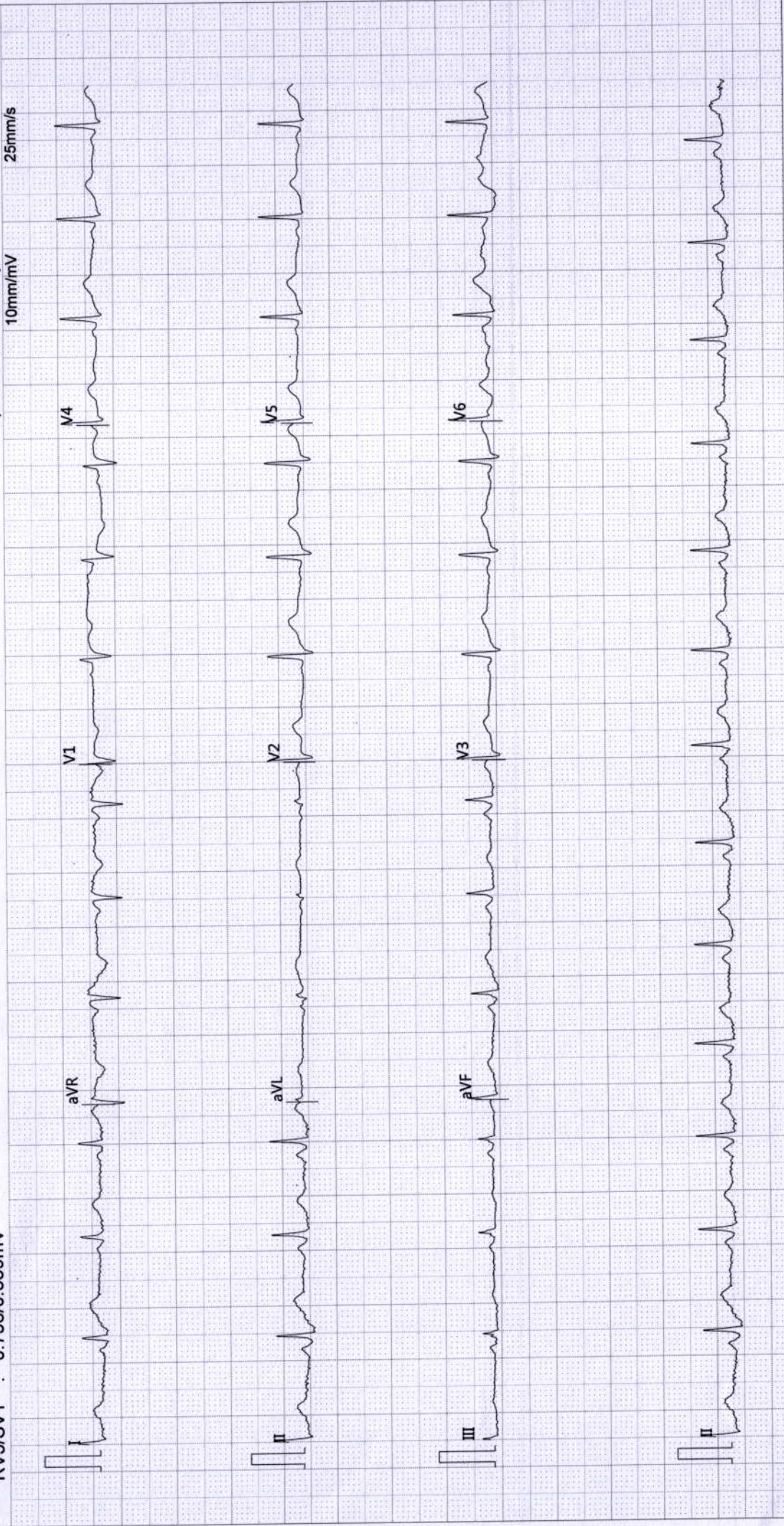
Room No.:

### Diagnostic Information:

1. Sinus Rhythm
2. Short PR Interval
3. Low Voltage(Chest Leads)

HR : 81bpm  
P : 95ms  
PR : 117ms  
QRS : 83ms  
QT/QTc : 373/435ms  
P/QRS/T : 63/50/40deg.  
RV5/SV1 : 0.758/0.359mV

Report Confirmed By:



R

