

Sonalij Raj

Routine eye check-up


O/E Vn 6/6p unaided, NB
Colour vision - WTM

Ant seg - WTM

Fundus - NAD

Adv

- Annual eye check-up



10/9/22 -
Consultant
Department of Ophthalmology
SIGNATURE HOSPITAL
Gurugram

(This is only professional opinion and not the diagnosis. Please correlate clinically)

Sector 37-D, BPTP, Dwarka Express Way, Gurugram, Hry.,

Ph.: 0124-6034444, 8526000000, E-mail : signaturehospital@gmail.com, Web.: www.thesignaturehealthcare.com
PARK GROUP OF HOSPITAL : ★ West Delhi ★ South Delhi ★ Gurugram ★ Faridabad ★ Panipat ★ Karnal

The Signature

ADVANCED SUPER SPECIALITY
HOSPITAL



Patient Name : Mr. SONALI RAJ
 Age / Gender : 30 Years 0 Months 0Days / Male
 Referred By : Dr. CMO
 Req.No : 22223017
 Sample ID : 2234388
 Patient Type : OPD
 Bed No :

UHID : 22324
 IPNO :
 Registered : 10/09/2022/ 9.02 AM
 Sample Collection Dt & Tm : 10/09/2022/ 11.42 AM
 Sample Receiving Dt & Tm : 10/09/2022/ 11.45 AM
 Report Released on : 10/09/2022/ 1.43 PM

HEMATOLOGY

Complete Blood Count -CBC(Hb\TLC\PCV\RBC\Platelet)

TEST NAME	RESULT	UNITS	REFERENCE INTERVAL	BIOLOGICAL SPECIMEN TYPE
TEST METHOD				WHOLE BLOOD
Hemoglobin (Hb) (Colorimetry)	11.0	gm/dl	13.5 - 18.0	
TLC (Electrical Impedence)	4400	cell/cumm	4500 - 11000	EDTA WHOLE
DIFFERENTIAL COUNT				
Neutrophils (Flow Cytometry)	66	%	40 - 75	EDTA WHOLE
Lymphocytes (Flow Cytometry)	27	%	20 - 45	EDTA WHOLE
Monocytes (Flow Cytometry)	05	%	1 - 10	EDTA WHOLE
Eosinophil (Flow Cytometry)	02	%	1 - 6	EDTA WHOLE
Basophil	00	%	0 - 1	
RBC (Electrical Impedence)	4.7	millions/cumm	4.7 - 6.1	EDTA WHOLE

**** End of Report ****

This is Provisional Report

Lab Technician

Dr.NishaTiwari
(MD.Microbiology)


 Dr. Nisha Gupta
 MBBS,MD(Pathology)
 (Consultant Pathologist)

Dr. Shreya Pradhan
 MBBS,MD(Microbiology)
 (Consultant Microbiologist)

Page 1 of 2

(This is only professional opinion and not the diagnosis. Please correlate clinically)

Sector 37-D, BPTP, Dwarka Express Way, Gurugram, Hry.,

Ph.: 0124-6034444, 8526000000, E-mail : signaturehospital@gmail.com, Web.: www.thesignaturehealthcar

PARK GROUP OF HOSPITAL : ★ West Delhi ★ South Delhi ★ Gurugram ★ Faridabad ★ Panipat ★

Patient Name : Mr. SONALI RAJ
 Age / Gender : 30 Years 0 Months 0Days / Male
 Referred By : Dr. CMO
 Req.No : 22223017
 Sample ID : 2234388
 Patient Type : OPD
 Bed No :

UHID : 22324
 IPNO :
 Registered : 10/09/2022/ 9.02 AM
 Sample Collection Dt & Tm : 10/09/2022/ 11.42 AM
 Sample Receiving Dt & Tm : 10/09/2022/ 11:45 AM
 Report Released on : 10/09/2022/ 1.43 PM

HEMATOLOGY

PCV (Electrical Impedance Calculation)	33.2	%	40 - 50	EDTA WHOLE
MCV (Electrical Impedance Calculation)	74.5	fl	76 - 96	EDTA WHOLE
MCH (Electrical Impedance Calculation)	23.3	pg	27 - 34	EDTA WHOLE
MCHC (Electrical Impedance Calculation)	33.1	gm/dl	30 - 36	EDTA WHOLE
RDW	14.5	%	11 - 16	
PLATELETE COUNT (Electrical Impedance)	133	1000/microLit	150 - 450	EDTA WHOLE

-**** End of Report ****-

This is Provisional Report

Lab Technician

Dr.NishaTiwari
(MD.Microbiology)


 Dr. Neha Gupta
 MBBS,MD(Pathology)
 (Consultant Pathologist)

Dr. Shreya Pradhan
MBBS,MD(Microbiology)
(Consultant Microbiologist)

Page 2 of 2

(This is only professional opinion and not the diagnosis. Please correlate clinically)

Sector 37-D, BPTP, Dwarka Express Way, Gurugram, Hry.,

Ph.: 0124-6034444, 8526000000, E-mail : signaturehospital@gmail.com, Web.: www.thesignaturehealthcare.co

PARK GROUP OF HOSPITAL : ★ West Delhi ★ South Delhi ★ Gurugram ★ Faridabad ★ Panipat ★ Kar

Patient Name : Mr. SONALI RAJ	UHID : 22324
Age / Gender : 30 Years 0 Months 0Days / Male	IPNO :
Referred By : Dr. CMO	Registered : 10/09/2022/ 9.02 AM
Req.No : 22223017	Sample Collection Dt & Tm : 10/09/2022/ 11.42 AM
Sample ID : 2234388	Sample Receiving Dt & Tm : 10/09/2022/ 11:45 AM
Patient Type : OPD	Report Released on : 10/09/2022/ 1.43 PM
Bed No :	

BIOCHEMISTRY

Blood Sugar Fasting

TEST NAME	RESULT	UNITS	REFERENCE INTERVAL	BIOLOGICAL SPECIMEN TYPE
TEST METHOD				
BLOOD SUGAR FASTING (God- Trinders)	78	mg/dl	75 - 115	Flouride Plasma

Increased In:

- Diabetes Mellitus
- Stress (e.g, emotion, burns, shock, anesthesia)
- Acute Pancreatitis
- Chronic Pancreatitis
- Wernicke encephalopathy (Vitamin B1 deficiency)
- Effect of drugs (e.g. corticosterogens, alcohol, phenytoin, thiazides)

Decreased in :

- Pancreatitis disorders
- Extrapancreatic tumors
- Endocrine disorders
- Malnutrition
- Hypothalamic lesions
- Alcoholism
- Endocrine Disorders

-**** End of Report ****-

This is Provisional Report

Lab Technician
Dr.NishaTiwari
(MD.Microbiology)


 Dr. Nisha Gupta
 MBBS,MD(Pathology)
 (Consultant Pathologist)

Dr. Shreya Pradhan
MBBS,MD(Microbiology)
(Consultant Microbiologist)

(This is only professional opinion and not the diagnosis. Please correlate clinically)

Sector 37-D, BTPP, Dwarka Express Way, Gurugram, Hry.,

Ph.: 0124-6034444, 8526000000, E-mail : signaturehospital@gmail.com, Web.: www.thesignaturehealthcare.c

PARK GROUP OF HOSPITAL : ★ West Delhi ★ South Delhi ★ Gurugram ★ Faridabad ★ Panipat ★ Ka

Patient Name : Mr. SONALI RAJ	UHID : 22324
Age / Gender : 30 Years 0 Months 0 Days / Male	IPNO :
Referred By : Dr. CMO	Registered : 10/09/2022/ 9.02 AM
Req.No : 22223017	Sample Collection Dt & Tm : 10/09/2022/ 11.42 AM
Sample ID : 2234388	Sample Receiving Dt & Tm : 10/09/2022/ 11.45 AM
Patient Type : OPD	Report Released on : 10/09/2022/ 1.43 PM
Bed No :	

BIOCHEMISTRY

Lipid Profile


TEST NAME	RESULT	UNITS	REFERENCE INTERVAL	BIOLOGICAL SPECIMEN TYPE
TEST METHOD				
LIPID PROFILE				
CHOLESTROL (CHOD-TRINDER)	142	mg/dl	00 - 200	SERUM
TRIGLYCERIDES (GPO-Trinders)	63	mg/dl	35 - 170	SERUM
HDL- CHOL (Direct Method/ Enzymatic Colorometric)	40	mg/dl	40 - 60	SERUM
VLDL-CHOL CALCULATED	12.6	mg/dl	10 - 40	
LDL-CHOLESTROL	89.4	mg/dl	0 - 130	
LDL/HDL RATIO	2.24		0-3	
CHOLESTROL/HDL RATIO	3.55			

-**** End of Report ****-

This is Provisional Report

Lab Technician

Dr.NishaTiwari
(MD.Microbiology)


 Dr. Neha Gupta
 MBBS,MD(Pathology)
 (Consultant Pathologist)

Dr. Shreya Pradhan
MBBS,MD(Microbiology)
(Consultant Microbiologist)

Page 1 of 2

(This is only professional opinion and not the diagnosis. Please correlate clinically)

Sector 37-D, BPTP, Dwarka Express Way, Gurugram, Hry.,

Ph.: 0124-6034444, 8526000000, E-mail : signaturehospital@gmail.com, Web.: www.thesignaturehealthcare.com
PARK GROUP OF HOSPITAL : ★ West Delhi ★ South Delhi ★ Gurugram ★ Faridabad ★ Panipat ★ Karnal

Patient Name : Mr. SONALI RAJ	UHID : 22324
Age / Gender : 30 Years 0 Months 0Days / Male	IPNO :
Referred By : Dr. CMO	Registered : 10/09/2022/ 9.02 AM
Req.No : 22223017	Sample Collection Dt & Tm : 10/09/2022/ 11.42 AM
Sample ID : 2234388	Sample Receiving Dt & Tm : 10/09/2022/ 11:45 AM
Patient Type : OPD	Report Released on : 10/09/2022/ 1.43 PM
Bed No :	

BIOCHEMISTRY

Renal Profile

TEST NAME	RESULT	UNITS	REFERENCE INTERVAL	BIOLOGICAL SPECIMEN TYPE
TEST METHOD				
BLOOD UREA (Urease UV/GLDH)	22	mg/dl	13 - 45	SERUM
SERUM CREATININE (Jaffe Rate)	0.9	mg/dl	0.6 - 1.4	SERUM
URIC ACID (Enzymatic/Uricase)	4.1	mg/dl	3.6 - 7.2	SERUM
<u>ELECTROLYTES</u>				
SODIUM (ISE-Indirect)	145	mmol/L	132 - 150	SERUM
POTASSIUM (ISE-Indirect)	4.8	mmol/L	3.5 - 5.5	SERUM

-**** End of Report ****-

This is Provisional Report

Lab Technician

Dr.NishaTiwari
(MD.Microbiology)


The Signature
HOSPITAL
Dr. Nisha Gupta
 MBBS,MD(Pathology)
 (Consultant Pathologist)

Dr. Shreya Pradhan
MBBS,MD(Microbiology)
(Consultant Microbiologist)

Page 1 of 2

(This is only professional opinion and not the diagnosis. Please correlate clinically)

Sector 37-D, BPTP, Dwarka Express Way, Gurugram, Hry.,

Ph.: 0124-6034444, 8526000000, E-mail : signaturehospital@gmail.com, Web.: www.thesignaturehealthcare.com

PARK GROUP OF HOSPITAL : ★ West Delhi ★ South Delhi ★ Gurugram ★ Faridabad ★ Panipat ★ Karnal

Patient Name : Mr. SONALI RAJ	UHID : 22324
Age / Gender : 30 Years 0 Months 0Days / Male	IPNO :
Referred By : Dr. CMO	Registered : 10/09/2022/ 9.02 AM
Req.No : 22223017	Sample Collection Dt & Tm : 10/09/2022/ 11.42 AM
Sample ID : 2234388	Sample Receiving Dt & Tm : 10/09/2022/ 11:45 AM
Patient Type : OPD	Report Released on : 10/09/2022/ 1.43 PM
Bed No :	

BIOCHEMISTRY

Liver Function Test Profile

TEST NAME	RESULT	UNITS	REFERENCE INTERVAL	BIOLOGICAL SPECIMEN TYPE
TEST METHOD				
<u>BILIRUBIN TOTAL AND DIRECT</u>				
BILIRUBIN TOTAL (Diazonium Salt)	0.4	mg/dl	0.1 - 1.2	SERUM
BILIRUBIN DIRECT (Diazonium Salt)	0.2	mg/dl	00 - 0.3	SERUM
BILIRUBIN INDIRECT (CALCULATED)	0.2	md/dl	0 - 0.9	
SGOT/AST (UV-KINETIC)	20	U/l	0 - 45	SERUM
SGPT/ALT (UV-KINETIC)	12	U/l	0 - 45	SERUM
ALKALINE PHOSPHATASE (ALP) (Kinetic)	161	U/l	41 - 137	SERUM

-**** End of Report ****-

This is Provisional Report

Lab Technician

Dr.NishaTiwari
(MD.Microbiology)


 Dr. Neha Gupta
 MBBS,MD(Pathology)
 (Consultant Pathologist)

Dr. Shreya Pradhan
 MBBS,MD(Microbiology)
 (Consultant Microbiologist)

Page 1 of 2

(This is only professional opinion and not the diagnosis. Please correlate clinically)

Sector 37-D, BPTP, Dwarka Express Way, Gurugram, Hry.,

Ph.: 0124-6034444, 8526000000, E-mail : signaturehospital@gmail.com, Web.: www.thesignaturehealthcare.com
PARK GROUP OF HOSPITAL : ★ West Delhi ★ South Delhi ★ Gurugram ★ Faridabad ★ Panipat ★ Karnal

Patient Name : Mr. SONALI RAJ	UHID : 22324
Age / Gender : 30 Years 0 Months 0Days / Male	IPNO :
Referred By : Dr. CMO	Registered : 10/09/2022/ 9.02 AM
Req.No : 22223017	Sample Collection Dt & Tm : 10/09/2022/ 11.42 AM
Sample ID : 2234388	Sample Receiving Dt & Tm : 10/09/2022/ 11:45 AM
Patient Type : OPD	Report Released on : 10/09/2022/ 1.43 PM
Bed No :	

BIOCHEMISTRY

PROTEINS

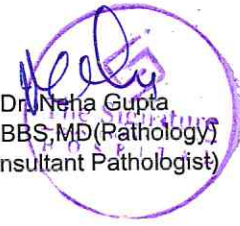
TOTAL PROTEIN (Biuret)	6.6	g/dl	6.0 - 8.3	SERUM
ALBUMIN (BCG- DYE)	4.2	g/dl	3.2 - 5.0	SERUM
GLOBULIN Calculated	2.4	gm/dl	1.5 - 3.6	
A/G RATIO Calculated	1.75		0.9 - 2.0	

-**** End of Report ****-

This is Provisional Report

Lab Technician

Dr.NishaTiwari
(MD.Microbiology)


 Dr. Neha Gupta
 MBBS,MD(Pathology)
 (Consultant Pathologist)

Dr. Shreya Pradhan
MBBS,MD(Microbiology)
(Consultant Microbiologist)

(This is only professional opinion and not the diagnosis. Please correlate clinically)

Sector 37-D, BPTP, Dwarka Express Way, Gurugram, Hry.,

Ph.: 0124-6034444, 8526000000, E-mail : signaturehospital@gmail.com, Web.: www.thesignaturehealthcare.co

PARK GROUP OF HOSPITAL : ★ West Delhi ★ South Delhi ★ Gurugram ★ Faridabad ★ Panipat ★ Karn

Patient Name : Mr. SONALI RAJ
Age / Gender : 30 Years 0 Months 0Days / Male
Referred By : Dr. CMO
Req.No : 22223017
Sample ID : 2234388
Patient Type : OPD
Bed No :
UHID : 22324
IPNO :
Registered : 10/09/2022/ 9.02 AM
Sample Collection Dt & Tm : 10/09/2022/ 11.42 AM
Sample Receiving Dt & Tm : 10/09/2022/ 11:45 AM
Report Released on : 10/09/2022/ 6.03 PM

HEMATOLOGY

Blood Group And Rh Factor


TEST NAME	RESULT	UNITS	BIOLOGICAL REFERENCE INTERVAL	SPECIMEN TYPE
TEST METHOD				
BLOOD GROUP(ABORh)	"B" POSITIVE			

-**** End of Report ****

This is Provisional Report

Lab Technician

Dr.NishaTiwari
(MD.Microbiology)


Dr. Nisha Gupta
MBBS,MD(Pathology)
(Consultant Pathologist)

Dr. Shreya Pradhan
MBBS,MD(Microbiology)
(Consultant Microbiologist)

Page 1 of 1

(This is only professional opinion and not the diagnosis. Please correlate clinically)

Sector 37-D, BPTP, Dwarka Express Way, Gurugram, Hry.,

Ph.: 0124-6034444, 8526000000, E-mail : signaturehospital@gmail.com, Web.: www.thesignaturehealthcare.co

PARK GROUP OF HOSPITAL : ★ West Delhi ★ South Delhi ★ Gurugram ★ Faridabad ★ Panipat ★ Karr

Patient Name : Mr. SONALI RAJ	UHID : 22324
Age / Gender : 30 Years 0 Months 0Days / Male	IPNO :
Referred By : Dr. CMO	Registered : 10/09/2022/ 9.02 AM
Req.No : 22223017	Sample Collection Dt & Tm : 10/09/2022/ 11.42 AM
Sample ID : 2234388	Sample Receiving Dt & Tm : 10/09/2022/ 11:45 AM
Patient Type : OPD	Report Released on : 10/09/2022/ 6.04 PM
Bed No :	

CLINICAL PATHOLOGY

Urine Routine And Microscopy.

TEST NAME	RESULT	UNITS	REFERENCE INTERVAL	BIOLOGICAL SPECIMEN TYPE
TEST METHOD				
QUANTITY	30 ml			
COLOUR	PALE YELLOW			
TURBIDITY	S.TURBID			
SPECIFIC GRAVITY (Bromthymol Blue)	1.020		1.003-1.030	Urine
PH (Chromatography)	6.0		4.7-7.0	Urine

-**** End of Report ****-

This is Provisional Report

Lab Technician

Dr.NishaTiwari
(MD.Microbiology)


 Dr. Neha Gupta
 MBBS,MD(Pathology)
 (Consultant Pathologist)

Dr. Shreya Pradhan
MBBS,MD(Microbiology)
(Consultant Microbiologist)

(This is only professional opinion and not the diagnosis. Please correlate clinically)

Sector 37-D, BPTP, Dwarka Express Way, Gurugram, Hry.,

Ph.: 0124-6034444, 8526000000, E-mail : signaturehospital@gmail.com, Web.: www.thesignaturehealthcare.com

PARK GROUP OF HOSPITAL : ★ West Delhi ★ South Delhi ★ Gurugram ★ Faridabad ★ Panipat ★ Karnal

Patient Name : Mr. SONALI RAJ	UHID : 22324
Age / Gender : 30 Years 0 Months 0Days / Male	IPNO :
Referred By : Dr. CMO	Registered : 10/09/2022/ 9.02 AM
Req.No : 22223017	Sample Collection Dt & Tm : 10/09/2022/ 11.42 AM
Sample ID : 2234388	Sample Receiving Dt & Tm : 10/09/2022/ 11:45 AM
Patient Type : OPD	Report Released on : 10/09/2022/ 6.04 PM
Bed No :	

CLINICAL PATHOLOGY

MICROSCOPIC EXAMINATION - URINE

PUS CELLS (Microscopic)	2-4	/HPF	0 - 3	Urine
RBC- Urine (Per Oxidase Reaction)	1-2	/HPF	NIL	Urine
EPITHELIAL CELLS	15-20	/HPF	0 - 5	
CAST	NIL		NIL	
CRYSTALS	NIL		NIL	
BACTERIA	NIL			
OTHERS	NIL			

COMMENTS: Actual numerical values for WBCs, RBCs and Epithelial cells are not defined and must be correlated clinically.

Test Methods: Reagent strip analysis and urine sediment microscopy.
 Reagent strip / chemical analysis are based on: pH-Double Indicator principle; Specific gravity ion exchange method; Glucose Glucose oxidase-peroxidase/Benedicts; Protein Acid-base indicator/Sulfosalicylic acid; Urobilinogen Coupling reaction/Ehrlichsreaction, Bilirubin Coupling reaction, Ketones Nitroprusside method/Rotheras test.

-**** End of Report ****-

This is Provisional Report

Lab Technician

Dr.NishaTiwari
(MD.Microbiology)


 Dr. Neha Gupta
 MBBS,MD(Pathology)
 (Consultant Pathologist)

Dr. Shreya Pradhan
 MBBS,MD(Microbiology)
 (Consultant Microbiologist)

Page 3 of 3

(This is only professional opinion and not the diagnosis. Please correlate clinically)

Sector 37-D, BPTP, Dwarka Express Way, Gurugram, Hry.,

Ph.: 0124-6034444, 8526000000, E-mail : signaturehospital@gmail.com, Web.: www.thesignaturehealthcare.com

PARK GROUP OF HOSPITAL : ★ West Delhi ★ South Delhi ★ Gurugram ★ Faridabad ★ Panipat ★ Karnal


The Signature
ADVANCED SUPER SPECIALITY
H O S P I T A L



PATIENT NAME	: Mr SONALI RAJ	MR NO	: 22324
BILL NO	: 22223017	BILL DATE/TIME	: 10/09/2022 9.02 AM
AGE/SEX	: 30 YEARS / MALE	SAMPLE DATE/TIME	: 10/09/2022 10.32 AM
TYPE	: OPD	REPORTING DATE/TIME	: 14/09/2022 3.53 PM
DOCTOR NAME	: Dr. CMO	APPROVED DATE/TIME	:
		PRINT DATE/TIME	: 14/09/2022 3.53 PM
		MOBILE NO	: 8299757598

DEPARTMENT OF X-RAY

X-RAY CHEST.

X-RAY CHEST

Lung fields are clear.

Bilateral hilar shadows are normal.

Mediastinum and domes are normal.

Costophrenic angles appear sharp.

Cardiac silhouette appears normal.

No obvious rib fracture seen.

Adv: Clinical and lab data correlation.



(This is only professional opinion and not the diagnosis. Please correlate clinically)

Sector 37-D, BPTP, Dwarka Express Way, Gurugram, Hry.,

Ph.: 0124-6034444, 8526000000, E-mail : signaturehospital@gmail.com, Web.: www.thesignaturehealthcare.com

PARK GROUP OF HOSPITAL : ★ West Delhi ★ South Delhi ★ Gurugram ★ Faridabad ★ Panipat ★ Karnal
Page No:1


The Signature
ADVANCED SUPER SPECIALITY
H O S P I T A L



PATIENT NAME	: Mr SONALI RAJ	MR NO	: 22324
BILL NO	: 22223017	BILL DATE/TIME	: 10/09/2022 9.02 AM
AGE/SEX	: 30 YEARS / MALE	SAMPLE DATE/TIME	: 10/09/2022 10.32 AM
TYPE	: OPD	REPORTING DATE/TIME	: 10/09/2022 10.39 AM
DOCTOR NAME	: Dr. CMO	APPROVED DATE/TIME	:
		PRINT DATE/TIME	: 10/09/2022 10.39 AM
		MOBILE NO	: 8299757598

DEPARTMENT OF ULTRASOUND

ULTRA SOUND WHOLE ABDOMEN

LIVER: is normal in size and echotexture. No evidence of any focal lesion or IHBR dilation is present. Portal vein and CBD are normal in caliber at porta.

GALL BLADDER is well distended and lumen is echofree. Wall thickness is normal. No pericholecystic fluid is seen.

SPLEEN: is normal in size and echotexture. No focal lesion is seen.

PANCREAS: is normal in size and echotexture. Peripancreatic fat planes are clear. MPD is not dilated.

RIGHT KIDNEY: is normal in size and position and outline corticomedullary differentiation is maintained. There is no evidence of any focal lesion / calculus / backpressure changes.

LEFT KIDNEY: is normal in size and position and outline corticomedullary differentiation is maintained. There is no evidence of any focal lesion / calculus / backpressure changes.

URINARY BLADDER is well distended. Wall thickness is normal. No evidence of any focal lesion.

UTERUS: is normal in size, shape and position. Myometrial echotexture is normal. There is no focal lesion.


OVARIES: Both ovaries are normal.

Cul de Sac is clear.

IMPRESSION:

- No significant abnormality.

Please correlate clinically



Dr. Guru

Senior Consultant

Diagnostic & Interventional Radiology

(This is only professional opinion and not the diagnosis. Please correlate clinically)

Sector 37-D, BPTP, Dwarka Express Way, Gurugram, Hry.;

Page No:1

Ph.: 0124-6034444, 8526000000, E-mail : signaturehospital@gmail.com, Web.: www.thesignaturehealthcare.com

PARK GROUP OF HOSPITAL : ★ West Delhi ★ South Delhi ★ Gurugram ★ Faridabad ★ Panipat ★ Karnal

TRANSTHORACIC ECHO- DOPPLER REPORT

NAME - MRS SONALI RAJ	AGE/SEX -30/F
MR. NO. - 22324	DATE - 10/9/2022

M-MODE / 2-D DESCRIPTION

- ❖ **Left Ventricle:** No regional wall motion abnormality. LVEF ~ 60 %.
- ❖ **Left Atrium:** Normal.
- ❖ **Right atrium:** It is Normal Sized.
- ❖ **Right ventricle:** It is Normal Sized. RV Systolic Function is Normal.
- ❖ **Aortic valve:** Aortic Cusps are Normal.
- ❖ **Mitral valve:** It Appears Normal.
- ❖ **Tricuspid valve:** It Appears Normal.
- ❖ **Pulmonic valve:** It Appears Normal.
- ❖ **Main pulmonary artery & its branches:** Appear Normal.
- ❖ **Pericardium:** No Pericardial Effusion Seen
- ❖ **Inter atrial septum:** It is Intact.
- ❖ **Inter ventricular septum:** It is Intact.
- ❖ **IVC:** It is Normal in Size, collapsing & Respiratory Variability.
- ❖ **Clot / Vegetation:** No Intracardiac Clot, Vegetation.

Measurements (mm):

LEFT HEART			RIGHT HEART		
	Observed values (mm)	Normal values		Observed values (mm)	Normal values
Aortic root	30	20-36 (22mm/M ²)	IVC size	-	17-21mm
Aortic valve opening		15-26 (mm/M ²)	IVC respiratory variability		>50%
LA size	34	19-40 (mm/M ²)	RA size	-	<18cm ²
LA volume index (ml/M ²)		<34 ml/M ²		-	
LVID(D)	48	(ED=37-56)	RV basal		24-42mm
LVID(S)	38		RV mid cavity	-	20-35mm
IVS(D)	9	(ED=6-12)	RV longitudinal	-	56-86mm
			RVOT proximal	-	18-33mm
PW(D)	10	(ED=5-10)	TAPSE	-	>15mm
			RV free wall thickness	-	<5mm
LVEF(%)	60%	55%-70%	RVEF		>44%

(This is only professional opinion and not the diagnosis. Please correlate clinically)

Sector 37-D, BPTP, Dwarka Express Way, Gurugram, Hry.,

Doppler velocities (cm/sec)

Aortic valve		Pulmonary valve	
Max/ Vel	124	Max velocity	121
Max/ PG		Max PG	
Mitral valve		Tricuspid valve	
E	63	Max Velocity	
A	61	PASP	-
DT	-	E/E' (>6)	-
E/A	-	S' Velocity (>10cm2/sec)	-

Regurgitation

MR		TR	
Severity	Nil	Severity	Nil
AR		PR	
Severity	Nil	Severity	Nil

Final Interpretation:

- No regional wall motion abnormality. LVEF ~ 60 %
- Normal Cardiac Chamber Dimension.
- No MR, No AR, No TR.
- Normal MIP,
- No Vegetation, Pericardial Effusion.



Dr. AJAY DUA
 DNB (Medicine), DNB (Cardiology)
 Sr. Consultant Interventional Cardiology

(This is only professional opinion and not the diagnosis. Please correlate clinically)

Sector 37-D, BPTP, Dwarka Express Way, Gurugram, Hry.,

Ph.: 0124-6034444, 8526000000, E-mail : signaturehospital@gmail.com, Web.: www.thesignaturehealthcare.com
PARK GROUP OF HOSPITAL : ★ West Delhi ★ South Delhi ★ Gurugram ★ Faridabad ★ Panipat ★ Karnal