



MURUGAN HOSPITALS

HEALING HANDS



LAB REPORT

Patient Name : Mr. G.RAMESH
Age / Gender : 47-Years / Male
UHID ID : MH20220041419
Doctor Name : Dr. ARUN PRAKASH

OP Report No. : INVA2107703
Bill No. : INV2205257
Sample Date : 12/11/2022 - 09:44 AM
Report Date : 12/11/2022 - 01:46 PM

Test Name	Result	Units	Reference Interval
HAEMATOLOGY			
Complete Blood Cell Count(CBC)			
HAEMOGLOBIN	14.8	gms/dl	male :13.0 - 17.0 female :12.0 - 15.0
PACKED CELL VOLUME	46.0	%	male : 40 - 50 female : 36 - 46
RBC COUNT	<u>5.06</u>	millions cells/cu.mm	female: 3.8 - 4.8 male : 4.5 - 5.5
TOTAL WBC	8,500	Cells/Cumm	4,000 - 11,000
Differential Count			
NEUTROPHILS	<u>70</u>	%	40 - 65
LYMPHOCYTES	<u>25</u>	%	30-50
EOSINOPHILS	05	%	01-06
MONOCYTES	<u>00</u>	%	1-10
BASOPHILS	00	%	0-2
ESR 60 MTS	08	mm	5 - 20
PLATELET COUNT	2.14	Lakhs/cumm	1.5 - 4.5
MCV	91.0	fL	76 - 96
MCH	29.2	pg	27 - 32
MCHC	32.1	gms/dl	30 - 36

INTERPRETATION: Test done on automated three part cell counter, all abnormal results are reviewed and confirmed microscopically.

BLOOD GROUPING & RH TYPING " O " POSITIVE

Page 1 of 4

Healing Hearts and Lives

264/125, Kilpauk Garden Road, Kilpauk, Chennai - 600 010.
Phone : +91 44 4644 8989 / 75500 53335 | Email : muruganhosp@gmail.com
Website : www.muruganhospitals.in



MURUGAN HOSPITALS

HEALING HANDS



LAB REPORT

Patient Name : Mr. G.RAMESH
Age / Gender : 47-Years / Male
UHID ID : MH20220041419
Doctor Name : Dr. ARUN PRAKASH

OP Report No. : INVA2107703
Bill No. : INV2205257
Sample Date : 12/11/2022 - 09:44 AM
Report Date : 12/11/2022 - 01:46 PM

Test Name	Result	Units	Reference Interval
BIO CHEMISTRY			
BLOOD SUGAR FASTING	102	mgs/dl	70-110
BLOOD SUGAR POST PRANDIAL	110	mgs/dl	80- 160
SERUM CREATININE	1.0	mg/dl	0.6-1.4
SERUM URIC ACID	5.4	mg/dl	male 3.1-7.0 , female 2.5-5.6
LIPID PROFILE			
TOTALCHOLESTEROL	172	mg/dl	< 200
TRIGLYCERIDE	145	mg/dl	< 150
HDL	43	mg/dl	35 - 80
VLDL	29	mg/dl	2 to 30
LDL	100	mg/dl	<130
CHOLESTEROL/ HDL RATIO	4.0	mg/dl	

Healing Hearts and Lives

264/125, Kilpauk Garden Road, Kilpauk, Chennai - 600 010.
Phone : +91 44 4644 8989 / 75500 53335 | Email : muruganhosp@gmail.com
Website : www.muruganhospitals.in



MURUGAN HOSPITALS

HEALING HANDS



LAB REPORT

Patient Name : Mr. G.RAMESH
 Age / Gender : 47-Years / Male
 UHID ID : MH20220041419
 Doctor Name : Dr. ARUN PRAKASH

OP Report No. : INVA2107703
 Bill No. : INV2205257
 Sample Date : 12/11/2022 - 09:44 AM
 Report Date : 12/11/2022 - 01:46 PM

Test Name	Result	Units	Reference Interval
LIVER FUNCTION TEST			
BILLIRUBIN(TOTAL)	0.6	mg/dl	0.0 -1.0
BILLIRUBIN(DIRECT)	0.2	mg/dl	0.1- 0.30
BILLIRUBIN(INDIRECT)	0.4	mg/dl	0.2-0.8
SGOT	22	IU/L	0-38
SGPT	24	IU/L	0.0-40
ALKALINE PHOSPHATASE	92	IU/L	40-140 4-6Years 93-309 13-15Years 74-390
TOTAL PROTEIN	7.8	gm/dl	6.6-8.7
ALBUMIN	4.5	gm/dl	3.5 - 5.5
GLOBULIN	3.3	gm/dl	2.0-3.5
AG RATIO	1.3		
GAMMA G T	15	U/L	male<49 female<32
BLOOD UREA NITROGEN	9.3	mg/dl	7-21
HBA1C	5.5	%	normal: <6.0 good control: 6.1-7.0 fair control: 7.1- 8.0 poor control:8.1 -10.0 unsatisfactory: >10.0

Healing Hearts and Lives

264/125, Kilpauk Garden Road, Kilpauk, Chennai - 600 010.
 Phone : +91 44 4644 8989 / 75500 53335 | Email : muruganhosp@gmail.com
 Website : www.muruganhospitals.in



MURUGAN HOSPITALS

HEALING HANDS



LAB REPORT

Patient Name : Mr. G.RAMESH
 Age / Gender : 47-Years / Male
 UHID ID : MH20220041419
 Doctor Name : Dr. ARUN PRAKASH

OP Report No. : INVA2107703
 Bill No. : INV2205257
 Sample Date : 12/11/2022 - 09:44 AM
 Report Date : 12/11/2022 - 01:46 PM

Test Name	Result	Units	Reference Interval
-----------	--------	-------	--------------------

CLINICAL PATHOLOGY

URINE SUGAR (F)	NIL		
URINE SUGAR (PP)	NIL		
URINE ROUTINE			
COLOUR	PALE YELLOW		
APPEARANCE	CLEAR		
REACTION	ACIDIC		
SUGAR	NIL		
ALBUMIN	NIL		
DEPOSITES			
PUS CELLS	2 - 3	/ HPF	
EPI CELLS	1 - 2	/ HPF	
RBC COUNT	NIL	/ HPF	
CAST	NIL		
CRYSTALS	NIL		
OTHERS	NIL		

KAVIYARASAN

Verified by

*** End of Report ***



Healing Hearts and Lives

264/125, Kilpauk Garden Road, Kilpauk, Chennai - 600 010.
 Phone : +91 44 4644 8989 / 75500 53335 | Email : muruganhosp@gmail.com
 Website : www.muruganhospitals.in



MURUGAN HOSPITALS

HEALING HANDS




LAB REPORT

NAME : MR. RAMESH G (9831)
PIN : AND22380167358
AGE/GENDER : 47 Year(s)/Male
REFERRED BY : Dr. ARUN PRAKASH
CLIENT NAME : MURUGAN HOSPITAL

SAMPLE NO : 3822110780
COLLECTED ON : 12/11/2022 06:22 PM
RECEIVED ON : 12/11/2022 06:22 PM
REPORTED ON : 12/11/2022 07:30 PM
REPRINT DATE : 12/11/2022 07:31 PM

Test	Obtained Value	Units	Bio.Ref.Intervals
IMMUNOASSAY			
PSA(Prostate Specific Antigen) - Total, Serum (SERUM,ECLIA)	0.387	ng/mL	<= 2.0

-- End of Report --



Uma

Dr. T. Uma MD, DCP
Consultant Biochemist

Page 1 / 1
Healing Hearts and Lives

264/125, Kilpauk Garden Road, Kilpauk, Chennai - 600 010.
Phone : +91 44 4644 8989 / 75500 53335 | Email : muruganhosp@gmail.com
Website : www.muruganhospitals.in

MURUGAN HOSPITALS

HEALING HANDS



LAB REPORT

Name : Mr. G.RAMESH
Gender : 47-Years / Male
ID : MH20220041419
Physician Name : Dr. ARUN PRAKASH

OP Report No. : INVA2107703
Bill No. : INV2205257
Sample Date : 12/11/2022 - 09:44 AM
Report Date : 12/11/2022 - 08:36 PM

Test Name	Result	Units	Reference Interval
-----------	--------	-------	--------------------

ENDOCRINOLOGY

T3	0.864	ng/ml	0.52-1.85
T4	6.192	ug/dl	5.0 -13.0 ug/dl
TSH	0.457	uIU/ml	0.39 - 6.16 uiu/ml

NITHYALAB
Verified by

*** End of Report ***

Authorized Signature



ID : 2211120005

Name: MR. RAMESH

Sex : Male

Divisions:

DataTime: 2022-11-12 10:19

Age : 47

BP : 150/90 mmHg

Bed No.:

PatientID: 41419

Height : 180 cm

Weight : 96 kg

Hospital No.:

Hospital: MURUGAN HOSPITALS

Diagnosis Info
800: Sinus Rhythm

Normal ECG

HR 67 bpm

P Dur/PR int 101/148ms

QRS Dur 97 ms

QT/QTc int 391/416 ms

P/QRS/T axis 5/6/18°

RV5/SV1 amp 1.095/0.621mV

RV5+SV1 amp 1.716mV

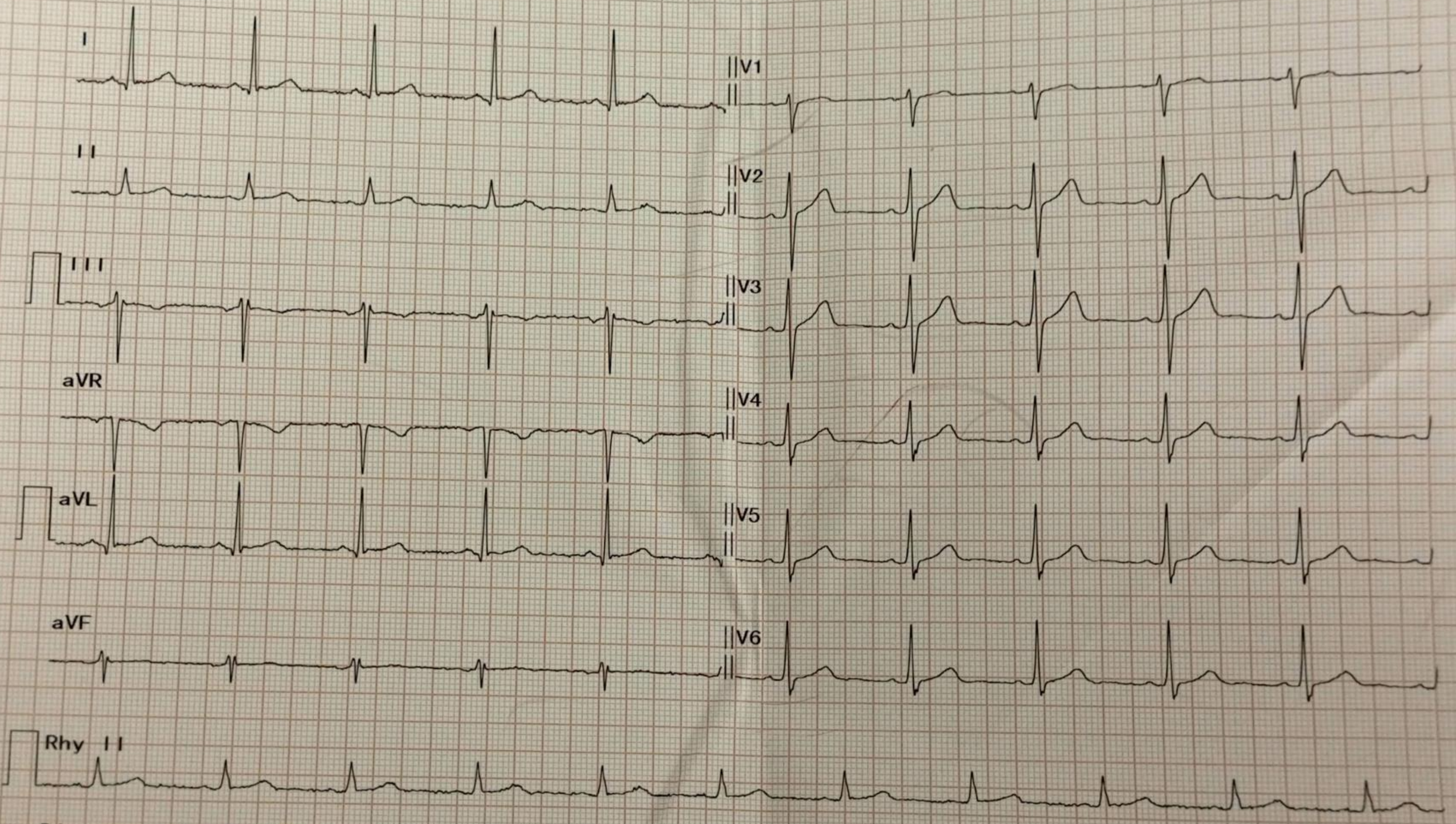
RV6/SV2 amp 1.187/1.064mV

Minnesota Code

3-1-4(aVL)

3-3-3(I)

9-4-1(V3)



Diagnosis for reference, ask your doctor to confirm

AUTO PRINT 6X2+1R 67bpm 10 mm/mV 0.50Hz-35Hz AC 50Hz 25 mm/sec

Confirmed By:

172120



MURUGAN HOSPITALS

HEALING HANDS



ECHO CARDIOGRAM REPORT

NAME : MR. G.RAMESH

UHID NO: MH20220041419

AGE&SEX : 47Y/MALE

IP/OP : OUTPATIENT

CONSULTANT: DR. ARUN PRAKASH

DATE : 12-11-2022

2D PLAX (mm)

RV - 29 mm
AO - 34 mm
LA - 34 mm

COLOR DOPPLER

Normal

M-Mode (mm)

IVS - 07 mm
PW - 09 mm
LVD - 43 mm
LVS - 27 mm
EF - 68 %
FS - 37 %

DOPPLER (m/sec)

MITRAL E - 0.7 m/s
MITRAL A - 0.9 m/s
PULMONARY - 1.0 m/s
AORTIC - 1.2 m/s
TRICUSPID - 0.4 m/s

IMPRESSION:

No RWMA
Normal LV Systolic function
Grade I left ventricular diastolic dysfunction
Normal RV function
No pulmonary hypertension
No pericardial effusion
No clot/ Vegetation.


DR. SIDHARTHAN MD., DM.,
CONSULTANT CARDIOLOGIST

Healing Hearts and Lives

264/125, Kilpauk Garden Road, Kilpauk, Chennai - 600 010.

Phone : +91 44 4644 8989 / 75500 53335 | Email : muruganhosp@gmail.com

Website : www.muruganhospitals.in



MURUGAN HOSPITALS

HEALING HANDS



SCAN REPORT

NAME : MR.RAMESH
AGE /GENDER:47YRS/ MALE
CONSULTANT: DR.ARUNPRAKASH

UHID : MH20220041419
IP/OP : OP
DATE : 12.11.2022

X-RAY CHEST (PA VIEW)

- The cardio thoracic ratio is normal
- The heart size and configuration are within normal limits
- The aortic arch is normal
- The lung fields show normal broncho- Vascular markings
- Both the pulmonary hila are normal in size
- The costophrenic and cardiophrenic recesses and the domes of diaphragm are normal
- The bones and soft tissues of the chest wall show no abnormality

IMPRESSION:

Normal Study



MEDICAL OFFICER

Healing Hearts and Lives

264/125, Kilpauk Garden Road, Kilpauk, Chennai - 600 010. Phone : +91 44 4644 8989 / 75500 53335
Email : muruganhosp@gmail.com | Website : www.muruganhospitals.in



MURUGAN HOSPITALS

HEALING HANDS



SCAN REPORT

NAME	: MRS.G.RAMESH	PATIENT ID	: MH20220041419
AGE/SEX	: 47 Years / MALE	IP / OP NO	: OP21034483
CONSULTANT	: DR.ARUN PRAKASH	DATE	: 12/11/2022

ULTRA SOUND SCAN OF ABDOMEN

LIVER: Enlarged in size and measures- 16.8 cm and increased in echotexture. No focal lesions are seen. No dilatation of intra-hepatic biliary radicals present. Hepatic veins and IVC appear normal. Portal vein is normal in caliber. Common bile duct is normal in caliber.

GALL BLADDER: Contracted.

PANCREAS: Normal in size and echotexture. No focal lesions are seen. No evidence of calculi or calcifications. No evidence of pancreatic duct dilation.

PARA AORTIC AREAS: Aorta and IVC appear normal. No evidence of para aortic lymphadenopathy.

SPLEEN: Normal in size. Normal in echotexture. No evidence of focal lesions.

RIGHT KIDNEY: Measures 10.0 x 5.0 cm and is normal in size and echotexture. Cortico medullary differentiation is well maintained. There is no hydronephrosis or mass.

LEFT KIDNEY: Measures 9.9 x 4.5 cm and is normal in size and echotexture. Cortico medullary differentiation is well maintained. There is no calculus or hydronephrosis or mass.

Healing Hearts and Lives

264/125, Kilpauk Garden Road, Kilpauk, Chennai - 600 010. Phone : +91 44 4644 8989 / 75500 533
Email : muruganhosp@gmail.com | Website : www.muruganhospitals.in

PROSTATE: Could not be assessed.

No ascites present. No retroperitoneal lymphadenopathy present.

IMPRESSION:

- **Hepatomegaly with fatty infiltration.**
- **No other significant abnormality.**

DR. SAKTHI MDRD.,
CONSULTANT RADIOLOGIST,

