

Diwakar Diagnostic Centre
E-7/636, Aera Colony, Bhopal

881 / SAPNA UIKEY / 40 Yrs / F / 0 Cms / 0 Kg Date: 19-Nov-2022 Refd By : BOB

Report



(GEM213180307)(R)Allengers

Report :

TEST OBJECTIVE : ROUTINE CHECK UP
RISK FACTOR : FEMALE
ACTIVITY : SEDENTARY
MEDICATION : NONE
REASON FOR TERMINATION : FATIGUE, HEART RATE ACHIEVED
EXERCISE TOLERANCE : AVERAGE
EXERCISE INDUCED ARRHYTHMIAS : NO
HAEMODYNAMIC RESPONSE : NORMAL
CHRONOTROPIC RESPONSE : NORMAL
FINAL IMPRESSION : STRESS TEST IS NEGATIVE FOR EXERCISE INDUCED ISCHAEMIC HEART DISEASE

Bob



881 / SAPNA UIKEY / 40 Yrs / F / 0 Cms / 0 Kg Date: 19-Nov-2022 Refd By : BOB

Stage	Time	Duration	Belt Speed (mph)	Elevation	METs	Rate	% THR Achieved	BP	RPP	PVC	Comments
Supine	00:15	0:01	00.0	00.0	01.0	89	49 %	112/74	099	00	
Standing	00:25	0:01	00.0	00.0	01.0	89	49 %	112/74	099	00	
HV	00:37	0:01	00.0	00.0	01.0	091	51 %	112/74	101	00	
ExStart	01:36	0:06	01.7	10.0	01.1	089	49 %	112/74	099	00	
BRUCE Stage 1	04:36	3:00	01.7	10.0	04.7	157	87 %	118/78	185	00	
PeakEx	05:59	1:23	02.5	12.0	05.8	163	91 %	118/78	192	00	
Recovery	06:58	1:00	00.0	00.0	01.0	121	67 %	118/78	142	00	
Recovery	07:58	2:00	00.0	00.0	01.0	098	54 %	116/70	113	00	
Recovery	08:58	3:00	00.0	00.0	01.0	095	53 %	112/70	106	00	
Recovery	09:19	3:20	00.0	00.0	01.0	097	54 %	112/70	108	00	

Findings :

Exercise Time : 04:24
 Max HR Attained : 163 bpm 91% of Target 180
 Max BP Attained : (Sys) 118/78
 Max WorkLoad Attained : 5.8 Fair response to induced stress
 Test End Reasons : Fatigue, Heart Rate Achieved


 भारत निर्वाचन आयोग
 ELECTION COMMISSION OF INDIA
 मतदाता फोटो पहचान पत्र - ELECTOR PHOTO IDENTITY CARD

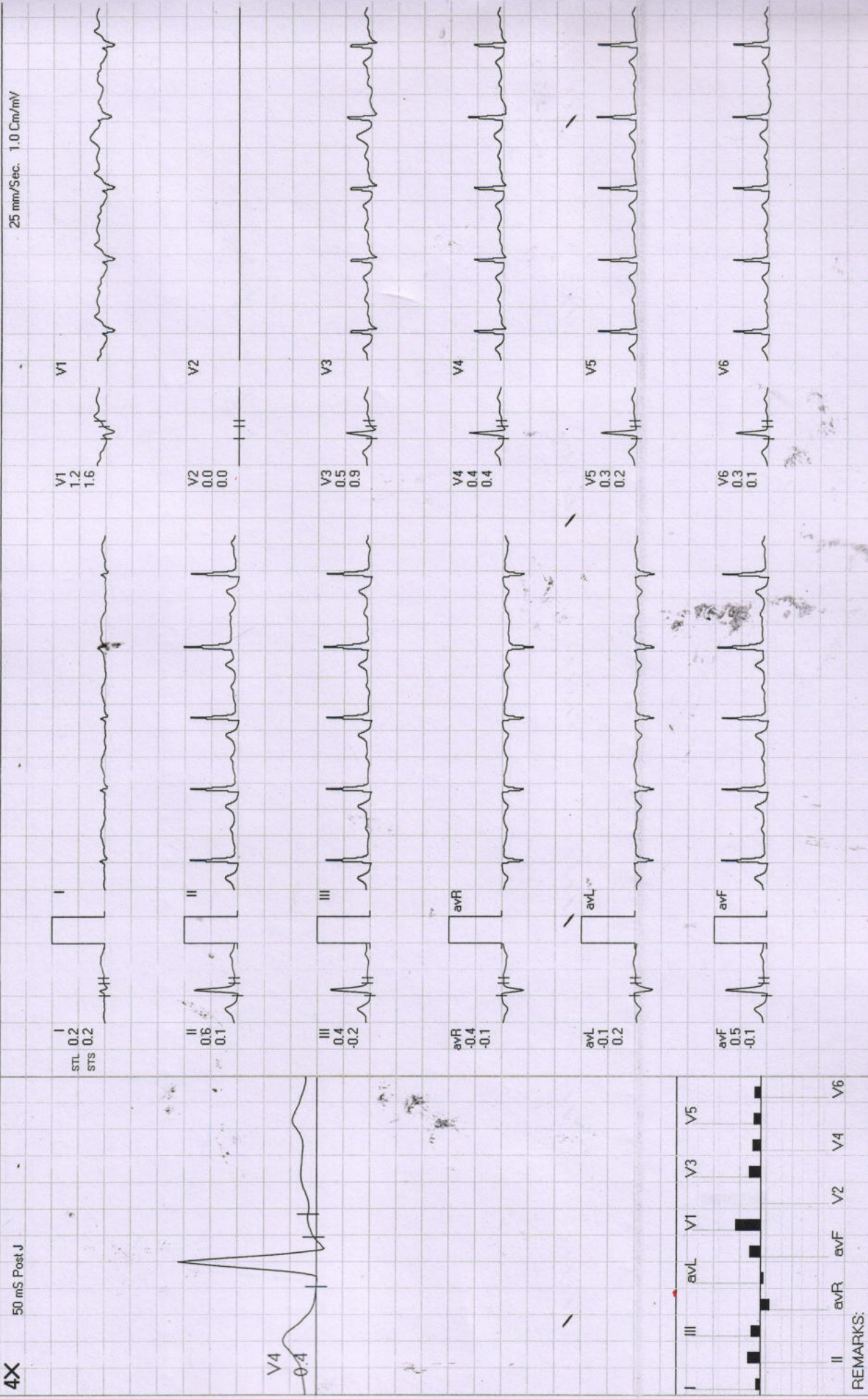

 NMU3803731



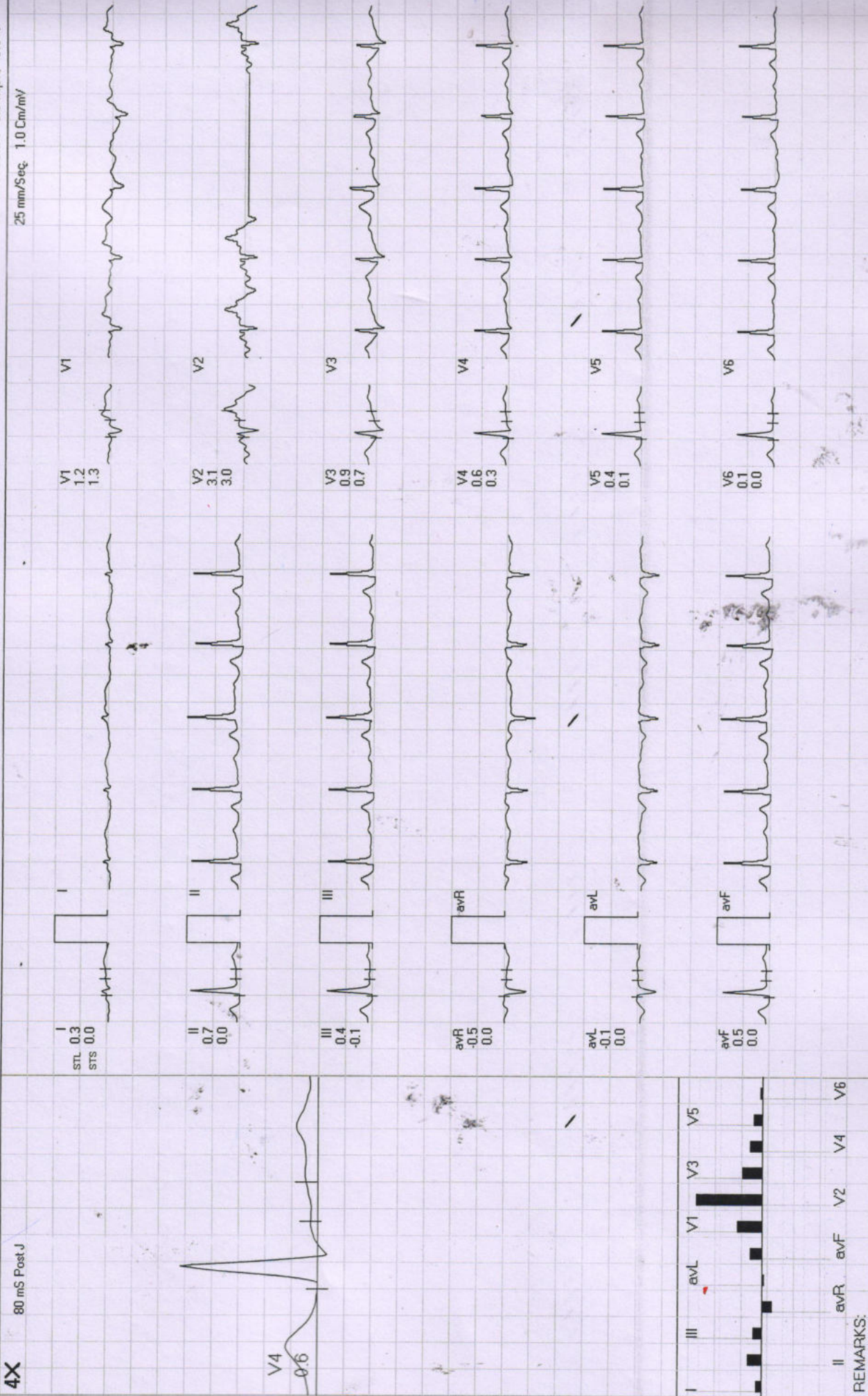
निर्वाचक का नाम सपना उईके
 ELECTOR'S NAME • SAPNA UIKEY
 पति का नाम राजेंद्र कुमार उईके
 HUSBAND'S NAME RAJENDRA KUMAR UIKEY



सपना



Date: 19-Nov-2022 09:49:33 AM METS: 1.0/ 89 bpm 49% of THR BP: 112/74 mmHg Raw ECG/BLC On/ HF 0.05 Hz/LF 20 Hz ExTime: 00:24 0.0 mph, 0.0%



Diwakar Diagnostic Centre

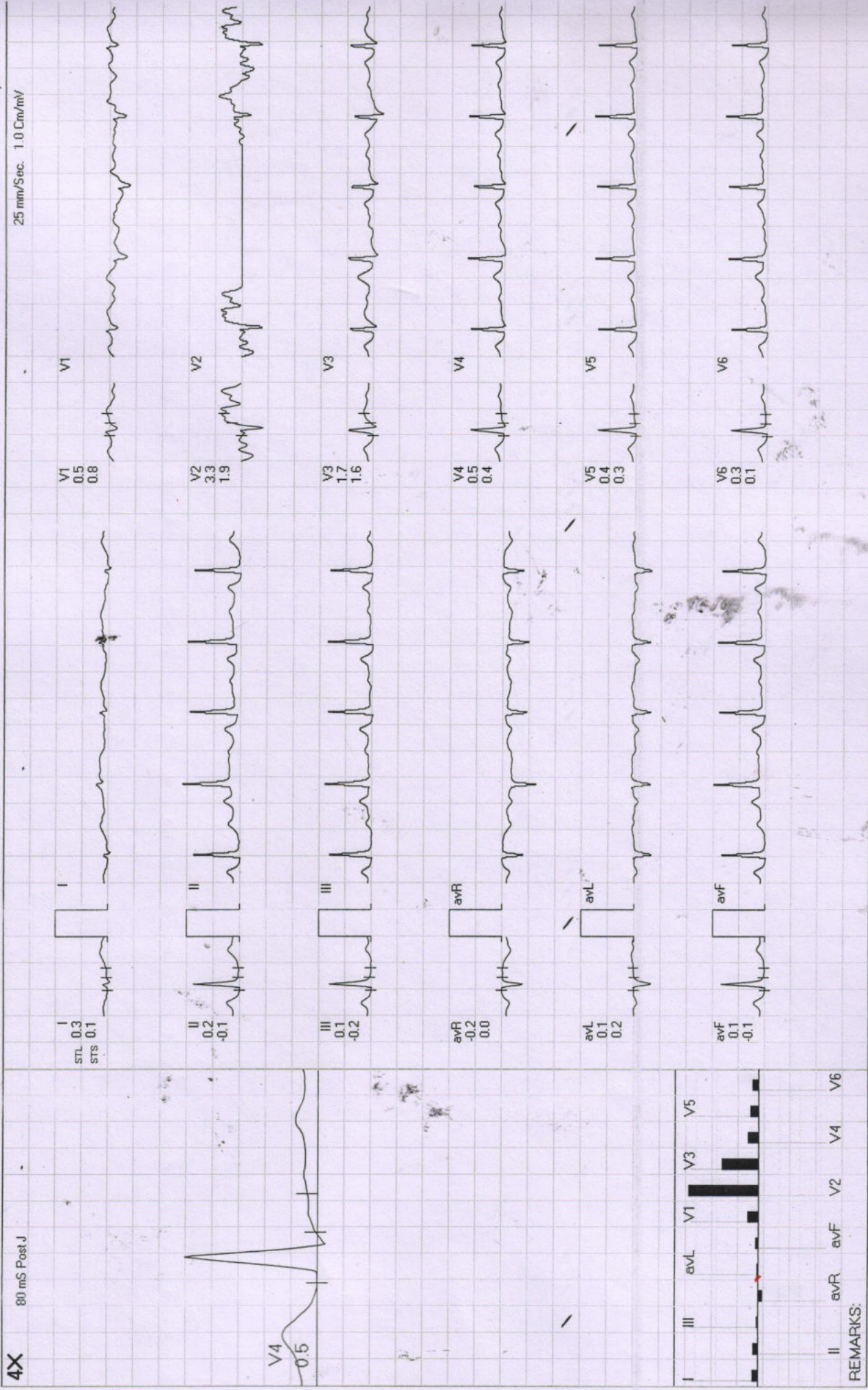
881 / SAPNA UIKEY / 40 Yrs / F

HV



Date: 19-Nov-2022 09:49:33 AM METS: 1.0/91 bpm 50% of THR BP: 112/74 mmHg Raw ECG/BLC Onr/ HF 0.05 Hz/LF 20 Hz

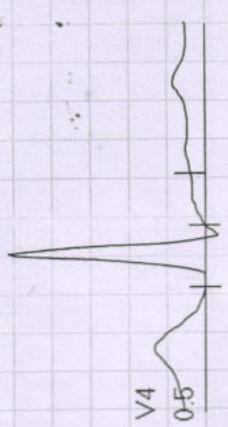
EXTime: 00:36 0.0 mph 0.0%



4X

40 mS Post J

I
STL 0.3
STS 0.5



V4
0.5

II
-0.3
-0.2

III
0.1
-0.6

avR
-1.9
1.0

avL
0.1
0.6

avF
0.1
-0.4

V1
0.5
1.8

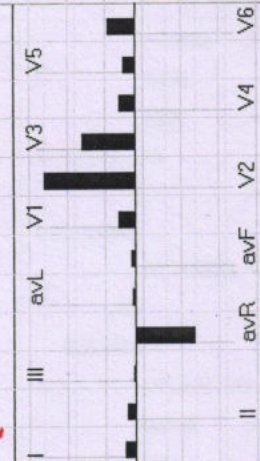
V2
3.0
3.7

V3
1.7
3.3

V4
0.5
1.0

V5
0.4
0.5

V6
0.9
-2.2



REMARKS:



BRUCE : Stage 1 (03:00)

Diwakar Diagnostic Centre

881 / SAPNA UIKEY / 40 Yrs / F

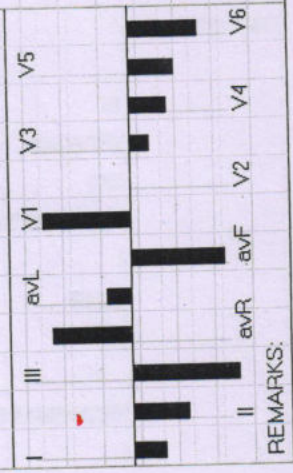

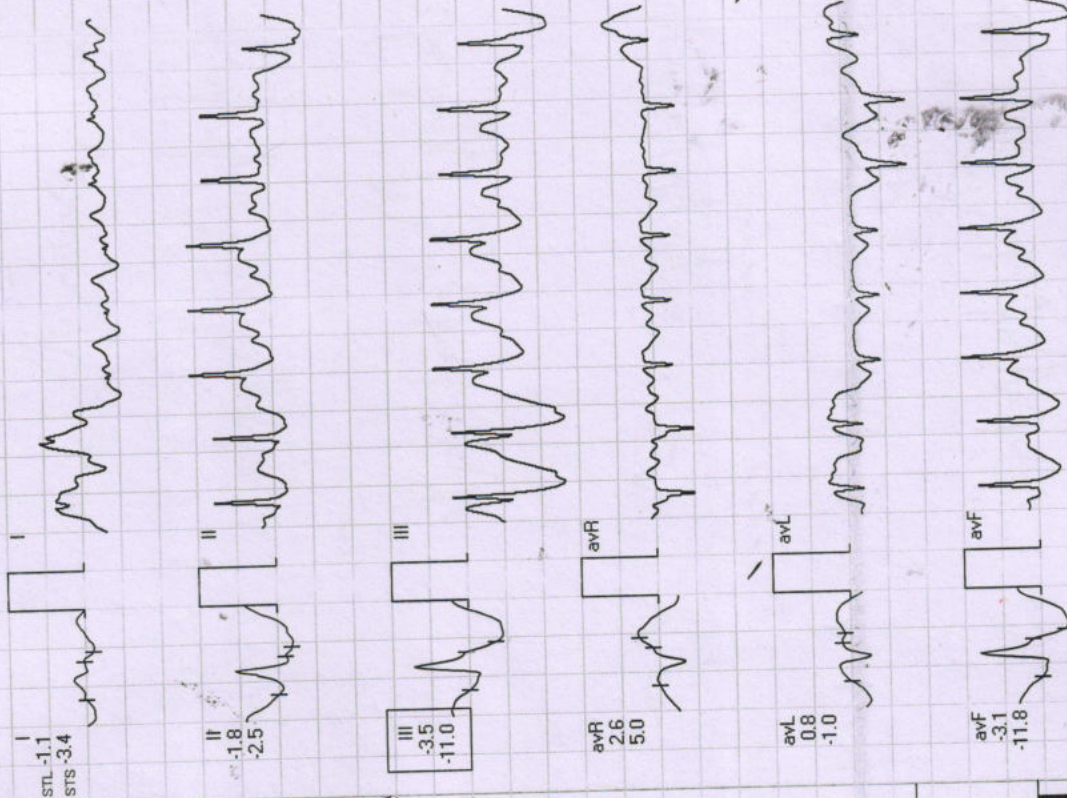
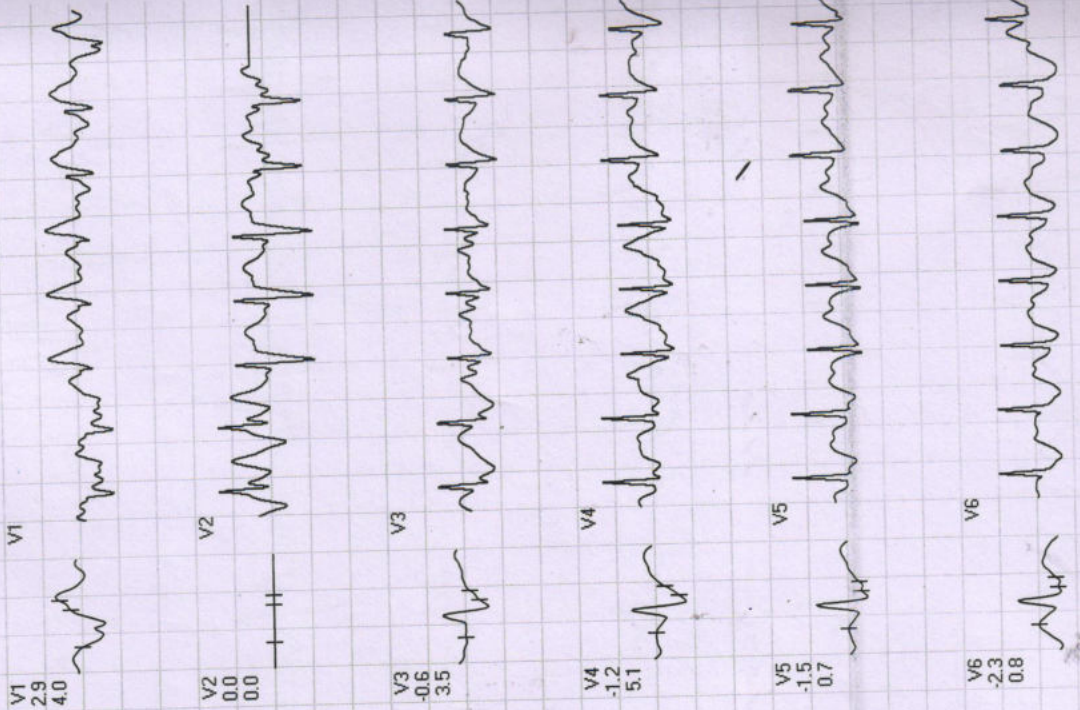
ExTime: 03:00 1.7 mph. 10.0%

Date: 19-Nov-2022 09:49:33 AM METS: 4.7/ 157 bpm 87% of THR. BP: 118/78 mmHg Raw ECG/BLC Or/ HF 0.05 Hz/LF 20 Hz

4X

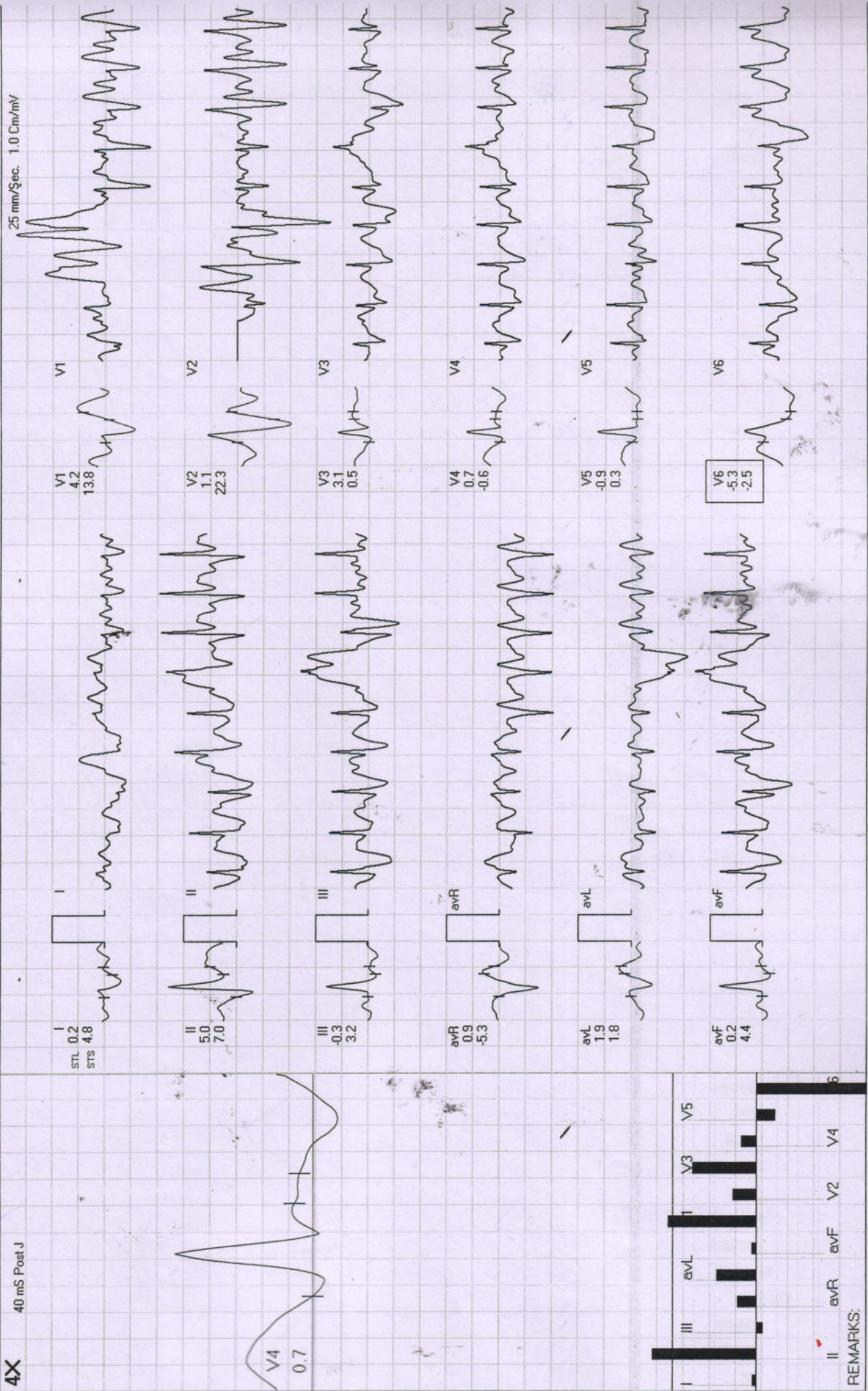
40 mS Post J

25 mm/Sec. 1.0 Cm/mV



REMARKS:

Date: 19-Nov-2022 09:49:33 AM METS: 5.8 / 163 bpm 90% of THR BP: 118/78 mmHg P_{raw} ECG/BLC On/ HF 0.05 Hz/LF 20 Hz ExTime: 04:23 2.5 mph, 12.0%



Recovery : (01:00)



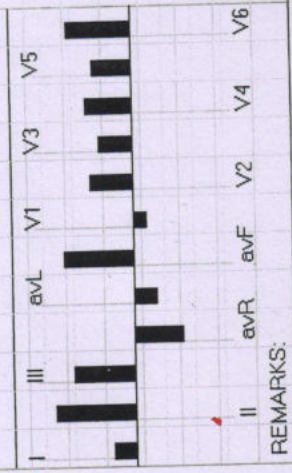
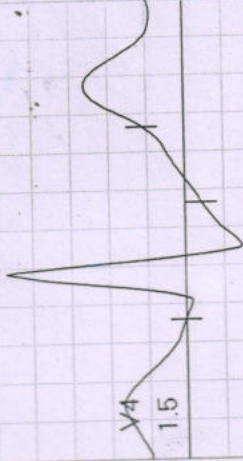
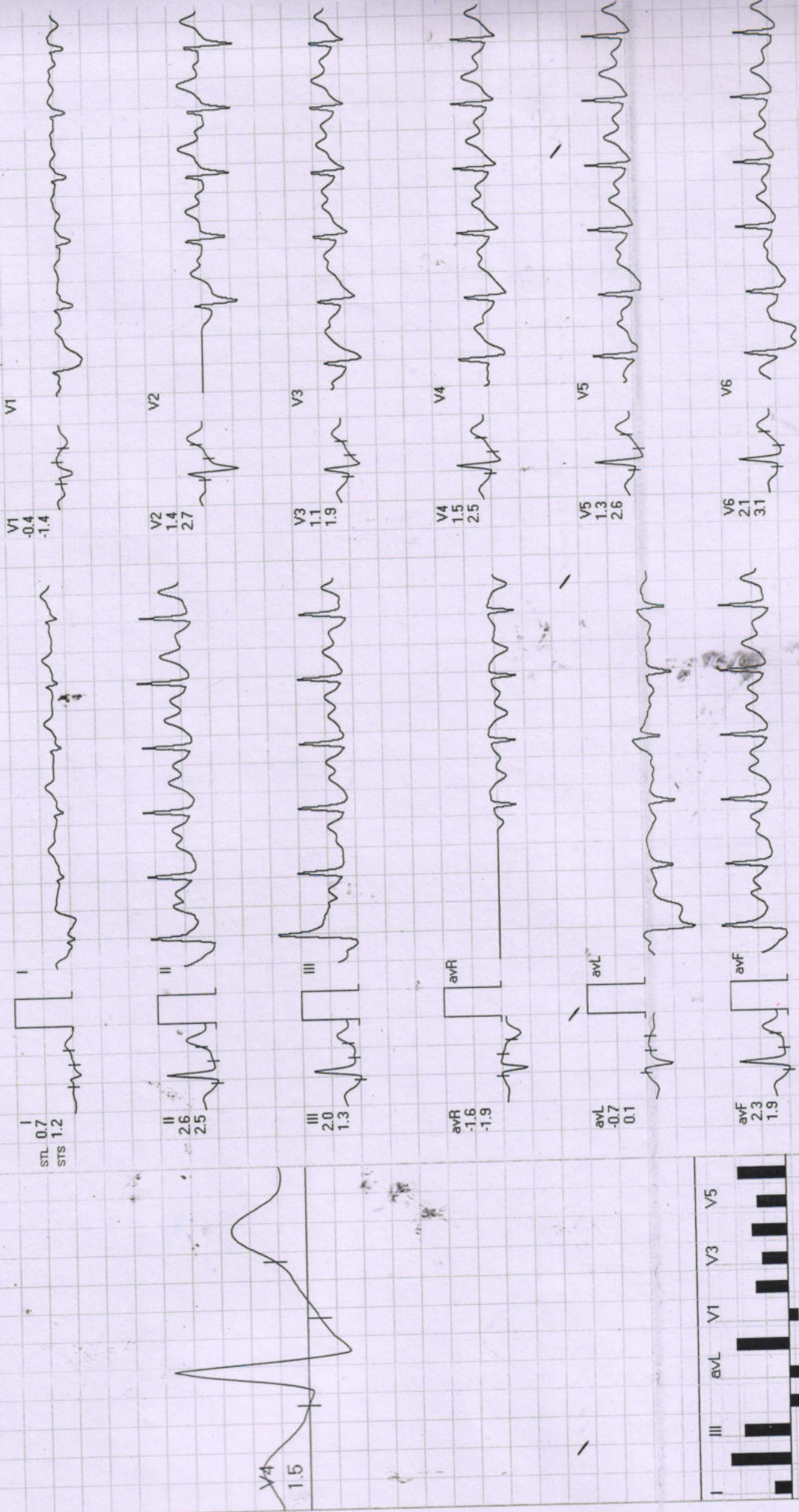Diwakar Diagnostic Centre

881 / SAPNA UIKEY / 40 Yrs / F

Date: 19-Nov-2022 09:49:33 AM METS: 1.0/ 121 bpm 67% of THR BP: 118/78 mmHg Raw ECG/ BLC On/ H/F 0.05 Hz/LF 20 Hz

ExTime: 04:23 0.0 mph, 0.0%
25 mm/Sec. 1.0 Cm/mV

4X 80 mS Post J



REMARKS:

(GEM213180307)(A)Allengers



Recovery : (02:00)

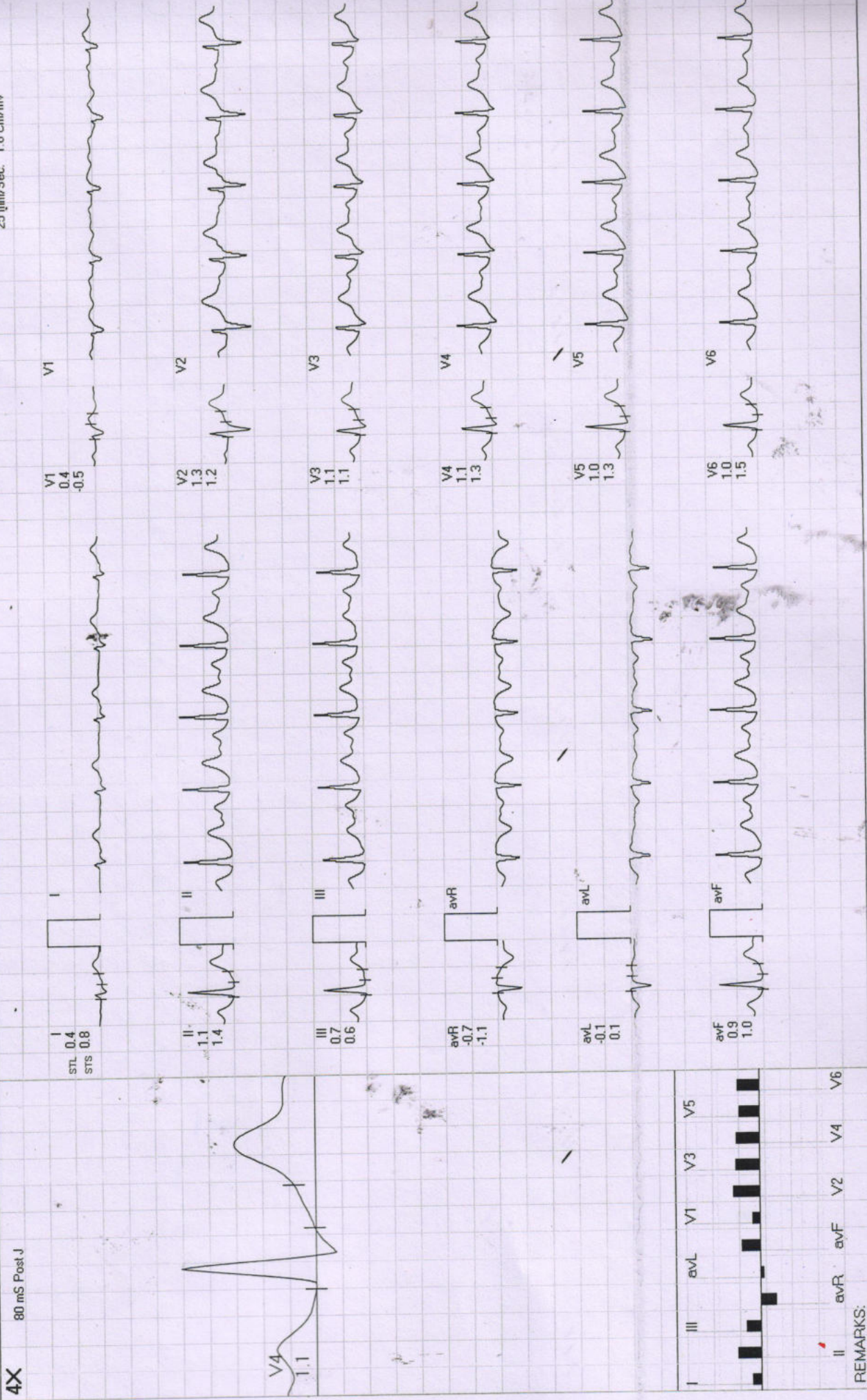
Diwakar Diagnostic Centre

881 / SAPNA UIKEY / 40 Yrs / F

Date: 19-Nov-2022 09:49:33 AM METS: 1.0/98 bpm 54% of THR BP: 116/70 mmHg Raw ECG/BLC Ony/Notch Ony/HF 0.05 Hz/LF 20 Hz

ExTime: 04:23 0.0 mph. 0.0%

25 mm/Sec. 1.0 Cm/mV



REMARKS:

Diwakar Diagnostic Centre

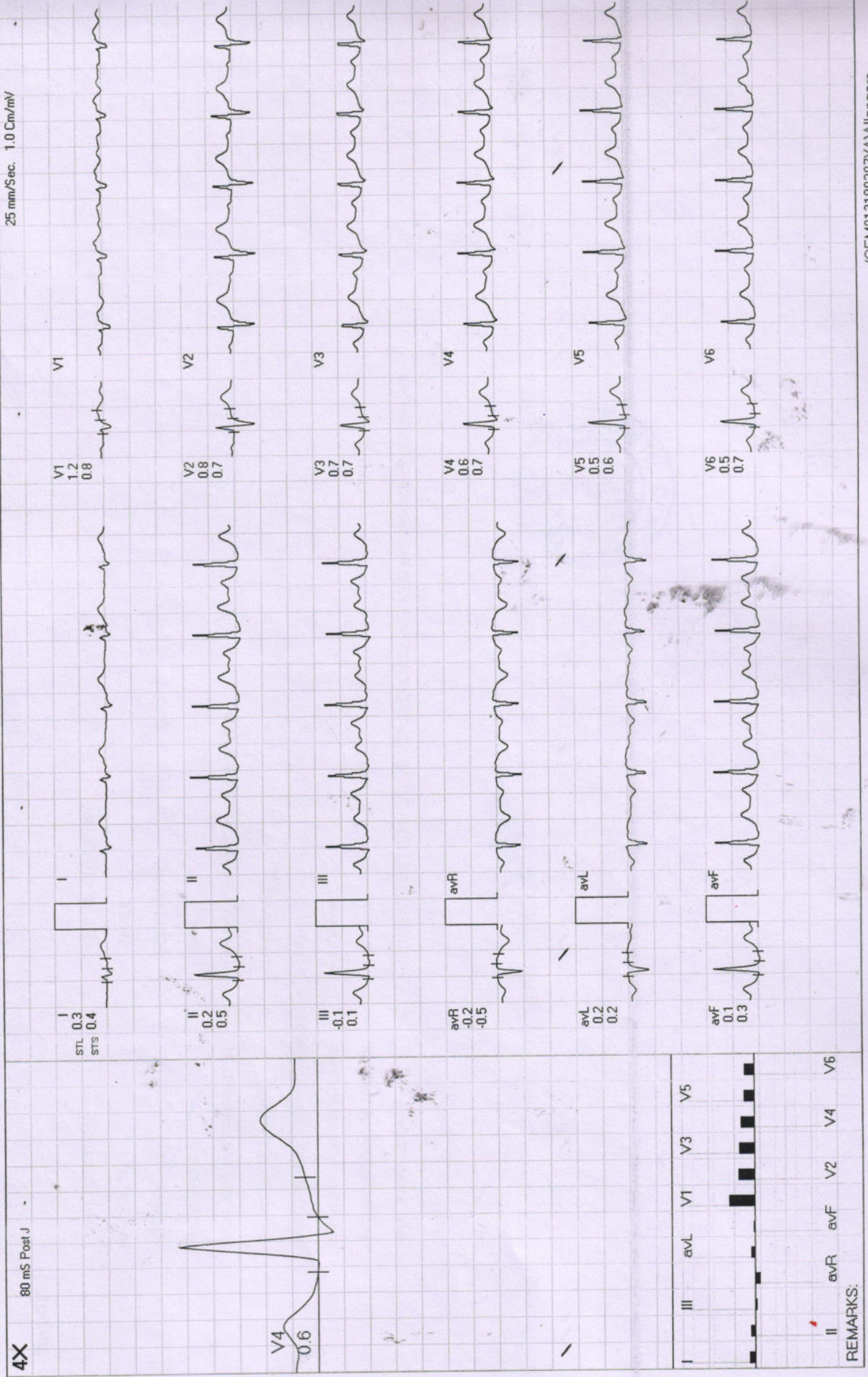
887 / SAPNA UIKEY / 40 Yrs / F

Recovery : (03:00)

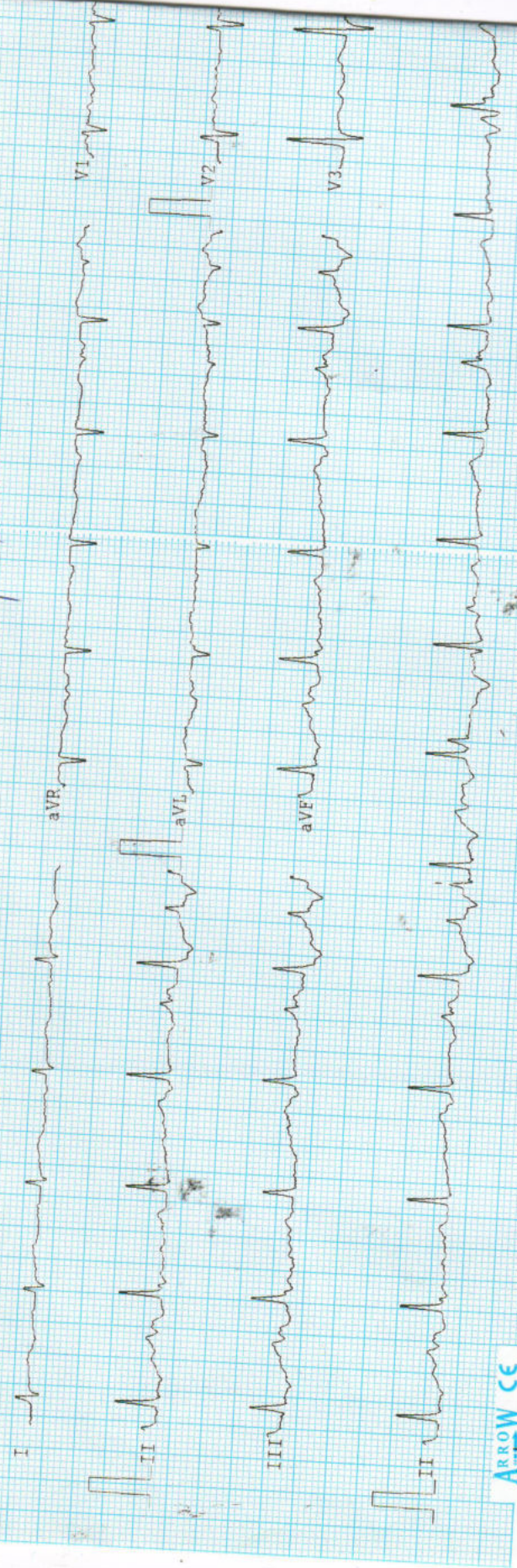

Date: 19-Nov-2022 09:49:33 AM METS: 1.0/ 95 bpm 52% of THR BP: 112/70 mmHg Raw ECG/ BLC On/ Natch On/ HF 0.05 Hz/LF 20 Hz

ExTime: 04:23 0.0 mph, 0.0%



Sapna Vikraj. Age - 40/Y/f 19/11/2022



Arrow CE

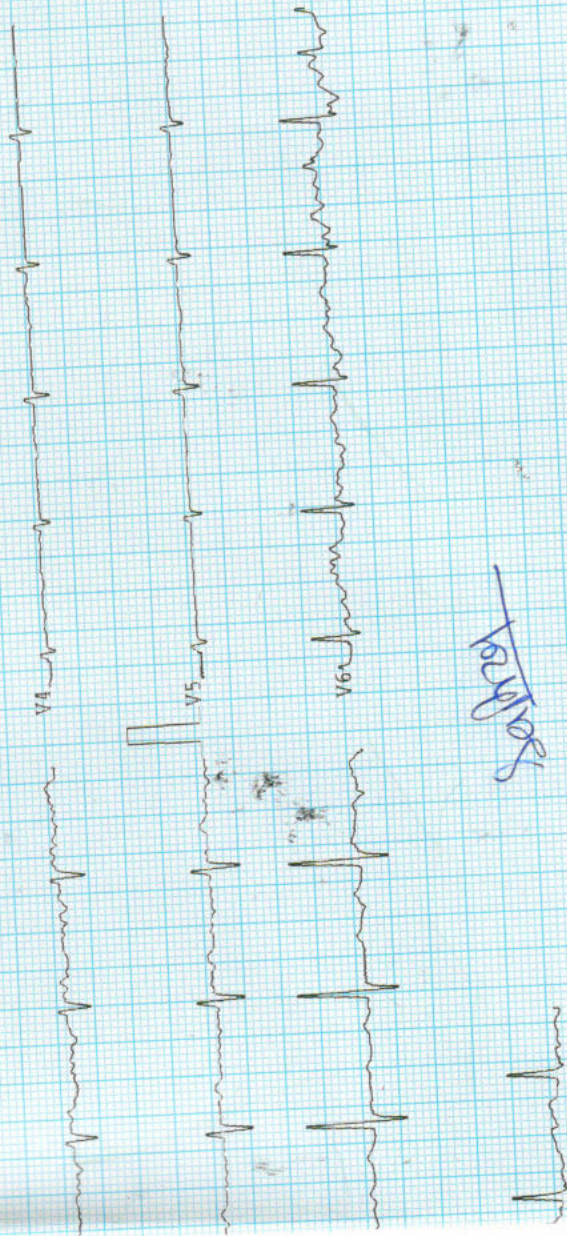
Observations :-

HR :- 90 bpm
R-R :- 666 ms
P-R :- 116 ms
QRS :- 69 ms
QT/QTc :- 250/306 ms
P Axis :- -24 °
R Axis :- -02 °
T Axis :- -09 °



Remarks :-

Unconfirmed report



Sahay

ARTOW CE

PTO

Right Kidney is normal in size, shape and position. Corticomedullary differentiation (CMD) is well maintained. Normal cortical thickness is noted. No E/O hydronephrosis or calculus is noted.

Pancreas appear normal in size, shape and echo texture with smooth contour. No peripancreatic pathology seen. (Not seen due to gases) Spleen is normal / enlarged in size and normal in echo texture. IVC and aorta appear to be normal. No evidence of lymphadenopathy is noted. No evidence of free fluid is noted.

Gall Bladder is physiologically well distended / collapsed. No E/O echogenic foci in GB lumen. GB wall is normal / thickened. No E/O pericholecystic collection. common duct reveals normal course and caliber.

Liver appears normal / enlarged in size and shape with smooth in outline. Normal / increased parenchymal echogenicity is noted. No E/O focal lesion / IHBR dilatation is seen. Hepatic veins and portal veins appear normal. No E/O Subdiaphragmatic Collection.

WHOLE ABDOMEN ULTRASOUND REPORT

Indication :

Name : Mrs. Sapna Verma
Age : 40 / F
R/B : Health check-up
Date : 19.11.2022

श्री. सविता रिडियोलॉजिक
34, भूतल, मोहिनी अदिति आर्कड, शाहपुरा मस्जिद के पास
भरत नगर रोड, ई-7/194, अररा कॉलोनी, भोपाल - 462038
Mob. : 8989649694, 9516333619
Clinic Registration : CL/5392/Jun/2017
PNDT Registration : MP/CPN/DT/BPL/2017/206



Left Kidney is normal in size, shape and position. CMD is well maintained. Normal cortical thickness is noted. No E/O hydronephrosis or calculus is noted.

Urinary Bladder is well distended (physiological) / collapsed. Its contents are echo free. No E/O bladder wall thickening is noted. Post-void residue is insignificant.

Prostate is normal in size, shape and echo texture with smooth outline. No E/O focal lesion is noted.

Uterus is ante/~~retro~~verted and normal in size, shape and echotexture with smooth outline. No E/O focal lesion is noted, endometrial echo appear normal. Cervical and vaginal shadows appear normal. *Small 1.51 cm size out wall fibroid noted. endometrium narrowed*

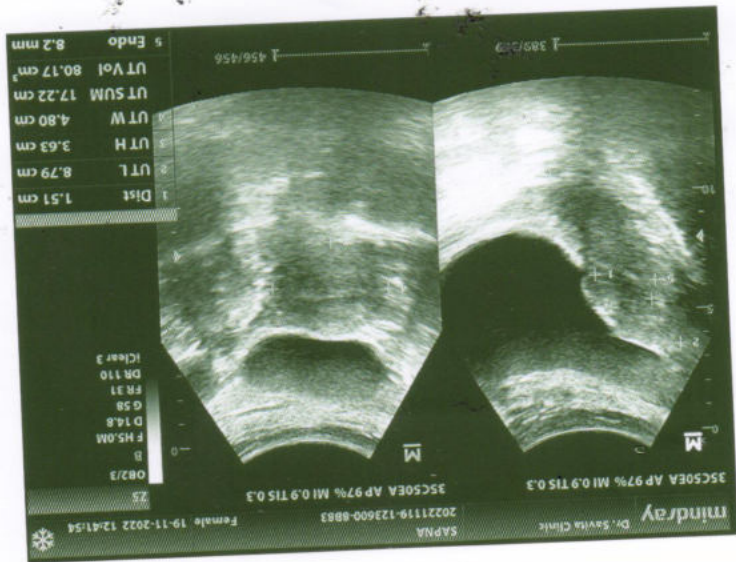
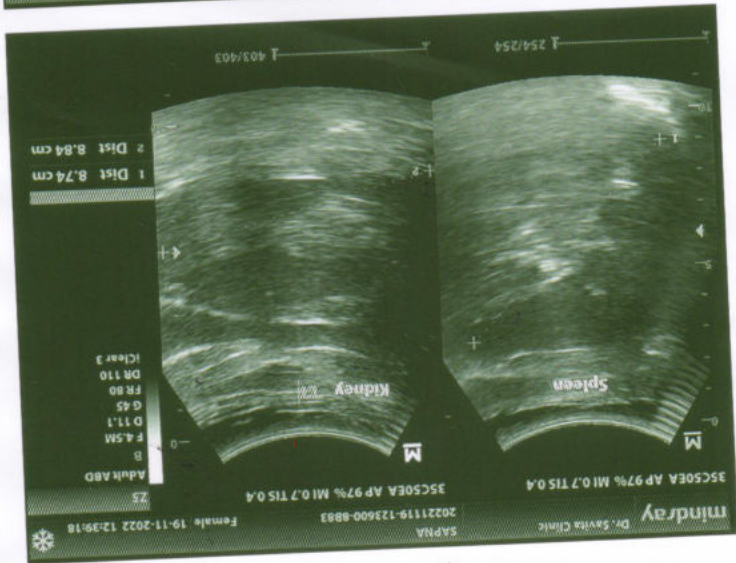
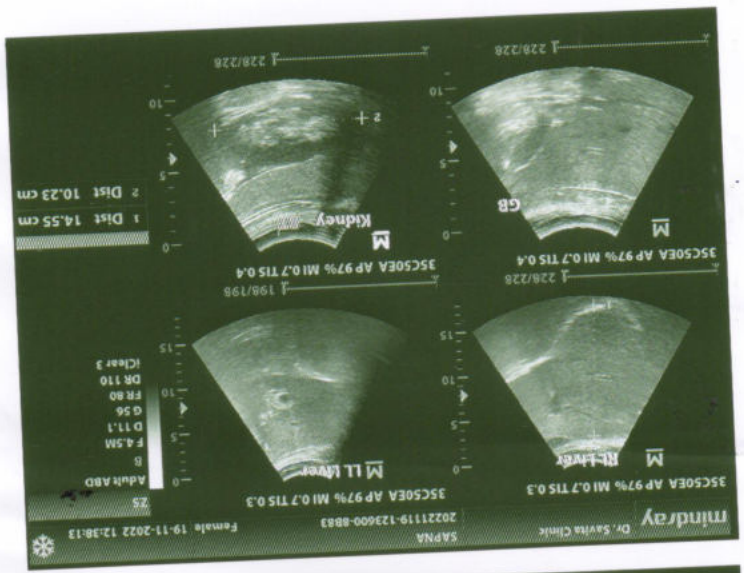
Right Ovary appears Enlarged / Normal in size, shape and echo texture.

Left Ovary appears Enlarged / Normal in size, shape and echo texture.

Impression : Normal study. *Small seedling fibroid uterus.*

Jain

Advised clinical Correlation.





Dr. B. M. Agarwal
Pathologist
MBBS, DCP
Consultant Pathologist

All test have technical limitation. Collaborative clinic pathological interpretation is mandatory. In case of disparity test may be repeated immediately. Typographical mistakes should be get correct instantly. This report is not valid for medico legal purpose

TEST	RESULT	NORMAL VALUE
Haemoglobin	11.0gms%	Female 12-16gms%, Male 14-18gms%
Red Cell count	4.12	4.5-5.6 million /cumm
Platelet Count	1.85	1.5-5.6 Lac/cumm
Leucocytes per.cu.mm	6800/cumm	5000-11000/cumm
Neutrophils	51%	50-70%
Lymphocytes	36%	20-40%
Eosinophils	07%	0-7%
Monocytes	06%	2-8%
PCV	44.6	37-47
MCV	87.9	76-96
MCH	26.7	27-32
MCHC	30.4	31-35
Blood Group	"O" Positive	Male 0-9, Female 0-20mm/FHR
Total Serum Cholesterol	178.0	100-250 mg%
Serum Triglyceride	148.0	Up to 150 mg%
Serum Cholesterol HDL	51.0	Up to 65 mg%
Serum Cholesterol LDL	97.4	Up to 125 mg%
LDL	29.6	Up to 30 mg%
S.Bilirubin(Total)	0.9	0.2-1.0mg/dl
Direct	0.5	0.0-0.25mg/dl
Indirect	0.4	
SGOT	26.0	5-35U/L
SGPT	30.0	8-40U/L
Alk Phosphatase	8.9	3-13 KA units
S. Protein(Total)	7.0	6.0-8.0mg%
Albumin	4.9	3.7-5.3mg%
Globulin	2.4	1.5 to 3.5 mg%
Blood Urea	22.0	Up to 40 mg%
S.Creatine	0.98	0.5-1.4mg/dl
S. Uric Acid	6.0	3.5-7.5mg%
GGTP	24.0	5-35 UL/dl
Fasting Blood Sugar	84.2	Up to 110 mg%
PP Blood Sugar	110.0	Up to 125 mg%
Glycosylated Hemoglobin	5.5	Below - 6.0% - Non Diabetic control 6-7% - Excellent control Above- 8% - Poor control
Thyrod Stimulating Hormone(TSH)	3.9	0.27-4.2

EXAMINATION OF BLOOD

Date :- 19/11/2022

Lab. No. :- 06

Age :- 40/F

Pt Name :- Mrs. Sapna Virkey 9826340190

E-7/636, पंजाब रेगुलर बैंक के पास, धन रोड, अंशु कॉलोनी भीमल (म.उ.)

डिवाकर डायग्नोस्टिक सेंटर





Dr. B. M. Agarwal
MBBS, DCP
Consultant Pathologist
Pathologist

A. PHYSICAL EXAMINATION	
1. Colour	Pale Yellow
2. Appearance	Clear
3. Specific Gravity	Q.N.S.
B. CHEMICAL EXAMINATION	
1. Reaction	Acidic
2. Albumin	Nil
3. Sugar	Nil
4. Bile Salts	Absent
C. MICROSCOPIC EXAMINATION	
Pus Cells	2-3/HPF
R.B.C.	Nil
Epithelial Cell	2-3/HPF
Cast	Nil
Crystals(Cal, Oxa)	Nil
Bacteria	Nil
Amorphous	Nil
T. Vaginitis	Nil

URINE ANALYSIS

Pt Name :- Mrs. Sapna Utkay
Age :- 40/F
Lab. No. :- 06
Date :- 19/11/2022



डिवाकर डायग्नोस्टिक सेंटर
E-7/636, पंचाल चेंबर ब्लॉक के पास, मैन रोड, अरुण कॉलोनी भीमल (म.प्र.)
फोन: 0755-2465288, 0755-3520545 मो: 9826340190