



भारतीय विशिष्ट पहचान प्राधिकरण
भारत सरकार
 Unique Identification Authority of India
Government of India

Enrolment No.: 2076/20842/04586


Download Date: 04/10/2018

To
 Fatima Alves
 W/O Aldrin Lobo
 H No 126/1
 Alariwaddo
 Canaguimim
 Naquerim
 Cuncolim
 South Goa Goa - 403703
 9881884051

Generation Date: 03/10/2017

Signature Not Verified

Digitally signed by 9881884051
 UNIQUE IDENTIFICATION
 AUTHORITY OF INDIA
 Date: 2018.10.04 14:55:29
 IST



QR Code with Photograph

आपका आधार क्रमांक / Your Aadhaar No. :

8380 3246 9631

VID : 9157 7103 4638 4068

मेरा आधार, मेरी पहचान



भारत सरकार

Government of India



Fatima Alves
 Date of Birth/DOB: 08/04/1983
 Female/ FEMALE

8380 3246 9631

VID : 9157 7103 4638 4068



Dr Madkaiker's City hospital
 "Ashirwad bldg" 1st floor,
 Opp Meenaxi hotel
 Isidor Baptista road,
 Margao- Goa 403601

Name: Mrs. Fatima Alves

Age: 40yrs/F

Date: 10/06/23

REF by: Dr R.N.Madkaiker/ CITY HOSPITAL/Medivheel

ABDOMINAL SONOGRAPHY

LIVER : Liver with normal echotexture. No focal lesion seen. Intrahepatic branching of hepatic & portal radicles prominent and within normal limits. Liver normal size 13.5x11 cms
GALL-BLADDER : Normal size, distended, , no calculi. No fluid seen around gall bladder. CBD normal

SPLEEN : Is normal size and shape
PANCREAS : Maintained in its size with normal echotexture.

RIGHT KIDNEY : is normal is size.9.3x4.45cms

LEFT KIDNEY : Is normal in size 11.61x7.08cms
 No calculus seen in lower pole,
 Pelvi calyceal system appears dilated grade 1 hydronephrosis normal.

Is normal in echotexture
 No calculus, or hydronephrosis noted.

PARA AORTIC REGION : Appears Normal

URINARY BLADDER : Fully distended, normal size 7x6 cms central endometrial echo

UTERUS: Uterus appears normal size ith central endometrial echo

NO FREE FLUID SEEN IN POST POUCH

IMPRESSION: NORMAL ABDOMEN AND PELVIC SCAN

SONOLOGIST
 Dr R N Madkaiker




Dr Madkaiker's City hospital
 "Ashirwad bldg" 1st floor,
 Opp Meenaxi hotel
 Isidor Baptista road,
 Margao- Goa 403601

0yrs/F Date:10/06/23

Mediwheel

SONOGRAPHY

re No focal lesion seen.

apatic & portal radicles prominent and within
 size 13.5x11 cms

calculi. No fluid seen around gall bladder. CBD

normal echotexture.

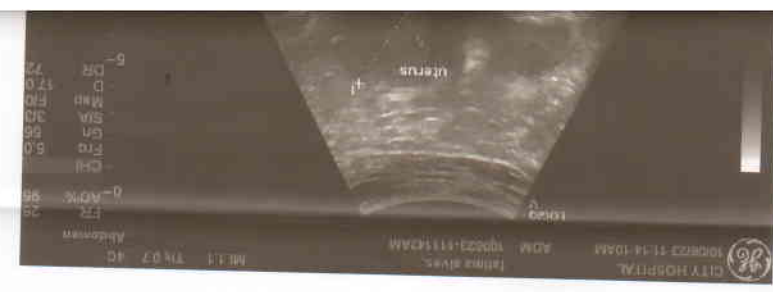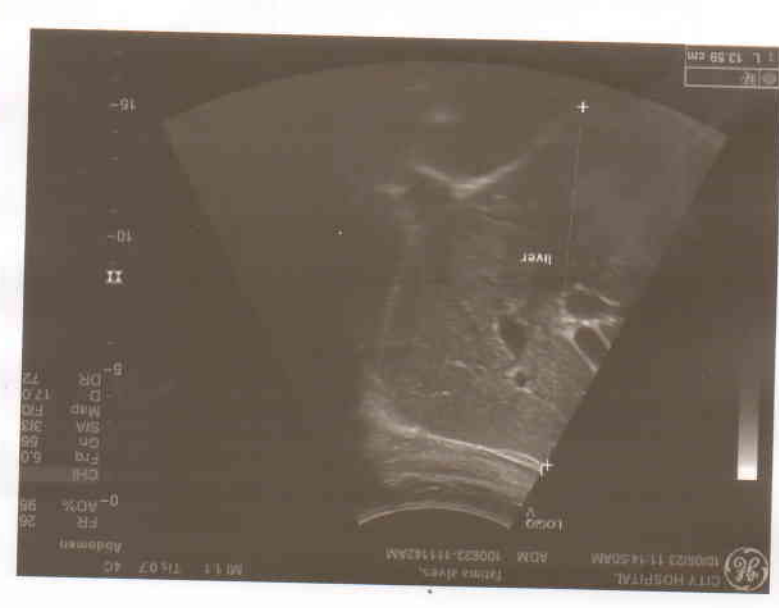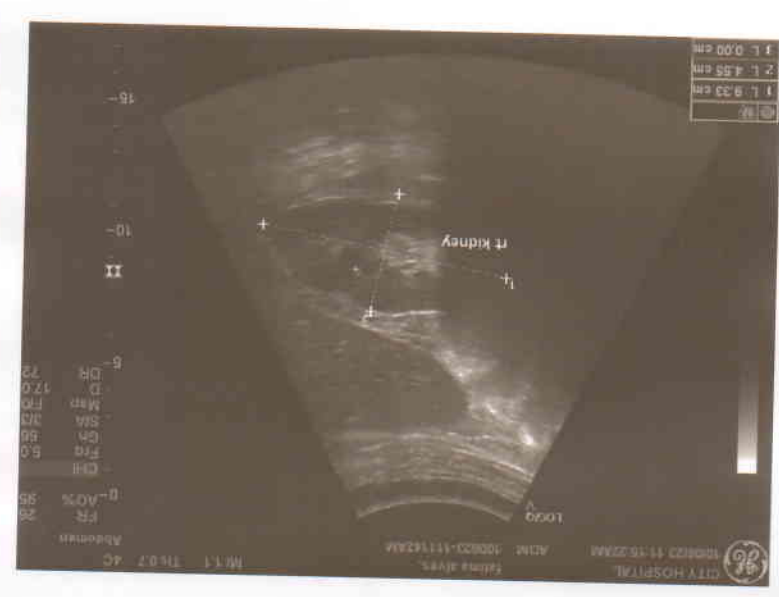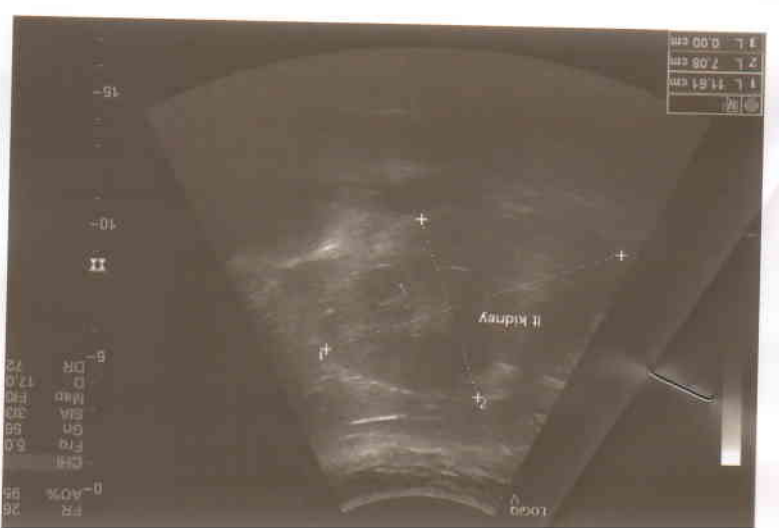
ms
 rs dilated grade I hydronephrosis normal.

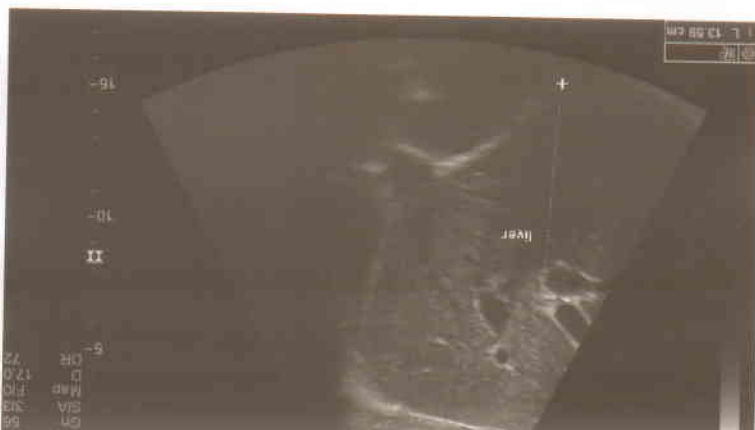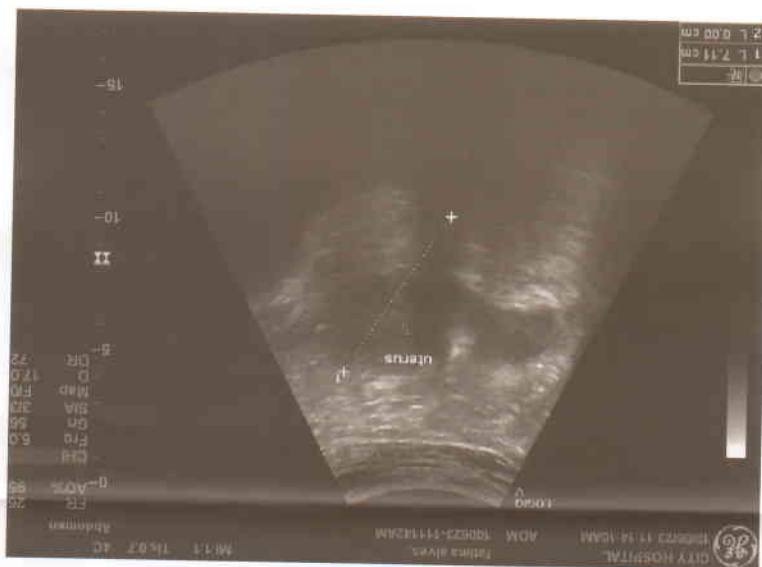
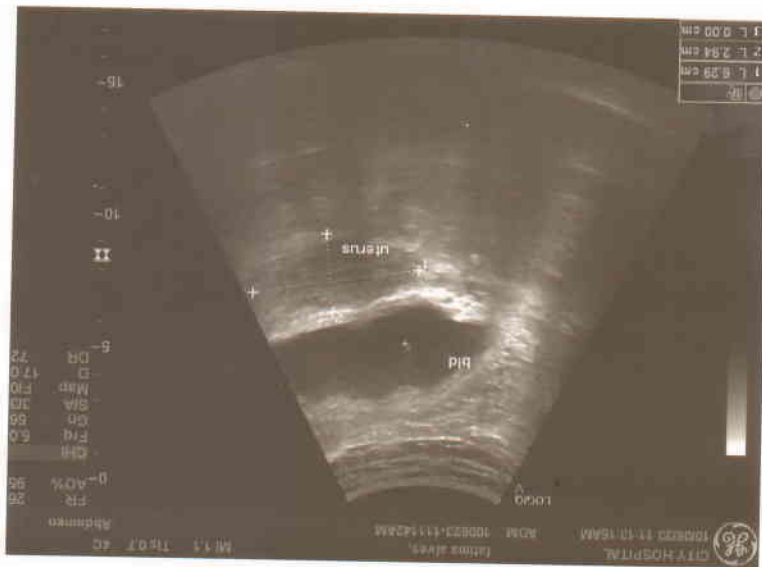ms

sis noted.

size 7x6 cms central endometrial echo
 ral endometrial echo

VIC SCAN
 SONOLOGIST
 Dr R N Madkaiker





6 cms central endometrial echo

dometrial echo

Dr R N Madhakar

SONOLOGIST

CAN



DENTAL EXAMINATION RECORD

Date: 10/06/2023

Name: Fatima Alves

Age: 40yrs. Sex: F

ORAL HEALTH CONDITION:

Date of Examination				
Age last birthday				
Presence of Debris	Y	N	Y	N
Inflammation of Gingiva	Y	N	Y	N
Presence of Calculus	Y	N	Y	N
Under Orthodontic Treatment	Y	N	Y	N

Dentofacial Anomaly, Neoplasms, Others, specify:

Tooth Count		T	P	T	P
Number of Teeth Present					
Number of Caries Free Teeth					
Number of Decayed Teeth	2				
Number of Missing Teeth	6				
Number of Filled Teeth	2				
Total of X-Rays Teeth					

<input type="checkbox"/> Lips	<input type="checkbox"/> Floor of Mouth	<input type="checkbox"/> Palate	<input type="checkbox"/> Tongue	<input type="checkbox"/> Neck & Nodes
-------------------------------	---	---------------------------------	---------------------------------	---------------------------------------

INITIAL PERIODONTAL EXAM

GINGIVAL INFLAMMATION:	<input type="checkbox"/> Slight	<input type="checkbox"/> Moderate	<input type="checkbox"/> Severe
SOFT PLAQUE BUILDUP:	<input type="checkbox"/> Slight	<input type="checkbox"/> Moderate	<input type="checkbox"/> Heavy
HARD CALC BUILDUP:	<input type="checkbox"/> Light	<input type="checkbox"/> Moderate	<input type="checkbox"/> Heavy
STAINS:	<input type="checkbox"/> Light	<input type="checkbox"/> Moderate	<input type="checkbox"/> Heavy
HOME CARE EFFECTIVENESS:	<input type="checkbox"/> Good	<input type="checkbox"/> Fair	<input type="checkbox"/> Poor
PERIODONTAL CONDITION:	<input type="checkbox"/> Good	<input type="checkbox"/> Fair	<input type="checkbox"/> Poor
PERIODONTAL DIAGNOSIS:	<input type="checkbox"/> Normal	<input type="checkbox"/> Gingivitis	<input type="checkbox"/> Advanced
PERIODONTITIS:	<input type="checkbox"/> Early	<input type="checkbox"/> Moderate	<input type="checkbox"/> Advanced
MUCOGINGIVAL DEFECTS:			

CLINICAL DATA:

OCCUSIO N:	<input type="checkbox"/> Class I	<input type="checkbox"/> Class II	<input type="checkbox"/> Class III
T.M.J. EXAM:	<input type="checkbox"/> Pain	<input type="checkbox"/> Popping	<input type="checkbox"/> Deviation
<input type="checkbox"/> Tooth Wear			

DENTAL/ORAL EXAMINATION REVEALED THE FOLLOWING CONDITIONS AND RECOMMENDATIONS.

Needs Prostheses (Denture)	Yes
Needs Oral Hygiene (Materia Alba, Calculus, Stain)	-
Indicated for Restoration/Filling	7/8
Indicated for Extractions	-
Gingival Inflammation	Yes
Needs Oral Prophylaxis	Yes

TO: The Examining Dentist

Dr. Nikita R. Madhakar

Dr. Madhakar

For Endodontic Treatment	-
For Orthodontic Consultation	-
For Pits and Fissures Sealant Application	-
For Pit & Fissures Sealant Application	-
Scalings Others	-
No Dental Treatment Needed at Present	-

Please accomplish the treatment needed and send back this form for inspection. Kindly sign and send back this form for inspection. Kindly sign and send back this form for inspection. Kindly sign and send back this form for inspection.

Speed : 25 mm/sec

Standardization : 1 cm : 1 mv

I

AVR

VI

V4

AUTO 5mm/mV

I

5mm/mV

aVR

5mm/mV

V1

5mm/mV

II

aVL

V2

V4

III

aVF

V3

V5

V5 5mm/mV

25mm/s AC50Hz+EMC35Hz+DFTO. 67HZ

Handwritten signature in blue ink, possibly "Anand".



V4

V1

Handwritten notes and signature in the left margin.

5mm/mV

V1

V2

V3

5mm/mV

V4

V5

V6

2023-06-10 09:32

ID :

Name : fatima alves

Sex : Female Age : 40

Height: cm Weight: kg

SYS : mmHg

DIA : mmHg

HR [bpm] : 70

P Interval [ms] : 192

P Duration [ms] : 120

QRS Duration [ms] : 80

T Duration [ms] : 190

QT/QTc [ms] : 395/427

P/QRS/T Axis [deg] : 32.9/85.8/25.8

R (V5)/S (V1) [mV] : 1.15/0.17

R (V5) + S (V1) [mV] : 1.32

<< Conclusions >>

Normal Sinus Rhythm
Cardiac electric axis normal;

Physician



Referred by :

Sinus

Sudhir Shet
Diagnosis :

DR. SUDHIR SHET
M.D.
CONSULTANT PHYSICIAN
Reg. No.: GMC 3170



val :

plex :

rent :

No.

Dr. Madkaiker's

CITY HOSPITAL

Ashirwad Building, 1st Floor, Opp. Meenaxi Hotel,
Isidor Baptista Road, Margao-Goa - 403 601.

☎ : (H) 2714354 (R) 2703473

E-mail : madkaikercityhospl@rediff.com

ELECTROCARDIOGRAM

Name : *Felina Alves*

Sex : *Female*

Address :

Age : *10 yrs.*

Date : *10/06/23.*



Report

Normal Sinus
Rhythm.

Referred by :

[Signature]
Diagnosis :

Rate :

Rhythm :

P. wave :

P-R Interval :

QRS Complex :

S-T Segment :

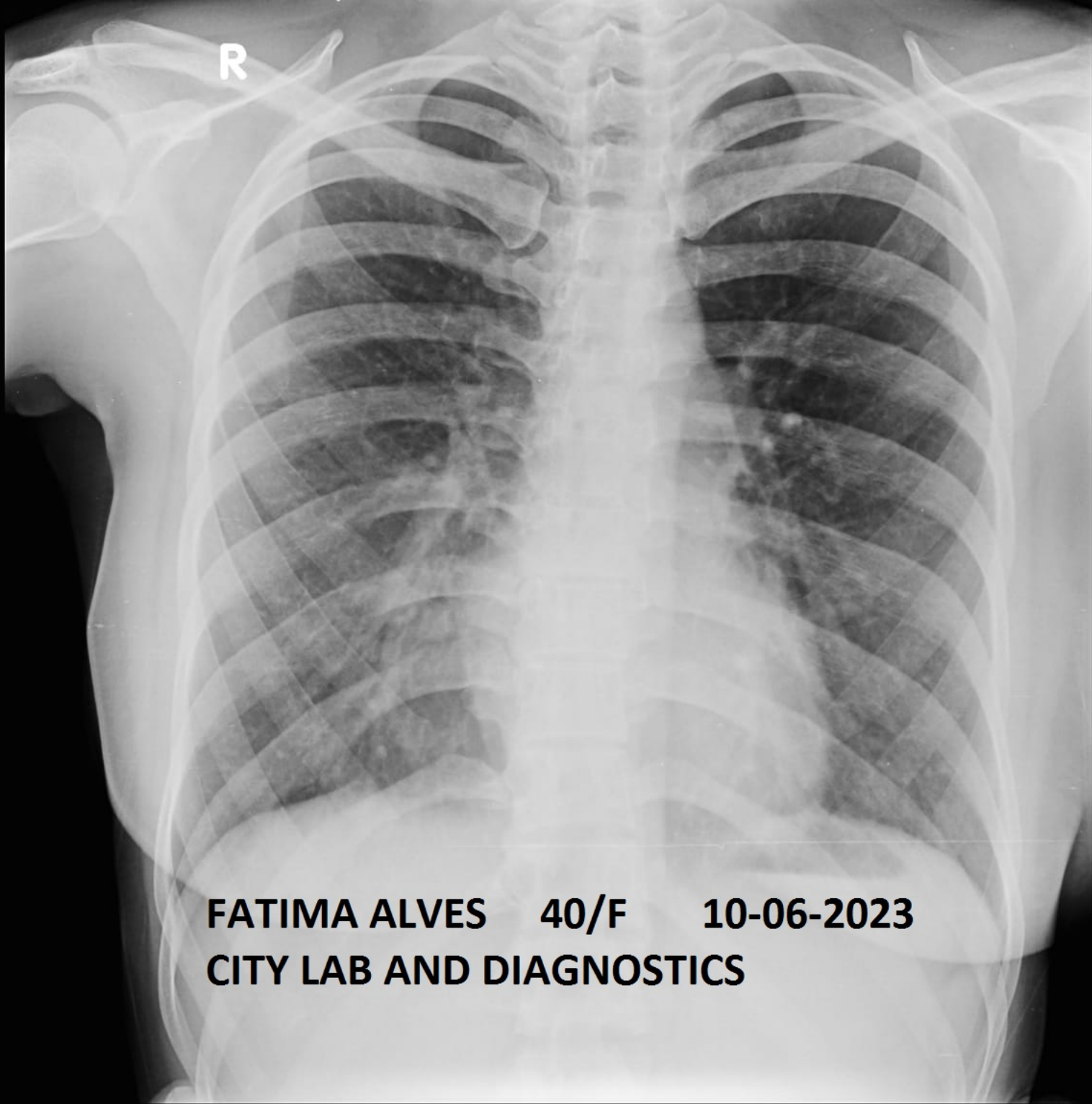
T. wave :

U. wave :

Remarks :

DR. SUDHIR SMET
M.D.
CONSULTANT PHYSICIAN
Reg. No.: GMC 3170





FATIMA ALVES 40/F 10-06-2023
CITY LAB AND DIAGNOSTICS

Dr Madkaiakar's City hospital
 "Ashirwad bldg, 1st floor,
 opp meenaxi hotel,
 Isidor Baptista road,
 Margao- Goa 403601
 Ph. : 2714354

Name of Examinee: MRS. FATIMA ALVES
 Nationality: Indian
 Age: 40 yrs
 Sex: Female
 Date of Examination: 10/06/2023

General Examination & Lifestyle

Height: 155 cms

Weight: 65 kgs
 BMI : 27.1

B.P: 110/60 mmHg

Diet : Mix

Pulse Rate: 70 per min

Personal H/o: illness, fracture, operation, hospitalization, Hypertension, Diabetes and IHD : Diabetes since 4 years.

Past/ Family H/o: Diabetes, TB, Asthma, Hypertension, Allergy and IHD : No

System Examination

CVS: Normal

RS : Normal

CNS: Normal

Abdomen: Normal

Others

Hernia: Nil

Varicose Veins: Nil

Extremities: Nil

Deformities: Nil

Skin: Normal

EYE CHECKUP :

- Far Vision : Right Eye- 6/6
- Near Vision : Right Eye - N/5
- Color Vision: Normal.

Left Eye- 6/6 (With Glasses)
 Left Eye-N/5 (With Glasses)

Dr. R.N. Madkaiakar
 M.D., D.O., D.F.P. & P.S.
 Reg. No. GMC 689
 Medical Director

Signature and stamp of medical Officer



Dr Madkaikar's City hospital
 "Ashirwad bldg, 1st floor,
 opp meenaxi hotel,
 Isidor Baptista road,
 Margao- Goa 403601
 Ph. : 2714354

NAME: Mrs. Fatima Alves

40 yrs/F

Date: 10-06-2023

REF. BY: MEDI WHEEL

COMPLETE HAEMOGRAM

MALE FEMALE
 Haemoglobin 12.4 gm% (13.0-18) (11.5-16.5)

PCV 37.0 cc% (40-50) (37-47)

ESR(westergren's method) 30 mm/hr (up to 15) (up to 20)

R.B.C COUNT 4.2 millions/cm³ (4.5-6.0) (4.0-5.5)

Erythrocytes Indices

MCH 29 pg 27-32

MCHC 32 % 32-36

MCV 86 cu-microns 82-92

Platelet Count 2,12,000 cells/cm³ (150,000-500,000)

Total W.B.C Count 5,400 /cm³ (4,000-10,000)

Differential Count

Neutrophils 58 % (50-70)

Lymphocytes 37 % (20-50)

Eosinophils 02 % (0-8)

Basophils 00 % (0-2)

Monocytes 03 % (0-8)

GLYCOSYLATED HB (HbA1c) 7.8 %
 (A.B.G - 177.8 mg/dl)

Normal : Up to 6%
 Good control : 6-7 %
 Fair control : 7-8 %
 Unsatisfactory: 8-10 %
 Poor control : > 10



Pathologist/Analyst

[Handwritten Signature]

Dr. Shet Sunayana Sudhir
 M.D. (Path.)
 Reg. No. GMC 3311

Dr Madkaikar's City hospital
 "Ashirwad bldg, 1st floor,
 opp meenaxi hotel,
 Isidor Baptista road,
 Margao-Goa 403601
 Ph. : 2714354

NAME: Mrs. Fatima Alves

40 yrs/F

Date: 10-06-2023

REF. BY: MEDI WHEEL

BLOOD BIOCHEMISTRY

TEST	PATIENT'S VALUE	NORMAL RANGE
------	-----------------	--------------

Serum Creatinine	0.8 mg./dl	0.5-1.4mg./dl
------------------	------------	---------------

Serum Uric Acid	3.4 mg./dl	M: 2.4-7.0 F: 2.4-6.0mg./dl
-----------------	------------	-----------------------------

BUN	13.5 mg./dl	5-25 mg/dl
-----	-------------	------------

BUN/CREATINE	16.8 mg./dl	5-20 mg/d
--------------	-------------	-----------

LFT		
-----	--	--

Total Bilirubin	0.8 mg./dl	0.2-1.0 mg./dl
-----------------	------------	----------------

Direct Bilirubin	0.2 mg./dl	0.1-0.2 mg./dl
------------------	------------	----------------

Indirect Bilirubin	0.6 mg./dl	Up to 0.8 mg/dl
--------------------	------------	-----------------

S.G.P.T	26.0 Units/L	0-49 units/L
---------	--------------	--------------

S.G.O.T	22.0 Units/L	0-46 units/L
---------	--------------	--------------

Alkaline Phosphatase	179.0 Units/L	108-306 units/L
----------------------	---------------	-----------------

Total Protein	7.4 gm./dl	6-8 gm.dl
---------------	------------	-----------

Albumin	3.8 gm./dl	3.5-5.5gm./dl
---------	------------	---------------

Globulin	3.6 gm./dl	1.8-3.6gm/dl
----------	------------	--------------

A/G	1.1	1.2-2.1
-----	-----	---------

LIPID PROFILE		
---------------	--	--

Serum Cholesterol	178.0 mg./dl	25-260 mg./dl
-------------------	--------------	---------------

Serum Triglycerides	145.0 mg./dl	M:60-165 F:40 140mg./dl
---------------------	--------------	-------------------------

HDL Cholesterol	44.0 mg./dl	M:30-63 F: 35- 75 mg./dl
-----------------	-------------	--------------------------

LDL Cholesterol	105.0 mg./dl	Up to 145 mg./dl
-----------------	--------------	------------------

Total Chol/HDL Chol Ratio	4.0	2-5
---------------------------	-----	-----

LDL Chol/HDL Chol Ratio	2.4	Up to 3.5
-------------------------	-----	-----------

HEMATOLOGY

TEST	PATIENT'S VALUE	REFERENCE RANGE
------	-----------------	-----------------

BLOOD GROUP	'O' Rh-"POSITIVE"	
-------------	-------------------	--



[Handwritten Signature]
 Pathologist/Analyst

Dr. Shet Sunayana Sudhir
 M.D. (Path.)
 Reg. No. GMC 3311

NAME: Mrs. Fatima Alves

REF. BY: MEDI WHEEL

GLUCOSE TEST

Time	Blood Sugar	Urine sugar
'0' Hrs (fasting)	179.0 mg/dl	TRACE
2Hrs.after Breakfast	222.0 mg/dl	++

EXAMINATION OF URINE

PHYSICAL EXAMINATION

Colour ... Pale yellow

Odour ... Ammonical

Appearance Clear

pH. 6.0

Sp. Gravity ... 1.020

Deposits ' ... Nil

MICROSCOPIC EXAMINATION

Pus cells/HPF 1-2

R.B.C.s /HPF Nil

Epithelial Cells/HPF ... 1-2

Crystals/HPF Nil

Casts/HPF Nil

CHEMICAL EXAMINATION

Albumin ... Absent

Sugar ... TRACE

Ketone bodies ... Nil

Bilirubin Nil

Occult Blood ... Nil

Urobilinogen... Nil

OTHER FINDINGS : Nil

Dr Madkaikar's City hospital
 "Ashirwad bldg, 1st floor,
 opp meenaxi hotel,
 Isidor Baptista road,
 Margao- Goa 403601
 Ph. : 2714354

40 yrs/F

Date: 10-06-2023



Dr. Shet Sunayana Sudhir
 M.D. (Path.)
 Reg. No. GMC 3311

Pathologist/Analyst

Dr Madkaikar's City hospital
"Ashirwad bldg, 1st floor ,
opp meenaxi hotel,
Isidor Baptista road,
Margao- Goa 403601
Ph. : 2714354

NAME: Mrs. Fatima Alves

REF. BY: MEDI WHEEL

THYROID FUNCTION TEST

Investigation	Observed Value	Unit
T3	2.83	ng/dL
T4	98.78	ug/dl
TSH	4.11	µIU/ml

Sample : Serum.

Method : FULLY AUTOMATED ELFA METHOD.



Pathologist/Analyst

Dr. Shet Sunayana Sudhir
M.D. (Path.)
Reg. No. GMC 3311

CITY LAB
(Clinical laboratory)

Dr Madkaikar's City hospital
"Ashirwad bldg, 1st floor,
opp meenaxi hotel,
Isidor Baptista road,
Margao- Goa 403601
Ph. : 2714354

NAME: Mrs. Fatima Alves 40 yrs/F Date: 10-06-2023

REF. BY: MEDI WHEEL

PAP SMEAR REPORT

Specimen Type : Conventional pap smear

Adequacy of Specimen : Satisfactory for Evaluation

Cells : Superficial & Intermediate Squamous Epithelial
Cells. NO evidence of atypia.

Interpretation of (negative) Non malignant abnormalities: Mild inflammatory smear

Interpretation of epithelial Cell Abnormalities :
Negative for Intraepithelial lesion or Malignancy
Perimenopausal state.

Recommendation Repeat PAP smear after antibiotic therapy.



Dr. Shet Sunayana Sudhir
M.D. (Path.)
Reg. No. GMC 3311
Pathologist/Analyst

Dr Madkaikar's City hospital
"Ashirwad bldg, 1st floor ,
opp meenaxi hotel,
Isidor Baptista road,
Margao- Goa 403601
Ph. : 2714354

(Clinical laboratory)

CITY LAB

NAME: Mrs. Fatima Alves

REF. BY: MEDI WHEEL

X-RAY Chest PA

Lungs are clear.

Hilar and the mediastinal shadows are normal.

Pleura, the c.p angles are clear.

Cardiac aortic Silhouette is normal

Soft tissues of the chest wall and Bony cage are normal.

Impression: Normal


T. Shetty

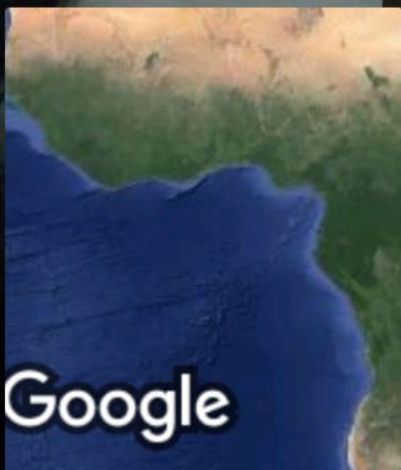

Dr. Francis Almeida
M.B.B.S. D.M.R.D. (30M) F.R.C.S. (CPS)
Consultant Radiologist
Reg. No. 1553 GMC

Dr. Raj R. Madkaikar
M. B. B. S, D.G.O, D.M.A.S, F.M.A.S, AFIH
Consulting Obstetrician & Gynaecologist
Laposcopist & Assisted Reproduction Clinic



 GPS Map Camera



Margao, Goa, India

2, near Punjab National Bank, New Market,
Margao, Goa 403601, India

Lat 15.272047°

Long 73.961147°

10/06/23 09:24 AM GMT +05:30