



భారత ప్రభుత్వం  
GOVERNMENT OF INDIA

పరిశోధనా  
P Chalthanya



జన్మ సంవత్సరం Year of Birth 1989  
పురుషుడు : Male



4070 8955 5168

అధికారి - సామాన్య ని హక్కు

భారత ప్రభుత్వం  
GOVERNMENT OF INDIA

పరిశోధనా  
S/O Paruchuri

చిరునామా: S/O Paruchuri  
Chenchaiah, 20-1-470-17C,  
c s r colony, korlagunta,  
Tirupati (Urban), Tirupati,  
Chittoor, Andhra Pradesh,  
517501

చిరునామా: S/O పరుచూరి వెంకట్రావు  
20-1-470-17C, సి యస్ ఆర్ కాంపి  
కొర్లగుంట, తిరుపతి, చిత్తూరు  
ఆంధ్ర ప్రదేశ్, 517501

1947  
1800 180 1947

help@uidai.gov.in

www.uidai.gov.in

సం. ప్ర. 20, 1947.  
20-1-470-17C

Phanthu





# MURUGAN HOSPITALS

HEALING HANDS



## LAB REPORT

Patient Name : Mr. P.CHAITHANYA  
Age / Gender : 33-Years / Male  
UHID ID : MH20220041816  
Doctor Name : Dr. ARUN PRAKASH

OP Report No. : INVA2107894  
Bill No. : INV2205626  
Sample Date : 26/11/2022 - 09:30 AM  
Report Date : 26/11/2022 - 04:04 PM

Test Name	Result	Units	Reference Interval
-----------	--------	-------	--------------------

### HAEMATOLOGY

#### Complete Blood Cell Count(CBC)

HAEMOGLOBIN	14.0	gms/dl	male :13.0 - 17.0 female :12.0 - 15.0
PACKED CELL VOLUME	42.5	%	male : 40 - 50 female : 36 - 46
RBC COUNT	<u>4.87</u>	millions cells/cu.mm	female: 3.8 - 4.8 male : 4.5 - 5.5
TOTAL WBC	7,900	Cells/Cumm	4,000 - 11,000
<b>Differential Count</b>			
NEUTROPHILS	58	%	40 - 65
LYMPHOCYTES	36	%	30-50
EOSINOPHILS	04	%	01-06
MONOCYTES	02	%	1-10
BASOPHILS	00	%	0-2
ESR 60 MTS	05	mm	5 - 20
PLATELET COUNT	1.77	Lakhs/cumm	1.5 - 4.5
MCV	87.3	fL	76 - 96
MCH	28.7	pg	27 - 32
MCHC	32.9	gms/dl	30 - 36

INTERPRETATION: Test done on automated three part cell counter, all abnormal results are reviewed and confirmed microscopically.

**BLOOD GROUPING & RH TYPING** \* AB\* POSITIVE

Page 1 of 4

**Healing Hearts and Lives**

264/125, Kilpauk Garden Road, Kilpauk, Chennai - 600 010.  
Phone : +91 44 4644 8989 / 75500 53335 | Email : muruganhosp@gmail.com  
Website : www.muruganhospitals.in





# MURUGAN HOSPITALS

HEALING HANDS



## LAB REPORT

Patient Name : Mr. P.CHAITHANYA

Age / Gender : 33-Years / Male

UHID ID : MH20220041816

Doctor Name : Dr. ARUN PRAKASH

OP Report No. : INVA2107894

Bill No. : INV2205626

Sample Date : 26/11/2022 - 09:30 AM

Report Date : 26/11/2022 - 04:04 PM

Test Name	Result	Units	Reference Interval
-----------	--------	-------	--------------------

### BIO CHEMISTRY

<b>BLOOD SUGAR FASTING</b>	88	mg/dl	70-110
<b>BLOOD SUGAR POST PRANDIAL</b>	101	mg/dl	80- 160
<b>SERUM CREATININE</b>	0.9	mg/dl	0.6-1.4
<b>SERUM URIC ACID</b>	4.3	mg/dl	male 3.1-7.0 , female 2.5-5.6
<b>LIPID PROFILE</b>			
TOTALCHOLESTEROL	165	mg/dl	< 200
TRIGLYCERIDE	68	mg/dl	< 150
HDL	45	mg/dl	35 - 80
VLDL	14	mg/dl	2 to 30
LDL	106	mg/dl	<130
CHOLESTEROL/ HDL RATIO	3.6	mg/dl	

**Healing Hearts and Lives**

264/125, Kilpauk Garden Road, Kilpauk, Chennai - 600 010.

Phone : +91 44 4644 8989 / 75500 53335 | Email : muruganhosp@gmail.com

Website : www.muruganhospitals.in





# MURUGAN HOSPITALS

HEALING HANDS



## LAB REPORT

Patient Name : Mr. P.CHAITHANYA

Age / Gender : 33-Years / Male

UHID ID : MH20220041816

Doctor Name : Dr. ARUN PRAKASH

OP Report No. : INVA2107894

Bill No. : INV2205626

Sample Date : 26/11/2022 - 09:30 AM

Report Date : 26/11/2022 - 04:04 PM

Test Name	Result	Units	Reference Interval
<b>LIVER FUNCTION TEST</b>			
BILLIRUBIN(TOTAL)	0.6	mg/dl	0.0 -1.0
BILLIRUBIN(DIRECT)	0.2	mg/dl	0.1- 0.30
BILLIRUBIN(INDIRECT)	0.4	mg/dl	0.2-0.8
SGOT	22	IU/L	0-38
SGPT	14	IU/L	0.0-40
ALKALINE PHOSPHATASE	52	IU/L	40-140 4-6Years 93-309 13-15Years 74-390
TOTAL PROTEIN	7.2	gm/dl	6.6-8.7
ALBUMIN	4.3	gm/dl	3.5 - 5.5
GLOBULIN	2.9	gm/dl	2.0-3.5
AG RATIO	1.4		
<b>GAMMA G T</b>	10	U/L	male<49 female<32
<b>BLOOD UREA NITROGEN</b>	9.8	mg/dl	7-21
<b>HBA1C</b>	5.0	%	normal: <6.0 good control: 6.1-7.0 fair control: 7.1- 8.0 poor control:8.1 -10.0 unsatisfactory: >10.0

**Healing Hearts and Lives**

264/125, Kilpauk Garden Road, Kilpauk, Chennai - 600 010.

Phone : +91 44 4644 8989 / 75500 53335 | Email : muruganhosp@gmail.com

Website : www.muruganhospitals.in





# MURUGAN HOSPITALS

HEALING HANDS



## LAB REPORT

Patient Name : Mr. P.CHAITHANYA

Age / Gender : 33-Years / Male

UHID ID : MH20220041816

Doctor Name : Dr. ARUN PRAKASH

OP Report No. : INVA2107894

Bill No. : INV2205626

Sample Date : 26/11/2022 - 09:30 AM

Report Date : 26/11/2022 - 04:04 PM

Test Name	Result	Units	Reference Interval
<b><u>CLINICAL PATHOLOGY</u></b>			
URINE SUGAR (F)	Nil		
URINE SUGAR (PP)	Nil		
<b>URINE ROUTINE</b>			
COLOUR	Pale yellow		
APPEARANCE	Clear		
REACTION	Acidic		
SUGAR	Nil		
ALBUMIN	Nil		
<b>DEPOSITES</b>			
PUS CELLS	2 - 3	/ HPF	
EPI CELLS	1 - 2	/ HPF	
RBC COUNT	Nil	/ HPF	
CAST	Nil		
CRYSTALS	Nil		
OTHERS	Nil		

SHENBAGAVALLI

Verified by

\*\*\* End of Report \*\*\*



PAVITHRA

Pathologist

Reg. No. 78256

Healing Hearts and Lives

264/125, Kilpauk Garden Road, Kilpauk, Chennai - 600 010.

Phone : +91 44 4644 8989 / 75500 53335 | Email : muruganhosp@gmail.com

Website : www.muruganhospitals.in





# MURUGAN HOSPITALS

HEALING HANDS



## LAB REPORT

NAME : MR. CHAITHANYA P  
PIN : AND22380178360  
AGE/GENDER : 33 Year(s)/Male  
REFERRED BY : Dr. ARUN PRAKASH  
CLIENT NAME : MURUGAN HOSPITAL

SAMPLE NO : 3822117980  
COLLECTED ON : 26/11/2022 03:26 PM  
RECEIVED ON : 26/11/2022 03:26 PM  
REPORTED ON : 26/11/2022 04:48 PM  
REPRINT DATE : 26/11/2022 04:49 PM

Test	Obtained Value	Units	Bio.Ref.Intervals
<b>IMMUNOASSAY</b>			
PSA(Prostate Specific Antigen) - Total, Serum (SERUM,ECLIA)	0.244	ng/mL	<= 1.4

-- End of Report --



*D. Sakthivel*

D. SAKTHIVEL M. Sc  
BIOCHEMIST

Page 1 / 1

**Healing Hearts and Lives**

264/125, Kilpauk Garden Road, Kilpauk, Chennai - 600 010.  
Phone : +91 44 4644 8989 / 75500 53335 | Email : muruganhosp@gmail.com  
Website : www.muruganhospitals.in





# MURUGAN HOSPITALS

HEALING HANDS



## ECHO CARDIOGRAM REPORT

NAME : MR. P.CHAITHANYA

UHID NO: MH20220041816

AGE&SEX : 33Y/MALE

IP/OP : OUTPATIENT

CONSULTANT: DR. ARUN PRAKASH

DATE : 26-11-2022

### 2D PLAX (mm)

RV - 28 mm  
AO - 36 mm  
LA - 34 mm

### COLOR DOPPLER

Normal

### M-Mode (mm)

IVS - 07 mm  
PW - 09 mm  
LVD - 43 mm  
LVS - 27 mm  
EF - 68 %  
FS - 37 %


### DOPPLER (m/sec)

MITRAL E - 0.6 m/s  
MITRAL A - 0.5 m/s  
PULMONARY - 0.9 m/s  
AORTIC - 0.9 m/s  
TRICUSPID - 0.4 m/s

### IMPRESSION:

No RWMA  
Normal biventricular function  
No pulmonary hypertension  
No pericardial effusion  
No clot/ Vegetation.

DR. S. BHARTAN MD.,DM.,  
CONSULTANT CARDIOLOGIST



Healing Hearts and Lives

264/125, Kilpauk Garden Road, Kilpauk, Chennai - 600 010.

Phone : +91 44 4644 8989 / 75500 53335 | Email : muruganhosp@gmail.com

Website : www.muruganhospitals.in





**SCAN REPORT**

NAME :MR. P.CHAITHANYA  
AGE / SEX :33Y /MALE  
CONSULTANT: DR. ARUN PRAKASH

UHID NO : MH20220041816  
IP / OP NO: OUTPATIENT  
DATE : 26-11-2022

**ULTRA SOUND SCAN OF ABDOMEN**

**LIVER:** Normal in size and measures- 13.8 cm and **normal** in echotexture. No focal lesions are seen. No dilatation of intra-hepatic biliary radicals present. Hepatic veins and IVC appear normal. Portal vein is normal in caliber. Common bile duct is normal in caliber.

**GALL BLADDER:** Normal in size and wall thickness. No evidence of any calculus or mass present. No evidence of pericholecystic collections.

**PANCREAS:** Normal in size and echotexture. No focal lesions are seen. No evidence of calculi or calcifications. No evidence of pancreatic duct dilation.

**PARA AORTIC AREAS:** Aorta and IVC appear normal. No evidence of para aortic lymphadenopathy.

**SPLEEN:** Normal in size and measures 10.4 cm. Normal in echotexture. No evidence of focal lesions.

**RIGHT KIDNEY:** Measures 9.1 X 3.9 cm and is normal in size and echotexture. Cortico medullary differentiation is well maintained. There is no calculus or hydronephrosis or mass.

**LEFT KIDNEY:** Measures 9.9 X 5.1 cm and is normal in size and echotexture. Cortico medullary differentiation is well maintained. There is no calculus or hydronephrosis or mass.

**Healing Hearts and Lives**

264/125, Kilpauk Garden Road, Kilpauk, Chennai - 600 010. Phone : +91 44 4644 8989 / 75500 53335  
Email : muruganhosp@gmail.com | Website : www.muruganhospitals.in



**URINARY BLADDER:** Normal in size, contour and wall thickness. There is no evidence of calculus or mass. No vesical diverticulum present.

**PROSTATE:** Normal in size and echotexture. Measures 2.5 X 3.9 X 3.2 cm and approximate volume being 17.1 cc. Seminal vesicles appear normal.

No ascites present. No retroperitoneal lymphadenopathy present.

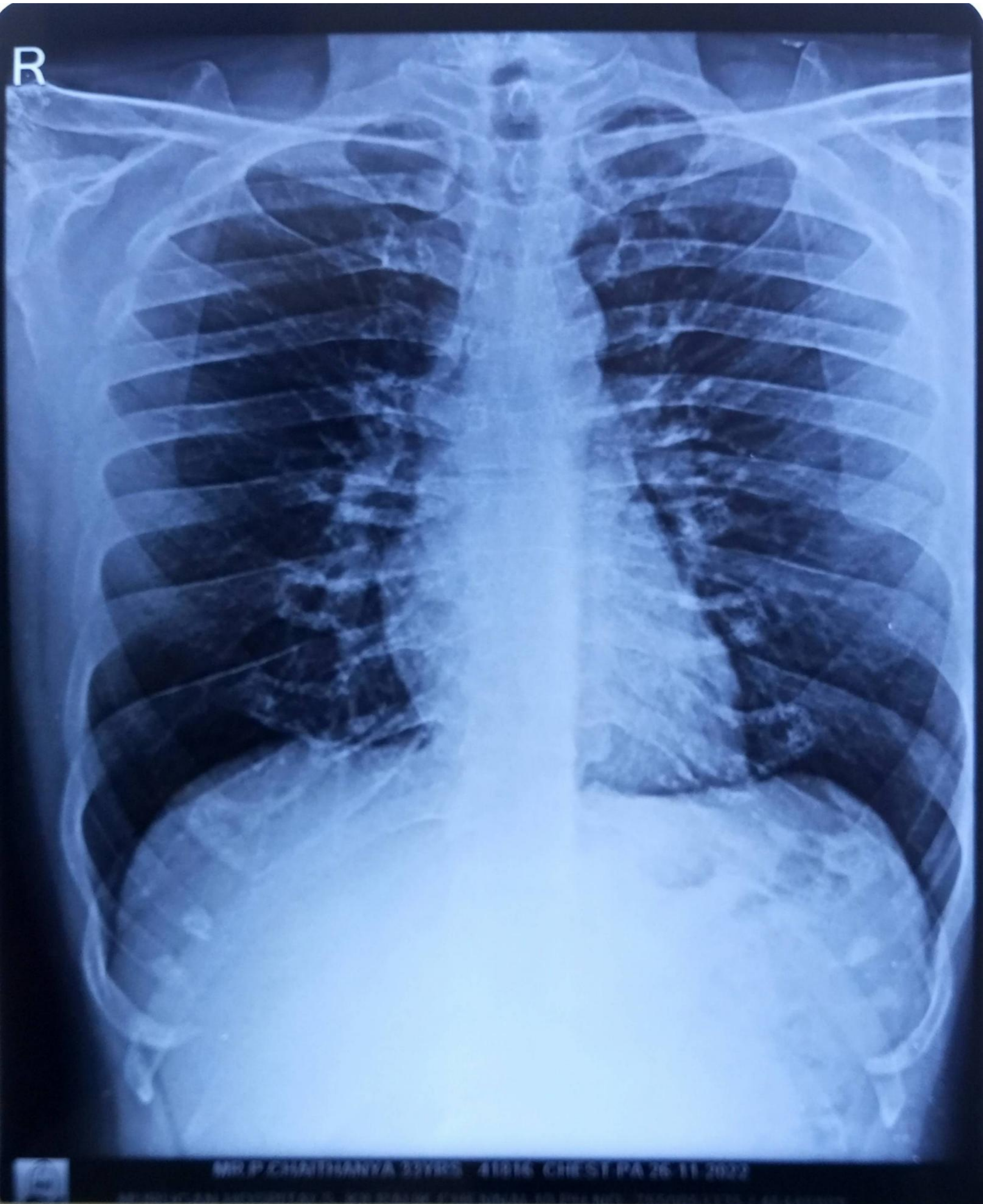**IMPRESSION:**

- No significant abnormality detected seen in the visualized organs.

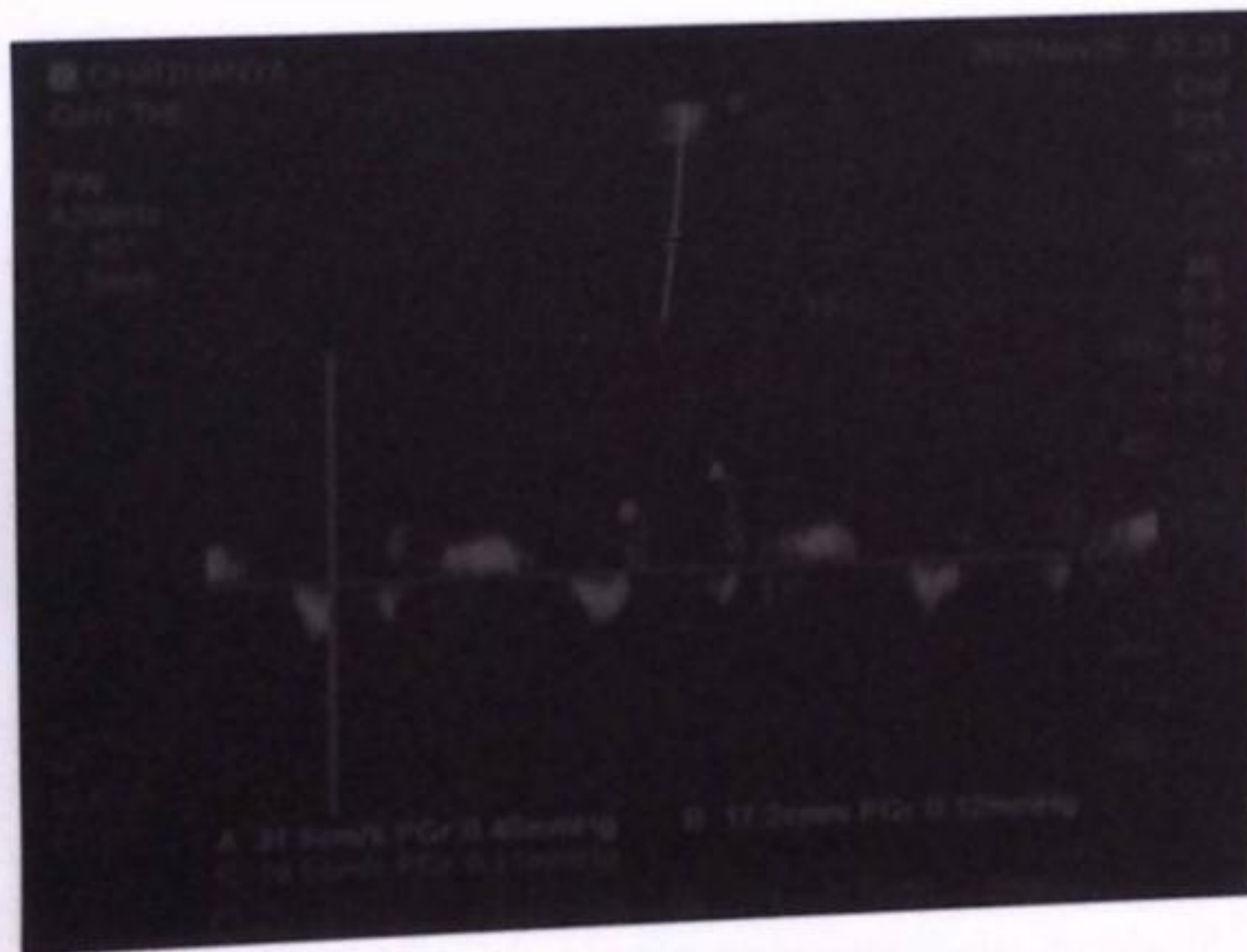
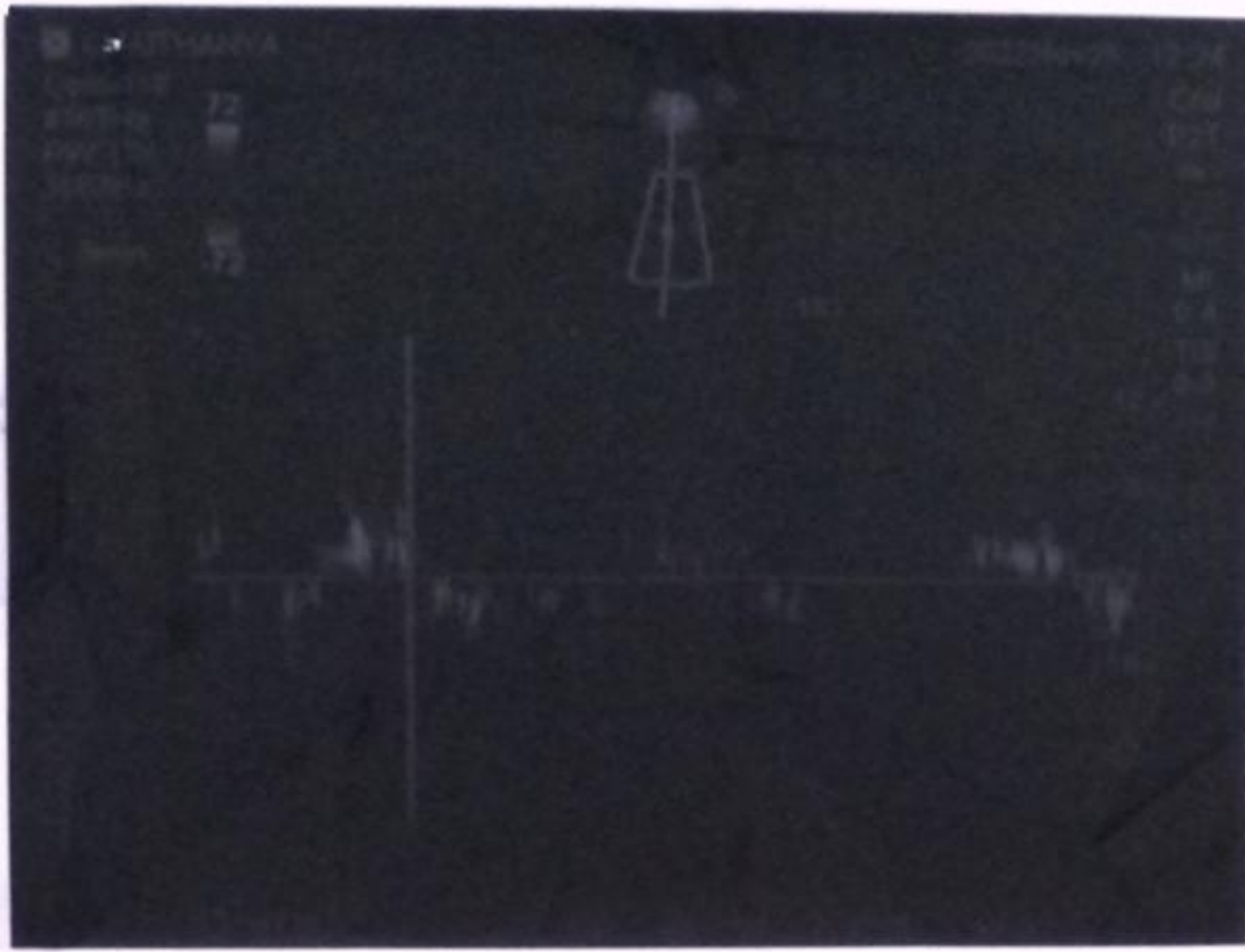
A circular blue ink stamp from Murugan Hospital. The outer ring contains the text "MURUGAN HOSPITAL" at the top and "Salem" at the bottom. In the center, there is a logo featuring a hand holding a caduceus. Below the stamp, the text "Dr. SAKTHI, M.D." and "Consultant Radiologist." is printed in a bold, black font.

**Dr. SAKTHI, M.D.**  
**Consultant Radiologist.**

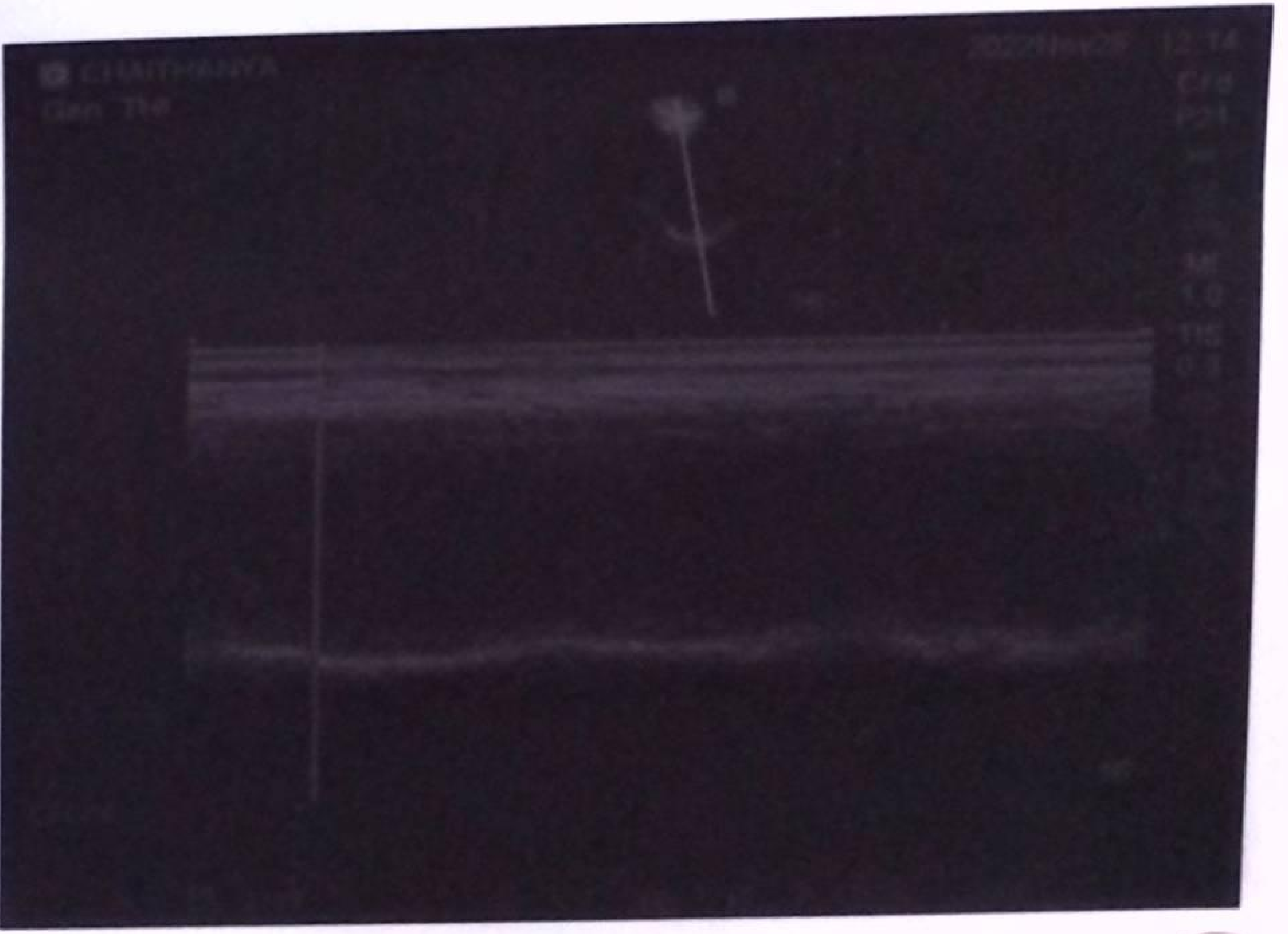




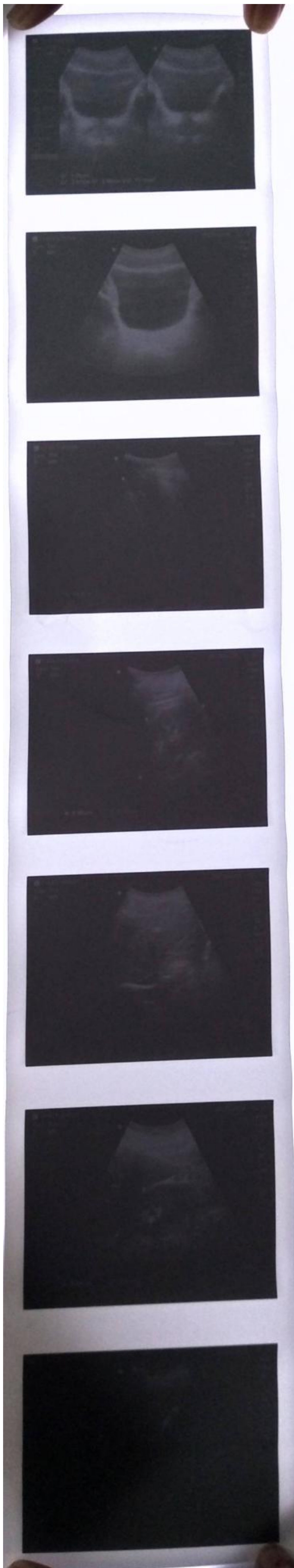





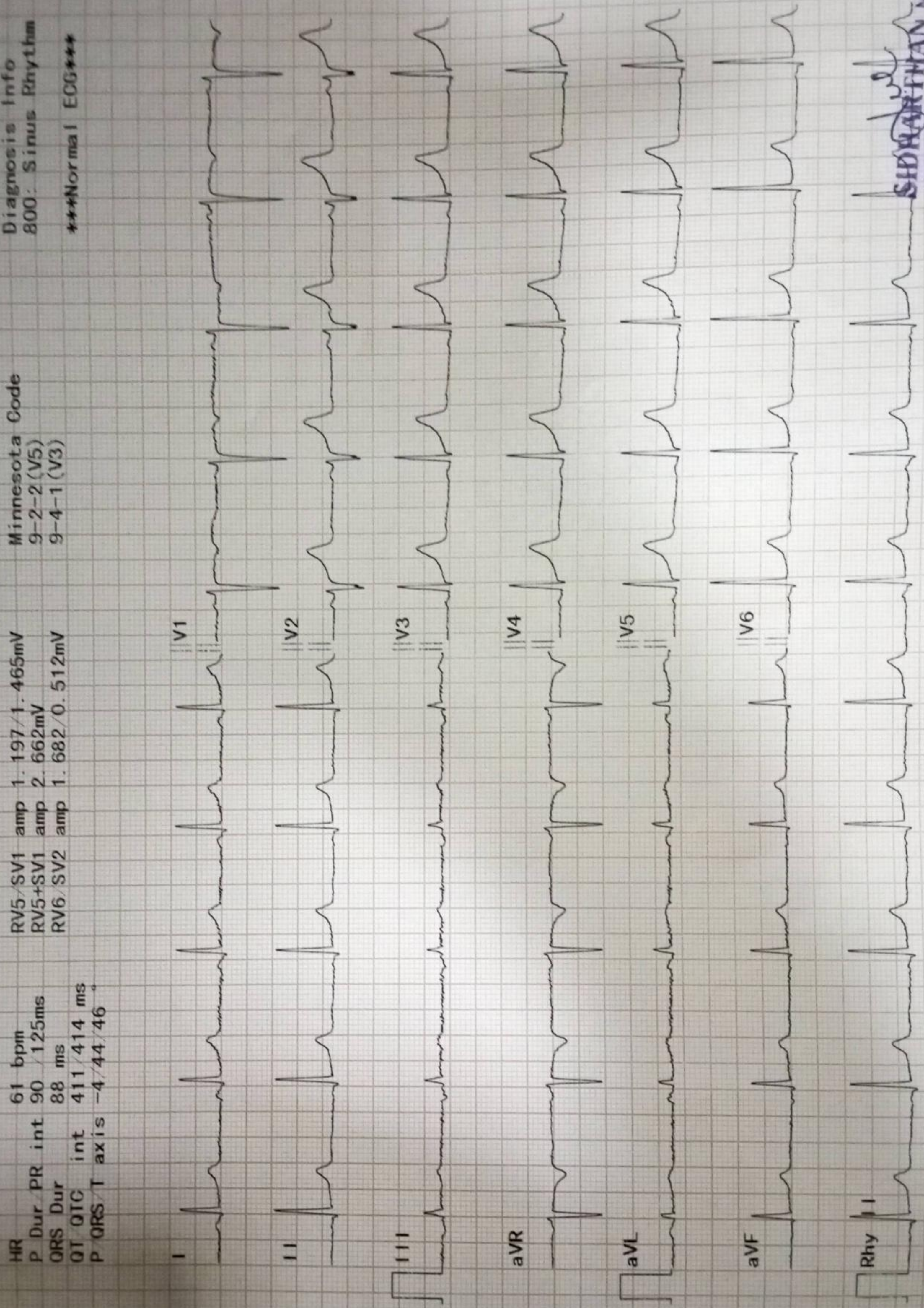








ID : 2211260001      DataTime: 2022-11-26 09:29      PatientID:      Hospital: MURUGAN HOSPITALS  
 Name: MR CHATHANYA      Age : 33      Height : 182 cm      Diagnosis Info  
 Sex : Male      BP : 110/70 mmHg      Weight : 80 kg      800: Sinus Rhythm  
 Divisions:      Bed No.:      Hospital No.:      \*\*\*Normal ECG\*\*\*  
 HR 61 bpm      Minnesota Code  
 P Dur/PR int 90/125ms      RV5/SV1 amp 1.197/1.465mV      9-2-2(V5)  
 QRS Dur 88 ms      RV5+SV1 amp 2.662mV      9-4-1(V3)  
 QT/QTc int 411/414 ms  
 P/QRS/T axis -4/44/46



Diagnosis for reference, ask your doctor to confirm  
 AUTO PRINT 6X2+1R 61bpm      10 mm/mV      0.50Hz-35Hz      AC 50Hz      25 mm/sec      Confirmed By:

SIDDHARTHAN MD, DM  
 Consultant Cardiologist  
 Reg. No: 62979





# MURUGAN HOSPITALS

HEALING HANDS

**NAME : MR.CHAITHANYA**  
**AGE /GENDER:33YRS/ MALE**  
**CONSULTANT: DR.ARUNPRAKASH**

**UHID : MH20220041816**  
**IP/OP : OP**  
**DATE : 26.11.2022**

## X-RAY CHEST (PA VIEW)

- The cardio thoracic ratio is normal
- The heart size and configuration are within normal limits
- The aortic arch is normal
- The lung fields show normal broncho- Vascular markings
- Both the pulmonary hila are normal in size
- The costophrenic and cardiophrenic recesses and the domes of diaphragm are normal
- The bones and soft tissues of the chest wall show no abnormality

### IMPRESSION:

Normal Study



264/125, Kilpauk Garden Road, Kilpauk, Chennai - 600 010.

☎ : +91 44 4644 8989 / 75500 53335 email : muruganhosp@gmail.com

Website : www.muruganhospitals.in